22101896668

Med
K51618

M. VIII Cab

STUDIES IN

CLINICAL VETERINARY MEDICINE AND SURGERY

By P. J. CADIOT

Professor of Surgery at the Veterinary School of Alfort; late President of the Central Society of Veterinary Medicine of Paris.

TRANSLATED, EDITED, AND SUPPLEMENTED
WITH 49 NEW ARTICLES AND 34 ILLUSTRATIONS

By JNO. A. W. DOLLAR, M.R.C.V.S.

Corresponding Member of the Central Society of Veterinary Medicine of Paris;
Life Member of the Royal Italian Society of Hygiene;
Corresponding Associate of the Royal Spanish Society of Hygiene;
Corresponding Member of the Society of Veterinary Medicine of Brabant (Belgium);
Honorary Associate of the Spanish Society of Arts; etc.

EDINBURGH
DAVID DOUGLAS, 10, CASTLE STREET.

1900.

[*ALL RIGHTS RESERVED.*]

2232526

WELLCOME
HISTORICAL
MEDICAL
LIBRARY

WELLCOME INSTITUTE
LIBRARY

Coll.	welMOmec
Call	
No.	V

TO

VICTOR HORSLEY

This work is, with permission, dedicated

AS A

TOKEN OF RESPECT AND GRATITUDE

BY

THE TRANSLATOR AND CO-AUTHOR.

BY THE SAME AUTHOR.

Royal 8vo, 438 pages, 406 illustrations.

A HANDBOOK OF HORSE-SHOEING,

With Introductory Chapters on the Anatomy and Physiology of the Horse's Foot, and 54 full-page plates with descriptive notes by Albert Wheatley, F.R.C.V.S.

60 *large pages* (14½ × 10 *inches*), 315 *illustrations.*

AN ATLAS OF VETERINARY SURGICAL OPERATIONS.

Demy 8vo, 42 pages, 16 full-page plates.

A SURGICAL OPERATING TABLE FOR THE HORSE.

Royal 8vo, 732 pages, 142 illustrations.

MÖLLER'S VETERINARY SURGERY,

Translated from the last German edition and Edited by

JNO. A. W. DOLLAR, M.R.C.V.S.

PREFACE.

NOTWITHSTANDING the general consensus of opinion in favour of clinical teaching, this method of instruction has until recently been somewhat neglected in British veterinary schools. In Germany, on the other hand, ambulatory cliniques occupied an important position from a very early date, and in the two great French schools of Lyons and Alfort clinical demonstrations have received an extension and been brought to a pitch of perfection probably unsurpassed elsewhere.

Convinced from my student's days of the value of this system I was greatly attracted by the impromptu lectures at Alfort, and early began the collection of extensive notes, and in some cases of drawings, designing on my return home to publish a small clinical volume. Pressure of literary and other work unfortunately—or perhaps fortunately—rendered this impossible. Meanwhile Professor Cadiot, one of the foremost clinical teachers in France, whose instruction I consider myself fortunate in having received, gave a renewed impulse to my purpose by the publication last year of his 'Études de Pathologie et de Clinique.' A glance at this admirable work convinced me that in great part at least my work had been anticipated, and that instead of pursuing my original intention I should better serve the interests of English-speaking colleagues by assuming the humble but (from their standpoint) no less useful part of translator, utilising my own material and that to be derived from English literature by way of supplement to the experiences of my former teacher.

On this conviction I have acted. The first part of the original

work, together with certain chapters considered of minor interest, have been omitted; forty-nine new articles have been added, and the number of illustrations has been nearly doubled.

To Professor Cadiot, who has extended to me every assistance in his power, I hereby express my liveliest gratitude; while for the unfailing patience and friendly sympathy with which Professor McQueen, of the Royal Veterinary College, London, has carried through the task of reading the proof-sheets of the present work I desire to tender him my sincerest thanks.

JNO. A. W. DOLLAR.

56, New Bond Street, London, W.;
September 29th, 1900.

CONTENTS.

PART I.

SURGICAL PATHOLOGY AND PRACTICE.

		PAGE
I.	Dentigerous cysts in the temporal region	1
II.	Purulent collections in the facial sinuses and dental caries	8
III.	Affections of the turbinated bones in the horse	15
IV.	Tumours in the facial sinuses and cancer of the superior maxilla	22
V.	The surgical treatment of chronic roaring	30
VI.	Acute inguinal hernia	35
VII.	Deep-seated inguinal abscess after castration	40
VIII.	Diaphragmatic hernia	44
IX.	Blennorrhœa in the dog	52
X.	Amputation of the penis in the horse	56
XI.	Radial paralysis in the horse	64
XII.	The treatment of spavin	72
XIII.	The treatment of picked-up nail	78
XIV.	Plantar neurectomy	86
XV.	Neurectomy of the median and of the ulnar nerves	92
XVI.	Lymphangitis and multiple abscesses in the horse, due to the presence of staphylococci	97
XVII.	External tuberculosis in the dog and cat	100
XVIII.	A case of sarcomatous disease	106

PART II.

MEDICAL PATHOLOGY AND PRACTICE.

XIX.	Acute endocarditis in the horse	116
XX.	Aortic insufficiency in the horse	125
XXI.	Mitral insufficiency in the horse	132
XXII.	Myocarditis	142
XXIII.	Ossification of the cardiac auricles	153
XXIV.	Cardiac intermittency in the horse	157
XXV.	Pericarditis in the dog	162
XXVI.	Pneumonia in the horse	170
XXVII.	Pneumonia in the horse (conclusion)	185

PAGE

XXVIII. Chronic pleurisy in the horse 202
XXIX. The abdominal form of influenza in the horse 210
XXX. A case of pharyngitis due to strangles 219
XXXI. Tuberculosis in the horse 225
XXXII. Tuberculosis in the dog 234
XXXIII. Tuberculosis in the cat 244
XXXIV. Hæmoglobinuria (azoturia) in the horse 249
XXXV. Hæmoglobinuria (azoturia) in the horse (conclusion) . . . 257
XXXVI. Diabetes mellitus in the dog 264
XXXVII. Exophthalmic goitre 272
XXXVIII. Eczema in the dog 279
XXXIX. Eczema in the dog (conclusion) 286
XL. Eczema in the horse 291

PART III.

CLINICAL CASES.

I.—Head and Spinal Cord.

A. *Cranium, brain, and spinal cord.*
Supernumerary tooth in the temporal region—operation—suppurating median otitis 298
Tumour of the right hemisphere of the brain 300
Tumour of the cerebellum 303
Tumour of the brain in the horse 304
Brain disease—tumour in neighbourhood of cerebellum and medulla . . 304
Cerebral injury and Cheyne-Stokes respiration in a horse . . . 307
Tumour of the vertebral column 308

B. *Eye and ear.*
Cancer of the lower eyelid and globe of the eye 309
Malignant carcinomatous intra-orbital growth with destruction of the eye in a cow. 310
Traumatic cataract 311
Cataract—operation 312
Symbiotic acariasis and eczema of the ear 312

C. *Nose and nasal cavities.*
Necrosis of the nasal septum 314
Necrosis of the cartilage of the left nostril 315
Sebaceous cysts in the false nostril 316
Chronic inflammation and necrosis of the posterior (maxillary) turbinated bone . 317
Tumours in the nasal cavities 319
Purulent inflammation of the sinuses; meningo-encephalitis . . . 323

D. *Lips.—Cheek.—Jaws.—Mouth.—Pharynx.*
Pseudo-cancroid of the lip 324
Papillary sarcoma of the cheek 326
Fracture of the lower jaw 326
Ostitis of the inferior maxilla—necrosis—sequestrum 327
Cancer of the inferior maxilla 328
Dental caries 330
Dental fistula 331

PAGE

Section of the tongue 333
Foreign body in the mouth 334
Chronic pharyngitis—double hyovertebrotomy 335
Cold abscess in the retro-pharyngeal glands 336

II.—Neck.

Wound of the neck 338
Poll-evil 339
Sinus of the neck 340
Moist gangrene in the neck 340
Phlebitis of the jugular vein 341
Extensive lacerated wound in neck of horse; rupture of the trachea; recovery . 344
Foreign body in the œsophagus 345
Fœtid abscess in the neck of a cat caused by a needle 347
Surgical treatment of chronic roaring 347

III.—Thorax.

Fistulous withers 354
Abscess in the left costal region—necrosis of the last rib 357
Fracture of the first rib in the horse 357
Myoma of the œsophagus 358
Chronic endocarditis 359
Myocarditis—cardiac intermittency 361
Hydatid cyst of heart 364
Intra-mural cardiac abscess in a cow 365
Foreign body in the pericardium—intra-pericardial hæmorrhage . . . 365
Rupture of the right ventricle in the horse 366
Rupture of the pulmonary artery 366

IV.—Abdomen and Tail.

Necrosis of aponeurotic tissues in the flank 368
Herniæ 369
Cancer of the stomach 374
Abscess of the liver in the horse 376
Intestinal obstruction 377
Perforation of the intestine 378
Subcapsular hæmorrhage in the liver of the horse; partial recovery; relapse and death 379
Chylous ascites in the cat; meningitis as an accompaniment . . . 380
Constipation 384
Foreign body in the rectum 385
Rupture of the posterior aorta 386
Thrombosis of the iliac arteries in the horse 387
Acute nephritis 388
Cancer of the kidney 389
Diseased prostate in the dog 391
Cryptorchid operations 397
Cryptorchidism in the cat 404

PAGE

Cancer of the scrotum 405
Cancer of the testicle—unsuccessful attempt to inoculate 405
Spermatic aneurysmal varix in the ox 408
Scirrhous cord with urethral obstruction in the horse; operation; recovery . 408
Necrosis of the penis 409
Cancer of the penis 410
Paralysis of the penis 411
Atrophy of the penis 414
Calculus in the urethra 414
Urethrotomy for removal of calculus in a horse 415
Nymphomania—ovariotomy 416
Hysteria in a mare 417
Prolapsus vaginæ in a young mare 418
Cystic degeneration of the ovary and Fallopian tube 421
Prolapse of the uterus 422
Myxoma of the uterus 423
Imperforate vagina 423
Amenorrhœa due to imperforate hymen 424
Epithelioma of the vulva 424
Rupture of the perinæum—operation 426
Cancer of the tail—generalisation after ablation 427

V.—The Limbs.

Ossifying periosteal sarcoma of the shoulder—generalisation . . . 429
Total necrosis of the scapula 430
Disease of the scapulo-humeral articulation—necrosis of the articular cartilages . 432
Injury of the flexor brachii muscle 433
Fracture of the humerus in a horse 434
Penetrating wound of the elbow 435
Foreign body in the knee 436
Suppurating synovitis of the carpal sheath 437
"Luxation" of the patella 438
Ossification of the tendon of the semi-tendinosus muscle 442
Fracture of the tibia in a horse 443
Suppurating lymphangitis—abscess formation in the popliteal lymphatic glands—treatment with hydroxyl 444
Spavin and knuckling over at the fetlock 445
Distension of tendon sheaths in front of the hock 446
Median and ulnar neurectomy—after complication 447
Quittor—partial necrosis of the anterior lateral ligament of the pedal joint . 449
Operation for picked-up nail 451
Complicated cases of corn 455
Granuloma on foot of stallion 457
Rupture of the sesamoid ligaments in both fore-limbs 461

VI.—Infectious Diseases.

Tuberculosis in the horse 463
Tuberculosis in a cow—inflammation of the omasum and ulceration of the abomasum 469

PAGE

Tuberculosis of the cerebrum 470
External lesions of tuberculosis in the dog 471
Tuberculosis in the cat 473
Transmission of pulmonary tuberculosis from man to the cat . . . 475
Transmission of tuberculosis from man to the paroquet 475
Bothryomycosis 477
Pneumonia 481
Purpura hæmorrhagica 498
Tetanus 498

VII.—Various Diseases.

Parasitic anæmia (ixodes) 504
Echinococcosis of the brain, lungs, and liver in the horse 504
Paresis of the hind limbs (chorea) 510
Rheumatism 511
Rheumatism or pachymeningitis 512
Sarcomatous disease of the lung 515
Round-celled sarcoma of the right testicle with enormous intra-abdominal tumour in the horse 516
Carcinoma of the kidney in the horse 517
Mammary adenoma in the bitch with pulmonary metastasis . . . 517
Infective granuloma in a mare 519

PART IV.

EXPERIMENTAL AND COMPARATIVE PATHOLOGY.

I. A contribution to the study of avian tuberculosis 522
II. Tuberculosis of parrots—its relation to human tuberculosis . . . 558
III. Experimental tuberculosis in the goat 575
IV. Malignant tumours in animals 579

PART V.

EXPERIMENTAL THERAPEUTICS.

I. The treatment of tuberculosis 595
II. The serum treatment of glanders 600
III. The action of vanadine 604
IV. Intra-venous injections of iodine 607

Appendix—A comparative table showing the approximate equivalent in Fahrenheit scale of a given Centigrade reading 614

Index 615

LIST OF ILLUSTRATIONS.

Fig.		Page
1.	Pre-auricular fistula due to presence of a dentigerous cyst	4
2.	Method of closing the communicating orifice between the mouth and maxillary sinus left after punching out a molar tooth	9
3.	The same as Fig. 2. Lower (palatine) surface	11
4.	Necrosis of the turbinated bones	20
5.	Pavement-celled epithelioma of the maxilla. Transverse section of the face in front of the fifth molar	27
6.	Diaphragmatic hernia	46
7.	Amputation of the penis	61
8.	Neurotomy of the anterior tibial nerve	76
9.	" " " "	76
10.	Moist gangrene of the foot after plantar neurectomy	88
11.	Neurectomy of the ulnar nerve	95
12.	" " "	95
13.	Tuberculous ulcer in the throat	101
14.	" " in the neck	101
15.	" " of the nose	104
16.	Chronic endocarditis of the aortic valves	126
17.	Chest bandage	168
18.	Tuberculosis of the liver	238
19.	" " " (atypical form)	239
20.	" " epiploon	239
21.	Tuberculous pneumonia. Section through right lung showing cavernous spaces	245
22.	Tuberculosis of the tracheo-bronchial and mediastinal glands	245
23.	Brain disease. Position at rest	305
24.	Brain seen from left side	306
25.	Vertical section through brain	307
26.	Sarcoma of the vertebral column	309
27.	Necrosis of the nasal cartilage	315
28.	Sarcoma of the nose	320
29.	Cancer of the inferior maxilla	328
30.	Internal surface of the right branch of maxilla	329
31.	Loop of thread removed from dog's tongue	334
32.	Wound of the neck	338

FIG. PAGE
33. Lacerated wound of the neck, etc. 344
34. Fistulous withers (left side) 355
35. „ „ (right side) 356
36. Fractured first rib 358
37. Chylous ascites 381
38. Chylous fluid 382
39. Microscopic appearance of fresh milk 383
40. Diseased prostate, etc., naked-eye appearance 392
41. Prostate of dog. General structure (microscopic appearance) . . . 393
42. „ „ Section of tumour 394
43. „ „ „ of calcified portion of tumour 395
44. Right kidney of dog 396
45. Epithelioma of the testicle (section) 406
46. Amputation of penis, showing stump and urethral orifice 413
47. Prolapsus vaginæ in a mare 420
48. Malignant epithelioma of anus and vulva in a cow 425
49. Suture for rupture of perinæum 426
50. Total necrosis of the scapula 431
51. Disease of the scapulo-humeral articulation 432
52. Injury of the flexor brachii muscle 434
53. Fracture of the humerus 435
54. Foreign body in the knee of a dog 437
55. Luxation of the patella (position at rest) 439
56. „ „ „ (position during movement) 441
57. Fracture of the tibia in a horse 443
58. Rupture of the flexor tendons, etc., after neurectomy 448
59. Granuloma on coronet of stallion (off-side view) 458
60. „ „ „ (near-side view) 459
61. The above case three months after operation 460
62. Paroquet with cutaneous tuberculous growths 476
63. Bothryomycotic swelling of the shoulder 477
64. Bothryomycosis of the hock 479
65. Echinococcosis. Region of insensibility 505
66. Liver with cysts 506
67. Liver, showing cysts, laid open 507
68 Right lung, showing cysts 507
69. Débris in cyst fluid 508
70. Echinococcus scolex 508
71. Brain, showing cysts 509
72. Rheumatism or pachymeningitis? attitude when quiescent . . . 513
73. „ „ attitude during an attack . . . 514
74. Malignant granuloma from stomach 519
75. „ „ from lung 520
76. Tuberculosis of the liver (fowl) 528
76A. „ „ „ 546
77. Horny growth developed on a tuberculous patch on cheek . . . 563
78. Tuberculous lesion in neighbourhood of eye 564
79. Tubercle from liver of parrot 566
80. Tuberculosis of crest (parrot) 568
81. Tuberculous vegetations on head (parrot) 569
82. „ „ „ „ 570

Fig.		Page
83.	Tuberculous growth in left ventricle of goat	577
84.	Epithelioma of the mammary gland	584
85.	,, ,, ,, ,,	584
86.	Fusiform-celled sarcoma from mammary gland	585
87.	Chondroid sarcoma of the mammary gland	586
88.	Osteoid sarcoma of the mammary gland	587
89.	Epithelioma of the testicle	587
90.	,, of the parotid	588
91.	Pavement epithelioma of stomach	588
92.	Epithelioma of the perianal gland	589
93.	Sebaceous epithelioma	589
94.	Fusiform-celled sarcoma of the vertebral column	590

TEMPERATURE CHARTS.

Charts I and II	482
,, III and IV	483
Chart V	484
,, VI	485
,, VII	486
,, VIII	491
,, IX	494

COLOURED PLATES.

	To face page
Heart of a horse dead of contagious pneumonia. Acute myocarditis	142
Tuberculous infiltration of the lung. Section of right lobe	226
Sarcomatous form of pulmonary tuberculosis. Section of left lung	228
Tuberculous endocarditis in the horse. Left ventricle	232

CLINICAL VETERINARY MEDICINE AND SURGERY.

PART I.

SURGICAL PATHOLOGY AND PRACTICE.

I.—DENTIGEROUS CYSTS IN THE TEMPORAL REGION.

A FEW days ago our advice was sought concerning a horse which showed on the temporal region, a little in front of and above the eye, a soft, fluctuating, indolent swelling, which several of you thought to be a simple cyst, and others took for a "cold abscess." The owner of the horse having been offered several contradictory opinions as to the nature of this swelling, and the proper method of treatment, had finally decided to send the animal here.

On account of the position and character of the swelling, I at once came to regard it as a dental or dentigerous cyst developed in the temporal region, an abnormality of which you will probably not see another example during the course of the present year. I was therefore anxious to utilise the chance offered of drawing your attention to this singular condition, the nature of which has long been known, but which often escapes notice, although a number of cases have been described.

Dentigerous cysts have been found in many species of animals and in various organs, particularly in the genital region, in the ovary and testicle. They are, however, specially common in the temporal region, at the base of the ear, on the forehead, and in the sinuses. These cysts have been divided into dental and radiculo-dental: in the latter, which are rare, the root of the tooth projects towards the centre of the cyst; whilst in the former, which are more frequent, the crown

occupies that position. It is of little importance whether the tooth be temporary or permanent. The mere inclusion of a tooth will not produce a dental cyst. In point of fact, one sometimes finds undeveloped teeth buried in foreign tissues, and cysts have been observed in which the included tooth does not project into the interior of the cyst at all, but is enclosed in its wall.

Various theories have been advanced to explain the pathology of these cysts. The most probable is that of Monsieur Malassez, enunciated during his study of the paradental epithelial débris. This author explains their origin by the persistence of some epithelial débris around the included tooth, and considers them due to the irritation produced during the growth of the tooth. Those containing several teeth result from the formation of a cyst at some spot where several tooth germs have been buried close together; the teeth develop and break into the cyst cavity.

I leave on one side the general history and pathology of these curious growths; I wish to speak particularly from the clinical standpoint, and to restrict myself to dentigerous cysts of the temporo-auricular region, which are by far the commonest and most interesting to the practitioner. Their degree of frequence is established by statistics long ago published by Lanzilotti and Generali. Of seventy-five cases mentioned in the veterinary journals sixty-eight were of this character.

I believe Mage-Grouillé published the first authentic case in De Fromage de Feugré's *Correspondance*. He punctured a collection of fluid developed between the left zygomatic process and ear of a three-year-old colt. At the base of the cavity he found implanted in the cranial wall a sort of "bony peg," which he removed. It was a large, irregular molar, measuring two and three eighths inches in length, and three and a half in circumference.

Under the title of 'Eburnated Degeneration of the bony part of the Temporal,' Rodet related in 1827 a second case of supernumerary teeth.

The following year Bénard recorded a third case in the *Recueil*, and corrected Rodet's diagnosis. You will find in one of Goubaux's Reports, communicated to the Central Society of Veterinary Medicine in 1853, an outline of the principal cases published at that date. Among the more recent works relative to this question I may cite an article of Macorps, inserted in the *Annals of Veterinary Medicine* of 1860, and the memoir of Lanzilotti and Generali, published in 1873 in the *Gazzetta Veterinaria*.

Our last case may be described in a few words. The animal is a four-year-old horse, bought at Beauce a fortnight ago by a dealer, who

did not notice the existence of the swelling. One morning, however, he remarked on the left side of the animal's head a swelling the size of a small egg. Being unable to obtain any exact information as to its nature and gravity he sent the horse here. At the first examination it was easy to see that we had not to deal with an abscess. The swelling was uniformly soft, fluctuating, cold, and painless. Its position in front of the ear and above the zygomatic process, its sharp delimitation, the absence of inflammatory symptoms, and the discovery of a prominence of bony consistence in the depths, sufficiently suggested its nature. It was, in fact, a dentigerous cyst. The owner did not wish to run the risks of treatment, and removed the horse.

In October last I operated on a two-year-old colt, which showed an open sinus about three eighths of an inch in front of the base of the ear. This sinus, which ran obliquely forwards and was about four inches long, ended over a kind of rough bony swelling, which was regarded by some of you as an exostosis, by others as a necrotic patch of bone. The animal having been cast, and the front of the fistula laid open, we discovered a rounded prominence of bony consistence, with an irregular summit and smooth sides. It was, in fact, a supernumerary tooth. I seized it with dental forceps and attempted to loosen it. It readily became detached, and when extracted had the appearance of a small molar. A little behind was another, which I removed without much difficulty. The cavities left by these teeth were rounded, regular, and partly lined with fibrous membrane. Hæmorrhage was trifling. The cavities were curetted and plugged with gauze. The dressing was renewed in forty-eight hours and several times later. In a month the wound had healed.

In 1888 I saw another case of this kind, in which intervention was equally simple and cure rapid. Towards the middle of September a six-year-old horse was sent to the external Clinique, with an old sinus in front of the ear. The margins were denuded of hair, hardened, and from them escaped a little greyish, laudable pus, without offensive odour. A probe introduced into this sinus was finally stopped by a raw, bony surface, and by manipulating it a little I was able to satisfy myself of the presence of some hard moveable body, like a sequestrum. Having opened up the fistula, I removed this body with a pair of bent-necked forceps. It proved to be a small molar, completely detached, and held in its alveolus by a root little larger than the crown. The walls of the cavity were scraped, and the parts washed out with strong carbolic solution. Suppuration proceeded for several weeks, doubtless because of some change in the bone, but the wound eventually healed.

Dentigerous cysts in the temporal region usually appear during the first few years of life—in fact, during the period of dentition. At first the dentigerous cyst consists of a soft swelling, flattened or hemispherical, painless, or slightly sensitive, varying in size between that of a nut and an egg. Sometimes it persists for long in this condition; in other cases—and this is the more common—the skin ulcerates towards the centre, or at some point of its surface, the contents of the cyst escape, and a sinus forms.

As a rule, the opening of the sinus is at the side of the cranium, a little in front of and an inch or so from the base of the ear,—occasionally, however, on a level with the scutiform cartilage; sometimes it is a

Fig. 1.—Pre-auricular fistula due to presence of a dentigerous cyst.

little further forward, sometimes nearer the middle line or the zygomatic process; occasionally it is situated at the base of, or more or less high upon, the free portion of the ear. In Rodet's and several other cases the sinus, though opening some distance up on the conchal cartilage, had originated from near the zygomatic process. The wound is sometimes encircled with a ring of granulation, sometimes appears as a simple aperture in the skin, but more frequently is situated at the base of a narrow infundibulum, produced by the retraction of the walls of the fistula. In most cases the parts are swollen, or indurated to a greater or less extent, but when the condition is old-standing, the swelling or induration which at first existed may almost have disappeared.

The sinuses vary in extent, some being only three quarters to an inch and a half, others three or four inches deep. A probe, when introduced, comes in contact with a rough, irregular, bony surface, which gives a sensation similar to that produced by a fragment of necrosed bone still adherent to the surrounding parts. Sometimes one can distinguish an irregular protuberance, surrounded by a trifling circular depression. In other cases, like that to which I have just drawn your attention, the body encountered is moveable. Whatever its position and characters, the sinus always discharges a thin greyish pus, more or less abundant, inodorous or fœtid, which glues together the neighbouring hair, and sometimes forms on the cheek or parotid region a long streak, in which greyish particles may be detected.

A sinus of this nature being formed, the condition may persist for years without much change; the amount of suppuration varying from time to time. In some animals the discharge almost ceases at certain periods, and the sinus, becoming reduced to very trifling dimensions, seems to heal. Later the parts become inflamed, suppuration increases, and the fistula reopens, or another appears in the neighbourhood. In old-standing cases several cicatrices, due to closed sinuses, may often be detected around the wound.

Besides the recorded cases of multiple supernumerary teeth, others exist where several dental cysts have developed in succession, each giving rise to a fistula.

In Rodet's case, after the extraction of the first tooth a second cyst appeared. The fourteenth case treated by Macorps was operated on twice at an interval of three months. Each time a tooth was removed. A little later a new fluctuating swelling appeared, due to the eruption of a third tooth. Such relapses, however, have only been recorded in a few instances.

As a rule these cysts neither produce functional disturbance nor general symptoms, though exceptions to this rule exist. Two patients treated by Macorps and Gamgee showed difficulty in mastication and general wasting, troubles which only disappeared after removal of the tooth. Much graver complications may occur when the tooth develops within the cranial cavity, thrusts back the dura mater, and compresses the brain. Bay has related an interesting case of this character. A horse which had long suffered from a non-fistulous swelling of the temporal region, but without accompanying disturbance, died in twenty-four hours with symptoms of meningitis and encephalitis. Autopsy revealed the presence within the cranium of a new growth of apparently osseous nature, which, on more careful

examination, was found to consist of four molar teeth; the two lower had developed from the region of the sella turcica, and compressed portions of the brain, which in this situation, as is known, is very intolerant of injury. Monsieur Barreau published the history of a horse which, after long suffering from a temporal sinus, showed difficulty in mastication, general wasting, and unmistakable signs of some brain lesion. It was slaughtered. In the cranium was found a kind of bony new formation, hemispherical in shape, developed from the squamous temporal bone and the corresponding wing of the sphenoid.

The anatomico-pathological characters presented by even the more benign of these lesions vary greatly. They may resemble dermoid cysts, abscesses, or recent or old-standing fistulæ. The cyst generally contains only one tooth. Sometimes, however, there may be two, three, or more, either distinct or fused together. They usually present the appearance and characters of molars; in other cases they more closely resemble incisors. Their shape is either prismatic, pyramidal, or rounded; the majority, however, are very irregular. In composition they do not essentially differ from normal teeth, dentine, enamel, and cement being associated in varying proportions, the dentine usually predominating.

The firmness with which these teeth are fixed in position varies greatly. In certain cases, as in that seen by you, extraction is easy. In others it is difficult, and not without danger. In a two-year colt Degive, after removing one tooth, discovered a more deeply placed eburnated swelling, formed by several teeth incompletely fused together. The removal of this growth opened the cranial cavity, its lower portion being in direct contact with the dura mater.

Provided the nature of these cysts and sinuses in the temporo-auricular region is recognised, the operator is less likely to commit indiscretions. Without doubt, in this as in other regions, ordinary cystic swellings develop sinuses, and are kept discharging by the presence of bony or cartilaginous necrosis; but such accidents are infinitely rarer than those consequent on dental irregularities.

Several cases described as necrosis of the scutiform cartilage—Martin's among others—and some referred by the writers to inflammatory changes of the temporal bone, can now safely be assigned to the presence of supernumerary teeth. If, before intervention, one hesitates between diagnosing a dental cyst or necrosis of bone, it should be borne in mind that the former hypothesis is by far the more probable. When the swelling embraces the base, and extends more

or less high on the free portion of the ear, it awakens suspicion of necrosis of the conchal cartilage, and may be mistaken for that at the first glance, but palpation of the parts and exploration of the sinus generally settle the question.

What is the prognosis in these lesions? I have already said they persist for long periods, even for years. I will add that they are very rebellious to ordinary treatment. The lesion, whether only a swelling or a sinus, depreciates the value of the animal. When there is discharge of pus this fouls the region of the wound, and the parts often emit a fœtid odour, noticeable on first entering the stable. You have seen that complications sometimes result. Finally, if intervention is usually followed by success, it may also involve accidents of the most serious character.

The treatment formerly recommended included puncture of the cyst or slitting up the fistula, and caustic injections or cauterisation of the walls of the cyst. These methods are insufficient. Cure can only be effected by removing the tooth and destroying the wall of the cyst.

As a rule the operation is simple and without danger. The horse being cast, the bridle is removed and the head extended. The parts having been prepared, the fistula is laid open or the swelling incised in the form of a cross, and the tooth exposed by reflecting the flaps. The attachment is often slight, or the tooth may be loose. It is easily removed with strong forceps or with special tooth forceps, the cyst being afterwards curetted. When it is deeply seated, and the operator is unable to grasp the crown, it may be loosened by means of a chisel and mallet, but cases occur where, in order to free it, a groove must be formed around the tooth by means of a narrow-bladed gouge. It is always necessary to proceed cautiously, avoiding violence, on account of the risk of fracturing the skull and injuring the meninges and brain. All possible antiseptic precautions should be observed. Even when properly carried out the operation may be followed by various complications, by necrosis of a portion of the alveolar wall, bruised during extraction, by fracture of the tympanum (if the tooth abuts on the middle ear), or, if the deep portion is in contact with the dura mater, by meningo-encephalitis.

When intervention is considered dangerous, it is better to refrain altogether from interfering with the tooth, rather than risk a fatal accident. The only case in which a cranial tooth should be touched is when it produces grave symptoms in consequence of its pressing on the brain.

II.—PURULENT COLLECTIONS IN THE FACIAL SINUSES AND DENTAL CARIES.

During the years 1896 and 1897 eighteen horses affected with collections of pus in the sinuses were trephined in the hospital. According to the nature or cause of the disease, these eighteen cases may be divided as follows:—Simple inflammation of the sinuses, four; inflammation of the sinuses produced by tumours, five; inflammation of the sinuses of dental origin, nine.

The small number of cases of simple inflammation is truly striking. This may possibly be due in part to the fact that the animals sent to us are those regarded by ordinary practitioners as unpromising, but I believe the number of cases of secondary inflammation of the sinuses is in reality greater than is generally supposed. In addition to dental caries and to true tumours one sees diffuse myxomatous degeneration of the mucous membrane of the sinuses.

In all the cases of inflammation of the sinuses due to new growths the tumours were malignant or beyond operation. I therefore confined myself to trephining and verifying diagnosis.

In the cases of dental origin, treatment consisted in trephining the maxillary and frontal sinuses, afterwards enlarging the lower orifice and removing the diseased molars by punching. After cleansing the parts I plugged the alveolar cavity with gauze and cotton wool; this dressing was renewed every twenty-four or forty-eight hours; the sinuses were cleansed and irrigated as in cases of simple collections of pus. The results have been good. Of nine horses thus treated six were cured in a month to six weeks.

The alveolar cavity does not heal with equal readiness in all cases. In some it fills up slowly, in others with fair rapidity, and these differences are seen in animals of the same age or thereabouts. In the following case closure of the cavity was particularly rapid.

In November, 1896, I had to punch out the third and fourth upper molars of a seven-year-old mare. The large communicating space between the mouth and sinus was plugged with gauze and wadding,

the dressing being renewed daily for the first week, and every second day for the next three weeks. At the end of this time the alveolar cavity of the third molar was almost filled up. That of the fourth still admitted a man's little finger. Ten days later only a narrow canal

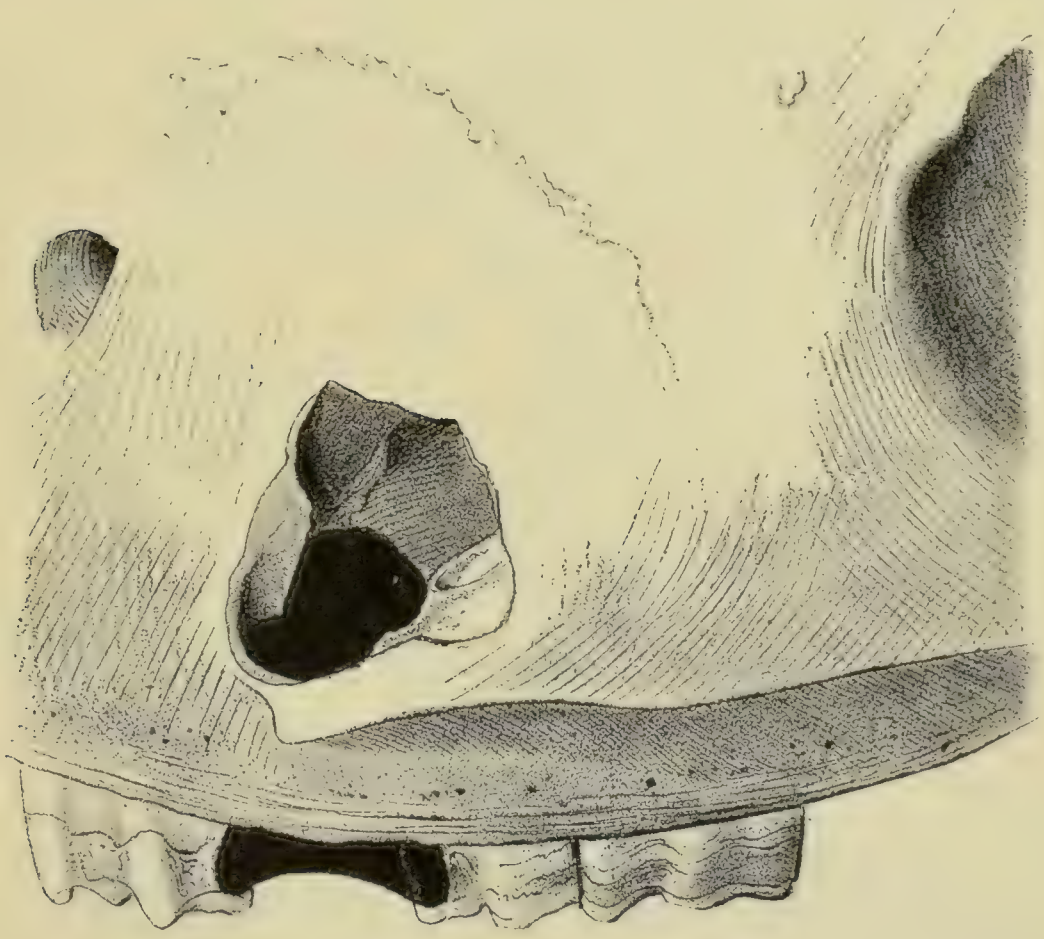

FIG. 2.—Shows the method of closing the communicating orifice between the mouth and maxillary sinus left after punching out a molar tooth.

existed, food no longer passed into the sinus, and the mare was able to leave the hospital. Towards the end of January we were informed that cure was perfect.

At the commencement of June of the same year, one of my colleagues in the Seine and Marne district sent me a horse affected with double-sided collections of pus of dental origin. On the right side the condition was due to caries of the third molar, and on the left to caries of the fourth. We first trephined the right side and punched out the diseased molar. In five weeks, with the precautions just mentioned, the alveolar cavity had filled up. We then performed the same operation on the left side. The parts healed as steadily as before, although the alveolus closed rather more slowly, and healing

was not complete until the eighth week. The pain and disturbance of mastication caused by the caries and by the two operations had produced very marked bodily wasting, but the diseased animal gradually improved. A fortnight later, after the second operation, its weight was 642 kilogrammes, a fortnight later it weighed 649 kilos., and in a month 660 kilos.*

Another horse, in which I punched out the fourth left molar, quitted the infirmary when the opening between the mouth and sinus was still of considerable size. It was neglected, food accumulated in the sinus, and the discharge again became abundant and horribly fœtid. At the end of two months it was returned here in an extremely thin condition. The sinuses were full of stinking food material and pus. The walls of the alveolar cavity were lined with a whitish, fibrous, pseudo-mucous membrane, which gave no hope of satisfactory granulation. I decided to fill the parts with gutta percha. The animal was cast on Daviau's table, the mouth kept open with a gag, and the tongue moderately drawn to the right side, so as to freely expose the left molars. The sinus and alveolar cavity were carefully cleansed and dried with tampons of cotton wool. Two pieces of gutta percha, softened in water at about 112° F., were pushed from the sinus into the alveolus, and fixed with the aid of the left index finger introduced into the sinus, the right being introduced by the mouth between the third and fifth molars. I was careful to slightly flatten out the upper part of the inserted piece on the wall of the sinus around the alveolar orifice, and the lower part around the two neighbouring molars. In order to more rapidly harden the gutta percha it was irrigated for some minutes with cold water both by the mouth and by the sinus. The latter was afterwards plugged with gauze. The dressing was renewed each following day. A discharge occurred around the upper part of the mass of gutta percha, but was trifling in quantity and no longer fœtid. The trephined orifice was left open and contracted little by little. The animal's condition gradually improved. When it left the school a week later it only showed a trifling discharge, and the trephine wound scarcely suppurated.

This animal was brought back again in six months. It fed well, and its condition had become excellent. A trifling quantity of muco-purulent discharge escaped from the left nostril, but there was no offensive odour. The trephine wound had become replaced by a narrow fistula, which discharged a little whitish pus without odour. Examined through the mouth, the piece of gutta percha was not in any way displaced, and continued to perform its function perfectly.

* A kilogramme = 2·2 lbs. English.

Altogether the operation has given very good results, for before the alveolus was closed the sinus was continually full of decomposing food material, etc., and the smell was repulsive.

In the three cases of simple inflammation of the sinus cure was readily effected; in two in less than a month, in the other during the fifth week.

In one of these cases pus had existed in the sinus for four months. The animal, an eight-year-old entire horse, had a running from the left nostril. The discharge was little when at rest, but became abundant during exercise, was whitish, grumous, and offensive. There was no trace of any mechanical injury, and no deformity or tenderness about

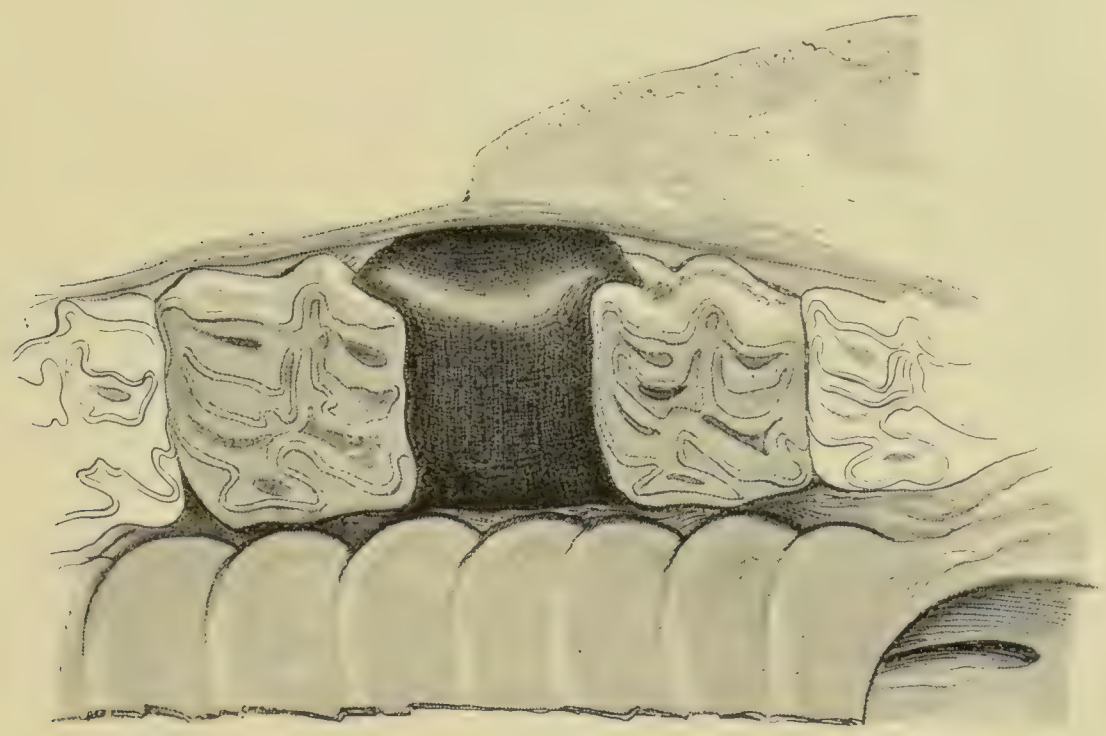

Fig. 3.—The same case as Fig. 2. Lower (palatine) surface.

the region of the sinus. The contents of the mouth had no unpleasant odour, and there was no dental disease. The submaxillary gland was as large as a nut, superficial, soft, moveable, and indolent.

The horse being cast, I trephined the left inferior maxillary sinus, giving exit to a large quantity of yellowish-white, very fœtid pus. The cavity having been cleansed, I freely broke down the septum between the two maxillary sinuses, and then, by means of a centre-bit, formed a counter-opening into the nostril from the lowest point in the inferior maxillary sinus. Night and morning the patient was dressed according to our usual method, by washing out the sinuses with a warm

antiseptic solution and plugging the trephine opening. At the end of a week the discharge by the trephine wound and left nostril had already diminished, and afterwards continued gradually to lessen. During the fourth week we ceased plugging the wound. Some days later the animal returned home.

As a rule, the troublesome cases are those where the mucous membrane is thickened, shows exuberant granulations, or is affected with polypoid degeneration. Sometimes persistence of the discharge is due to the anatomical formation of the inferior maxillary sinus, to the fact of its being prolonged an inch or so below the extremity of the zygomatic ridge,—that is, beyond the point where this sinus is usually trephined; a quantity of pus remains in the lower part of the cavity, and keeps up inflammation of the mucous membrane. It also happens at times that this sinus is very large and deep, allowing the purulent fluid to accumulate and keep up exudation from the mucous membrane. In cases of this nature it is advantageous to make an opening through the internal wall of the sinus, level with the inferior meatus of the nasal cavity as above indicated. With a small surgical stock and bit the operation is easy. Care is required, however, to make the opening level with the meatus, and not with the internal portion of the large submaxillary sinus; if placed too low the instrument penetrates into the palatine plate of the superior maxilla.

The need for plugging the trephine openings, to prevent their closing up before suppuration ceases, is unfavourable to cure, because during the interval between the times of changing the dressing pus is retained in the sinus. This may be prevented by fixing in the openings closely fitting tubes of wood, provided with a little handle on the external surface. With the same object, metal or gutta-percha cannulæ may be employed.

Before concluding, I must refer to one of our patients which died. An entire cart-horse, twelve years old, was brought here towards the middle of March, 1896. He had long had a discharge from the right nostril, which finally became so offensive that the driver refused to take him out. The animal was in a bad state, thin and exhausted; he lay down as soon as he entered his box. A purulent offensive discharge escaped from the right nostril. There was no deformity of the sinus, and the submaxillary glands were little enlarged. On examining the mouth it was seen that the horse "pouched" his food on both sides, especially on the right. The fourth right lower molar projected beyond the others nearly half an inch. Having inserted a gag, we discovered that the corresponding

upper molar was carious. The purulent inflammation of the sinus was, therefore, of dental origin.

Treatment was as follows:—The animal having been suitably secured, I first cut away the portion of the fourth lower molar which projected above the others. I then made three closely placed trephine openings in the inferior maxillary sinus, and removed the intervening portions of bony tissue. On introducing the finger into the sinus after free irrigation the root of the carious tooth was discovered. This was punched out. The crown was almost entirely destroyed, but the root was little damaged. The sinus and alveolar wound were then washed out with warm creolin solution and plugged with gauze.

Next day and the following days the dressing was renewed. The horse only ate a part of his food, but as the temperature did not rise more than a few tenths of a degree, I was not alarmed. As, however, the fæces were scanty and coated, I prescribed daily about four ounces of sulphate of soda. On the third day the bowels became relaxed, but the appetite always remained poor. The day after, the condition was greatly aggravated. The animal was exceedingly depressed and did not touch its food; there was twitching about the stifle and elbow; the respiration was accelerated, the pulse frequent, small and hardly perceptible; the conjunctiva was slightly injected; percussion and auscultation of the chest revealed nothing abnormal; there was fever to the extent of about $2\frac{1}{2}^{\circ}$ F. On rectal exploration the bladder was found empty. In the depths of the abdomen towards the right side could be felt a large, hard, slightly doughy mass, which yielded under pressure of the fingers. Palpation of the right flank appeared to indicate that this hard mass was formed by the cæcum crammed with food. We attempted to overcome the obstruction by repeated enemas, and by subcutaneous injection of a mixture of pilocarpin and eserin. A little dung was passed. During the day the animal took a small quantity of milk, but steadily became worse, and death occurred on the following day, preceded by symptoms of acute abdominal pain. At the *post-mortem* examination food material was found distributed in the peritoneal cavity, and the posterior part of the base of the cæcum was seen to be ruptured. The viscus itself was distended by an enormous mass of hard material. The tear was surrounded by a large hyperæmic zone, and the ecchymosis present clearly showed that the lesion was *ante-mortem*.

This animal had long suffered from dental caries and difficulty in mastication. The food material had ended by becoming impacted within the cæcum.

I have recalled the history of this horse because it points a moral.

When during the treatment of inflammation of the sinuses, consequent on dental mischief, the appetite falls off, and grave general disturbance occurs, one should beware of referring all this to the operative wound, and remember that dental affections in the horse and all large animals, especially when prolonged, favour obstruction of the large intestine, and may bring about impaction of the cæcum.

III.—AFFECTIONS OF THE TURBINATED BONES IN THE HORSE.

A FEW days ago, in making an examination of a horse which had died in hospital, we discovered it had suffered from necrosis of the turbinated bones. In drawing your attention to this condition I am completing what I have already referred to during my surgical pathological lectures on diseases of the nasal cavities.

In the horse the turbinated bones are subject to various diseased conditions, primary or secondary in character, of which, up to the present time, only incomplete and confused descriptions have been given.

The few clinical observations published concerning these conditions refer (1) to hypertrophy and eburnation of the turbinated bones; (2) to tumour formation within them; (3) to mucous degeneration; and (4) to empyema of their cavities and to necrosis.

In certain horses chronic nasal catarrh is followed by considerable thickening of the pituitary membrane, and hypertrophy of both turbinated bones, or only of the anterior. This hypertrophy is sometimes general, but more frequently partial. The mucous membrane becomes hyperplastic, irritated, fibrillated, is usually pale and firm, but sometimes reddish and less consistent. The anterior turbinated bone, hypertrophied and firm, forms a conical or cylindrical polypous mass, which compresses neighbouring parts, causes atrophy of the posterior turbinated bone, and more or less completely fills the nasal cavity on the affected side. Sometimes, as in the case mentioned by Stockfleth, it becomes as hard as bone or ivory. It may attain such dimensions as inwardly to displace the nasal septum, above the nasal bone, and externally the wall of the sinuses, into which it penetrates. There is always more or less abundant, sometimes fœtid, muco-purulent discharge. The diminution in size of the nasal cavity impedes respiration, and gives rise to an abnormal whistling or roaring sound. Later the upper portion of the face becomes deformed, the diseased side projecting, in consequence of the upper wall of the nasal cavity and of the sinuses being pushed up from below.

Only in exceptional cases does the turbinated bone become hypertrophied in its anterior part, so as to become visible on opening the wings of the nostril, but the swelling can often be felt with the finger; when, however, it is limited to the upper part of the turbinated bone it can be detected only by a catheter, or by examination with the rhino-laryngoscope, and in order to determine the character of the new growth a portion of morbid tissue must be examined microscopically.

Although most cases of hypertrophy of the turbinated bones result from chronic inflammation of the nasal mucous membrane, the only surgical treatment which can be recommended and which proves successful consists in ablation of the diseased bone.

The operation may be performed in two ways. In the first, the bone is removed through the nose with long powerful forceps or a pointed hook. Höyer, who used a hook, was obliged to make several attempts in order to remove all the diseased bone. Bleeding was trifling, and the animal recovered.

The other operative method, recommended by Jessen, consists in freely trephining the roof of the nasal cavity, making a large opening through which the turbinated bone is removed. Ablation can then be performed more methodically and completely, while if bleeding is abundant it is more easily checked by cauterisation and plugging. Jessen cured four animals by this method, which has succeeded equally well in the hands of other practitioners.

Whatever the technique employed, removal of the hypertrophied bone does not always cure. In some cases, especially when of old standing, fungous growths develop at the seat of operation, and in a short time again obstruct the nasal cavity.

New growths of varying character may develop on the turbinated bones. In the horse the commonest are mucous or fibrous polypi, myxomata, or fibromata, the evolution of which is usually slow. At first the symptoms are those of chronic catarrh, with unilateral mucopurulent discharge, sometimes streaked with blood. Later, respiration is impeded (as in the preceding condition), inspiration especially being more or less noisy. The animal frequently snorts, and as the tumour increases the symptoms become more marked. One meets with polypi originating from the base of one of the turbinated bones, or from the ethmoid bone extending into the nasal cavity, generally along the floor, or along the middle meatus, and pushing back the turbinated bones, finally reaching almost to the nostrils. In other cases they extend towards the pharynx and interfere with deglutition; others,

again, resemble the naso-pharyngeal polypi of man, and extend in all directions, invading the bone, and filling up the sinuses. This last variety, common in the dog, is exceptional in the horse; but a benign polypus, when of large volume, may push aside the nasal septum and the turbinals and raise the nasal bone, completely blocking the nasal cavity and deforming the face. Sarcomata, which are much rarer than polypi, extend to the bones forming the nose, and usually acquire large dimensions in a very short time. Epitheliomata (pavement, or cylindric celled) are equally rare. They rapidly seize on the lymphatics, and produce metastatic inflammation of the submaxillary gland.

Treatment is limited to benign tumours, *i.e.* to polypi. Several cases of spontaneous cure have been related. The tumour has finally been expelled during snorting or coughing. Such a termination, however, is rare, and must not often be looked for. Ablation should be performed by the method I shall describe in speaking of disease of the upper turbinated bone.

Under the name of mucous degeneration of the turbinated bones, Sand has described in the colt an affection of these parts, and of the bones of the nose and face, the symptoms of which recall those of inflammatory hypertrophy of the turbinated bones, and of tumours in the nasal cavities.

It is marked by unilateral muco-purulent discharge, by diffuse swelling about the nose and sinuses on one side of the face, and by abnormal breathing sounds, due to partial obstruction of the nasal cavity. The swollen parts of the facial bones are thinned, parchment-like, or softened, and appear to fluctuate. As a general rule these symptoms are first noted in the region of the maxillary sinuses, then in that of the frontal sinus. If a puncture be made over the centre of the swelling, and a probe introduced into the sinus, the instrument passes in all directions through a non-resisting tissue.

When the condition is bilateral, respiratory disturbance may be so severe as to threaten suffocation and necessitate tracheotomy.

Sand lays stress on the special anatomical changes in this affection, which he states are different from those of inflammatory hypertrophy of the turbinated bones and empyema of the sinuses. The most striking points are the dilatation of the sinuses, and of those portions of the turbinated bones contributing to their formation; the destruction of the bony walls of the sinuses and of the parchment-like leaf of the turbinated bones, or, more frequently, the replacement of a bony by a mucous tissue engorged with liquid; finally, the

accumulation of a serous exudate in the sinuses, whose orifice of communication with the nasal cavity has disappeared.

The cause of the disease is obscure. It seems always to appear in young animals. In some cases it makes rapid progress; in others, on the contrary, it is chronic, develops very slowly, and only produces functional disturbance after the lapse of years.

Treatment is similar to that of catarrhal inflammation of the mucous membrane of the sinuses: trephining, drainage, and antiseptic injections. Sand states that these methods usually suffice to arrest or cure recent cases.

Collections of pus in, and necrosis of the turbinated bones, have sometimes been regarded as due to glanders. A certain number of cases, most of them recent, have shown that such complications may, however, be purely local in character, sometimes consequent on acute inflammation of the pituitary membrane, caries of the last molars, indirect injury of the turbinated bones through the bones of the face, or direct injury through the nostrils.

On *post-mortem* examination I have never found necrosis of the turbinated bones as a primary affection, and had often debated with myself whether published cases were not complications of hypertrophic rhinitis, or of Sand's disease, until last week I saw the case to which I referred at the commencement of this lecture. The facts are as follows:

On the afternoon of the 4th May one of my colleagues * sent me a twelve-year-old mare, which had been ill for a fortnight. The condition was indicated by discharge from the nostrils, and had at first been regarded as due to a trifling sore throat. The discharge from the right nostril, however, persisted, and later increased and grew fœtid.

On the 3rd May the animal's condition suddenly became aggravated. The patient was greatly depressed, had difficulty in standing, and refused food. It was sent to the College. On arrival it could only be kept on its legs for a short time by partially lifting it with wooden bars, and soon had to be let down on the straw. Its comatose condition, the paralytic symptoms, diminution of general sensibility, and contraction of the pupil, indicated some affection of the meninges and brain. On the other hand, the fœtid discharge running from the right nostril, and trifling swelling of the submaxillary glands,

* An outside practitioner. It is usual in France for a professor thus to refer to a practitioner, or for one practitioner to refer to another. Unfortunately we do not use the term quite in this sense, and I cannot translate it more exactly.—Jno. A. W. D.

aroused suspicion of pus formation in the sinuses, or turbinated bones. The temperature was 101·1° F., the pulse 60, and the respirations 36 per minute. I first explored the naso-pharyngeal cavity with a catheter, and afterwards trephined the nasal bone. The right nasal cavity was clear, not diminished in size, and the sinuses of that side contained no pus. I considered it probable that the ethmoid cells were necrotic, a condition complicated by meningo-encephalitis. I prescribed warm boric irrigations of the nasal cavity, and put off until next day examination with the rhino-laryngoscope, by which I hoped to confirm the diagnosis.

During the night the temperature fell 1·8° F., the mucous membranes became reddish-violet, and the coma was interrupted by an attack of convulsions with spasmodic contraction of the limbs. The patient died next morning.

At the *post-mortem* examination we found secondary lesions of purulent inflammation, marked especially by the presence of large numbers of metastatic pulmonary abscesses. The primary changes were very extensive, affecting the turbinated bones, ethmoid, and the antero-inferior parts of the cranium. In the posterior portion of the right nasal cavity the pituitary membrane was extremely hyperæmic and infiltrated. Near its base the maxillary turbinated bone was destroyed over an oval space, about an inch to an inch and a quarter in its longer diameter, which corresponded with the long axis of the nose. Around this point the mucous membrane was thickened and blackish, except towards the back, where it was covered with necrotic suppurating points. In front, the turbinated bone was full of caseous putrid pus. Opposite the lesion of the maxillary turbinated bone, the ethmoidal turbinated bone showed a necrotic area where the mucous membrane was thinned, greyish-yellow, and covered with blood-stained pus. The ethmoid cells of the right side were deep red in colour, and in places ecchymosed; towards their base, the mucous membrane appeared partially necrotic. The ethmoid cells and sphenoidal sinus contained fœtid pus. In the region between the posterior border of the sphenoid, and the superior border of the cribriform plate of the ethmoid, the dura mater was thickened, yellowish or greenish-grey, and everywhere soaked in pus; the arachnoid cavity contained a fibrinous exudate, especially thick near the sella turcica. Immersed in pus, the pituitary gland had become softened and partly destroyed.

Bacteriologically examined, pus collected from the necrotic portions of the turbinated bones was found to contain various micro-organisms, but especially streptococci, in longer or shorter chains—the greater number in short chains—staphylococci, and a small bacillus strongly

resembling the bacillus of necrosis mentioned by Bang. Pus from the pulmonary abscesses also contained several varieties of organisms, streptococci predominating. In the intra-cranial exudate I only found streptococci in short chains, usually of three to six.

In this patient the phases of the process were probably as follows: At first, acute inflammation of the mucous membrane of the turbinated bones, and ethmoid cells; afterwards, partial necrosis of these organs, and suppurative inflammation of the ethmoidal and sphenoidal sinuses. From the ethmoid cells, suppuration extended through the holes in the cribriform plate of the ethmoid to the meninges of the brain. While these processes were gradually developing in the direction of the meninges, pyogenic organisms must have entered the venous circulation, and brought about purulent infection.

In volume ix of the *Journal of Military Veterinary Medicine*, Delamotte recorded a case which in regard to the nature of its

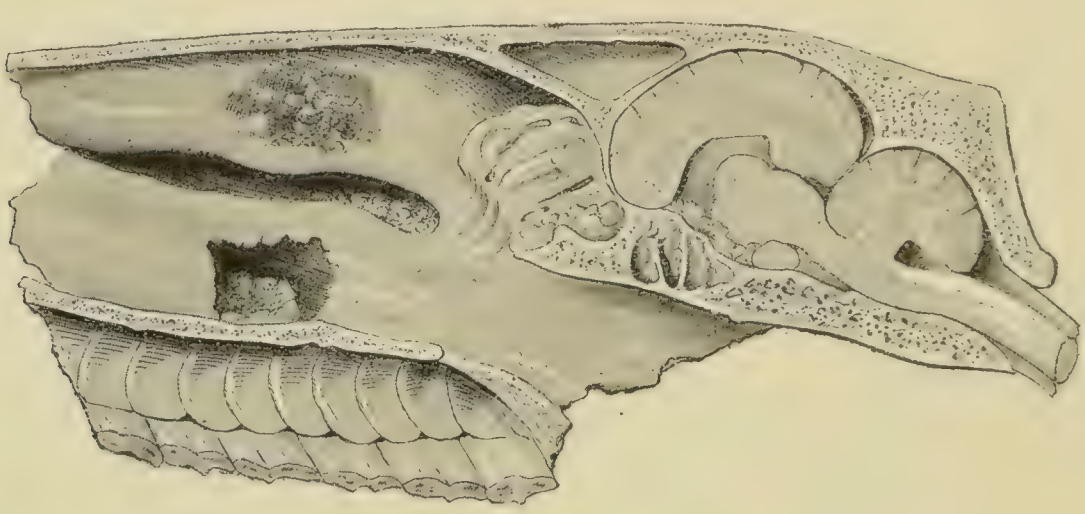

Fig. 4.—Necrosis of the turbinated bones.

lesions shows certain analogies to the preceding. It refers to a mule, which one morning, without any preliminary symptoms, was suddenly attacked with abundant epistaxis, and discharged from the mouth torrents of black, thick blood, of repulsive odour. An hour and a half after the onset of bleeding the animal died from loss of blood and asphyxia. At the *post-mortem* examination, in addition to obstruction of the bronchi by blood and lesions of asphyxia, the examiner found the mucous membrane of the ethmoid cells gangrenous, greenish-yellow, softened, and of offensive odour.

Necrosis of the turbinated bones usually long remains localised, and reveals itself by an offensive, one-sided discharge, interference with respiration due to diminution in the nasal cavity, trifling en-

largement of the submaxillary glands, and swelling at the base of the forehead. The cases reported by Sand, Möller, and Fröhner, all agree in this respect. The three cases referred to by the latter are interesting from a therapeutic stand-point. The essential facts are as follows: the first case was that of a six-year-old mare, which showed abundant, yellowish, offensive discharge from the right nostril, swelling of the submaxillary gland, to which the skin was adherent, injection of the pituitary membrane, and, towards the base of the nasal bone, a painful circumscribed swelling, over which percussion gave a dull sound. The changes affected the deep part of the nasal cavity. Examination by means of the nasal mirror failed to explain the nature of the condition. On trephining the nasal bone, the anterior turbinated bone was seen to be partially necrotic. The dead part having been removed, the cavity was washed out with creolin solution and plugged with iodoform gauze. Recovery occurred in three weeks.

The second case was that of a twelve-year-old mare, showing practically the same symptoms as the former. Discharge, however, was bilateral, and the swelling at the base of the forehead was on the left side near the wider portion of the nasal bone. This bone was trephined, the diseased portion of the upper turbinated bone removed, and the parts dressed as in the preceding case. Cure followed in a fortnight.

The third animal was a nine-year-old horse, with necrosis of the left upper turbinated bone. The same operation was performed as in the two previous cases. In six weeks the animal was returned home. Three weeks later it had completely recovered.

I ought to add that in other cases the result has not been so happy. Sometimes the discharge has persisted much longer. In one of Möller's cases necrosis recurred, and recovery appeared hopeless. You yourselves have seen that rapidly fatal complications may occur.

The facts just given and the case I have published sufficiently demonstrate the occurrence in the horse of a special disease, consisting in partial necrosis of one or both turbinated bones; a disease producing clinical signs permitting of diagnosis, which sometimes remains localised for a long period, sometimes is rapidly followed by complications, and which is best treated by trephining the nasal cavity, removing necrotic portions of the turbinated bone, and applying antiseptic dressings.

IV.—TUMOURS IN THE FACIAL SINUSES AND CANCER OF THE SUPERIOR MAXILLA.

You recently saw in the external clinique a patient with a tumour of the sinuses and of the bones of the face, on which I refused to operate. I wish to explain to you this morning the reasons for my abstention, and for that purpose shall take as my subject "New Growths in the Sinuses."

Although much less frequent than catarrhal inflammations of the mucous membrane, or simple inflammation of the sinuses, new growths in the sinus are, nevertheless, not very rare. I have collected a fair number of cases, differing considerably from one another in regard to the nature of the lesions and to their gravity.

In the sinuses of the horse one meets with cysts, myxomata, fibromata, sarcomata, and epitheliomata.

I will shortly relate some clinical cases, which will give you an idea of the symptoms, course, and prognosis of these various tumours, and will show you within what limits intervention is permissible.

Let us first of all consider the cysts.

In 1893 a Percheron horse, seven years old, was sent to the clinique on account of a discharge from the left nostril of two months' standing. The discharge was thick, grumous, and offensive. On the left side the submaxillary gland was slightly enlarged, and felt like a little bunch of grapes, the constituent portions, however, being moveable one over the other. The external wall of the sinuses was slightly raised, and sensitive on percussion; the sound given was distinctly dull. I concluded that suppuration was occurring in the sinuses. An exploratory puncture confirmed the diagnosis, and the patient was left in hospital for treatment.

Having trephined the parts, we found in the inferior maxillary sinus, along with a considerable quantity of pus, several small, soft tumours developed from the mucous membrane. In the frontal and superior maxillary sinuses the mucous membrane was simply thickened by inflammation. The teeth were normal, the maxilla was not

invaded, and the septum dividing the two maxillary sinuses was not destroyed. I incised one of these tumours with the point of a bistoury, and a little viscous fluid escaped. The case was clearly one of cyst formation in the mucous membrane, without doubt at the expense of the small glands therein contained. I sufficiently enlarged the opening in the inferior maxillary sinus, and scraped the mucous membrane. The head of a thermo-cautery was passed over the membrane, after which the animal was treated like a patient suffering from ordinary inflammation of the sinuses, drainage being provided for, and the parts washed out twice daily with a slightly antiseptic solution, followed by astringent injections. At the end of a month the drainage-tube was removed. The lower wound having been plugged to prevent it closing too rapidly, allowed of our continuing the injections some time longer. The animal was returned to work a few weeks afterwards. Recovery was complete.

These mucous cysts of the sinuses are not common, at least very few cases have been recorded.

Not less rare are the dental cysts, of one of which M. Liautard gives the following interesting account. A seventeen-year-old mare, after influenza, discharged freely from the nose, showed slight swelling of the submaxillary gland, and a little swelling of the right side of the forehead. An American veterinary surgeon diagnosed the case as glanders. M. Liautard, after carefully examining the animal, declared the symptoms due to a simple collection of pus in the sinuses. The teeth appeared sound, and there was nothing unusual in the mouth. On opening the inferior maxillary sinus, three dental cysts were found, each containing a hard moveable body of the consistence of enamel, —in fact, a rudimentary tooth similar to those found in cysts of the temporal region. Extraction of these teeth and destruction of the cysts offered no difficulty. In some weeks recovery was complete.

The first division of my subject comprises lesions which remain confined to the sinus, and usually only reveal themselves by symptoms of suppurative inflammation in these cavities, a condition which often complicates tumour formation after the lapse of a certain time.

Myxomata and fibrous polypi form two other varieties of tumours of the sinus, commoner and graver than the preceding, save when they are recent and limited to one of these cavities. Fibrous polypi, as a rule, are more dangerous than myxomata. Both usually affect the ethmoid or the floor of the sinuses. They grow somewhat rapidly, thrusting aside the bony walls, especially the external, invade neighbouring parts of the nasal cavity, and may there develop to a consider-

able extent, impeding respiration and producing a loud roaring sound, or even death by asphyxia. M. Trasbot has published a curious case of this nature. He had to treat a mare which for six months had suffered from intermittent muco-purulent discharge from the left nostril, sometimes streaked with blood. Tumour of the sinuses was suspected. The discharge grew more and more abundant, the submaxillary glands became swollen, and the animal roared loudly during work. Further examination revealed nothing, either in the forward portion of the cavities or in the mouth. The roaring sound became more intense; finally it was produced when at rest in the stable. Swallowing was interfered with, and the saliva escaped by the mouth. One morning this animal was found dead in its box. *Post-mortem* examination explained these peculiar symptoms. The tumour, which arose from the ethmoid, was formed of two perfectly distinct parts: one partially filled the frontal sinus without becoming in any way adherent to its walls; the other, extending along the anterior turbinated bone within the nasal cavity, had developed very extensively, passing beyond the guttural opening of the nasal meati, traversing the pharynx, and latterly arriving at the larynx, its extremity had at last accidentally entered the latter and had doubtless excited spasm, followed by death. On histological examination this tumour proved to be a myxoma. Considering the narrow base from which it originated on the ethmoid, excision would have been easy had the growth been early discovered.

M. Labat described a case of polypus of the sinuses, successfully treated by ablation, in an eight-year-old horse. The superior maxillary and frontal sinuses of the left side were the seat of a polypoid tumour, which had deformed the surrounding hard tissues. From the bone covering the superior maxillary sinus, a triangular piece, two and three quarters by three and a half by four inches in size, was removed. The tumour, which was attached to the roof of this cavity, was entirely removed. At the end of two months the opening in the bone was reduced to two thirds of its former size, but did not entirely fill up. Many practitioners have also operated with success on fibromata and myxomata of the sinuses.

The cases I have collected lead me to regard sarcomata of the sinuses as rather rare, nevertheless cases are seen from time to time. A number of you, without doubt, remember a horse whose case formed the subject of a clinical lecture last year, and the slaughter of which I recommended on account of sarcoma of the superior maxillary bone and of the sinuses. When brought here this horse showed, on the left

side of the face, a hard, diffuse, slightly painful tumour, without enlargement of the corresponding submaxillary space. A purulent discharge escaped from the left nostril. On examining the cavity of the mouth we only noted a trifling swelling of the mucous membrane on each side of the line of molars. The horse being old and used was slaughtered. *Post-mortem* examination showed that the sinuses of the left side were to a great extent filled by this tumour.

I confine myself to merely mentioning melanotic and mycotic tumours, which in exceptional cases may be met with in the sinuses.

I now arrive at an extremely grave form of secondary tumour occurring in these cavities: I mean epithelioma. The history of a few patients will doubtless fix in your minds the symptoms and malignity of these tumours.

Towards the end of last year, a ten-year-old horse was brought here by a man who had bought it a few days before. He had noted that the cheek was swollen, that the animal had a discharge from the left nostril, and that it ate with difficulty, symptoms which he thought would be cured by a few applications of the tooth rasp.

The animal's general condition was good, though it showed some depression, and the face indicated suffering. Attention was specially arrested by a curdled stinking discharge from the nose, and by strings of saliva running from the mouth. On examining the cavity of the mouth, the nature of the condition was easily recognised. Unfortunately, it was not at all what the owner had thought. The buccal cavity contained a large tumour, involving the hard palate, and extending the entire length of the left upper row of molars. It projected slightly above the level of the mucous membrane, so that its anterior boundary opposite the second molar was clearly distinguishable. Other points were made out by inserting a gag, and artificially lighting the mouth. The last left molars, partially buried in exuberant granulations arising from the new growth, were already loose. The prominence formed by the tumour was only pronounced in the neighbourhood of the molars; over the greater part of the hard palate it was scarcely noticeable. The mucous membrane appeared simply to be covered by a kind of granular membrane. The lower nasal cavity was deformed, its floor bulged upwards owing to pressure exercised by the tumour. The latter extended to the interior of the maxilla, but had principally developed in the mouth and sinuses. Another important symptom consisted in swelling of both submaxillary glands, a condition strongly indicating the nature of the new growth. The submaxillary gland on the left side formed a bosselated very hard mass,

as large as an egg, and adherent to the deeper-seated tissues. The right was the size of a pigeon's egg, showed the same irregularity, and was very hard. The diagnosis of epithelioma of the maxilla was therefore fairly clear. The animal was incurable. Being asked to leave it for a time, the owner preferred to remove and re-sell it, so that I did not again see this patient.

The following is a similar case dating from 1891. A twelve-year-old horse was brought to the clinique with this history: About three months before, its forehead was seen to be swollen; the swelling increased gradually, mastication became painful, and an offensive discharge occurred from the right nostril.

The right side of the face showed a diffuse, firm, slightly painful swelling, not extending beyond the anterior extremity of the zygomatic ridge of the superior maxillary bone. The submaxillary gland of the same side formed a hard bosselated mass, moveable in relation to the skin, but very adherent to the deep parts. From the right nostril a greyish ill-smelling discharge occurred. By separating the wings of the nostril, a greyish tumour could be seen filling the nasal cavity and extending forwards between the turbinated bones. On examining the cavity of the mouth, the portion of the hard palate extending along the line of upper molars was seen to be occupied by a reddish, exuberant, granulating swelling, which towards the middle of the mouth almost covered half the space between the rows of teeth. The cheek was partially filled by vegetations, and by food material in a putrefying condition. Several of the molars were very loose, and their alveoli had certainly been destroyed.

Though swelling of the forehead was relatively little pronounced, you saw that the changes were extensive. The diagnosis, incurable tumour of the maxilla, was patent to all. Microscopic examination of a fragment of new tissue removed from the hard palate opposite the second molar confirmed this diagnosis. The growth was a lobulated epithelioma of the pavement-epithelium type. Soon afterwards the animal was slaughtered. I was able to obtain the head, and trace the extent of the lesions. The tumour had destroyed almost the whole of the upper maxilla, the anterior portion of the palatine bone, and part of the turbinated bones. It filled the middle third, and part of the upper third of the right nasal cavity, as well as both maxillary sinuses. The third and fourth molars were completely detached, the second, fifth, and sixth hardly retained their positions. The affection was well marked in the submaxillary lymphatic glands, which presented the same characters as the tumour.

The case we have just seen is that of a gelding about fifteen years old. Six months ago it showed gradual swelling of the upper left maxilla. A veterinary surgeon who was consulted considered this due to injury, and prescribed treatment, but without success. The swelling slowly increased, mastication became difficult, and the breath from the left nostril stank. These symptoms had existed about two months before the animal was brought to our clinique.

The most striking feature at first glance was the asymmetry of the face. The cheek muscles were atrophied. The prominence of the masseter, usually so well marked, had disappeared, and was replaced

FIG. 5.—Pavement-celled epithelioma of the maxilla. Transverse section of the face in front of the fifth molar.

by a distinct depression. In the region of the superior maxilla, between the zygomatic process and the orbital cavity, was a tumour as large as a man's fist, uniformly hard except at its centre, where the skin had ulcerated, and allowed of fungous vegetations protruding. Examination of the parts was painful, and caused the animal to struggle. From the left nostril ran a grumous offensive discharge, the amount of which increased with exercise. The lymphatic glands in the submaxillary space were enlarged, a little indurated and

painful, but moveable under the skin. The mouth was offensive. On examining the buccal cavity, considerable destruction of mucous membrane was noted on the left, and the gum on either side of the row of molars was covered with vegetations. By using the mouth-gag, the second, third, and fifth molars were found to be loose and implanted in a soft tissue. They were surrounded with decomposing food. The fourth molar had fallen out, its place being occupied by fungating new tissue. In order to make a more complete examination the animal was cast and chloroformed. The face was trephined at three points around the centre of the tumour. The large opening thus made showed the greater part of the maxilla to be destroyed, and exposed the roots of the molars, whose bony alveoli had disappeared. The second and fourth molars were removed.

Diagnosis was easy. The symptoms were due to a tumour, which had invaded the greater part of the superior maxillary bone, had filled the sinuses, and had perforated the bony palate. Microscopic examination showed it to be another case of epithelioma of the pavement epithelium type.

The animal was slaughtered. No secondary growths could be detected in the viscera. The superior maxilla was almost completely destroyed. The first molar was still fairly firm, but the fifth and sixth yielded to gentle traction. The new growth hardly projected above the level of the palate, which, however, was invaded throughout the entire left side, from its posterior border to a point level with the first molar.

You see that these three cases are almost similar, the only differences being the position and extent of the lesions. In all three the tumours are similar in nature and origin—are, in fact, epitheliomata affecting deep-seated portions of the maxilla. Epithelial tumours originating in the mucous membrane of the mouth, nose, or sinuses, certainly occur, but are rare in the horse. Those most commonly seen in this region usually start from the maxilla. They undoubtedly develop from, and at the expense of, paradental epithelial débris, according to M. Malassez's theory in the case of similar tumours in man. Under the influence of hitherto unrecognised stimuli, the cells forming these small tracts of tissue may at any moment commence to proliferate, and may form in the depths of the bone a tumour which afterwards extends towards the mouth or sinuses, most frequently towards both simultaneously. Little by little the cancer destroys the walls of these cavities and the alveoli of the teeth. Sometimes it excavates in the bone a large cavity, lined

with epithelial fungations. This form has been termed rodent cancer of the maxilla. Even when the affection is discovered early, for example at the moment when the buccal mucous membrane becomes ulcerated, or when the face begins to show deformity, the body of the maxi la or the alveoli of the teeth have already undergone extensive injury.

You must guard against founding your prognosis of tumours in the region of the sinuses on the volume of the swelling, or distortion of the facial bones. Whilst epitheliomata of the maxilla, even though hardly visible, are of the greatest gravity, innocent tumours developed from the mucous membrane of the sinuses may press against the external wall of the cavity containing them, thinning, lifting, and perforating it, and finally breaking through the skin. Such benign tumours can be operated on with success. The animal is chloroformed, the invaded cavities freely opened—most frequently the two maxillary sinuses are those affected—and the new growth totally removed, either in one or several portions. Hæmorrhage is checked by plugging, or the use of the cautery. But in the case of truly malignant tumours such operations are unjustifiable, and the practitioner who wishes to avoid compromising his reputation will not attempt them.

In speaking of these tumours it is well, in animals as in man, to reserve the epithet of malignant for those which grow rapidly, invade neighbouring tissues—bone and soft parts—and which extend to the lymphatics ; to those, in a word, whose course simulates the progress of an infectious disease.

I may summarise the practical deductions to be drawn from the cases described in a few words :—Tumours developed on the mucous membrane of the sinus, which have only affected the bone by mechanically lifting it, or by exercising on it permanent prolonged pressure, are curable. If the value of the animal justifies intervention they should be removed.

When, however, the new growth invades tissues indiscriminately and has partially destroyed the walls of the sinus, or affected the alveoli of the teeth, without, however, seizing on the lymphatic glands, it is almost always of the nature of an osteo-sarcoma, and interference is not advisable.

Finally, when the tumour shows metastatic characters, and affects neighbouring lymphatic glands, it is usually a malignant epithelial tumour, beyond operation, and always liable to return if ablation is attempted.

V.—THE SURGICAL TREATMENT OF CHRONIC ROARING.

One day last week M. L—, of No. 12, Place Vendôme, Paris, sent us for examination a horse suffering from chronic roaring, asking whether we would carry out on this animal the operation performed last year on a mare belonging to his neighbour, M. D—. He stated that M. D—'s mare, which had suffered from intense roaring, rendering her useless before operation, was at that moment doing good service, and that M. D— was very well pleased with the result. I was not at the clinique on that day, but several of you will remember the mare in question. The operation indicated was arytænoidectomy.

I may shortly sketch the history of the animal thus cured. She was an Anglo-Norman mare, which excited much attention at the horse show of 1893, where she received the first prize for harness horses. Bought towards the end of the show by M. D—, she worked well until 1895. During the winter of 1895–6 she contracted pneumonia, and on return to work was found to have become a roarer. She was unsuccessfully treated with iodide of potassium. The roaring grew so marked that the animal, even at moderate paces, several times fell in the shafts. M. D— took the advice of several veterinary surgeons. A consultant told him that the disease was incurable, and that he would have to dispose of the mare. M. D— replied that he valued her greatly, and that he had heard speak of an operation which without the use of a tracheotomy tube had several times rendered roaring horses useful. He was informed that the operation did not succeed once in a hundred times.

Having been thus advised, M. D— came to me one morning at the school, and asked whether I would consent to operate on his mare. After having exactly informed him of the value of surgical treatment for roaring, I proposed to first perform the small operation, and in case of failure to perform the other—terms which he accepted.

On the 18th January I performed partial cricoidectomy. Returning to work on the 8th February the mare roared to the same extent as before operation. Being sent back here on the 5th March I

removed the left arytænoid. She once more went to work at the commencement of May, since when she has continued without interruption. At the present time she occasionally gives a few dry coughs, but no longer roars at a trot. At a very fast pace she produces a slightly abnormal noise, otherwise without importance, for it is not accompanied by any distress or interference with respiration.

This is not an exceptional case. Since the first results, which I published in 1890, a number of my patients have proved to be cured and others to be improved. During the last few months several animals have returned here, in which after intervals of a year, eighteen months, or two years, the good effects are found to have been maintained.

These results are interesting, if only from the point of view of the surgery of the larynx. They show that deep, extensive wounds of the larynx readily heal without pulmonary complications, and that intra-laryngeal wounds with loss of substance may cicatrise without producing contraction of the air-tube. Considering that the condition for which operation is performed was formerly regarded as absolutely incurable they are encouraging, for if failures are still frequent, we now know how to avoid various accidents to which the operation gave rise at the time when I commenced to study it. This is not one of those operations which only became possible after the discovery of antisepsis. The progress effected is simply due to more perfect technique.

On previous occasions I have spoken of the experiments made more than half a century ago by Günther with the object of curing roaring. I have also mentioned Möller's researches, of which I gave a *résumé* in my work in 1891. Among the various methods of operation proposed by these veterinary surgeons is one whose efficacy is undoubted, and which deserves preference before all others. This method is arytænoidectomy.

In the great majority of cases I have treated I performed arytænoidectomy pure and simple, following the method described in my work* and in my text-book on surgical treatment. I have since somewhat modified the instruments and technique. To ensure not injuring the mucous membrane of the trachea by undue compression, I replace the rubber balloon surrounding the Trendelenburg cannula with plaited gauze, fixed to the tracheotomy tube by ligatures. I only cut through the cricoid cartilage and first ring of the trachea. I

* See 'Roaring in Horses,' by P. J. Cadiot, translated by T. J. W. Dollar.

incise the laryngeal mucous membrane along the superior and posterior margins of the arytænoid a little within their borders. As a dressing I place in the larynx two rectangular, flattened tampons of gauze on edge, which I fix by passing through them the silk threads of the suture used to unite the muscle. I remove the dressing and tracheotomy tube at the end of twenty-four hours. For the first few days I keep the trachea open and the wound exposed, by passing through the centre of the skin and muscle forming the lips of the wound two threads, which are tied together above the neck. Whilst sparing the mucous membrane covering the superior and posterior margins of the arytænoid as much as possible, I slightly changed, though I ought to say without much benefit, the method of removing the cartilage. In certain cases I preserved a narrow band of the mucous membrane covering the anterior margin of the cartilage. In others, where the larynx was particularly narrow, I made the incision opposite the inferior margin of the arytænoid a little larger, extending it to the mucous membrane and the upper part of the vocal cord. In others, again, I removed the greater part of the articular angle of the arytænoid with cutting forceps. Except for this latter modification, I consider it very important to limit as far as possible the area of incisions in the laryngeal mucous membrane; not to extend towards the region of the œsophagus when detaching the upper surface of the arytænoid; and not to wound either the portion of the arytænoid left or the vocal cord.

With a little practice the manipulations in arytænoidectomy are easily performed, even without anæsthesia; but these manipulations cannot be carried out correctly, or with the necessary certainty, by an unpractised or clumsy hand.

When the wound resulting from ablation of the arytænoid heals regularly, when granulation is not excessive or new cicatricial tissue exuberant, the entrance to the larynx remains enlarged; the result is then good.

In favourable cases the course of events is as follows:—The mucous membrane at the four margins of the wound left by removal of the arytænoid is far from being equally moveable; the superior and inferior margins of this wound cannot be united by suture, but it is easy to bring the anterior and posterior in contact without dissection and without tearing; the reason being that the anterior edge is very moveable and can easily be drawn towards the posterior, thus covering the whole wound. If left to itself the wound granulates over its entire surface, and the cicatricial tissue in contracting draws the anterior margin much nearer the centre than it does the others. It is the

anterior margin, therefore, which principally restores the covering of the parts; and when repair occurs regularly, without excessive new tissue formation, the upper portion of the larynx is and remains distinctly concave at its left side, *i. e.* at the site of operation. Under these conditions the vocal cord can neither be pushed nor drawn towards the median line. It is fixed in the position it occupies or drawn slightly outwards.

Unfortunately, our subjects do not voluntarily allow anything to be done. It is impossible to follow the progress of the wound, to superintend the healing, or to repress the excessive granulations which may form, and thus to obtain a flat cicatrix—an essential condition for the disappearance or diminution of roaring.

Attempts have been made to still further enlarge the passage by excising, along with the arytænoid, either the vocal cord, or the vocal cord and internal wall of the laryngeal ventricle. These are old methods. Ablation of the arytænoid and of the vocal cord is not nearly so valuable as simple arytænoidectomy. After a large experience I regard the benefit sought by removing the vocal cord as illusory. The mucous wound is greatly enlarged, and its inferior part, whence the cord is removed, is precisely that which most readily vegetates and gives rise to excessive granulations.

There remains, then, arytænoidectomy, completed by removal of the internal wall of the laryngeal ventricle. The advantage of enlarging the air inlet throughout its extent, without sensibly increasing the surface of the excision wound, was claimed for this operation. It has been given up because most horses upon which it was performed died from mechanical pneumonia, due to passage of particles of food into the lungs. I avoided this by feeding my patients in the same way as human beings who have undergone arytænoidectomy, and by exercising the same care after operation.

The procedure was as follows:—I commenced by performing arytænoidectomy, following the ordinary method and suturing the borders of the wound. I afterwards passed the index finger into the ventricle of the larynx; with one limb of a pair of straight scissors, introduced into the ventricle, I vertically divided the inner wall of the latter throughout its depth. Grasping the anterior flap with forceps, I partially excised it with curved scissors, avoiding injury to the epiglottis. I next grasped the posterior flap, covered by the vocal cord, in the same way, and removed it from below upwards with a button-pointed bistoury. The dressing and the subsequent precautions adopted were similar to those after arytænoidectomy.

This operation always gave bad results.

Of the various methods suggested, arytænoidectomy not only causes the fewest possible complications, but also gives the greatest number of lasting successes.

Like all bold operations, like all surgical innovations directed against diseases previously considered incurable, arytænoidectomy has its drawbacks and dangers; but the fact remains, and cannot be gainsaid, that it renders useful for various kinds of work a number of roarers otherwise condemned to tracheotomy.

Like other methods of treatment, it must not be expected to effect too much, and those persons are certainly over-exacting who, after having all their lives proclaimed the absolute incurability of chronic laryngeal roaring, reproach it for its uncertainty and for its infrequent success, as if, instead of advancing a little even by the process of groping one's way, it were preferable to stand still.

It is, I feel sure, superfluous to labour the point, and I conclude by repeating with Lanzilotti:

"*E indubitato che molti cavalli sono guariti!*"
[Undoubtedly many horses are cured.]

VI.—ACUTE INGUINAL HERNIA.

Last month an entire horse left here for treatment underwent two grave operations on the same day, one of which was rendered necessary by a quite unexpected accident. We had cast the animal in the morning to operate for necrosis of some of the horn-secreting tissues resulting from a prick in shoeing. The same evening we had to cast it again: it had a strangulated inguinal hernia—a hernia certainly due to the violent struggles it had made during the first operation. The history of this horse is interesting for a double reason, of which you will judge later.

It was brought for examination on the 16th April because it went lame on the off fore-leg, and, to assist us in diagnosis, the driver stated that the animal had fallen the night before on the right side,—that before this fall it had not shown the slightest defect, but that it had gone lame immediately afterwards.

I may add that it was brought here by its regular driver, who mentioned that he had found the shoulder painful, that he regarded it as the seat of lameness, and that the farrier who had been referred to said the same thing. We thus had to guide us the opinion of two experts.

I examined the horse before you. I showed you that the different portions of the limb exhibited no recent lesion to explain the lameness, and that the shoulder especially was neither swollen nor painful. Rather more restlessness was certainly shown on this side when the two shoulders were comparatively examined, but that was due to a slight stimulant application which had been made, and possibly also to the manipulation, pressure, and traction carried out by the two colleagues. Percussion on the foot, however, produced very evident flinching. On lightly tapping around the hoof near the shoe the animal responded by lifting the foot. A similar test applied to the other foot produced no result. On removing the shoe—especially when I lifted the inner branch with the pincers—the animal again showed signs of pain. Similarly, when I "tried the foot round" by compressing the circumference, the animal was uneasy. The quarters and the inner heel were especially sensitive. I then proceeded to cut a groove along the white

line and expose the nail-holes, the animal meanwhile showing pain and drawing away the foot, and in a moment it became clear that the last nail was badly placed. On cutting down, the horn soon appeared yellowish and infiltrated. Finally a little greyish pus exuded. The horse had been pricked.

I thoroughly thinned the inner heel, sole, bars, and posterior portion of the quarter; in order to diminish compression of the injured parts I slightly enlarged the opening in the sole, washed out the purulent cavity with an antiseptic solution, and, as is our custom in cases of this kind, enveloped the foot in a thick layer of tow, moistened with five per cent. solution of sulphate of copper.

The horse at once appeared to be relieved, and lameness had diminished. During the evening, and following days, the tow dressing was again moistened with sulphate of copper solution. For some time the condition remained practically unchanged, but on the morning of the 20th lameness was excessive, and the animal showed evidence of shooting pains in the foot. Some complication existed, and it became necessary to interfere more actively.

The quarter having been thinned, the animal was cast on the right side, the affected foot released from the hobbles, and fastened above the hock of the same side. Opposite the point where the nail had penetrated I removed the entire horny wall for a distance of two to two and a half inches in breadth, corresponding to the area over which I concluded the sensitive tissues had become necrotic. In the lower third the sensitive laminæ, though thickened, infiltrated, and bright red in colour, were only inflamed, but between this part and the coronet was a black gangrenous patch as large as a two-shilling piece, dotted over with greyish points. I removed this dead piece of tissue, exposing at its upper part the lateral cartilage and below a narrow strip of the pedal bone. I excised a thin layer of the cartilage, which already appeared of a light green colour, and curetted the bone, the superficial layers of which were infiltrated with pus. Finally I irrigated the wound with a 1 in 1000 solution of sublimate, powdered it with iodoform, and covered the parts with a surgical wool dressing. The operation and dressing had lasted about half an hour.

On rising the horse walked much more comfortably than before operation. The foot was not lifted in the same restless way; the lancinating pains had ceased. It was returned to its box, and at once began to eat. This was about 10.30 a.m.

At 1 o'clock in the afternoon my assistant came to say that the animal was showing signs of acute colic. Some of you had noted a distinct difference in the two spermatic cords, but did not suspect the

existence of acute inguinal hernia. You will remember that on the first examination I was able to enlighten you on this point. Whilst the left cord was relaxed and free, and its different parts could readily be distinguished with the fingers, the right was retracted, enlarged, and felt as though inflated; the two principal parts, the vascular cord and the vas deferens, could no longer be distinguished. At the first touch one could feel that the distended vaginal sheath contained, in addition to the spermatic cord, a loop of intestine swollen by strangulation. The clinical characters were such as to leave no doubt regarding the condition.

The horse was cast on the left side, chloroformed, the off hind leg abducted and fixed with lengths of webbing by the usual method. Some attempts at taxis having failed, I was obliged, after preparing the parts, to perform the operation for strangulated inguinal hernia—kelotomy.

You will recall the stages—free incision of the scrotum and dartos in the long axis of the hernial swelling; isolation of the mass formed of deeper seated tissues, the vaginal sheath and its contents, by breaking down the subdartoid connective tissue, this isolation being prolonged upwards as far as possible; puncture of the vaginal sheath at its posterior part, where its parietal layer is in contact with the testicle; laying open the base of the vaginal sheath parallel to the long axis of the testicle for a distance corresponding to the entire length of the latter; seizing the edges of the sheath by means of broad-jawed forceps; incision of the outer edge of the hernial ring with a button-pointed bistoury; washing of the extravasated intestine with boiled water; reduction commencing with the upper parts of the loop; re-application of the vaginal sheath over the cord; torsion of these parts; application of curved clams; finally, removal of the testicle by dividing the cord half an inch below the clams.

In this horse the loop of herniated intestine, situated as usual in front of and inside the cord, measured about ten inches in length; it was severely congested and distended; its walls were infiltrated with fluid, but were firm, resistent, and not abraded, and there was therefore no fear of their tearing through under cautious manipulation. The first incision not having given sufficient space, I reintroduced the left index finger into the vaginal sheath as high as the hernial ring, and increased it. Although the opening was sufficiently enlarged, the intestine returned with difficulty. I therefore had the horse placed on its back, and whilst one of you exercised traction on the upper part of the herniated loop through the rectum, I recommenced taxis. Reduction was complete in a few minutes.

When the herniated loop of intestine is situated outside the cord it is sometimes difficult to incise the hernial ring, and great caution is then necessary to avoid injuring the cord itself. Last year we operated on a bubonocele of this character which had existed for twelve hours. Limited to the upper half of the inguinal canal, the loop was situated in front of and external to the cord. On account of the danger of injuring the intestine, which was greatly distended by gas, I was obliged to make several attempts before I succeeded in dividing the ring. Reduction was easy, and the animal recovered, practically without showing fever.

I return to our last patient. When taken back to his box he was still dull and stupid; but the symptoms due to chloroform gradually disappeared. In the evening he ate his food, and showed no abnormal symptoms. At 8 o'clock the temperature was 100·4° F.

During the following days his general condition remained perfectly satisfactory; the fever was moderate, the temperature not rising beyond 103·1° F. The horse placed weight on the foot, and lancinating pain was absent. Treated with sublimate irrigations the inguinal wound suppurated very little, and the swelling did not exceed that usual after castration. The clams were removed on the sixth day.

Healing of both operative wounds occurred without complication or accident of any sort. On the 17th May the patient left the hospital. Some days afterwards he returned to work.

This case shows that injuries of the fibro-cartilage of the foot may heal rapidly and without complications. It was long taught that necrosis of the central or anterior parts of this cartilage, or even their extensive exposure by removal of necrosed sensitive laminæ, necessitated removal of the cartilage *in toto*. This rule, as you see, admits of exceptions. In our patient the cartilage was freely exposed in front; its superficial layers exhibited the greenish colour peculiar to necrosis, and yet partial excision sufficed. The cartilage healed like the podophyllous membrane which normally covers it.

Several years ago I published a number of cases showing that wounds of the feet involving the fibro-cartilages could be perfectly cured, without subsequent necrosis and without complication, by simply removing the infected or mortified parts of the cartilage, and that success can be obtained whatever the point at which the fibro-cartilage is wounded or necrotic. Operations on the horse's foot especially show the great value of modern surgical methods—antisepsis and the use of surgical dressings.

But this is not the principal point to which I wish to draw your attention. The most important thing to bear in mind is the possible occurrence of such grave accidents as that which overtook our horse whilst I was operating on the foot, the occurrence of hernia from casting. Luckily such things are rare. Still it is necessary to know that they may occur in order to recognise and remedy them in time.

This accident is the second I have noted among injured animals in my clinique. I saw the first case in January, 1889, in a horse operated on for picked-up nail of the near fore-limb. The animal was cast on the right side. In his case hernia occurred on the left side. Its presence was indicated as usual by colic, and the condition was diagnosed three hours after occurrence. Performed rapidly and under good conditions the operation succeeded.

It is not always so. When sick animals are not watched with sufficient closeness hernia may fail to be recognised until too late, or pain resulting from strangulation of the intestine may be referred to the operation which has been performed, the real cause not being revealed until *post-mortem* examination. Even here I saw a case of this character some seven or eight years ago in a horse operated on at the school, and at once removed by its owner, who lived in the neighbourhood. The owner noted that the animal was suffering from colic, but as it had great difficulty in walking it was treated at home with some nostrum. No one suspected for a single instant the existence of hernia.

I conclude by formulating the warning to be drawn from the above facts :—Should an entire horse soon after having been cast for operation show signs of colic, bear in mind the possible existence of hernia ; compare the two inguinal regions, and in proportion as pain persists direct more and more attention to the state of these parts.

VII.—DEEP-SEATED INGUINAL ABSCESS AFTER CASTRATION.

During the holidays we operated on an English-bred five-year-old horse whose case was so instructive from the clinical point of view, and offered such peculiarities, as to merit some remark.

The horse was castrated during the early part of May, *i. e.* more than five months ago. The operation was performed by the covered method, with clams. The wounds healed slowly, that on the left side not closing entirely, and a fistulous wound persisted, due, as it was thought, to "scirrhous cord." A veterinary surgeon, being consulted regarding this sinus, first of all prescribed antiseptic injections. In a month's time, seeing that they had no result, he cast the animal, explored the inguinal region, and not finding any induration of the left cord, suggested, as a temporary measure, to continue the injections for a further time. New symptoms appeared; the animal's movements became impeded; the near hind leg, which was slightly swollen, was advanced with difficulty, and with a circular swinging movement (abduction). The appetite remained fair, but the animal lost flesh, and its coat appeared dull. M. Weber was asked to examine it. He was struck by the interference with movement of the near hind limb, and although swelling of the perinæum was little marked, and the purulent discharge trifling, he advised that fresh surgical treatment was necessary. The horse entered our clinique on the 27th August.

I had only been told part of this history when, two days later, I had the animal cast, thinking we had to deal with a simple scirrhous condition, situated more or less high in the cord. The inguinal region was, as I have just said, little swollen, but showed diffuse induration, extending forwards over the abdominal region beyond the opening of the sheath. Having passed a director and laid open the fistula in front and behind, I only found a purulent cavity the size of an egg, situated at the lower part of the fistula. I incised the fibrous layer covering the inguinal canal, the entrance of which I explored without discovering anything abnormal. The sinus and abscess could not explain the swelling of, nor the difficulty in moving the near hind leg.

The diffuse induration about the wound gave one the impression of a new growth, so that for a moment I fancied we might be dealing with an epithelial tumour developed in the perinæal region, and extending far forwards in the abdominal wall.

Having enlarged the fistulous track, I asked M. Weber to examine the parts, and explore the fistula and abscess cavity. He found nothing to explain the symptoms previously noted. Nevertheless we decided not to make a deeper exploration at the time. I curetted the walls of the abscess, excised a fragment of dead tissue for microscopical examination, washed out the wound with an antiseptic solution, and allowed the animal to rise. During the evening the operative wound was washed out several times with sublimate solution. Histological examination of the tissue removed showed that the lesion was of an inflammatory character, at least at the point from which the fragment had been removed.

Next day the patient's general condition was little changed. The neighbourhood of the wound was somewhat œdematous. Wishing to examine the state of the upper inguinal region and intra-abdominal portion of the cord, I had the animal fixed, without, however, casting it. The hind limbs hobbled, I proceeded to rectal exploration. In the pre-pubic zone, opposite the left inguinal ring, I found a kind of diffuse, rounded, smooth-surfaced swelling, larger than a man's two fists, and about four inches thick. This swelling was indolent or nearly so, and uniformly hard. No fluctuating point could be discovered with the fingers. The cord which emerged from it was scarcely enlarged. These are not the characters of an abdominal scirrhus; in that affection the neighbourhood of the inguinal ring is seldom much swollen, whilst the cord itself is large and hard.

Funiculitis, therefore, having been eliminated, with what condition had we to deal? It could only be a tumour or an abscess. The absence of pain on pressure, uniform hardness, and slightly bosselated surface of the swelling rather indicated a new growth than an abscess. On the other hand, the swelling of the corresponding hind limb, and the interference noted in regard to movement, might be explained by either theory, on the basis of the disease having extended.

On being informed of the discoveries I had made, and of the gravity of the condition, the owner granted me full permission to operate further if I thought it advisable. The following days the swelling of the inguinal region remained stationary, but that of the limb gradually increased. The temperature oscillated between 101·3° and 102·8° F., in addition to which there was depression and loss of appetite.

The 5th September, after examining the swelling *per rectum*, and

discovering that it showed the same characteristics as before, I cast the horse on the right side, and drew the left hind limb as far outwards as the swelling allowed. The inguinal region and surrounding parts were washed with warm water and soap, and afterwards irrigated with sublimate solution. With a bistoury I enlarged the wound in the direction of the long axis of the inguinal ring, cutting through the layer of hardened tissue surrounding the edges of the ring. A few vessels which bled rather freely were picked up with artery forceps. Having thus opened the inguinal canal, I enlarged the space by breaking down the connective and fibrous tissue which fills its lower part. Arrived at its middle portion without finding any traces of the spermatic cord, I was arrested by a strong partition running obliquely from above downwards and backwards, a partition which projected at its centre point, and through which I distinctly made out fluctuation. With a sudden thrust of the left index finger perpendicular to the general surface of the centre of this partition, I perforated it. A flood of whitish, creamy pus immediately escaped through the lower inguinal ring. To enlarge the aperture I cut through the lower part of the partition with a bistoury. The abscess cavity was enormous, extending particularly in the direction of the inguinal space. It did not contain four quarts of pus, as the prosector entrusted with the dressing has stated, but certainly at least two quarts.

The pocket was washed out with warm 2 per cent. creolin solution. Bleeding, which at first had been rather severe, soon ceased. A large drainage-tube was placed in the inguinal canal, its upper end entering the cavity of the abscess. The lips of the incision were brought together with four sutures, one of which was passed through the drainage-tube itself, about two inches from its lower extremity.

On rising the animal appeared to be greatly relieved, as one may very well imagine, and when returned to its box at once began to eat. During the evening the pus cavity was again twice washed out through the drainage-tube.

Next day the general condition was greatly improved. The animal had eaten all its food; weight was firmly placed on the limb, which, however, was still swollen, and the temperature was only a few tenths of a degree above normal.

During the following days improvement steadily continued. The swollen limb gradually diminished in size. As in most cases of infected wounds in the inguinal region, a fairly large œdematous swelling developed around the surgical incision, without, however, showing any disquieting character. Treatment was confined to washing out the abscess cavity with disinfectants.

Up to the 13th September suppuration remained abundant, and the swelling around the wound considerable, but the other symptoms—especially the serous infiltration of the limb and difficulty in movement—steadily diminished. On the 18th the intra-abdominal swelling was limited to the cord, which was, however, hard, conical in shape, and smooth on the surface.

From that date up to the 30th September the wound gradually contracted, its surroundings diminished in size by re-absorption of the interstitial exudate, and the purulent discharge diminished daily. On the 8th October, when our patient left hospital, the wound was only two and a half to two and three quarters inches in length—the margins a little swollen, the suppuration almost entirely ceased. By comparative examination of the upper inguinal regions one simply detected the persistence opposite the inguinal ring of a narrow indurated zone, and a rather firm condition of the cord for a distance of an inch or two.

After castration by ordinary methods abscesses sometimes develop under the dartos. Their nature is well known. They result either from too early union of one of the operation wounds—union occurring while suppurative inflammation is still going on in subjacent tissues; or from retention of a foreign body—one of the strings used for fastening together the branches of the clams, for example. But deep-seated abscesses in the inguinal space, where the pus remains enclosed for several months, as in the case just mentioned, are exceedingly rare.

Apart from its inherent interest, however, this case teaches a lesson you should never forget. I have repeatedly shown you that in wounds of the horse's foot, when the intensity of the general symptoms suggests grave local mischief, and when after removing the horn the subjacent sensitive tissues appear simply to be inflamed round about the wound, it is necessary to incise these tissues, and to seek below them the principal diseased centre. The same line of conduct applies to diseases of other regions, more particularly to those of complex anatomical structure. When the local lesions met with in superficial parts do not sufficiently explain the functional and general disturbance which have led to surgical interference, you must seek beyond, and explore the depths. With exact anatomical knowledge, prudent technique, and antiseptic precautions, exploration of these regions is unattended with danger.

VIII.—DIAPHRAGMATIC HERNIA.

On Thursday last a horse, which had suffered from colic for nearly a week, and whose state had rapidly become aggravated during the last night passed in its own stable, was sent here for advice. At the time of examination it was in a very grave condition, profoundly depressed, and staggering on its legs. The face was drawn, the pulse almost lost, the respiration very rapid and oppressed. Percussion of the thorax revealed dulness in the lower third and tympanitic resonance in the upper parts. On auscultation an exaggerated respiratory murmur was heard in the upper third of both sides of the chest; between the upper and middle thirds a slight deep-seated tubal blowing sound; in the lower parts a sound indicating the presence of liquid, and borborygmus. The heart-beats were very feeble, and both jugulars showed a venous pulse.

The extreme depression, marked pain, irregularity and exaggeration of the flank and chest movements, and especially the signs furnished by auscultation, led me to diagnose diaphragmatic hernia. In order to confirm this diagnosis I washed and shaved the lower half of the left costal region, and was preparing to puncture the chest with Dieulafoy's aspirator, when the animal suddenly fell, and died after a slight struggle.

The *post-mortem* examination confirmed the diagnosis just made. We found an old-standing diaphragmatic hernia with a very large rupture and extensive injury. Many of you were absent on that date, and neither saw the horse nor the state revealed on opening the body. As this is a very rare condition, of which we shall probably not see another case during the course of this year, M. Darras will read to you the notes which he made:

A twelve-year old gelding used for rapid work.

On the morning of the 11th October this horse, previously in good health, showed symptoms of colic. He appeared anxious and restless, pawed and turned his head towards the right flank, indicating that as the seat of pain. These symptoms disappeared in a few hours, to

return, however, during the night between the 16th and 17th October. The animal rolled and struggled in violent pain. On the morning of the 17th, having refused his food, he was sent to the college. He arrived there covered with sweat, greatly depressed, and looking continually towards his right flank. The face was drawn, the nostrils dilated, the extremities and ears cold, the mucous membrane cyanotic; the respiration was 32, irregular; the pulse very feeble, and could not be counted; the jugulars showed a well-marked venous pulse.

Rectal exploration disclosed nothing abnormal. On the catheter being passed, only a small quantity of urine was drawn off.

On percussion of the chest dulness was noted in the inferior half of both sides. On auscultation the vesicular murmur in the upper portions of both pulmonary lobes was exaggerated. Towards the middle region, especially on the left side, a slight tubular wheezing sound was heard, and in the lower third a liquid sound, especially marked on the left side. We at first regarded the case as one of pericarditis, but, after carefully examining the patient, M. Cadiot noted the splashing sound and borborygmus, and delivered the diagnosis of diaphragmatic hernia. To confirm the diagnosis he resolved to tap the chest. The animal died at the moment we were about to perform the operation.

Autopsy.—In the abdominal cavity traces of peritonitis were visible on the large colon, jejunum, and ileum. At its upper part, towards the left, the diaphragm showed a large opening, through which had passed a considerable mass of abdominal viscera, comprising among other parts the stomach and some loops of intestine. These viscera were soiled with food material.

The chest cavity contained a considerable quantity of yellowish acid-smelling fluid, holding in suspension fragments of food. The left lung, congested in its antero-inferior part, and emphysematous throughout almost its entire extent, was thrust upwards towards the spinal column. The spleen was situated externally and posteriorly, and was almost entirely in the thorax. It appeared normal. Its base was turned towards the abdomen; its point was advanced and slightly depressed. Between the lung, pericardium, diaphragm, spleen, and chest walls, was a voluminous greenish mass formed by the gastro-colic omentum (epiploon) filled with food. Towards the back, between the epiploic sac, spleen, and diaphragm, were two distinct masses of intestine. The first, situated above, was formed by a part of the small colon, about twelve inches in length, covered by the epiploon; the other, below, lodged in the angle formed by the diaphragm and the left thoracic wall, consisted of several empty loops of the jejunum, of a total length of about fifteen feet.

More deeply situated under the spleen and small colon we found the stomach, flaccid and empty, pushed close up to the vertebral column, the right half in advance, the smaller curvature turned towards the vertebral column, that portion of the left sac (fundus) nearest the œsophagus riding on the right margin of the rent in the diaphragm, a position which prevented food material returning into the œsophagus. The cardiac end (fundus) had also undergone rotation, which prevented vomiting. In the greater curvature of the right *cul-de-sac* was a large rent measuring about eleven and a half inches in length. The margins

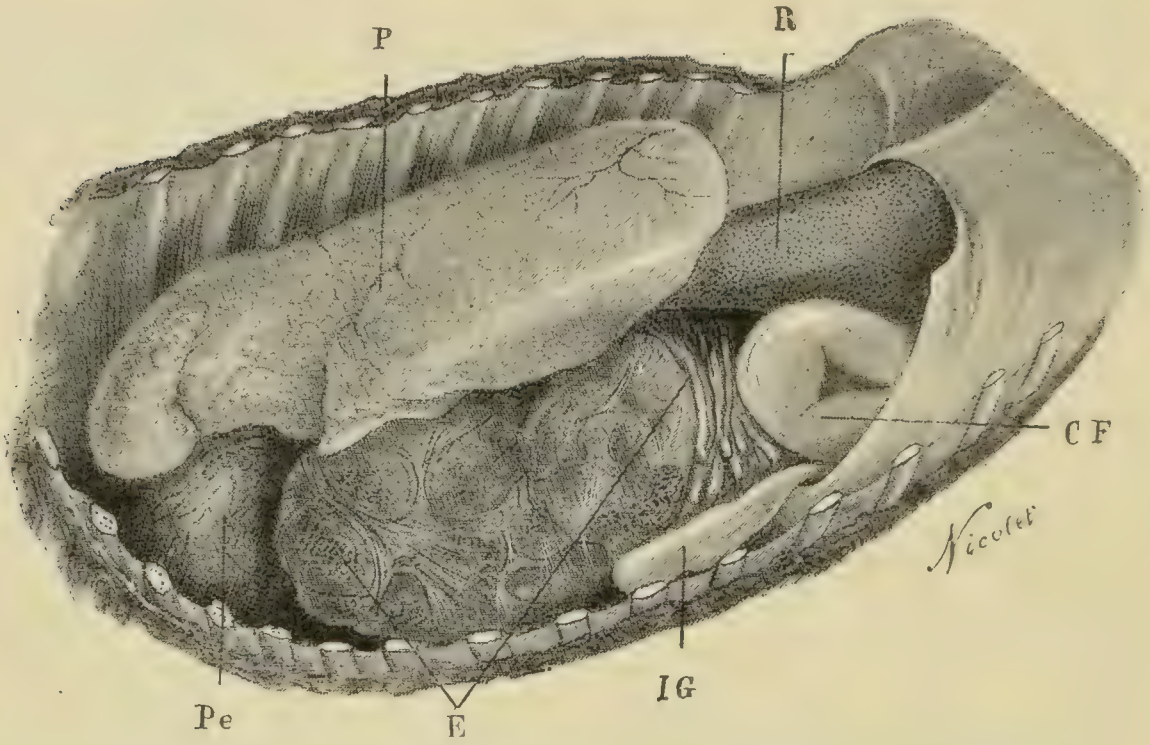

Fig. 6.—Diaphragmatic hernia. E, epiploon. I G, loop of small intestine. C F, floating colon. R, spleen. P, lung. Pe, pericardium.

were thin and blood-stained. The rent extended through the mucous membrane for a length of ten inches, and through the muscular and serous coats a further four inches. The two latter coats were retracted, forming a deep red margin around the opening in the mucous membrane. From this opening had escaped a large amount of food, which had distended the large epiploon.

The rupture through which the abdominal viscera had entered the chest was chiefly situated in the left upper portion of the diaphragm. It was elliptical in shape, and measured fourteen and a half by six inches. Its margins were smooth and fibrous throughout the greater part of their length. The right margin was straight, thick, and rigid, and ran obliquely from above downwards and from left to right. Its

upper extremity was situated about two inches from the œsophageal opening. The left margin was concave in shape, very thick above, but thin throughout the rest of its extent, and was everywhere fibrous except towards its centre, where it appeared injected and hæmorrhagic. At the centre of the tear was a strong fibrous band as thick as a lead pencil.

Through this large opening, which had certainly existed for several months, the stomach and spleen had been thrust into the chest cavity, describing a rotary movement forwards, and from left to right, around the cardiac end of the stomach as an axis, causing the right *cul-de-sac* of the stomach (pylorus) to advance a considerable distance into the thorax.

The right lung, congested and emphysematous like the left, was adherent at its posterior part to the sides of the chest. Here again we found food material, which had traversed the posterior mediastinum. Of this mediastinum only traces remained. The pericardium contained about a quart of greyish liquid.

The diaphragmatic rupture had existed for a long time; the fibrous state of its borders showed this clearly. The hernia, at first formed of a few loops of small intestine and epiploon, had scarcely inconvenienced the animal, for the first symptoms of colic were only noted six days before death. Gastric indigestion probably formed the first step towards producing the grave symptoms which preceded the end. The gastric hernia was probably produced by the animal's violent struggles on the night between the 16th and 17th October. In the position the stomach had assumed food could no longer enter it, the œsophageal opening being hermetically closed.

To sum up, this horse died from rupture of the stomach, a complication of the hernia from which it had already long suffered, as shown by the state of the walls of the diaphragmatic rent. The stomach was probably ruptured soon after it became herniated.

How may such a hernia occur? What is the primary cause of the diaphragm becoming ruptured?

Cases published during the course of the last half-century afford a reply to these questions. In these the accident has happened in consequence of violent struggles and energetic contraction of the abdominal muscles—either during work, or when animals had been cast. In some the horse was heavily laden, and after a specially great effort suddenly stopped, showed pain, fell, and died from asphyxia; or again survived for a few hours, showing symptoms of colic and severe dyspnœa. Sometimes an animal cast for operation, after struggling violently, presented the same alarming symptoms and died rapidly, or

after the lapse of a few days. In either case *post-mortem* examination showed rupture of the diaphragm, usually in the tendinous portion ; a recent extensive rupture with bleeding margins, through which the abdominal viscera had entered the chest. Contraction of the abdominal muscles had thrust the viscera violently against the diaphragm, overcoming its resistance. Overloading of the intestines, and of the stomach in particular, favours rupture. Chronic herniæ, consequent on extensive ruptures in the central portion of the diaphragm, are produced by the same mechanism, but in this variety the primary symptoms gradually diminish, and the lesions, though never repaired, do not necessarily prove fatal.

Injuries to the costal region opposite the insertion of the diaphragm, and fracture of the last ribs, are also fairly frequent causes of diaphragmatic hernia. In these cases the opening is often of small dimensions, and in the peripheral (muscular) portion of the septum. In fracture of one or several ribs, resulting from a fall, or from the violent impact of a comparatively soft body, the skin may not be penetrated, or may only be excoriated, while the extremities of the bones, being violently thrust back, rupture the muscular zone of the diaphragm at some point, producing a rent through which one of the abdominal organs may enter the thorax. As a rule, hernia soon follows the rupture. It may, however, be postponed to a later period, when the borders of the wound have to some extent cicatrised,—the rent, however, remaining patent. Passage of abdominal organs into the thorax through one of the normal openings in the diaphragm is somewhat rare—it could scarcely occur except after dilatation of the œsophageal foramen. Congenital hernia need only be mentioned—it is still rarer than the preceding. In this case the opening in the diaphragm results from arrest in development.

In these various forms of diaphragmatic hernia, intestine and epiploon are the structures oftenest found in the thorax. A narrow slit is sufficient to allow of their passage. Displacement of the stomach and spleen, of the small colon, of a part of the liver, or of one of the flexures of the large colon, is less common, and only occur when the opening is of very large dimensions, as in our case, in which the stomach, spleen, the greater part of the epiploon, a long loop of small intestine, and a loop of the small colon had entered the chest. However small the diaphragmatic rent, several organs may pass through it. The position they assume varies : for instance, a loop of small intestine and a portion of epiploon may become lodged between the two pulmonary lobes ; considerable masses of the same organs, or of

the small colon, may appear on the floor of the thorax in either of the pleuritic cavities, —oftenest, however, in both, the resistance of the posterior mediastinum being very rapidly overcome.

Whatever the variety of hernia, a hernial sac is never seen; the displaced organs are directly in contact with the pleura, and in herniæ of long standing adhesions usually occur between the organs and the costal, pulmonary, or mediastinal pleura. The pleural and peritoneal sacs may contain a certain quantity of serosity, but abundant exudate is rare, save after complications due to engorgement or strangulation.

The dimensions and shape of the diaphragmatic opening vary greatly. In recent hernia the margins are red, ecchymosed, and inflamed; in those of long standing thickened, more or less fibrous, and less vascular.

The gravity and character of the symptoms depend greatly on whether the condition is recent or of old standing, and on the volume of the organs which have entered the thorax.

Recent large herniæ produce violent colic. The animal then exhibits an anxious look, the eyes are widely opened, the nostrils extremely dilated; the respiration is markedly difficult, irregular, and jerky. When the volume of the hernia is small the symptoms are much less alarming and significant, consisting chiefly in depression, failure of appetite, and slight colic. The breathing shows little change, though as a rule it is short, and expiration is double.

Large chronic herniæ are accompanied by irregularity of the pulse. During work the animals soon become exhausted and "blow." It has been noticed that animals with unilateral herniæ always lie down on the same side as the hernia. If the herniated parts are of small size there may be no readily appreciable symptoms so long as the digested material and the blood circulate freely, and the animal may continue to do ordinary work for a long time without showing serious disturbance. A number of cases show this. Engorgement and strangulation, however, readily occur in such concealed herniæ, because the diaphragmatic opening is almost always of small dimensions. Complications of this kind are possible in all old-standing cases, and are announced by the same symptoms as obstruction ("stoppage") of the bowel.

The first series of symptoms produced by diaphragmatic hernia may be summed up as follows:—colic, great anxiety, dyspnœa, irregularity, jerkiness, and doubling of the expiratory movement.

When hernia is suspected, auscultation and percussion greatly

assist diagnosis, provided a considerable portion of the intestine or stomach has passed into the chest cavity. By applying the ear to the lower portions of the chest borborygmus and liquid sounds may both be very clearly heard; sometimes they are so strong as to give the impression of proceeding from portions of the intestine close to the thoracic wall, or directly under the region auscultated. I should remind you that similar but duller and more distant abdominal sounds may be heard during acute affections of the chest, when pleuritic effusion or pulmonary hepatisation exists.

Over the remainder of the chest one usually notes an increased vesicular murmur, and sometimes, towards the middle or lower third, a slight tubal sound.

Percussion of the lower part of the thorax reveals a zone of semi-dulness, with or without a tympanitic sound. In the upper parts resonance is normal. In recent or complicated hernia percussion may produce pain, indicated by groaning, or by the animal flinching from the operator.

When the indications furnished by auscultation and percussion are not sufficiently characteristic to assure the diagnosis, you have in exploratory puncture a last means of settling the question—I should say, which *may* settle the question,—for when the trocar or needle fails to bring away fluid from the stomach or intestine, it is sometimes because the instrument has not entered the viscus, despite the latter being displaced; while should the hernia consist of epiploon or spleen the result is necessarily negative.

Although diagnosis is possible, you see that in cases it is extremely difficult, and should be announced with the greatest reserve. In our patient the borborygmus and "glou-glou" sound extended far in advance, and were unmistakable; the puncture, which I suggested making, would have dissipated any final doubt. On passing the trocar we should have seen issue a little greyish liquid, mixed with fragments of semi-digested material, which had passed into the two pleural cavities from the rupture in the stomach.

The prognosis is in the highest degree grave. Large herniæ kill in some days, often even in a few hours; sometimes even more rapidly. Death may result almost instantaneously. When the accident occurs during work the animal becomes greatly depressed, groans, reels about, falls to the ground, and dies. The greater number of herniæ compatible with life sooner or later become complicated—with fatal results usually through strangulation and gangrene of the herniated organs, some-

times through rupture of the intestine or stomach, as in the case we have seen. Prognosis is rendered still graver by the uselessness of treatment.

In few conditions is there such a poverty of treatment. The methods suggested are either ineffective, dangerous, or impracticable. Let us shortly consider them.

The hernia is diagnosed, and is recent. It has existed for several days, or a day, or for only a few hours. What are we to do? Some authors recommend the treatment usual in colic, particularly bleeding. It is better to leave the animal quiet, to calm pain by morphine or chloral, and to give liquid nourishment—gruel, mashes, or milk. Provided the herniated mass is not too large, and the dimensions and shape of the rupture do not favour strangulation by engorgement, the animal may, after the subsidence of inflammatory symptoms, become capable of light steady work. Many reported cases show this.

When strangulation has occurred, death can only be prevented by surgical intervention, consisting in returning the herniated organs to the abdominal cavity. Bouley proposed this method. As, he says, in such cases death is certain, why not try the only possible method of avoiding it? This consists in introducing the hand into the abdomen through the left flank, and by gently pulling on the displaced viscera effecting reduction. Such interference, however, would be only palliative. The rent in the diaphragm remaining open, the hernia might at any moment recur with fatal consequences. As to radical cure, *i.e.* reduction of the hernia and closure of the diaphragmatic wound, it has hitherto been regarded as impracticable in large animals.

IX.—BLENNORRHŒA IN THE DOG.

In dogs brought to the clinique, and in those treated for varying diseases in our infirmary, you have often noticed a discharge from the prepuce which at first sight seems to present a distinct analogy with the discharge of blennorrhœa in man. Among the twenty-five dogs at this moment in my portion of the hospital eight are affected, and at all times of the year you will find a somewhat similar proportion. The condition, therefore, is very common. It will form the subject of my lecture to-day.

This disease has been termed blennorrhœa and gonorrhœa. The first title, under which Rénault mentions it in the *Recueil* of 1834, is the more appropriate, because it does not in any way prejudge the nature of the affection. That of gonorrhœa has the disadvantage of suggesting an analogy between this discharge and that of the same named condition in man. The term "échauffement" is wrong, for the discharge may appear in animals of very phlegmatic temperament, without having been produced by violent sexual excitement or by repeated sexual intercourse.

Almost always localised in the mucous membrane lining the prepuce and covering the base of the penis, the common form of this affection consists in a chronic catarrh which even at the outset is very rarely accompanied by appreciable inflammatory symptoms. Some writers aver that the disease is always limited to the lining membrane of the sheath, but in point of fact that of the penis is also affected, particularly about and behind the corona glandis.

The catarrh produces a more or less abundant though usually trifling muco-purulent secretion, which exudes from the orifice of the sheath, gluing together the hairs surrounding this point. Except when the animal has just urinated, and especially in the morning, these hairs are soiled with a greenish, greyish, or yellowish-white muco-pus, viscous in character, sometimes fairly thick, sometimes serous, which, by drying, may form little crusts fixed to the base of the hairs, and covering the parts surrounding the preputial opening. The amount of

secretion may be estimated by slightly pressing with the fingers along the course of the sheath from behind forwards. The greater portion of the muco-pus contained within the cavity of the sheath is thus expelled. When protruded, the penis is seen to be covered with this muco-pus, some of which may easily be collected on the flattened end of a director.

Very rarely indeed is the mucous membrane of the urethra affected. One may carefully manipulate the whole course of the exposed portion of the penis and of its inferior border (where the urethra is situated) without causing the smallest droplet of pus to exude. Urine is easily and painlessly voided, showing that the mucous membrane of the urethra is unaffected. But although in blennorrhœa in the dog the urethra is very generally healthy, cases are occasionally seen where the process has extended to the entire surface of the penis, and to a short portion of the urethra. Methodical compression from behind forwards then causes the discharge of a little greenish muco-pus. The mucous membrane covering the penis and prepuce may be at first a little infected, especially behind the corona glandis and the *cul-de-sac ;* afterwards the hyperæmia disappears, and the membrane resumes its normal appearance,—the morbid secretion, however, persisting. In time the parts may show small granulations of lymphatic origin, scarcely exceeding a grain of millet in size. When the mucous membrane is thus changed, pressure over it is always a little painful.

There are neither general nor local complications beyond the genital organs. The disorder produces no febrile symptoms, at least at first. One simply notes that the majority of animals, when lying down, appear to suffer from an itching sensation which causes them to lick the base of the sheath.

Blennorrhœa occurs under varying circumstances, and from many different causes. Very frequent in young animals, it appears usually during distemper, and is especially common in dogs, which show exanthematous outbreaks on the belly. At all ages it may accompany eruptive disorders. It is often seen in animals suffering from acute or chronic parasitic or dyscrasic diseases of the skin. It affects even the best nourished during the course of eczematous eruptions, a fact which has caused some to regard it as due to gout. Others have referred it to repeated coitus, especially between large males and small females. For a long time it was regarded as contagious, but this has not been proved either by clinical observations or by experiment. Rénault and Delafond in vain tried to communicate the disease from dog to dog. They collected some of the muco-pus and deposited it on the mucous membrane of the prepuce or penis. They even made sure

of its penetrating by infriction or inoculation, but always with the same negative result.

I have repeatedly attempted to transmit blennorrhœa to males and females, but whether the pus was placed at the entrance of the sheath and on the penis, or in the vulvo-vaginal cavity, whether it was simply spread on the mucous membrane by rubbing, or by pressure on the preputial sheath, or lips of the vulva, the attempts always failed. Nor was I more successful when applying it to the eye or conjunctival mucous membrane. Nevertheless, and despite the fact that the condition is rare in the bitch, I did not conclude from these experimental results that it is never transmitted during the sexual act. Under favourable circumstances, at present unrecognised, the exudate covering the penis may probably become virulent and infective.

Bacteriological examination of this exudate reveals the presence of numbers of common microbes, especially isolated micrococci, streptococci, and sometimes staphylococci and various bacteria. Soiling of the preputial opening when the dog is lying down, and of the penis during the attempts at coitus made by young dogs, readily explains the diversity of germs found in the exudate.

The duration of blennorrhœa varies greatly according to the patient's manner of life and the care bestowed on it. In young pet dogs, attacked during distemper, it is generally treated and disappears in a few weeks. In neglected, dirty, and badly fed animals it may persist for months, even for years, the discharge increasing or diminishing from time to time. Though usually easy to cure when recent, it in time becomes obstinate, and can only be dealt with by steady, long-continued treatment.

Apart from this benign form of blennorrhœa, the dog occasionally suffers from acute inflammation of the mucous membrane of the prepuce and penis, which sometimes extends to the first portion of the urethra, and is accompanied by an abundant greyish-green discharge, marked itching, and pain during micturition. When lying down the subject continually licks the sheath, which is more or less hot and swollen. Left to itself this disease may become complicated with inflammation of the inguinal glands and diffuse inflammation of the prepuce. In common with Siedamgrotzky and Möller, I have seen such cases. I believe this variety of blennorrhœa and its complications are due to one of the micro-organisms found in the former condition, the virulence of which, however, has increased. In pus from an abscess of the sheath I found streptococci in short chains.

The diagnosis of blennorrhœa in the dog, whether acute or chronic, offers no difficulty. In those extremely rare cases where the terminal

portion of the urethra is affected, examination of the urine voided towards the end of the act of micturition enables the disease to be distinguished from affections of the genito-urinary organs proper. Polypi developed on the penis, or lining membrane of the prepuce, give rise to a sanguinolent discharge, and as a rule produce knobby swellings of the sheath. Even when of small size, or deeply situated, they can immediately be diagnosed by exposing the base of the penis and drawing back the sheath. I should remind you of the occurrence of traumatic blennorrhœa, caused by the accidental entry into the sheath of some foreign body like a fragment of straw, a thorn, a husk of grain, a little fragment of wood, or more rarely by a ligature, which some mischievous person or child has applied to the penis.

Local applications are used in all cases, but in some varieties of the disease constitutional treatment appropriate to the general condition of the patient is also necessary.

The sheath is cleansed and disinfected by syringing out, for some days in succession, with warm boric solution. This is retained by closing the preputial orifice with the finger, and any fragments of mucus adherent to the lining membrane are removed by gently massaging the parts for a few moments before the liquid is allowed to escape. Boric acid is afterwards replaced by a ·1 or ·05 per cent. sublimate, by 1 per cent. sulphate or chloride of zinc, or by 2 to 3 per cent. alum or tannin solution. Injections need only be made once a day, or even once every two days. If the discharge diminishes rapidly the injections should still be continued for a time, as when it disappears too soon it is apt to return; a drop of muco-pus is seen one morning at the opening of the sheath, and each succeeding day increases. The 1 or 2 per cent. solution of nitrate of silver is rarely necessary, even in old-standing cases, the 1 per cent. solution of sublimate or chloride of zinc being preferable.

In the acute form of blennorrhœa the same treatment with boric or sublimate injections is indicated. In addition, a moist antiseptic compress is applied to the sheath, and retained in position with a bandage.

For distemper or other complications young dogs often require internal medication. According to their age, temperament, and bodily condition, adults are treated with alkalies, arsenical preparations, iodide of potassium, or iodide of iron.

X.—AMPUTATION OF THE PENIS IN THE HORSE.

Some days ago a horse was sent here, on which I at once performed ablation of the penis. I take advantage of this case to recapitulate the particulars of operation, to examine the various available methods of performing it, and to indicate that which I prefer.

As a general rule, grave disorders of the penis are distinctly rare in the horse. We see little else but tumours and paralysis, still wrongly described under the old name of paraphimosis.

Epithelial tumours—the cancroids—almost always spring from the lower portion of the penis, from its anterior surface, or from the corona glandis. They commence as indurated nodules, which more or less rapidly extend in area and depth, ulcerate, and discharge a greyish pus streaked with blood. Sometimes the ulcer spreads and perforates the glans, whilst the penis gradually becomes indurated; sometimes the process is of a markedly hypertrophic character. Exuberant bleeding granulations mask the ulcer, suppuration is abundant, hæmorrhage occurs from time to time, and staling may become difficult. The lower portion of the penis grows dense, hard, and painful, forming in advance of the sheath an irregular mass, which may attain the size of a child's head.

Sarcomata are much rarer than epitheliomata. In the few published cases the tumour developed towards the base of the sheath, and extended to the penis.

Apart from these malignant tumours I should draw attention to verrucous new growths, which also develop on the free extremity of the penis, sometimes become of large size, compress the urethra, and cause difficulty in staling, or even retention of urine. These papillomata have special characteristics by which they may be distinguished from epitheliomata and sarcomata. They are usually multiple, firm, hard, whitish, and of regular consistency throughout. They do not invade the subtegumental tissues, and permanently retain their early characteristics without becoming ulcerated. When very numerous they may become confluent, and, by the enormous development of their connective-tissue

basis, form fibrous tumours of considerable size. The transformation of papillomata into cancroids and invading new growths is admitted by some authors, and seems established by several good recorded cases. They can, however, usually be successfully excised, provided they are not very numerous, or when in difficult positions their excision is not likely to be followed by interference with micturition.

Paralysis of the penis may result from violent local contusions, or from injury to the perinæum. Cases occur where the history quite fails to explain the onset of the condition, and paralysis has several times been seen to occur suddenly in worn-out horses. It is oftenest of secondary character, resulting from certain infectious diseases, chief among which are contagious pneumonia and influenza. Sometimes it seems to have followed simple attacks of colic.

There is no paraphimosis, for the base of the penis is in no way strangulated by the sheath. Furthermore the persistence of local sensation, and the active movements still noted in certain cases, show that paralysis seldom becomes complete.

Anatomical and pathological researches undertaken for the purpose of clearing up the nature of this condition have, until now, only revealed accessory lesions in the corpus cavernosum, subtegumental* connective tissue, and upper venous trunks. The corpus cavernosum shows considerable thickening of the fibrous septa bounding the alveoli through which the blood passes from the arterial ramifications into the vein. This change is especially marked in the lower portion of the penis; it results from blood stasis. Free serous infiltration into the subcutaneous connective tissue is soon followed by induration, the parts becoming firm, lardaceous, and difficult to cut. The chief veins traversing this tissue are obliterated by old, hard, stratified clots. These lesions still leave the pathology of the condition obscure. It may result from disturbance due to extravasations of blood following violence, or to hæmorrhage, or to phlebitis occurring during some infectious disease, but very generally—like the majority of other local paralyses resulting from infection (and notably from contagious pleuro-pneumonia)—it is of toxic character, due to a lesion of the medulla, or of the nerves of the penis.

Whatever its nature and cause, paralysis of the penis, once produced, is marked by objective symptoms, which usually become aggravated in time. The penis appears more or less pendulous, increases

* The integument covering the penis is intermediate in texture between skin and mucous membrane. To avoid the inconvenience of repeating "integument," etc., at frequent intervals, I have taken the liberty of describing it as skin.—Jno. A. W. D.

in size, and becomes covered with circular ridges and depressions, which either extend to the whole organ or only to a part. Infiltration of the subcutaneous connective tissue slowly advances. This layer and the skin undergo a hardening process, the folds disappear, and in time the penis may become five to ten times larger than normal. It then appears as a heavy cylindrical mass which swings about during movement; its upper part is covered by the exposed and distended skin of the sheath, between which and the scrotum there is no distinct line of delimitation. When animals are kept in this condition the penis is exposed to continual irritation, in consequence of which, and also of trophic disturbance, the skin ulcerates, or patches become gangrenous, particularly about the lower parts. In one case you saw on the glans penis an ulcer as large as a two-shilling piece, produced by mortification of a fragment of skin; the walls of this ulcer were covered with old-standing indolent granulations.

In some cases paralysis of the penis becomes cured naturally; infiltration of the tissues gradually diminishes, and finally disappears; but much more frequently it persists even when rationally treated. The chief methods resorted to consist in superficial scarification, or light needle firing, douches, stimulant applications, repeated compression with a rubber bandage, and electricity. The most used are scarification, firing, and cold water treatment. Ten to fifteen narrow perforations are made with the bistoury or cautery around the swollen mass. If necessary, hæmorrhage is arrested by cold applications; on the following days three or four spray douches are given, lasting for five to ten minutes. In a few instances you have seen these methods succeed, but in the greater number they are disappointing.

Failing improvement, the animals may be worked by protecting the penis with a suspensory bandage or a leather sheath fixed to the breeching, and kept in position by one or more straps passed over the lumbar region; but by rubbing, the sheath often irritates the penis and favours the production, and afterwards the extension, of injuries like those of which I have just been speaking.

Where paralysis is of old standing, or malignant tumours exist, it is necessary to amputate the penis.

In the case of new growths excision, to give lasting results, must be performed through a healthy portion of the penis, a little above the upper margin of the tumour. When operating for paralysis, the penis is cut through between the middle and upper thirds.

The different operative methods are as follows:

Amputation by ligature is more than a century old. Huzard used it

with success in a horse with enormous papillomata of the glans penis. He introduced into the urethra a metallic tube, perforated near its free extremity with two holes, through which tapes could be passed and tied over the loins, fixing the tube in position. Towards the centre of the penis he applied a loop of waxed cord, which was gradually drawn tight until, about the eighth day, the lower portion of the penis became detached. The process was hastened by a few strokes of the bistoury.

The advantages offered by elastic cords render them preferable to the old forms of ligature. A tube or solid cord, of size proportionate to that of the penis, is chosen. A metallic sound having been introduced into the urethra, one end of the cord is grasped by an assistant and tightly stretched, in which condition it is passed three or four times around the penis at the point to be divided, the crossing of the two ends being united with a tightly tied piece of string. The ligature continues to contract until the tissues are completely divided. If at first well applied, it requires no supervision. The cord gradually cuts the tissues, closing and obliterating the vessels. There is no hæmorrhage, and suppuration is trifling. In a case related by Labat division was complete in eleven days; in a horse operated on in my clinique in 1889 it occurred on the ninth day.

Whatever the nature of the material employed, section proceeds very slowly. For this reason more rapid though still bloodless methods have been recommended.

Direct amputation has often been performed with a sharp-edged firing iron at a white heat. The operation is facilitated by introducing into the urethra a metallic sound. The upper and lower parts of the penis are covered with wet cloths, leaving the operation area exposed. An assistant grasps the free extremity of the penis, exercising moderate traction. A circular line is first traced at the point where section has to be performed, and the tissues are gradually cut through until section is complete. A series of irons heated to the proper temperature are generally necessary. M. Nocard has used the galvanic loop. With this instrument operation is complete in about ten minutes. Some practitioners prefer the écraseur; by cutting sufficiently slowly the loss of blood is trifling. The corpus cavernosum, however, offers great resistance to the chain, and sometimes renders it necessary to finally resort to the knife. In many cases the chain has broken, and the operator been compelled to use the ligature. M. Trasbot recommended introducing a director into the urethra, and using a small écraseur, the loop of which is passed round the penis, and shortened daily by means of a special catch engaging with the chain.

Simple excision with the bistoury is rapid but dangerous. Abundant

hæmorrhage may occur, even when the principal vessels are ligatured or closed by forceps. Barthélémy used this method in a horse with paralysis of the penis following influenza. He confined himself to amputation pure and simple, without taking any hæmostatic precautions, without tying the arteries or cauterising the stump. During the following days a considerable discharge of blood occurred when the animal staled. In all a large quantity was lost, "fifty pounds," it was said, but nevertheless the horse was able to return to work on the tenth day.

Any of the methods of operation just passed in review may involve a grave complication, which usually appears during the third month after recovery. I refer to contraction of the lower part of the urethra. Contraction of the cicatricial tissue developed in the stump first reduces and then more or less completely closes the urethral orifice. This complication is especially to be feared when the penis is of large size at the point where amputation is practised, *i. e.* in cases of paralysis. As soon as this attains a certain degree, emission of urine becomes difficult; it escapes in a fine intermittent jet, and ends by being expelled drop by drop. Colicky symptoms then appear, and if relief is not afforded the animal may die of rupture of the bladder. The simplest method of remedying this condition is to introduce into the urethral opening the points of a pair of dressing forceps, or of strong artery forceps, and while opening the jaws to steadily withdraw the instrument. The cicatricial tissue is thus broken down, and the orifice for the time being rendered patent; but contraction soon recurs, and with it the same difficulty in micturition. A new operation becomes necessary, in consequence of which the walls of the urethra afterwards become indurated for a greater distance; finally the operation becomes insufficient. Perinæal urethrotomy must then be performed, or the animal slaughtered.

Contraction of the urethra may be avoided by one of the two following methods.

The first consists in cutting through with the bistoury or thermocautery all the tissues of the penis except the urethra, which, after having been carefully dissected out, is divided about three quarters of an inch nearer the free end. This kind of artificial urethral tube is afterwards divided vertically and transversely, so as to form four flaps, each of which is fixed to the amputated surface by means of a suture. In the other method, derived from human surgery, where it was first practised by Richet and Ricord, and afterwards skilfully modified by M. Guyon, a reversed V-shaped incision is made immediately above

the line of amputation, and on the lower surface of the penis, the skin being first divided, then the subjacent tissues, the suspensory ligaments, corpora cavernosa, and erectile tissue; the urethra is next cut through transversely, opposite the base of the V, its inferior surface dissected free from all the exposed tissues, the edges of which are afterwards sutured to those of the cutaneous wound; lastly, the penis is cut through opposite the point where the urethra was divided, and the chief vessels closed by means of ligatures or forceps. Or, again, a preferable method so far as checking hæmorrhage is concerned, consists in applying an elastic ligature opposite the base of the wound, and amputating the penis an inch or so below.

At the present time I employ this latter method exclusively. The procedure is as follows:

The animal having been cast on the left side, the right hind limb

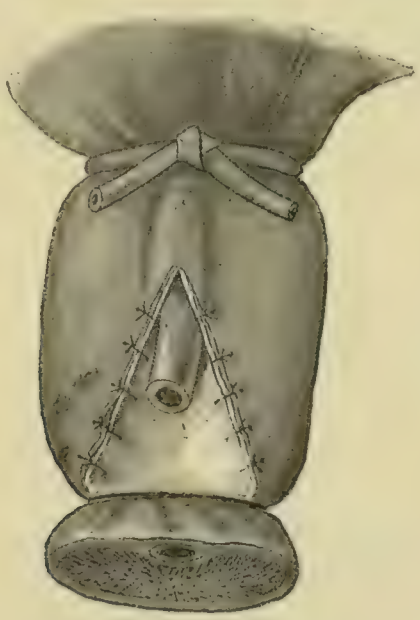

Fig. 7.—Amputation of the penis.

is lifted, carried forward, and fixed to the corresponding forearm, as in castration; the penis is disinfected, together with the posterior abdominal and scrotal regions.

Having introduced a catheter into the urethra for a distance of ten to twelve inches, an assistant covers the free portion of the penis with a cloth, and draws it gently forwards. Another assistant, placed behind the patient, draws the skin covering the base of the penis towards the perinæum. A ligature is then applied to the base of the penis.

A little above the point where I intend to amputate I trace on the inferior surface of the organ two lines, starting from above the urethra and diverging towards their free ends (an inverted V in fact), the extremities being about $1\frac{1}{4}$ to $1\frac{1}{2}$ inches apart. The base of these

incisions is united by a transverse incision, and the triangle of skin thus delimited is removed. I then excise the subjacent tissues, layer by layer, over the space covered by this wound until the urethra is exposed. This is opened at the lower margin of the wound by a transverse section. I then remove the catheter, and pass a grooved director into the exposed end of the divided urethra, the groove being directed towards the lower surface of the tube, and with the bistoury I divide the urethra along its middle line throughout the entire length of the part exposed. I then divide it transversely, and afterwards unite each flap of the mucous membrane of the urethra to the corresponding flap of the skin of the penis by silk sutures I complete the operation by applying, just at the base of the wound, four or five turns of a tightly stretched rubber cord. The ends of the cord are fastened together, and the penis divided an inch or so below with a single cut.

For several years before adopting the above method of preparing the urethral orifice I was in the habit of dividing the penis with a bistoury, and closing the principal arteries by ligatures, or by applying forceps. Abundant attacks of hæmorrhage used then to occur during several days, under the influence of the semi-erections which marked the moment of staling.

With the method referred to a mass of dead tissue remains for several days adherent to the end of the penis. Any risk of infection is prevented by antiseptic irrigations. The dead mass and ligature fall away between the sixth and tenth days. The stump is then usually much tumefied, but the swelling and œdema rapidly diminish. The wound suppurates little. A layer of granulations soon covers it, becomes hard, and contracts, gradually drawing the skin over the stump until towards the end of the third month; the cicatrix is comparatively small. As for the muco-cutaneous wound, when the sutures hold, and the mucous membrane does not cut through, the apposed lips rapidly unite. Most frequently, however, the mucous membrane cuts through at one or more points and becomes separated from the skin; vegetations occur on the exposed tissues, often becoming so abundant as partially to obstruct the meatus. There is, however, no cause for alarm. Excessive granulation soon ceases, the parts heal; like the wound on the extremity of the penis, cicatricial contraction results in drawing the mucous membrane towards the skin, and the urethral opening resumes and permanently preserves the shape given to it by the operator. In both cases the final result is the same; when the surgeon has done his part well, patency of the urethral opening is ensured. As soon as inflammatory symptoms disappear, the animal stales with the same ease as any other horse.

Of five cases operated on in my clinique, during a period of two years, not one has shown after-contraction; and in those treated between 1890 and 1895 the results—except for hæmorrhage—have been not less satisfactory.

Should you have to remove the penis in the horse, do not hesitate to adopt the operation you have seen me perform; though it demands a little more time and care than other methods, its superiority is beyond question.

XI.—RADIAL PARALYSIS IN THE HORSE.

To-day I intend to speak of the cases of radial paralysis we have treated during the course of the present session, and to show you that this paralysis assumes various clinical appearances which it is important you should recognise if you wish to avoid awkward mistakes.

Our last patient affected with radial paralysis is still in the clinique. It is a nine-year-old Percheron horse, with only one blemish, viz. a moderate-sized bog-spavin. You have, I am sure, watched it attentively, for its history is extremely interesting. When sent to us one evening last week it was on the road to the slaughterhouse. An empiric, practising in the department of the Seine and Oise, had the day before fired it in lines on the hock. The horse had thrown itself down violently, and on rising was no longer able to place weight on the off fore-limb. The quack declared the animal had fractured a phalanx, and was incurable. The owner thereupon sold it to a butcher in Paris for the sum of 100 francs, reserving to himself, however, the right to send it here for examination, so that the question as to its incurability might be finally decided.

The animal walked out of the ambulance without much difficulty. The foot of the so-called fractured limb was brought to the ground resting on the toe, and the flexion of the knee, fetlock, and elbow when at rest, as well as the excessive flexion of the last joint when walking, immediately suggested to me that the animal was suffering from radial paralysis. The phalangeal region, like all the other parts of the limb, showed no sign whatever of fracture. I was therefore able to reassure the owner, and the sale was broken off. We placed the animal in slings. Treatment consisted in simple massage of the shoulder, arm, and forearm, especially of the extensors of the forearm and metacarpus. At the end of forty-eight hours improvement was very manifest. At the present time—scarcely a week after the accident—cure is complete, so complete that there is not the slightest irregularity in movement, and it would be impossible for a stranger to say that the animal had suffered from paralysis.

In my portion of the hospital you have seen three other horses affected with this condition.

At the commencement of last March, a seven-year-old mare with paralysis of the left radial nerve, of unknown origin, was left for treatment. Having suffered, two months before, from pneumonia, this mare had returned to work without showing any after effects. One morning she was found standing on three legs, quite unable to place weight on the near fore-leg. The coachman, who had driven her the day before, declared that she had neither slipped nor fallen.

When at rest the peculiar position of the near fore-limb was striking. The joints were flexed, the extensor muscles of the forearm sunk in, the elbow dropped, and the angle of the shoulder-joint straightened. In consequence of the fetlock being flexed, only the toe of the foot rested on the ground. During movement these symptoms became more marked; when attempts were made to place weight on the limb the leg collapsed, the point of the elbow descended to an excessive degree. The fetlock was markedly flexed, and almost touched the ground. Sensation was preserved in all parts. The paralysis especially affected the extensors of the forearm, canon-bone, and phalanges. The case was one of radial paralysis, caused, without doubt, by a slip in the stable.

The muscles supplied by the radial were blistered, and two drachms of iodide of potash given daily in the food. During the first week there was not the least improvement. At the commencement of the third week a further blister was applied. Although walking was still very painful, the patient was exercised night and morning. On the first occasion it had great difficulty in advancing, but each day the distance was increased, and distinct improvement soon occurred. In a week remarkable progress had been made. The animal still went lame, but the limb was hardly flexed at the moment when weight was placed on it. Cure was complete in a month.

In November, 1897, we treated a fifteen-year-old mare affected with radial paralysis, which had appeared immediately after a fall. While drawing a cart loaded with a cow the mare stumbled and fell forwards. On being unharnessed and lifted she had great difficulty in placing any weight on the off fore-limb. As the accident happened close to the School, the injured animal was brought in.

The off fore-limb was rested on the toe, the fetlock and knee were flexed, the scapulo-humeral angle was excessively open, and the elbow dropped. Inside the upper part of the forearm was a slightly painful swelling, the size of a man's fist, which showed no fluctuation or crepitation such as is usual when blood is extravasated. The muscles

attached to the olecranon showed occasional slight trembling movements. Sensation was nowhere diminished. The temperature and chief functions were normal.

The mare was placed in slings. Several times per day the extensor muscles of the paralysed limb were massaged; $2\frac{1}{2}$ drachms of iodide of potash and $4\frac{1}{2}$ ounces of sulphate of soda were given daily. On the first three days the swelling of the forearm remained stationary. Next day the animal was depressed, hung back from the manger, and threw its whole weight on the slings. The elbow region was greatly swollen, hard, and only slightly sensitive to pressure; the swelling extended over the muscles of the forearm. The appetite was good, and temperature normal.

On the fifth and sixth days the swelling of the upper part of the forearm increased in prominence and extent. On palpation it seemed as though caused by liquid extravasated between the muscular layers. At the end of forty-eight hours it began to diminish, but functional disturbance remained almost as marked as on the first day. During the second week the general condition gradually improved. A daily dose of 2 ounces of bicarbonate of soda was added to the draught previously given. On the fifteenth day the animal was taken out of slings and left loose in its box; it then began to place weight on the affected limb. From this time onwards improvement was rapid, the limb soon being extended with more certainty and freedom. At the commencement of the fourth week the last symptoms had disappeared, and the animal was returned home. At the same time as the preceding patient there was in hospital a horse, in which paralysis of the right radial nerve had occurred during operation on the foot. The animal had been cast on the right side, and the off fore-leg drawn backwards and fastened to the corresponding hock. Being very strong the animal had struggled violently. On rising, it was unable to bear weight on the off fore-leg. The upper parts of the limb were blistered. As at the end of a few days no improvement had occurred, the horse was sent to the School.

At rest the injured limb was half flexed, the toe of the foot alone touching the ground. The scapulo-humeral angle was very open, the shoulder dropped, and the point of the elbow depressed. The skin covering the shoulder, arm, and forearm was denuded of hair, swollen, discharging and inflamed, in consequence of the blisters which had been applied. Sensation was preserved throughout the limb. When walking, the leg was moved forward with difficulty, and collapsed when the animal tried to place weight on it.

The horse was placed in slings, and, to hasten healing of the skin

wound due to the blister, carbolic lotion was applied to the scapulo-humeral and antibrachial regions. Four drachms of iodide of potassium were given daily. The wound on the foot was covered with a surgical wool dressing; it healed rapidly.

For a week the paralysis did not diminish in the smallest degree. The horse was exercised for a short time every day, and the parts massaged. During the second week no improvement was recorded.

The slings were then removed, the iodide of potassium was discontinued, and the animal was exercised for twenty minutes night and morning. Movement was particularly painful at first, and the limb could hardly be extended. Improvement did not commence until after a month. The patient then began to walk more willingly than before, the paralysed limb at times being distinctly extended. The muscles having commenced to waste to a marked degree, 10 c.c. of a one per cent. solution of sulphate of veratrin were injected under the skin, and the application repeated a week later. For a fortnight more there was little improvement; afterwards the animal recovered with fair rapidity. As time passed, more and more weight was placed on the limb, and during movement the parts were freely extended. The last symptoms did not disappear until the commencement of the third month.

Being almost entirely confined to the horse, and rare in other animals, radial paralysis was long mistaken for articular, bony, or muscular disease of the shoulder and arm. Continental authorities have erroneously attributed to Günther the merit of having in 1866 first exactly described it in his 'Myologie.' Goubaux, in his "Mémoires sur les Paralysies locales," which appeared in the *Recueil de Médecine Vétérinaire*, just half a century ago set forth the character of complete and of incomplete paralysis of the posterior humeral nerve. Since that time a large number of cases have been recorded.

In the fore-limb, movements of extension are specially under the control of the radial. It supplies the muscles attached to the olecranon and the anterior antibrachial muscles, the five extensor muscles of the forearm, the anterior extensor of the metacarpus, both extensors of the phalanges, and by a branch which passes in a backward direction the external flexor muscle of the metacarpus. On account of its position, course, and relations, the radial is exposed to compression and to mechanical violence; it is therefore much more frequently the seat of injury than the other nerves of the fore-limb. Double radial paralysis of central origin is said to have occurred, but almost all the practitioner is called on to treat are peripheral unilateral paralyses.

The ætiology is complex, but mechanical injury is by far the com-

monest cause of this paralysis. Bruises about the shoulder or arm, kicks, blows from the carriage pole, collisions against the jambs of doors, slips, and falls may all produce it. Prolonged compression resulting from the animal lying in an awkward or enforced position is, however, much the most frequent cause. Radial paralysis is often a sequence of casting, when the horse has been kept down for a long time with its legs crossed, or in the ordinary position, and especially when, under such circumstances, it has struggled violently. As a rule, though not always, the lower limb is that affected. Notwithstanding the assertion of Goubaux, and several other authors, the upper limb may be the seat of injury. I myself have seen one case. In operating on a fore-limb, either the diseased limb itself or that of the opposite side, which before casting was perfectly normal, may become affected.

Several cases of radial paralysis occurring during work, or in the stable, and quite apart from mechanical injury, have been recorded. The radial may certainly become paralysed in consequence of excessive contraction of the muscles which it supplies, but in cases of this kind either the nerve itself is injured, the paralysis is due to inflammation of muscle, or to polymyositis (inflammation of several muscles) consequent on excessive work.

Paralysis may occur in the stable either in consequence of slipping, of a struggle when rising, or of some peculiar position in which the animal is accustomed to lie. Rheumatic paralysis, or paralysis *a frigore*, and that of infectious or toxic origin, are rare.

The co-existence of radial paralysis and fracture of the first rib—a fracture which may result from falls or slips—has been demonstrated in many *post-mortems*. Hunting, relying on several cases in which fracture of the first rib had been detected, expressed the opinion that radial paralysis was probably always a consequence of such injury. This conjecture, however, is disproved by a study of the pathological anatomy of the condition. In most cases *post-mortem* examination of animals suffering from the disease fails to demonstrate the existence of fracture of the rib. The converse, however, is true, viz. that fracture of the upper part of the first rib is usually accompanied by radial paralysis—a result due to the proximity of the radial nerve to the point of fracture.

Radial Paralysis generally produces sufficient functional disturbance to permit of diagnosis, but the clinical picture is far from clearly defined. Sometimes the symptoms are very acute and alarming, leading both skilled and unskilled persons to suspect some extremely grave condition like fracture, as in the case we have just seen; sometimes they are obscure, their significance only becoming clear on careful examination.

These cases may be divided into three groups, viz. Complete, Incomplete, and Partial Paralysis.

In Complete Paralysis the joints of the affected limb, with the exception of the shoulder, are usually flexed when the horse is resting. In consequence of loss of power in the triceps and anterior brachial muscles, the arm is extended and straightened on the shoulder, the scapulo-humeral angle is open, and the elbow depressed. The forearm is flexed on the arm by the contraction of the coraco-radialis, while the metacarpus and plalanges are bent by the action of the posterior antibrachial muscles. The knee is carried in advance, level with, or in front of, a vertical line dropped from the point of the shoulder. The hoof is usually rested on the toe, but when advanced beyond the above-mentioned vertical line it may be placed flat on the ground, the joints then being less markedly bent. When the limb as a whole is flexed, it may be brought into normal position by thrusting back the knee with sufficient force to counteract the action of the flexor muscles.

In walking, the shoulder and arm are more or less "carried," the lame limb being moved as a whole; but as the lower portions of the limb are insufficiently extended, the stride is much shortened. The least attempt at placing weight on the leg causes all the joints to become flexed, and the shoulder and arm to suddenly drop; the animal, feeling itself falling, instantly transfers weight to the other limb. At a more rapid pace the animal goes on three legs, as though suffering from some exceedingly painful condition.

Incomplete Paralysis may either constitute a stage in recovery from complete paralysis, or an independent condition. At rest the limb is held as in the preceding form, but the entire plantar surface of the hoof more frequently comes in contact with the ground. In moving, lameness is less marked, and instead of occurring at every step may only appear at intervals, varying in length with the degree of paralysis, rapidity of movement, and smooth or rough character of the ground. The limb is slowly advanced, the stride shortened, and the hoof carried or dragged along the ground. The animal stumbles over the smallest obstacle, the limb immediately becoming flexed.

In Partial Paralysis most of the muscles supplied by the radial retain their function, and disturbance is much less marked. As a rule, the position of the limb at rest is normal. During movement it is freely extended, the stride is of ordinary length, and the joints do not collapse when weight is placed on the limb. Slight lameness is visible at a trot, the shoulder and arm being more or less markedly carried forward, without, however, rolling outwards, as in paralysis of the supra-scapular nerve.

Even in cases of complete paralysis, cutaneous sensibility is usually normal, or only slightly diminished, a fact attributed to the less susceptibility to injury of the sensory as compared with the motor fibres. This is probably an error, however, the persistence of sensation being due to collateral innervation, any deficiency being supplied by neighbouring nerves. Sometimes sensibility to pain is markedly diminished, and cases are not infrequently seen in which the anterior and external surfaces of the forearm are anæsthetic. Like loss of sensation, vasomotor disturbance is rare, though abundant perspiration, corresponding in area to that of the paralysed muscles, has been described. I have never seen coldness of the skin. Localised swelling is almost always due to violence, followed by hæmorrhage and sanguineous infiltration of the subcutaneous and muscular tissues; though it may also follow muscular rupture, hæmoglobinuria, or local strain.

The condition recognised as "radial paralysis" is not invariably of nervous origin; sometimes it follows muscular injuries. At the *post-mortem* of certain horses which had been over-driven, and showed symptoms of complete radial paralysis, Fröhner found the radial nerve intact, whilst the muscles it supplies were swollen, infiltrated, and yellowish; their fibres had lost the normal striation, and had undergone granular degeneration. In this form the paralytic symptoms are accompanied by those of acute inflammation of muscle.

The course taken by radial paralysis depends on its cause, as well as on the gravity of injury to the nerve and neighbouring tissues; but as it is impossible to detect the actual lesions, nothing precise can be said on this head. Sometimes the symptoms diminish within a few days, and the animal rapidly recovers; more frequently they persist unchanged for several weeks: improvement then occurs, and usually makes good progress. The paralysis generally persists for a month to six weeks. An important point to remember is that recovery is the common termination of simple unilateral radial paralysis. Of sixty-eight recorded cases, only two proved incurable, *i. e.* a proportion of about three per cent. In obstinate cases the atrophy of muscle which occurs at a certain stage renders prognosis somewhat graver. Exercise favours recovery, but it is important not to return animals to heavy work too soon. Relapses have often been seen, and are almost always very troublesome. I should add that this paralysis is very grave under two conditions: (1) when it is double-sided, because then the horse is obliged to remain lying for a long time; and (2) when an animal, in consequence of some severe operation on, say, the right fore-foot, has been forced to remain lying for a long time on the left side (or *vice*

versâ), and paralysis occurs from continued pressure. If, under such circumstances, the horse cannot stand on the diseased foot, it is evidently in great danger.

Diagnosis presents no difficulty except in partial paralysis. It should be remembered that in most attacks of this kind, when the horse is trotted, the point of the shoulder is jerked *forward* each time the limb comes to the ground, while lameness is marked. You will therefore not confuse this peculiar jerking movement of the point of the shoulder with deviation outwards—a symptom peculiar to paralysis of the supra-scapular nerve before the postea-spinatus muscle becomes atrophied. The symptoms of complete radial paralysis are at first sight somewhat alarming, and explain the view so often taken by owners, dealers, and quacks, that the arm or one of the phalanges is fractured. Differential diagnosis is too simple to require my speaking on it at length. Fracture of the elbow and inflammation of muscle, due to hæmoglobinuria or to over-exertion, are both clearly indicated by their respective symptoms.

As radial paralysis often follows casting, precautions should be taken against it, the animal being kept down as short a time as possible, awkward positions being avoided, and if necessary the twitch being applied to diminish struggling.

Curative treatment is similar to that of other paralyses of peripheral origin. It consists in massage of the affected parts, cold douches, local hypodermic injections of veratrine or salt solution, the induced electric current, and the administration of potassium iodide or sodium salicylate.

In complete paralysis it is often advantageous to sling the animal for a week or two. Massage and cold douches, or light blisters and exercise, are usually sufficient. As soon as the affected muscles begin to recover their contractility, improvement rapidly follows on exercise. The animal only requires to be moved for fifteen or twenty minutes night and morning, and left at liberty in a box. Electricity—and particularly the faradic current—is at present rarely employed. I have not used it in any of my cases. Salicylate of soda is only indicated when the existence of rheumatism is feared. I prescribe potassium iodide with the object of assisting reabsorption of exudate in the traumatic area, an exudate which might otherwise become organised, with serious consequences to the affected nerve.

More complex treatment has been recommended, but the above is that almost always followed.

Radial paralysis, I may remark in conclusion, tends naturally towards recovery.

XII.—THE TREATMENT OF SPAVIN.

During a previous lecture I stated that spavin, like most other exostoses of mechanical or traumatic origin, produced by violent strains during movement or by concussion, gives rise to lameness during its period of development. This is usually first treated by rest, and blisters to the internal surface of the base of the hock. In this way some cases soon become sound, but in the majority lameness either continues unchanged or returns intermittently.

Pathological anatomy affords the explanation of this persistent lameness by demonstrating the existence not only of a limited osteo-periostitis of the superficial layers of the affected bones, but of articular lesions. Veterinary surgeons have long been agreed on this point. The question at present in dispute is—Which of the morbid changes in this complex process occurs first? What is the primary lesion? Is the mischief at first confined to the points of insertion of ligaments, and must we regard the changes in the lower joints of the hock as secondary; or, does spavin originate in the depths of the articulation, and is the bony swelling which appears after a certain time, only a consequence of articular inflammation extending to the periosteum? Or, again, does inflammation of the joint occur simultaneously with that of the periosteum, and do the two develop together? Many different opinions have been enunciated.

Aronsohn has recently carried out some investigations tending to confirm those of Goubaux and Barrier, and favourable to the doctrine that spavin starts externally. According to this author, the disease commences as a periostitis, due to hyper-extension of the internal tarsal ligaments and tendon of the flexor metatarsi. The arthritis which occurs in the lower tarsal joints is regarded as always secondary.

Aronsohn's memoir appeared in 1893. He states that Eberlein, Joly, and Barrier have all carried out important investigations on the pathology of spavin. The conclusions are as follows:

According to Eberlein the first lesion of spavin consists in osteo-

porosis and rarefying ostitis, in the great majority of cases affecting the cuneiform bones and the metatarsus. This rarefying ostitis is soon succeeded by condensing arthritis. At the same time the corresponding articular cartilages become the seat of chondritis, with proliferation of cartilage cells and degeneration of the fundamental substance, resulting sooner or later in anchylosis of the joints in question. Often, though not invariably, inflammation extends to the joint, or, possibly, directly from the bone to the periosteum of the small tarsal bones, and there produces an ossifying periostitis, accompanied by exostoses on the inner surface of the lower line of bones of the hock. The lesions seen in the tissues surrounding the joint are secondary.

M. Joly considers that what is called spavin, and treated under that name, is a complex pathological process, the stages of which are as follows:—(1) Dry arthritis of the lower tarsal joints; this is spavin arthritis. (2) Anchylosis of the inflamed joints—spavin anchylosis. (3) Exostosis, localised, in consequence of the anatomical formation of the hock, at the infero-internal surface of the joint—spavin exostosis. (4) Extension of the disease to the lower tarsal joints, and invasion of the tarso-metatarsal joints and superior tarsal joints—circular spavin.

The author states that these four phases of the disease do not succeed in regular order throughout the entire extent of the hock. On the contrary, they extend by zones, gradually invading wider areas, one zone having terminated its second or third cycle when the next is only in the primary stages.

M. Barrier considers that spavin consists essentially in a dry chronic arthritis, usually leading to anchylosis and deformity. It starts in the joints at the infero-internal surface of the hock, and tends to travel from below upwards, and from within outwards.

The evolution of the morbid process which ends in spavin formation may be summarised as follows:—(1) Strain of the ligamentous structures, either at the surface or in the depths of the small tarsal joints. (2) Ostitis and osteo-periostitis, at first of a rarefying, then of a condensing character, of the osseous structures affected, or of neighbouring parts, under the influence of concussion. (3) Peripheral anchylosis, sometimes without deformity, but usually with new growths of bone, which later tend to envelop the joint. (4) Dry arthritis, ending either in central, very firm anchylosis, or in progressive osteoporotic deformation, or in eburnation of the diseased articular surfaces.

I believe that on this question of the pathology of spavin, as, for that matter, of the pathology of other affections, it is very necessary to avoid dogmatism. Because it is proved that a certain cause or process occurs, that is no sufficient reason for absolutely neglecting those whose influence is more difficult to demonstrate. The causes of spavin are certainly many. Defective conformation of the hock, injury suffered during movement, and strains of ligaments probably play important parts; while the constitutional condition of the animals and the character of the bony tissue—consequently hereditary predisposition —must not be lost sight of.

We cannot explain why or how the bones which form the lower portions of the hock, the synovial membranes interposed between them, and the ligaments which unite them, should be exempt from morbid processes which attack bones and serous and fibrous membranes; why, for instance, they should be exempt from injury by products of microbic activity. Whatever its cause, however, unless the inflammation in the periosteum, in the bones, or in the affected joints is allayed, lameness results. Another cause of lameness persisting is the mechanical disturbance, the interference with the action of the hock caused by bony growths—a disturbance which is possibly of less importance than is usually admitted, and which is certainly not constant. We sometimes see large spavins which, however, do not render horses lame. Furthermore, spavin very rarely interferes with the action of the tibio-astragalar joint.

The essential point in dealing with spavin lameness is to allay the inflammation developed in, or propagated to the lower tarsal joints, by producing anchylosis of these joints. Even when treatment follows close on the appearance of the disease, it is hopeless to attempt checking the inflammation or arresting its course. Treatment should aim at hastening the evolution of the process and the production of anchylosis. In this way the period of pain may be shortened, and without doubt the extent of the morbid changes diminished.

In old spavins, or in those which, though relatively recent, are producing lameness, and which have resisted blisters or superficial firing, what is the best treatment?

Among the methods suggested three stand pre-eminent, and usually suffice: deep penetrating firing, tenotomy of the flexor metatarsi tendon, and periosteotomy.

Firing in fine deep points is nowadays the treatment most commonly employed, and when used boldly, so that the red-hot needle penetrates the exostosis, often gives good results. Section of the inner terminal

tendon of the flexor metatarsi by the old open method has been so successful that certain operators declare it superior to firing. I usually combine these two methods, first piercing the exostosis with a finely pointed Paquelin cautery, or with the end of a medium-sized knitting-needle brought to a bright red, and afterwards making twenty, thirty, or forty similar points, extending a little beyond the area of the swelling. In large or old-standing spavins I apply the cautery twice, or sometimes three times, in each puncture. Following this I simply divide the tendon of the flexor metatarsi, or I excise a short portion.

The numerous instances I have recorded during the last few years show that this treatment removes spavin lameness in about 30 per cent. of cases. I do not believe that any other direct treatment is so efficient against osteo-arthritis of the hock. The only objection I can make to it is that it leaves a more or less apparent mark.

Penetrating firing, nowadays used by a large number of practitioners, produces much more intense immediate effects and much better results than the old superficial firing, and does not necessitate nearly so long rest. The time for operation can be shortened. Instead of covering the entire surface with closely placed points, three to six may be used, according to the size of the bony tumour; and these can be applied after placing a twitch on the upper lip, and lifting one of the fore-feet, *i. e.* without casting the animal. Fröhner, who has treated fifty-nine spavins in this way, states he had very good results last year. You see the advantages of this method: it avoids the necessity for casting the animal and saves a great deal of time, for the operation only lasts a few minutes. It is true that penetrating firing of the hock is sometimes followed by arthritis, but this complication has become exceptionally rare since the introduction of very finely pointed cauteries. It can more certainly be avoided by operating with antiseptic precautions. The hair is cut, and the skin shaven over the entire surface of the bony swelling. The field of operation is disinfected, firing performed, and the cauterised surface covered with iodoform collodion.

Periosteotomy, when practised aseptically, according to Peters' direction, has the advantage over the preceding of leaving no mark. A narrow transverse incision is made at the base of the swelling, opposite its vertical axis, and the exostosis cut into at several points, using a button-pointed bistoury with a convex cutting edge. But at present I have not sufficient personal experience of this operation to deliver an opinion concerning it. Those authors who have written on the subject vary greatly in opinion regarding it; but it has given successes and might prove useful, especially in valuable horses.

In a number of cases where the swelling is old, large, diffuse, and especially when it extends far forwards towards the bend of the hock, firing, even if repeated, and section of the terminal branch of the flexor metatarsi tendon fail, or only yield a very modified success; lameness persists or is remittent, being less marked after a certain amount of exercise than on leaving the stable, though sometimes it is equally pronounced before and after exercise: in these rebellious cases double neurotomy of the sciatic and anterior tibial nerve, a deep branch of the external popliteal sciatic, has been recommended. This treatment of obstinate spavin by neurectomy is based on the following anatomical

Fig. 8. Fig. 9.

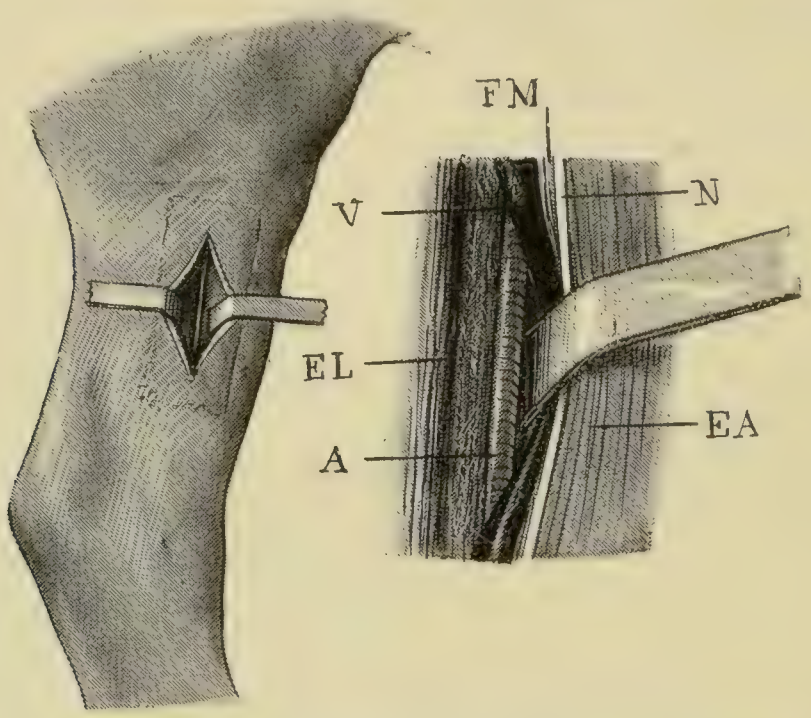

Figs. 8 and 9.—Neurotomy of the anterior tibial nerve. E A, anterior extensor of the phalanges. E L, lateral extensor. F M, muscular portion of the flexor metatarsi. N, tibial nerve. V, tibial vein. A, tibial artery. (The operation should be performed a little nearer the hock than indicated on Fig. 8.)

facts:—Opposite the point of the calcis the great sciatic nerve divides into two parts, the internal and external plantar nerves. Behind the hock-joint the external plantar nerve gives off a fairly large branch, which passes under the tendon of the deep flexor of the phalanges, and detaches several twigs, of which some ramify over the surface of the joint, whilst others penetrate into it. In front of the lower extremity of the tibia the tibial nerve gives off several branches, which enter the joint.

Neurectomy of the great sciatic is made a hand's breadth above the point of the hock. You know the technique.

In neurectomy of the tibial, the point selected is at the external surface of the lower part of the thigh, approximately at the same height as the former. The anterior tibial nerve is situated on the deep surface of the anterior extensor of the phalanges, between this muscle and the thin muscular portion of the flexor metatarsi which separates it from the tibial artery, and from its large satellite vein—vessels which lie directly on the anterior surface of the tibia, where they are surrounded by a thick layer of connective tissue.

The method is as follows :—The point of operation being prepared, the skin and subjacent aponeurosis are incised for a distance of two and a half to three inches, opposite the external margin of the anterior extensor of the phalanges. This muscle is separated from the lateral extensor, then from the muscular portion of the flexor metatarsi, on the anterior surface of which the tibial nerve is readily discovered. A fragment of this, three quarters of an inch to one and a quarter inches in length, is excised. The wound is closed by a few cutaneous sutures, with or without providing for drainage. The operation is easy. It is, however, always necessary to proceed methodically, and to take care not to injure the tibial vein, which thrusts the muscular portion of the flexor metatarsi prominently forwards as soon as the anterior extensor of the phalanges is reflected.

This double neurectomy has proved successful when all other methods had failed. Bosi reported six favourable cases, and more recently Fröhner has described others. Nevertheless it is not without danger, trophic changes in the extremities, local sloughing, and loss of the hoof sometimes occurring.

I may summarise the treatment of spavin as follows :—At first, when the disease is still latent, prolonged rest and blisters; later, when spavin is apparent, firing in deep penetrating points, and when the exostosis is large, section of the internal terminal tendon of the flexor metatarsi. Should improvement only be partial, repeat the firing; finally, if repeated firing fails, you may, after warning the owner of possible risk, perform neurectomy of the sciatics.

The heredity of certain organic conditions which favour the production of spavin suggests the only prophylactic measure applicable in our practice, viz. to avoid breeding from animals with this disease, or from those with specially defective hocks.

XIII.—THE TREATMENT OF PICKED-UP NAIL.

SINCE the commencement of the year I have several times lectured on the treatment of wounds of the lower surface of the horse's foot, and have described to you the methods of treating recent and complicated wounds in each of the parts into which this region has been conventionally divided.

To-day I return to the treatment of grave cases of picked-up nail in the middle zone, in order to study in some detail two modifications which can be made in the technique of the complete operation, and to show you the benefits resulting therefrom.

I wish to recall to your memory the conditions for which this operation is performed, viz. penetrating wounds, complicated with extensive and deep necrosis of the plantar aponeurosis, or with purulent synovitis of the navicular or small sesamoid sheath.

The complete operation for picked-up nail, as given by André and described by Bouley and Trasbot, consists of—(1) a large incision through the plantar cushion; (2) transverse section of the plantar aponeurosis opposite the posterior margin of the navicular bone, prolonged on each side as far as the retrorsal processes; (3) removal of the terminal portion of this aponeurosis; (4) scraping the lower surface of the navicular bone and that portion of the pedal bone over which is inserted the above-mentioned aponeurosis.

In 1879 M. Nocard recommended preserving the insertion of the aponeurosis into the pedal bone by making, opposite the posterior margin of the navicular bone from one lateral lacuna to the other, an incision perpendicular to the median line of the foot, and by giving to the two extremities of this incision, from the lacuna to the semilunar crest, a curved or concave form, looking forwards. Retraction of the stump of the tendon is thus avoided. As the tissue composing the plantar cushion granulates more rapidly than that of the aponeurosis, it used to be the custom to excise this part very freely, dividing it far back at the boundary between its middle and posterior thirds, or even within this, the incision taking an oblique direction from behind forwards.

Ten years ago I showed that scraping the surface of insertion of the

aponeurosis is superfluous, and that under an antiseptic dressing the fibrous tissue left covering the os pedis, far from undergoing necrosis (as had been suggested), rapidly becomes vascular and covered with granulations, like the other tissues in the wound. Even where necrosis has affected a portion of the end of the aponeurosis, you have always seen that I limited removal of the fibrous layer and scraping of the bone to that particular portion.

By thus preserving the fibrous covering of the pedal bone over the entire surface of insertion of the perforans tendon, operation is simplified—scraping being a delicate process, which endangers the interosseous ligament,—the chance of arthritis is less, and the anterior portion of the wound fills up more rapidly than after curetting the semilunar crest.

But in consequence of the obliquity with which the plantar cushion is divided, especially when the necrotic portion of the aponeurosis extends to or a little behind the posterior margin of the navicular bone, the operation wound is very large, sometimes almost alarming in size; and healing, even when uncomplicated, occupies a long time—some six to eight weeks. The majority of patients only return to work after extended rest.

Whatever the position of the necrosis or of the penetrating wound in the navicular sheath, the period of healing and consequently the required rest may be diminished by sparing, as far as possible, the plantar cushion, and reducing to a minimum the loss of substance by making the primary incision at right angles to the surface of the plantar region, or even inclined a little obliquely from in front backwards. Antiseptic treatment and plugging of the wound with gauze prevents the complications which caused older operators to excise the plantar cushion so freely. You will at once see the advantages of this method,—more rapid closure of the operative wound, and a smaller cicatrix, the tenderness of which is sometimes the only reason for lameness persisting; in a word, more rapid and complete recovery.

You have been able personally to estimate these advantages in a certain number of our cases. I may repeat to you the history of the most recent.

On the 15th March last a heavy seven-year-old cart mare entered hospital. Three weeks before she had picked up a nail about the centre of the left hind foot. The nail had penetrated perpendicularly into the internal lacuna, not far from the limit between the middle and posterior zones. A veterinary surgeon had thinned the sole around the wound, which he had laid open and disinfected, and had afterwards covered the parts with an iodoform dressing. Despite this treatment the wound became complicated. Towards the end of the second week

lameness was extremely marked, and five or six days later the patient was sent here. When seen by us the left hind foot was scarcely brought in contact with the ground, the lower part of the limb was greatly swollen, and the animal continually lifted the foot, showing signs of darting (lancinating) pain. Pus, mixed with synovia, escaped from the wound on the under surface of the foot, around which, for a distance of an inch, the exposed sensitive tissues were swollen and exuberantly granulating. The case was one of picked-up nail, complicated by suppurative inflammation of the small sesamoid (navicular) sheath, and possibly by necrosis of the plantar aponeurosis. We might have thinned the foot, laid open the sinus, and afterwards used baths and antiseptic dressings, but such treatment gave little hope of success. Operation was evidently preferable, and was arranged for the day afterwards.

The usual method was employed, with the modification, however, of which I have just spoken. After stripping the sole I divided the plantar cushion at right angles to its surface, so as to preserve the larger part. The plantar aponeurosis, being exposed, was divided transversely, a little in front of the posterior margin of the navicular bone, and dissected away, the sides, however, being spared as much as possible. The nail had touched the inner facet of the navicular, where it had produced a small wound and a patch of ostitis. I curetted the lower surface of the bone, forming a slight depression at the injured point. In the excised portion of the aponeurosis was a necrotic ring surrounding the sinus; the stump showed a greyish point, where the fibres were a little softened and possibly necrotic, but the terminal portion of the aponeurosis was healthy over its entire area of insertion, and was therefore not touched. I did not interfere with the pedal bone. Having freely irrigated the wound with lukewarm two per cent. carbolic solution, the greyish point on the end of the tendon was touched with tincture of iodine, which was also applied to the hollow formed in the navicular bone, the wound was powdered with iodoform, and afterwards plugged with gauze. To prevent discharge accumulating in the cul-de-sac behind the tendon sheath, I was careful to lift the end of the aponeurosis and pass the gauze under it. Finally I applied the surgical dressing usually employed after serious operations on the foot.

On rising the mare placed more weight on the diseased limb, and appeared in less pain than before operation. That evening the temperature rose to 39·3° C. (102·7° F.). The day after the foot was rested on the toe, and the animal suffered from lancinating pain; but it ate most of its food, the general condition was satisfactory, and the fever moderate. During the first week the condition remained prac-

tically stationary, any change, however, being towards improvement. The temperature never rose beyond 39·3° C. (102·7° F.). On the eighth day more weight was placed on the foot, and the lancinating pain had disappeared. The dressing was removed. To loosen the gauze which adhered to the deeper parts, the foot was placed in warm carbolic solution. There was only a little reddish discharge; the wound appeared very healthy and granulations were everywhere springing up, except on the navicular bone and in the stump of the perforans tendon, where preparations for granulation were seen. After thorough cleansing, the parts were again covered with a cotton-wool dressing.

On the tenth day the patient's condition was excellent; fever had ceased, and weight began to be placed on the affected limb. On the fourteenth day the dressing was renewed. The layer of gauze was moist; the wound, which contained a little pus, was entirely covered with granulations. A thin shoe was applied, with four nails, and the surgical dressing fixed in position with splints.

After the eighteenth day improvement occurred rapidly. The animal still walked lame, but placed more weight on the leg. Exercise was commenced, night and morning. A week later the wound was about three quarters healed, and the lameness scarcely noticeable at a walk. Twenty-four days after operation the mare was able to do a little work. She did not leave hospital, however, for another week. At that time lameness was scarcely perceptible when walking.

It may be said that, of course, this injury was in a hind foot, and that injuries to fore-feet are graver, and treatment would be more prolonged. But two months after this case I operated in the same way on another horse, which had picked up a nail in the off fore-foot. The case was also complicated with necrosis of the aponeurosis and with purulent synovitis. The result was as favourable as in the preceding instance, and the period of treatment not much longer. The horse, in fact, returned to work in five weeks. A little later the then existing lameness had completely disappeared.

By preserving the larger portion of the plantar cushion not only is the period of healing diminished, but the volume and area of the mass of resulting cicatricial tissue are reduced. This cicatricial tissue often remains excessively sensitive, keeping up lameness even where there is no periostosis or marked swelling about the coronet. The more you preserve the plantar cushion, the smaller will be the cicatrix and the more certain and complete the result of treatment.

On this first point, I may remark, it is not always necessary to divide the plantar cushion perpendicularly to the long axis of the foot, as you usually do in the animals provided for exercises in practical

surgery. To avoid excessive cutting, and to reduce as far as possible the extent of the wound, one may depart from the rule; and if the sinus is in one of the lateral lacunæ, far enough removed from the point of the sensitive frog, if necrosis is limited to one half of the aponeurosis, or is situated near one of its margins, you may make the transverse incision through the aponeurosis and plantar cushion more or less oblique to the long axis of the foot, and thus, while removing the whole of the necrotic patch, preserve on the opposite side the larger proportion of the healthy tissues.

By lifting the end of the aponeurosis with the flattened end of a director or any blunt object, it becomes easy to separate the cartilaginous material surrounding the navicular bone with a button-pointed knife, or a cautiously handled sharp-pointed knife. In practice, therefore, it is sometimes advisable to depart from the rules of the classical operation. Different cases require different treatment, and it is always important to preserve tissue as far as possible.

With the advent of antisepsis the surgery of the foot has become more conservative. In complicated injuries of the plantar region, in particular, we should endeavour to reduce the operative wound to the smallest dimensions.

Let us now consider the treatment of necrosis of the plantar aponeurosis, occurring close to the synovial cul-de-sacs in the flexure of the pastern. In this region necrosis is very common as a result of suppurating corns, or of foreign bodies having passed through the central zone in an oblique direction upwards and backwards. In operating for such injuries, excision of the entire eschar would expose us to the risk of opening the synovial cul-de-sacs of the pedal joint and of the great sesamoid sheath. Those of you who have been present at my operations for picked-up nail know how I proceed under such circumstances. After removing all tissue which can be taken away without injuring these synovial sacs, I form a counter-opening in the flexure of the pastern. After preparing the pastern region, shaving away the hair and disinfecting the skin, I introduce the special "sage-leaf" shaped knife at the bottom of the wound at the spot where I have been obliged to leave a necrotic or doubtful piece of tissue, and from this point push it upwards and backwards between the aponeurosis and plantar cushion (keeping close to the former) until it emerges above the bulb of the heel.* If necessary I enlarge the opening by guiding the knife along a hollow director. Then I pass a piece of gauze to act as a drain, saturate the suspected portion on the stump of the tendon with

* The procedure is precisely similar to that in passing a frog-seton.—Jno. A. W. D.

tincture of iodine, and apply a first dressing, with or or without a shoe. If the end of the perforans tendon does not granulate throughout, or the necrotic tissue fails to separate, drainage may be supplemented by antiseptic injections made through the opening in the bend of the pastern. Some months ago you were able to watch the progress of two cases thus treated. They recovered without further interference. I may briefly recapitulate the facts in connection with the first.

At the commencement of last September we received a horse which had picked up a nail in the middle zone of its off hind foot, and had already been twice operated on by the veterinary surgeon who sent it.

No weight was placed on the foot, and the animal showed evidence of frequent lancinating pain. On examining the hoof the operative wound in the plantar cushion was seen. Its deeper part formed a sinus, from which discharged a considerable quantity of greyish viscous pus. The aponeurosis was necrotic, and the tendon sheath had become transformed into a suppurating cavity.

The same day I practised the complete operation. Necrosis had extended for a long distance in the perforans tendon, and I was unable, without risking injury of the synovial cul-de-sac, to remove the entire mass of the eschar. I made a counter-opening in the bend of the pastern, irrigated the wound with an antiseptic liquid, inserted a gauze drainage-tube, and then, with the end of a director enveloped in wadding, I swabbed with tincture of iodine that portion of the tendon stump in which I had been obliged to leave a fragment of necrotic tissue. The parts were covered with a layer of iodoform, the foot enveloped in a large dressing.

On the four following days the animal showed acute pain. During the greater part of the time it remained lying down, and took little food. Fever was marked, the temperature oscillating between 39·3° and 39·9° C. (102·7° and 103·8° F.).

On the fifth day the dressing was renewed. I changed the gauze drain, again touched the necrotic portion of the tendon with tincture of iodine, and applied a new cotton-wool dressing. From the next day the condition improved. The appetite increased, the fever diminished, and the lancinating pains became less frequent. The improvement was continued on the following days. Gradually the horse began to place weight on the affected limb. The dressing was allowed to remain until the end of the second week. At that time the wound was granulating throughout almost its entire surface, only the navicular bone still showing a small dry point. The gauze being changed, a dressing and shoe were applied, and antiseptic injections made daily through the

artificial sinus. Still later the dressing was changed each week, and the amount of gauze used as a drain was diminished.

At the end of a month weight was freely placed on the limb, the sinus suppurated feebly, and drainage was stopped. From this time the horse was exercised daily. When he left hospital at the beginning of the sixth week he walked almost sound.

The second patient entered hospital a short time before the preceding left, having been like it unsuccessfully treated for some time by the colleague who finally sent it to us.

When I examined the horse it showed marked pain, and could scarcely bring the off fore-foot in contact with the ground. The internal lacuna near the heel showed a fistulous wound, from which ran a little grumous, stinking pus. The hoof was pared out, thoroughly cleansed by immersion in a sublimate bath, and enveloped in a dressing of peat wool, the first layers of which had been moistened with an antiseptic solution.

I performed the complete operation, making the incision a little larger on the near side by giving to the transverse section, through the plantar cushion and aponeurosis, an oblique direction backwards and towards the inner heel. A few suspicious points, nevertheless, remained on the stump of the tendon. I made a counter-opening in the bend of the pastern, inserted a gauze drain, and dressed the parts with tincture of iodine and iodoform.

The progress of the case was practically similar to that of the first. Fever was a little more prolonged; during the first week the temperature remained at 39·5° C. (103·1° F.). The animal had capricious appetite, placed little weight on the limb, and frequently lifted it with a jerky movement, suggesting lancinating pain. Shortly after operation an abscess developed in the plantar cushion in spite of the drainage. Nevertheless towards the fifteenth day weight was placed on the foot, and improvement was afterwards rapid. In the course of the fourth week a light shoe and a dressing, fixed in position by splints, were applied.

Some days later the animal began to stand on the foot, and exercise was commenced finally. Drainage was stopped on the thirtieth day. A week later the animal returned to walking work.

You may remember another case in which, when attempting to remove the whole of the dead part, I opened a synovial cavity—without doubt that of the large sesamoid. A quantity of synovia ran from the bottom of the wound, and I was forced to cease the operation. The

foot was dressed as in the preceding cases. The complication I had feared did not occur, but such a good fortune must not be anticipated when the synovial capsule is wounded in the neighbourhood of infected tissue, and by an infected instrument.

In conclusion I may say that, apart from all operative accidents, extensive necrosis of the plantar aponeurosis constitutes a very grave condition. From the economic standpoint treatment is not to be recommended or undertaken in more than a certain proportion of cases, and only when the animals are of value, or when it is of importance to keep them alive irrespective of questions of cost, long duration of treatment, and uncertainty of result.

XIV.—PLANTAR NEURECTOMY.

In cases of obstinate lameness you have frequently seen me perform plantar neurectomy, both above and below the fetlock, according to the seat and extent of the morbid changes we are called on to remedy. When the lesions are limited to the back part of the foot I prefer the low operation, reserving the other for cases affecting the front or sides of the entire foot, or the coronet or pastern. I wish this morning to draw your attention to the advantages and drawbacks of these operations, and incidentally to clear up a disputed point in their history.

Plantar neurectomy was first conceived and performed by Moorcroft, a professor at the Veterinary College in London. At the commencement of this century Moorcroft made his earliest experiments on section of the plantar nerves. He did not publish his results until eighteen years later. There is no reason to believe that Sewell was the inventor of this operation, but he helped to extend its use in England, and showed by numerous published cases the benefits to be derived from it. Moorcroft practised indifferently section or excision above or below the fetlock. Sewell recommended neurectomy below the fetlock, in order to leave a certain degree of sensation in the tissues of the foot. Blaine suggested high double neurotomy for ringbone. Coleman and Goodwin also studied neurectomy, and reported a certain number of observations in support of its efficacy.

Percival had given a good description of the operation in his lectures, which Narcisse Girard analysed in 1824 in the first volume of the *Recueil de Médecine Vétérinaire*. From this time the operation began to be practised in France. Its introduction was not unopposed. In the discussions concerning it many objections were made, because during the period of trial it had not only given contradictory results, but caused a considerable number of accidents. Rénault, Delafond, Leblanc, and Bouley helped to define its field of usefulness.

Neurectomy is a palliative operation. Except in rare cases it produces no curative effect; it has no direct influence on the lesions, nor on the morbid processes for which it is practised, but by destroying sensation in the regions in which these lesions and processes occur it

diminishes or entirely removes the lameness for a time, and thus allows the animals to be used. The duration of its effects is very variable. Sometimes the lameness returns in a few months, sometimes only after years. Cases occur when, for example, the morbid changes have arrived at their final stage of development, and the inflammation which caused them has ceased, in which it never returns.

From the practical standpoint, neurectomy is a valuable operation when performed with a full knowledge of the state to be treated, and when judiciously employed. Had it not done signal service it would long ago have been abandoned, because it certainly entails the possibility of serious accidents.

I need only remind you of the permanent weakness of the limb on which neurectomy has been performed, the first objection made to the operation. After neurectomy, it has been said, movement of the limb is less assured, and the animal is liable to stumble and fall. This must be conceded, but such accidents only occur in a small number of cases, even after high neurectomy. Two Army Veterinary Surgeons, MM. Jacoulet and Coméný, who kept animals on which they had operated under prolonged observation, published cases showing that as a general rule neurectomy does not render troopers unsafe to ride, nor prevent them placing full weight on the limb. In a large number of my own cases the results have been excellent. Six years ago I performed high neurectomy on the off fore-leg in an English mare, which has since done continuous saddle work, without ever showing the least hesitation in the action of the limb. From time to time I have seen a horse in which I performed low neurectomy on the near fore-leg four years ago. It recovered perfectly, has not since gone lame, and has in no way lost control over its movements.

Another, much graver drawback is the danger of inflammatory and trophic changes developing in the tissues formerly supplied by the divided nerve. These may occur soon after operation, or may be delayed, and usually end in loss of the hoof, or rupture of the flexor tendons. Though comparatively few accidents of this kind have been recorded, many have undoubtedly happened.

Sewell, who first practised high double neurectomy, had so many complications of this nature soon after operation, that he abandoned the method, and practised low neurectomy alone. Rabouille, among seven cases, had two of separation of the hoof. Renault, Beugnot, Delafosse, Delafond, and Verheyen, operating like the preceding authors above the fetlock, had similar accidents. Stanley only reports

two cases in one hundred operations, and on each occasion the complication was produced by an injury to the foot.

M. Nocard, between 1880 and 1886, performed about one thousand neurectomies without a single accident. This is practically the best recorded series. M. Comény, who often performed high double neurectomy, never saw after complications in his patients.

Benjamin and Redon give the history of a horse in which high double neurectomy was followed by periostosis of the pastern, obstinate

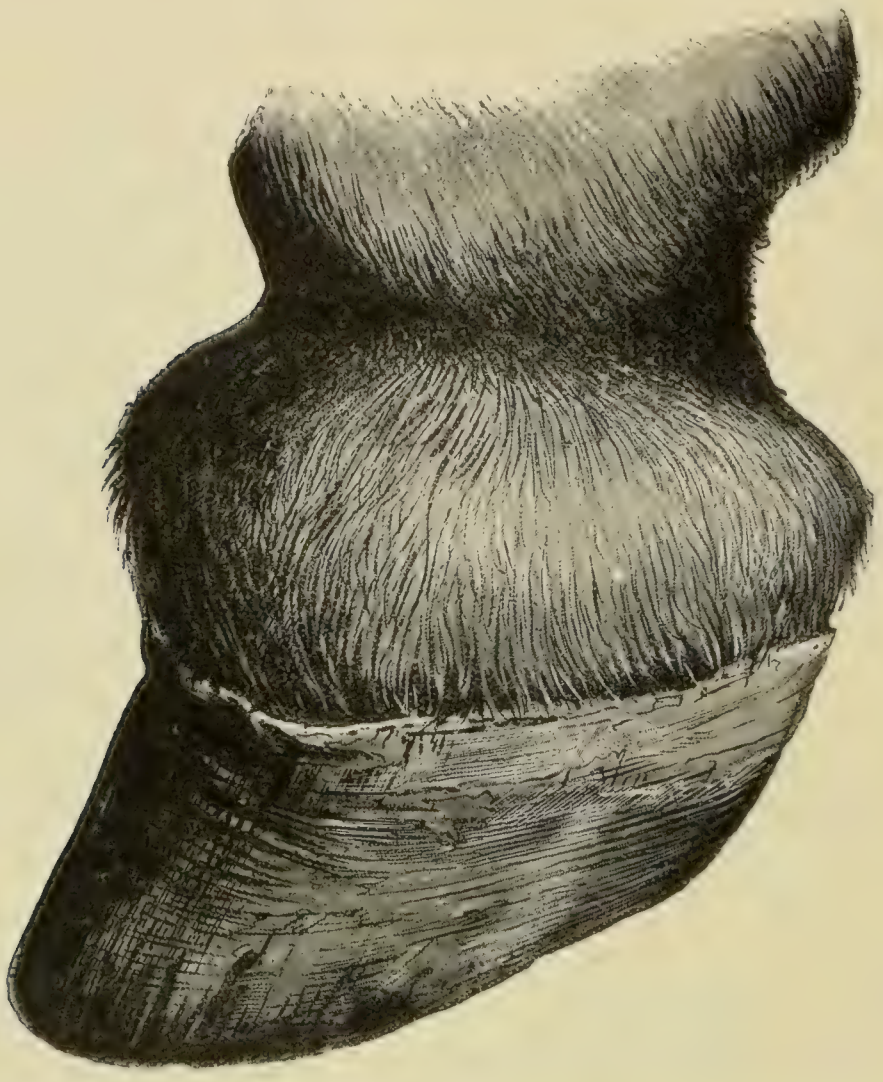

Fig. 10.—Moist gangrene of the foot after plantar neurectomy above the fetlock.

ulceration of the skin, and other changes which necessitated slaughter. In one instance M. Jacoulet saw, two months after operation, inflammation of the tissues of the phalanx, with enormous swelling and superficial ulceration of the skin. In a horse suffering from large ringbones, which had resisted firing, M. Trasbot, after unsuccessfully performing low double neurectomy, proceeded to divide the plantar nerves above the fetlock. Three days later the coronet became greatly

swollen, and the hoof partially loosened. Having to treat a horse affected with ringbones, Palat performed high neurectomy on the side of the larger bony growth, and a fortnight later on the other side. The animal returned home, and continued working regularly for more than a year. During the fifteenth month swelling of the coronet and separation of the hoof were observed ; the animal had to be slaughtered. Hendrickx reported three cases of loss of the hoof after high neurectomy. In one the accident was deferred more than four years. Delamotte and Brocheriou performed neurectomy first below and next above the fetlock, in a mare suffering from navicular disease ; but the animal then developed ringbones, which they treated by firing. Six weeks later the hoof was shed.

All these cases refer to loss of the hoof after high double neurectomy, but the same complication may result from section of one of the plantar nerves above the fetlock.

Here is an illustration made from a photograph showing the condition of the near fore-foot of a horse in which, two years before, I had divided the external plantar nerve above the fetlock. A very large ringbone existed on this side. After five weeks' rest lameness disappeared, and the animal was able to resume work.

About six months ago lameness returned, and the coronet greatly increased in size, in spite of which the horse was able to work until the commencement of the present month. As the lameness and swelling of the coronet had by that time become very marked, the animal was left in hospital for treatment.

No weight was placed on the near fore-limb, which was half flexed, and from time to time convulsively lifted, suggesting lancinating pains. The lower parts of the limb, from the middle of the forearm, were greatly swollen. The coronet showed a diffuse, hard, warm, slightly painful swelling, particularly marked on the outer side, at which point the thin upper edge of the hoof was softened and detached from the enlarged and inflamed coronary band. All the outer quarter of the hoof was separated. Along the plantar commissure the horn was softened and yellowish. The strictest examination of the foot revealed no recent injury.

Treatment was by continued irrigation, but as the separation of the wall steadily continued, and in a few days extended as far as the toe, the case was considered incurable, and the horse was slaughtered.

On dissecting the foot, the skin and subcutaneous connective tissue were found greatly thickened and indurated ; the coronary band was double its ordinary size, and along the entire external quarter the wall was separated. The posterior branch of the external plantar nerve was

atrophied. On vertical section of the hoof, the articular synovial membranes and the small sesamoid (navicular) sheath appeared inflamed, injected, and infiltrated; the synovia was scanty and reddish in colour. The navicular bone showed signs of rarefying ostitis; its lower surface was denuded of cartilage, its compact tissue was undergoing exfoliation, and its cancellous tissue was hyperæmic and friable.

Softening and rupture of the flexor tendons may always follow plantar neurectomy, but are commonest when the operation has been performed for navicular disease, appearing due in part to extension of the disease, in part to trophic changes produced by the operation. Among French authors, Renault, Beugnot, and Rabouille were the first to note this. In two cases operated on by Rabouille, rupture of the tendons ended in the fetlock and the bulbs of the heel coming in contact with the ground, the digit from the fetlock downwards lying horizontally. In both cases the tendons showed trophic changes in the phalangeal region, and the perforans was completely ruptured close to its insertion into the pedal bone. Bouley, Goubaux, MM. Jacoulet, Mollereau, and many others have seen similar cases, but, I repeat, these lesions occur where neurectomy has been performed for navicular disease, and if the operation has favoured their development it is not entirely responsible for their occurrence.

The course taken by injuries affecting a neurectomised foot varies. Bouley states that under the influence of the cerebro-spinal system, "healing inflammation" proceeds normally in the parts affected by neurectomy. This, however, is not always the case. You recently saw a horse, unnerved for a large external sidebone, afterwards develop a quittor on the inner surface. In treating the quittor the lateral cartilage was removed, and the subsequent traumatic inflammation showed very special characters. The wound became indolent and healed very slowly, while the coronet and pastern increased enormously in size; severe lameness continued, and the animal became useless.

The cases I have just mentioned, together with others published abroad and certain collected by human surgeons, show that if removal of nervous influence does not produce immediate and evident effects on the phenomena of nutrition, it may, in combination with other causes, like wounds, infections, etc., produce lesions of rapid or slow development, and of inflammatory, gangrenous, hypertrophic, or atrophic nature. No organ or tissue, in the region served by the divided nerve, is safe from these changes. They appear especially to affect the skin,

connective tissue, bones, and articulations; and if, up to the present, their pathology is incompletely understood, it is known that mechanical violence does not appear necessary for their production.

It has been shown that after section of nerves the specialised cells of the peripheral end undergo retrogressive changes ending in destruction, and that regeneration occurs by a kind of branching of the fibres of the central end. This reconstitution of nerves explains the occasional return of lameness after operation, and the removal of this secondary lameness when neurectomy is again performed above the point first selected. Stanley related a case of this kind. Two years after the first treatment the horse went lame and he again operated, this time above the cicatrices left by the former intervention. As in the first instance, the animal became sound.

But this regeneration, which occurs when only a short portion of the nerve has been removed, is always somewhat imperfect. The permanent good effects of neurectomy, and the delayed complications which it sometimes produces, are both referable to this incomplete regrowth. This view, better than any other, explains the lasting good effects of neurectomy. Success is due to the fact that sensation only returns to a modified extent in the tissues from which it has temporarily been removed. The pathogeny of the after complications, trophic or otherwise, is governed by the same cause.

I conclude by reminding you that, on the whole, grave complications after neurectomy are not frequent, and that even taking them into account, the practical value of the operation remains indisputable. Plantar neurectomy has too often given good results to be condemned. Undoubtedly it is only a kind of *ultima ratio*, but before abandoning a case of lameness which has improved but little or not at all under other treatment this last resource should certainly be tried.

XV.—NEURECTOMY OF THE MEDIAN AND OF THE ULNAR NERVES.

At the present time we have in hospital a horse on which I have successively performed neurectomy of the median and of the ulnar nerve. To-day I intend to speak of this horse, and of the two operations to which we have been obliged to resort.

A little more than a month ago—it was during the first days of May—M. H—, carman at Paris, brought a six-year-old horse for examination. It had long been lame on the off fore-leg. On examining the lower parts of the leg I found chronic changes in the bones, joints, and tendons. This examination showed the existence of an old-standing strain of the flexor tendons, an indurated windgall, phalangeal periostitis, and two sidebones, the inner a little larger than the outer. Furthermore, the fetlock was upright and had commenced to knuckle over. The tendon and coronet showed traces of penetrating firing. On examining the limb the tendons appeared slightly painful, especially at their upper part opposite the check ligament. The lameness, which was quite distinct at a walk, was very marked at a trot.

M. H—, in bringing his horse, thought that we would again fire the tendon and the ringbones. I assured him that firing would be of no benefit. It could certainly not cure all these chronic changes, nor produce sufficiently marked effects to remove the lameness, but as the animal seemed worth it I proposed median neurectomy, and in your presence explained on what grounds I justified this method of treatment, which was accepted.

On the 6th May, after having applied thin-heeled shoes to the fore-feet (the heels of which were contracted), I performed median neurectomy by the usual method. The animal was cast on the right side, and the near fore-foot secured to the canon-bone of the corresponding hind limb. The hobbles being drawn back, a strip of webbing was applied to the canon-bone of the off fore-leg, which was released from the hobbles and drawn forward into a position of full extension, in which it was secured by two assistants holding the webbing. In this way the

inner surface of the limb is well uncovered, and by kneeling in front of the chest, near the neck, the operator can proceed in comfort and entire safety.

[The operation of median neurectomy is as follows.

The median nerve is readily discovered on the inner surface of the forearm, running obliquely downwards and slightly backwards just behind a ridge on the head of the radius, into which is inserted the internal lateral ligament of the elbow. It crosses the posterior radial artery at a very acute angle, and passes with it towards the posterior surface of the radius. The posterior radial vein (or veins) is situated in front of the nerve. The operation is performed opposite the lower portion of the elbow-joint, or immediately behind the upper extremity of the radius towards the upper point in the depression between the radius and the flexor muscles of the fore-limb.

The skin having been shaven and disinfected, an incision about an inch in length is made, traversing successively the skin, subcutaneous connective tissue, and the prolongation of the posterior superficial pectoral muscle. Towards the lower angle of the wound the fascia of the forearm is slightly incised, a grooved director passed under it and pushed upwards, parallel with the nerve. By passing the bistoury along the groove the fascia is then laid open. Another method consists in using a probe-pointed bistoury. Certain operators even go so far as to snip away with scissors an elliptical fragment of fascia on either side, thus more freely uncovering the nerve. The skin wound is then held open with retractors. The next step in operation consists in dissecting free the nerve (sometimes a rather tiresome process), and raising the nerve on a grooved director or tenaculum. The nerve is cut through as high up as possible, and again near the lower limit of the wound, a piece about three quarters of an inch in length being removed. The operation is concluded by wiping the wound dry, dusting with iodoform, suturing the skin, and applying a little iodoform collodion or similar dressing.—Jno. A. W. D.]

When the incision is skilfully made at the proper point, and the antibrachial aponeurosis opened, the nerve often appears immediately as a flattened whitish cord, which has a tendency to become thrust forward and to protrude between the lips of the incision in the aponeurosis. This occurred in our horse. The operation only lasted a few minutes. When the nerve does not appear, it is usually sufficient to slightly alter the position of the limb in order to bring it under the

incision; for this purpose the assistants have only to increase or diminish the pull on the limb. You know that in certain animals operation is rendered difficult by an abnormal arrangement of the radial veins, but this is rare. I return to our patient.

After excising about three quarters of an inch of the nerve I placed a fragment of gauze in the wound to act as a drainage-tube, and over it I united the skin with a couple of sutures. On rising the horse appeared a little less lame than before operation. Next day the sutures were cut, the gauze removed, and the parts treated with antiseptic lotions like an open wound. Healing occurred towards the end of the second week. Unfortunately the result was bad. Lameness was still too marked for the horse to work.

Peters, and after him others, showed that division of the median nerve alone may remove lameness resulting from bilateral lesions,—that is to say, occupying both sides of one of the lower parts of the leg, or encircling these regions. The results are explained by the preponderating influence of the median nerve in the innervation of structures below the knee, a preponderance due to the fact that at a variable point in the forearm the nerve terminates by dividing into two branches, one of which is continued as the internal plantar nerve, while the other joins the ulnar at the upper border of the pisiform bone, beneath the tendon of the middle flexor, and is continued as the external plantar nerve.

In hospital you have seen horses with various chronic affections, like strained tendons, splints, cartilaginous ringbones, and periostitis of the phalanges, in which lameness has been removed, or certainly diminished, by dividing the median nerve.

But others occur in which section of the nerve fails to remove lameness caused by lesions on the outer side of the limb, or at times even on the inner. The persistence of pain and lameness in the latter case is explained by the existence of recurrent fibres. Under such circumstances, ulnar neurectomy, first practised by Vennerholm, often proves useful. As, in our patient, severe lameness continued after radial neurectomy, division of the ulnar was resorted to.

Throughout the whole extent of the forearm the ulnar cutaneous nerve, accompanied by the ulnar artery and vein, is situate between the oblique and external flexors of the metacarpus, and immediately under the fascia uniting them. By palpation with the finger tips the muscular interspace which fixes the line of operation is readily discovered.

In performing this operation the horse is cast on the sound side. The affected limb is left in the hobbles, but drawn tense by means of two strips of webbing, one fixed on the upper portion of the canon-bone being pulled backwards, the other, attached to the coronet, in a forward direction. Two assistants, holding the free ends, keep the parts steady.

The operator kneels in front of the upper part of the forearm; the point selected is four to six inches above the knee.

The parts having been prepared, my colleague M. Almy made, at the point just indicated, an incision about one inch and a quarter to

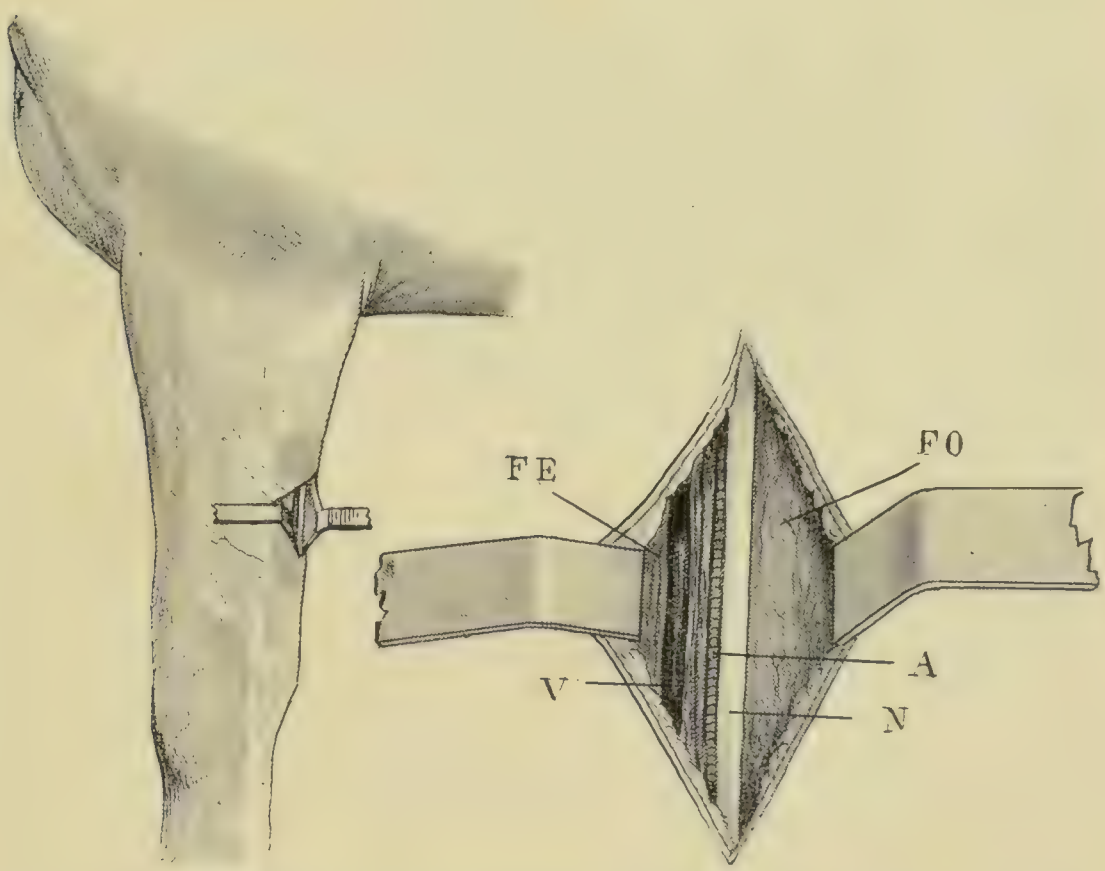

Figs. 11 and 12.—Neurectomy of the ulnar nerve. F E, flexor metacarpi externus; F O, flexor metacarpi obliquus; N, ulnar nerve; A V, ulnar artery and nerve.

one inch and a half long through the skin. He then divided the subcutaneous connective tissue, the antibrachial aponeurosis, and the fascia which unites the aponeurotic covering of the two muscles.

With forceps and bistoury he dissected away the connective tissue surrounding the nerve, following the direction of the wound, and carefully avoiding injury to the ulnar artery and vein which accompany the nerve.

Having isolated the nerve, he divided it at the upper angle of the wound, and excised a fragment about one inch and a quarter in length.

The wound was cleansed and the skin brought together with three small sutures.

The results of this second operation were satisfactory. On rising the horse no longer walked lame. The wound healed by first intention. At the present moment the animal is exercised night and morning. At a trot it only shows trifling lameness, and as it is used for heavy draught it will soon be able to return to work.

I shall recommend the owner to keep careful watch over the condition of the foot and of lower parts of the limb. We must bear in mind the possibility of trophic changes and of sloughing, which I referred to when treating of plantar neurectomy.

You will not often see this double neurectomy performed. Even neurectomy of the median alone often has serious drawbacks. It should be reserved, as I have already said, for *old-standing* chronic affections of the fore-limb, and—particularly in dealing with valuable animals—should not be tried until all other methods of treatment, especially firing, have proved unsuccessful.

I do not agree with the advice of the *savant* who recommended it for all cases of strained tendon uncured at the end of six weeks. That would have ended in a perfect debauch of neurectomy.

XVI.—LYMPHANGITIS AND MULTIPLE ABSCESSES IN THE HORSE, DUE TO THE PRESENCE OF STAPHYLOCOCCI.

In explaining to you the modern doctrine of suppuration, I stated that all suppuration seen in our patients is the work of certain microbes, chief amongst which are the *Staphylococcus albus* and *aureus* and the streptococci—other varieties occurring much less frequently. The microbes enter the tissues by many paths, the commonest being cutaneous or mucous wounds. Very trifling abrasions, often concealed by the hair and practically imperceptible, may serve as points of entry. Sometimes they simply produce a local abscess, at others they enter the lymph channels, causing lymphangitis or abscess formation in neighbouring or far-removed lymphatic glands, according to the condition of the lymph channels. Occasionally they enter the circulation, are swept along by the blood, and give rise to varying mischief, according to their degree of virulence. In this way streptococci and staphylococci produce the metastatic abscesses of pyæmia, and the microbe of strangles induces the majority of abscesses seen during the course of this disease.

In my part of the hospital you have seen two horses in which staphylococci have thus caused abscesses in different parts.

Some months ago a seven-year-old Percheron horse, in which I had removed the lateral cartilage of the off fore-foot on account of quittor, showed four days after operation very marked swelling of the limb, especially pronounced below the knee—a swelling which extended to the forearm, and caused me to fear the existence of deep-seated abscess in this region. All danger of immediate complications was however removed by the use of warm antiseptic baths, followed by iodoform dressings; the operation wound healed steadily, swelling of the limb at the same time diminishing.

The lymphangitis had completely disappeared when a fortnight later we discovered a number of small abscesses scattered about the neck, sides, and limbs. Of what nature were these abscesses?

Although there was no clinical sign pointing to farcy the animal was injected with mallein. The result was as I had foreseen; no local reaction followed, and the temperature rose only half a degree. I had collected with the usual precautions some pus for bacteriological examination and cultivations. The microscope revealed a few staphylococci, and the tubes of gelatine which we sowed gave a pure culture of the *Staphylococcus albus*.

Treated by injections of dilute sublimate solution the abscesses rapidly healed. No others formed. The animal's general health was excellent, and to explain the production of these multiple abscesses I see no other possible hypothesis than infection of the blood by some pyogenic microbe which had multiplied in the wound in the foot and given rise to the lymphangitis. Against that may be urged the time which elapsed between the acute phase of the lymphangitis and the appearance of the abscesses, but well-established facts show that secondary suppurative lesions may occur after a much longer time. Many other microbes besides staphylococci may cause disturbance after remaining dormant for weeks, months, or even years.

The second case is not less interesting than the first, and shows like it that the *Staphylococcus albus* may be the sole cause of secondary abscesses developing far from the primary centre. A fifteen-year-old Percheron mare suffering from circumscribed gangrenous inflammation on the near fore-pastern was received into hospital on the 6th December, 1895. The eschar was removed, and the wound appeared about to heal when diffuse lymphangitis extended throughout the limb, the swelling became enormous, sensibility excessive, and interference with movement very marked. The first abscess formed on the inner surface of the knee, and opened spontaneously. During the next few days the wound on the pastern presented a less favourable appearance; it discharged freely; its margins were swollen and painful. The swelling next invaded the upper portions of the limb, extending as high as the shoulder. Soon afterwards the hair was shed over a line extending from the wound on the knee. On this line, which corresponded to the course of the inflamed lymphatics, five subcutaneous abscesses developed, and were opened in succession. Close to the point of the shoulder was a circular swelling, denuded of hair, and measuring an inch or more in diameter, produced by another superficial abscess.

The wound on the knee, circular in form, and as large as a florin, became covered with firm healthy-looking granulations. Its margins projected slightly above the surrounding skin, and its centre showed a

sinus which communicated with a subcutaneous conduit exactly corresponding with the depilated line above mentioned. It discharged whitish, thin, slightly viscous pus, similar in character to that always formed in lymphatic vessels or glands. The lower parts of the limb showed relatively little œdematous swelling. The wound on the pastern was about two and a half to two and three quarter inches long, and half an inch across.

These wounds had no resemblance to ulcers, and neither they nor the lymphatic vessels were surrounded by much induration. The animal had not suffered from any disease for years, and its general condition was excellent.

For the purpose of bacteriological examination I punctured an abscess on the inner surface of the forearm, and with a sterilised pipette collected a little pus, which I sowed on gelatine and potato. At the temperature of the lecture-room colonies of *Staphylococcus albus* developed.

The clinical course of these lesions differed from those usually seen in glanders. An injection of mallein produced a very trifling reaction. After puncturing the abscesses treatment consisted in antiseptic injections into the sinus. On the 16th December the swelling and wounds on the near fore-limb still showed the same characters.

On the 18th we discovered on the outside of the right thigh, a little behind and above the patella, a hot, sensitive œdematous swelling, the centre of which showed fluctuation. It was punctured aseptically, and some pus collected for cultivation. The cultures gave colonies of the same staphylococcus. The animal received daily in its food one and a half ounces of bicarbonate of soda in the morning, and two and a half drachms of sulphate of quinine at night.

On the 20th December a warm, painful swelling was noted in the region of the extensor muscles of the right forearm, suggesting the formation of an abscess. Next day œdematous enlargement appeared below the elbow, examination of which revealed the presence of fluctuation in the depths. The abscess was punctured and some of the pus sown on gelatine and potato. The *Staphylococcus albus* was again found to be the only micro-organism present.

Finally, eight days later, a fresh suppurating centre, also produced by the same microbe, formed on the right side of the neck.

The wounds having healed and the lymphangitis disappeared, the horse returned to ordinary work. It has not since been seen; but some months later we were told that it had not developed any further abscesses. Its system, therefore, appeared to have become entirely free from staphylococci.

XVII.—EXTERNAL TUBERCULOSIS IN THE DOG AND CAT.

You know that tuberculous dogs may eject material containing bacilli by the nose, anus, and urethra. To-day I purpose showing you that some also distribute the virus by external lesions, the specific character of which has been overlooked, lesions which may persist for a long time, and discharge pus rich in bacilli. I shall take as my subject tuberculous wounds and sinuses. The region of the neck is that most commonly affected. I have seen wounds of this kind in fourteen patients; in twelve they were situated at varying points on the anterior margin of the neck; in one the thoracic wall showed a sinus, and in the last the wound was close to a joint.

To show you the danger of such lesions conveying the disease, I shall briefly describe three cases from among those which I have investigated.

On the 21st May, 1895, a two-year-old poodle, belonging to M. V—, Avenue du Maine, Paris, was brought for examination. At the beginning of March, in the same year, this dog had had an abscess at the upper part of the neck. The wound, produced by puncture, instead of healing had become ulcerous, and the animal had lost flesh to a marked degree.

When I examined the patient the front of the neck displayed a large ulcer with thin margins, separated from the skin to a considerable extent, bathed in greyish pus, and with a granular base, penetrated by a number of sinuses running toward the larynx and origin of the trachea. The animal's thin condition and the appearance of the wound immediately suggested tuberculosis. Bacteriological examination of the pus revealed numerous bacilli. This poodle lived in the suite of rooms occupied by its owners. The lesion in the neck having been regarded as a simple wound had been unsuccessfully treated for two months with all kinds of applications, and had even been sutured.

FIG. 13.—Tuberculous ulcer in the throat.

FIG. 14.—Tuberculous ulcer in the neck.

On the 23rd July, 1895, a small bitch belonging to M. L—, Rue de Charenton, Paris, was brought for examination.

For about six weeks this bitch had shown, nearly over the centre line of the front of the neck, two sinuous wounds. During the journey from Paris to Alfort the child who brought it had bandaged the animal's neck with her handkerchief, and in our presence she wiped away the pus running from the wounds with this same handkerchief.

The appearance of the wounds, the thinness of the patient, and the dyspnœa, awakened suspicion of tuberculosis. I made cover-glass preparations with the pus; all contained bacilli.

This animal was left, and kept in the stable belonging to the surgical clinique. Five months later it died from generalised tuberculosis. The sinuses never healed.

On the 16th May last, M. H—, living in the Rue St. Martin, Paris, brought us a four-year-old dog, which had suffered for three months from an ulcerous wound one and a quarter inches in length and three quarters of an inch in width about the middle of the neck. The margins were separated from the skin, eroded, and covered with crusts and blood-stained pus. Four inches below this lesion was a slender sinus masked by the agglutinated hair. As in the cases just mentioned, pus from these lesions was found to contain large numbers of bacilli.

Until the day it was brought to Alfort this dog lived in a corner of the single room inhabited by M. M—, his wife, and their child.

These tuberculous wounds of the neck are of lymphatic origin. Only one case had been published previous to my researches, and the author, Müller of Dresden, regarded the case as of primary cutaneous origin. I have been able to follow the development in several subjects. It is similar to that of tuberculous suppurating adenitis in man, and exhibits three principal stages: (1) Glandular disease; (2) Abscess formation in, or around a lymphatic gland; (3) Ulceration of the skin. When a lesion of this kind is fully developed, or has existed for some weeks, it usually presents the following appearance: A circular, oval, or irregular wound, the margins of which are denuded of hair, torn or thinned, and separated from the subjacent tissues; with reddish, uneven base covered with indolent granulations, or dotted over with yellowish points, from which sinuous tracts lead towards the trachea, or along the line of adjacent vessels. The wound discharges greyish or blood-stained pus, always purulent, and sometimes rich in bacilli.

Their true nature not being recognised, these lesions are treated like simple wounds; they continue to suppurate. In certain patients

the cutaneous ulcer contracts; in others it gradually increases. Abscesses sometimes develop in the neighbourhood and open externally, producing small wounds, which may unite with the first; sometimes the skin becomes separated from subjacent structures over a large area, and is rapidly riddled with ulcers. The muscular and connective tissues traversed by the sinuses are inflamed, hardened, and fused together. On dissection granulations and caseous tubercles are found. The retro-pharyngeal and cervical lymphatic glands are always affected; either they are hypertrophied, inflamed, and on section appear dotted over with yellowish points formed by the granulations, or they appear as little swellings the size of a haricot bean or a hazel nut, with softened purulent centres. I have twice seen the cervical glands connected by knotted lymphatic vessels with the tracheo-bronchial lymphatic glands.

The mucous membranes in the domain of the affected lymphatics rarely show specific lesions. I have only seen three such. One showed tuberculous ulceration of the left tonsil; another, a submucous tubercle in the pharynx; and the third, ulceration of the mucous membrane of the larynx.

Despite the very rare occurrence of lesions indicating the point of entrance of bacilli, these tuberculous ulcers of the neck result from auto-inoculation of the pharyngeal, laryngeal, or nasal mucous membranes, by purulent products formed in the lung and coughed into the pharynx or posterior nasal cavities. Of the above-mentioned twelve patients showing tuberculous ulcer of the neck ten had very marked disease of the lungs, which were partially destroyed by the formation of cavernous spaces. Pharyngeal catarrh is known to be fairly common in the dog. Under these circumstances auto-inoculation occurs readily. The mucous membrane, whether normal or deprived of its epithelium, when covered with virulent muco-pus is penetrated by the bacilli, which afterwards extend to the neighbouring lymphatic glands. Pressure of the collar causes inflammation of the infected glands, favours suppuration of the surrounding tissues, and ulceration of the skin. This is the true pathogeny of tuberculous ulcers in the dog's neck.

Subcutaneous or open tuberculous lesions are also seen in the cat. In addition to the three cases of this nature mentioned I may cite the two following:

At the beginning of April, 1895, a seven-year-old female cat was brought to the clinique. It had been ill for some time, and already showed marked wasting. The owner had particularly noted difficulty in breathing, attacks of coughing, and at certain times a little nasal

discharge. Although the appetite was sometimes capricious, the animal usually ate the greater part of its food. It belonged to a woman who had long suffered from chronic cough, which she regarded as asthmatic, though to a better-informed person she clearly had the appearance of a consumptive. About six weeks before a suppurating wound had been noticed at the upper part of the cat's neck. Situated near the origin of the trachea, this wound was circular in form, hardly two lines in diameter, and had thin separated edges. It communicated with a long sinuous track, ending on the left surface of the trachea. It discharged

FIG. 15.—Tuberculous ulcer of the nose.

a greyish pus, in which bacilli were discovered on bacteriological examination. I was unable to prevail on the owner to leave this cat, and it was never brought back again.

A year later, in 1896, a three-year-old cat was brought for examination whilst still in good health. For five or six months it had suffered from an ulcerous wound of the nose and face.

I kept this patient in hospital for some time. The wound was rounded in form, occupied the entire dorsal region of the nose and a portion of the face and forehead, and measured nearly an inch and a half in diameter. Its margins were indurated and excavated perpendicularly.

Its base was greyish, fairly level, and presented the general appearance of an ulcerated cancer. Yellowish granulations, however, appeared at points; and around its outer edge, beneath the separated skin, caseous material could be seen. Greyish pus ran from the nostrils, which were soiled and covered with crusts. Both submaxillary lymphatic glands were slightly enlarged. The lesion was, therefore, of tuberculous character, and very virulent. The nasal discharge, pus, and caseous material from the wound contained considerable numbers of bacilli.

On *post-mortem* examination we found disease of the precæcal mesenteric glands, which were as large as a hazel nut, hard, gritty on section, and showed caseous, and even chalky, points. The liver also presented some tubercles. The lungs contained numerous caseous centres; the tracheo-bronchial, retro-pharyngeal, and submaxillary glands were diseased.

The ulcer on the nose had not only destroyed the soft tissues, but had invaded the subjacent bone, which was soft and friable, eroded in places, and infiltrated with caseous material. The upper wall of the nasal cavities was, however, only pierced at one point, between the nasal and superior maxillary bones, midway between the eye and base of the nose, whence communication existed with the left nasal cavity by an orifice which had escaped notice during life. For a distance of about three eighths of an inch around the ulcer, the skin and subcutaneous connective tissue showed on section yellowish points denoting softened tubercles. In the thickness of the end of the nose similar lesions were found. Close to the perforation, and particularly over the turbinated bones, the pituitary membrane was thickened, ulcerated in places, and covered with fine tuberculous granules; thickening of the mucous membrane was specially marked towards the opening of the nostrils, which it partially blocked.

Ulceration of the tissues of the nose was probably secondary; a centre having first formed on the pituitary membrane, extended to the turbinated bones, thence to the lower portion of the nasal bones, and lastly to the skin. The process would be favoured by rubbing or scratching the parts. It is also possible that the skin may have been directly inoculated by the action of the paws.

XVIII.—A CASE OF SARCOMATOUS DISEASE.

During the past month you have had opportunities of following in hospital the progress of a rare form of sarcomatous disease in the horse, distinguished by its clinical characters from the varieties hitherto described in animals. In our patient development of the disease was indicated by the appearance of numerous tumours of varying size in the subcutaneous connective tissue and muscular interstices, without the skin or lymphatic glands being invaded, as is the rule in sarcoma, and, until the last few days at least, without grave symptoms pointing to the existence of visceral new growths having occurred.

Sarcomata have a marked preference for the connective tissue. They may occur wherever this tissue exists, *i.e.* in all organs. The majority have a well-marked tendency to generalisation. This process, which occurs by the venous channels, is often very irregular. Secondary tumours sometimes develop in large numbers in almost all the viscera; sometimes they are comparatively rare. The lung is most frequently invaded when infection is general, and usually shows the greatest number of growths. Cases occur, however, where sarcomata appear to extend systematically, affecting almost exclusively the bones, skin, or subcutaneous connective tissue, and producing particular varieties of disease, distinguished by special clinical and anatomical pathological characters.

Thirty years ago Kaposi described, under the name of cutaneous sarcoma, a human disease characterised by circumscribed swellings of the skin, raised patches, and flattened, isolated, or confluent swellings, the structure of which was that of sarcoma. A similar affection occurs in animals. M. Trasbot described it in the article on Sarcoma in the *Dictionnaire de Médecine Vétérinaire*, under the title "Variétés Verruqueuses." In solipeds, says M. Trasbot, this variety is confined to surfaces where the skin is fine—around the eyes, nose, mouth, ears, sheath, and mammary gland, and on the inner surfaces of the limbs; sometimes it invades the abdominal, thoracic, and inferior cervical regions. The tumours may assume one of two forms, appearing either as warts adherent to and projecting, more or less, above the surface of the skin, or as globular masses lodged in the subcutaneous connective

tissue; both forms, however, are always associated in the same subject. The tissue of these new growths is pale grey, without marbling, is firmer and denser than that of other sarcomata, and is composed exclusively of fusiform cells. Round-cells never occur.

Such were not the clinical or anatomical features of the disease in our patient. The skin was altogether unaffected; the tumours were dispersed throughout the subcutaneous and intra-muscular connective tissue; only a few adhered to the skin, and even they did not penetrate it. Moreover *post-mortem* examination showed much more extensive visceral lesions than we had anticipated. The visceral lesions preceded those in the subcutaneous connective tissue, but we were unable to make out any close connection between the subcutaneous and the visceral tumours from the point of view of their origin. No vascular lesions existed to explain the generalisation.

The patient died at the commencement of the sixth week after admission to hospital. I wish to remind you of its history. The report of the *post-mortem* examination leaves no room for wonder at the animal's death.

A Dutch gelding, about twelve years old, in fairly good condition. Sent to the College on account of subcutaneous swellings in different regions. The largest was situated on the right side of the chest, opposite the fourth, fifth, and sixth ribs, a little above the line of the elbow. Hemispherical in form, it measured nearly six inches in diameter. Another of about the same size lay immediately in front of the cervical angle of the scapula. A third, as large as a fowl's egg, was noted about halfway up the left side of the chest, opposite the sixth rib. At the lowest part of the same side of the chest, opposite the twelfth rib, was a nodule the size of a nut. On the left side again, over the thirteenth rib, was a tumour as large as a pigeon's egg. All were practically of the same character, being firm, slightly elastic, painless, sharply defined, moveable under the skin and over the subjacent parts, or in cases slightly adherent to the latter.

The temperature, respiration, and circulation were normal. The urine showed considerable sediment, consisting largely of carbonate and phosphate of lime, but contained no albumen, sugar, or bile pigments. There was no change in the proportion of urea.

The blood was normal. The number of blood-corpuscles was found to be as follows:

Red corpuscles . . .	5,602,875 per cubic millimetre.
White corpuscles . .	5864 ,, ,,
Proportion	1 to 955.

This horse was sent to us by a colleague, who regarded it as suffering from "cold abscesses." But subcutaneous cold abscesses are less sharply defined than were the tumours; they grow more rapidly, are adherent to the skin, and pressure on them produces pain; finally, they are usually found in parts covered by the harness. Exploratory puncture through the centre of the two largest swellings gave a negative result.

We began to consider whether the case was one of tuberculosis. There was no enlargement of the glands at the entrance of the chest, in the groin, or under the lumbar vertebræ. On the supposition of tuberculosis some at least of these swellings should have been accompanied by lymphangitis and by specific inflammation of lymphatic glands, as in the case of which I recently spoke. We cleared up this question, however, by testing with tuberculin, by bacteriological examination, and by inoculation.

One of the tumours was removed from the right side of the chest. It was flattened, circular in form, and its tissue greyish-white, and slightly firm. Microscopic examination showed it to be entirely formed of round-cells, with large nuclei. It contained neither tuberculous centres nor giant-cells; and bacteriological examination produced no bacilli. An emulsion formed by crushing a fragment of the tumour in a little sterilised water was injected into the peritoneum of two guinea-pigs. The day afterwards 30 centigrammes of tuberculin were injected on the right side of the horse's neck. This was followed by no appreciable reaction, no fever, no rise in pulse-rate, etc., nothing except a very trifling swelling. We then inferred the new growths to be sarcomatous in character.

I may here add, to avoid having afterwards to return to the question, that the result of inoculation was negative. When killed at the end of five weeks neither guinea-pig showed any tuberculous or sarcomatous lesion whatever on *post-mortem* examination.

There was no hope of removing the tumours. I prescribed 2 drachms potassium iodide, and at a later stage 15 grains of arsenious acid daily. No tangible improvement occurred. I now return to the clinical history.

Some days after the horse entered hospital new tumours appeared in different regions, and others successively followed.

At a trot the animal's breathing at once became laboured. The horse was unable to work, and as the number and size of the tumours increased it progressively became weaker.

During the first week the general condition showed little change;

the temperature never rose above 38·4° C. (101·1° F.). The patient only ate a part of its food, and was usually dull and sleepy. The respiration was short, and tended to become more rapid.

A week later a fresh examination gave the following results:

General condition worse; muscular wasting more marked; the bones appeared more prominent; the coat stared; the lower portions of the limb were swollen; the heart's action was rapid and strong; temperature 38·6° C. (101·4° F.); pulse 80; respirations 30. Nearly fifty tumours were counted; all the old ones had increased in size, and a number of new tumours were scattered throughout various regions. We noted—

On the left side of the body, behind the shoulder and about the middle line of the ribs, two new growths the size of a large hen's egg; immediately beneath the skin three smaller flattened tumours; one behind the acromion process; another in the precordial region; a third under the girth, near the median line; nine tumours the size of a shilling to that of a five-shilling-piece formed a string along the hypochondriac region; over the thin part of the flank were four similar tumours; in the inguinal region, especially along the upper border of the internal surface of the thigh, was a chain of tumours, some the size of a pigeon's egg; a large number of nodules were scattered throughout the connective tissue.

On the right side were a few small tumours around the large growth in front of the scapula; along the hypochondriac region a dozen flattened tumours, arranged in a string; in the thin part of the flank, six inches below the angle of the haunch, a tumour the size of a pigeon's egg; in the groin and inner surface of the thigh numerous hard, isolated, or agglomerated nodules; immediately below the inguinal ring a tumour, difficult to examine, on account of its deep-seated position, but which appeared large in size.

On the inner surface of the left forearm a subcutaneous tumour as large as a two-shilling piece; nothing on the right limb; nothing about the head or upper two thirds of the neck.

There was no enlargement of the sublumbar lymphatic glands. Rectal exploration only revealed the presence of a tumour the size of a hen's egg on the anterior margin of the left ilium at the height of the ilio-pectineal crest.

The temperature was only a few tenths above normal; the heart's action was rapid and tumultuous, the first sound being strong, the second replaced by a diastolic murmur.

One morning a few days after this examination, when the patient seemed in the same condition as on the preceding days, and had taken

a part of its food, the condition suddenly became aggravated. The horse was found stretched on the ground, the face drawn, the respiration very rapid, dyspnœa marked, and the mucous membrane cyanotic. It rose with much difficulty, but almost immediately fell again, and struggled violently. The dyspnœa became more and more marked; the animal broke out in perspiration; the limbs became cold; and death followed.

Autopsy.—Lesions of asphyxia; mucous membranes cyanotic; muscular tissues deep red in colour; the capillaries of the subcutaneous cellular tissue engorged with blackish liquid blood, which turned red and coagulated rapidly on contact with air; viscera congested; patches of ecchymosis in the lungs, cavities of the heart, and under the endocardium.

The new growth was more generalised than had been suspected during life. Tumours existed in very large numbers. Some were globular; the greater number flattened; a few thinner at the centre than at the periphery. Their dimensions varied between those of a pea and of a child's head. All were sharply circumscribed; all developed in the connective tissue—the majority in the subcutaneous connective tissue,—some under the serous membranes, and in the muscular interstices. Sections through muscles failed to reveal any in the muscular tissue itself. The majority of these tumours, especially those of small size, or recent formation, had produced no change in the surrounding tissues. Others had caused inflammation as indicated by sclerosis, or the formation of a fibrous limiting membrane; others, again, were surrounded by a gelatinous yellowish or blood-stained exudate. Their physical characters and structure varied according to their age. The smaller, or more recent, were soft and friable, formed of a homogeneous whitish tissue; others, of larger size and firmer consistence, were greyish towards the centre; in the largest, three concentric zones could be distinguished—an external friable zone, light in colour, resembling in structure the recent tumours; a middle, greyish; finally, a central, light yellow in colour and irregularly defined, formed by broken-down tissue. The superficial layers of many of these new growths showed fine ecchymoses.

In the left hind leg, between the muscular portion of the short adductor, the pectineus and the adductors of the thigh, was a tumour weighing $3\frac{3}{4}$ lbs.; above the right shoulder, under the cervical trapezius and the rhomboideus, another, weighing $25\frac{1}{2}$ oz.; behind this shoulder, between the great serratus and great dorsal muscle, still another, more than 21 oz. in weight.

We counted fifty between the muscles of the right arm and the

great serratus muscle; thirty below the left shoulder. They were very numerous in the pectoral, abdominal, and costal muscles.

On opening the abdomen we were struck by the abundance of fat still remaining in the lumbar region, around the kidneys, and in the pelvis. We only found one tumour there, that which had been recognised by rectal exploration at the anterior margin of the ilium. There were none in the liver, spleen, kidneys, or bladder; nor in the walls of the stomach or intestine. Dissection showed a few in the interstices of the psoæ muscles.

The pleuræ contained a little lemon-yellow liquid, but showed neither tumours nor granulations. The left lung only exhibited the ordinary lesions of hypostatic congestion. Sections through the centre of the right lung revealed four recent whitish, friable tumours, the size of a nut, but not surrounded by any congestive or inflammatory zone.

The pericardium contained a little lemon-yellow liquid. Both its layers were normal; between the external and the mediastinum, distributed in a layer of adipose tissue, were about twenty small flattened tumours.

The heart showed remarkable lesions. The myocardium appeared slightly hypertrophied, softened, and pale yellow in colour. All the valves were deformed by the presence of little flattened biconvex tumours, developed in their thickness; the largest the size of a sixpence, the smallest of a pea. In general they were closer to the line of insertion than to the free margin; they were especially thick in the aortic semilunar valves. The diastolic murmur noted during the last days of life had resulted from their interfering with the action of the valves. All were formed of a friable, greyish-white tissue, punctated with fine hæmorrhagic spots.

Finally, at the base of the heart was a large lesion, which explained both the fatal termination and its sudden character. Astride the bifurcation of the common aorta and closely in contact with both its branches was a large tumour, 8 inches in length, 5 in depth, and 2¾ in thickness, weighing 2 lbs. 10 oz., surrounded by a number of small satellite new growths, distributed in a layer of connective tissue enveloping the whole. This tumour, which had invaded the tunica adventitia of the aorta, was intimately adherent to the middle coat; the parts could not be separated with a director; it was necessary to use the bistoury. On section, however, the line of demarcation was very clear, the new greyish-white tissue showing up distinctly against the yellow ground of the arterial wall. Like those above mentioned, this tumour could be divided into three zones: a soft reddish tissue

occupying the periphery, a denser greyish tissue the intermediate part, and yellowish irregularly-defined patches the centre. The two former zones were marked with numerous hæmorrhagic points. The pneumogastric nerves were surrounded by the peripheral layer of this tumour.

The submaxillary and tracheo-bronchial lymphatic glands were slightly enlarged, but not in consequence of sarcomatous growths. The sublumbar, inguinal, and prepectoral glands were healthy, despite the fact that lymph from highly infected regions passed through them. Nothing whatever in the nervous centres.

Four days before death examination of the blood had shown a proportion of 4,562,750 red blood-corpuscles to 12,918 leucocytes per cubic millimetre, *i. e.* one white corpuscle to 353 red. Generalisation of the sarcomatous process had, therefore, been followed by marked leucocytosis.

There, then, you have a very exact and detailed description of this peculiar case.

I have said that to the naked eye and under the microscope these tumours showed the appearances of sarcomata; but of what variety? You know that four principal kinds are distinguished: (1) encephaloid or globo-cellular sarcoma, formed of round-cells with large nuclei and scanty protoplasm, interspersed with thin-walled embryonic blood-vessels; (2) fasciculated or fuso-cellular sarcoma, formed of elongated fusiform cells and blood-vessels, resembling those just mentioned; (3) myeloid sarcoma, a new growth affecting bony tissue, in which large multi-nucleated cells resembling the myeloplaxes of bone-marrow predominate; (4) and finally, melanotic sarcoma, the tumour of white horses, in which the cells are full of grey or black pigment granules.

The tumours in our patient did not belong to any of these varieties. They were formed of cells of unequal size, the majority rounded, but some irregular, and of vessels without clearly-defined walls. In addition we detected a reticulum, varying in thickness according to the points examined and the age of the tumours.

In recent tumours all the cells were round, while the reticulum was delicate and scanty, though quite clear in sections which had been carefully manipulated with a brush. In the larger, older, and therefore harder tumours, a certain number of the cells were irregular or fusiform, and the reticulum more abundant, forming at certain points narrow interlacing bands. Their histological characters placed these tumours between the sarcomata and lymphadenomata; they were lymphoid or lymphadenomatous sarcomata.

You must not, however, hastily conclude that all generalised or localised dermic or hypodermic tumours, whether distributed irregularly or systematically, are necessarily sarcomata. Tuberculosis may produce similar growths. I have given you an example. Other new growths may also behave in the same way. In the horse and dog several cases of fibromatosis have been reported.

Some years ago I saw a bitch affected with numerous fibrous tumours in and below the skin, but confined exclusively to the extremities. Some months before a few little tumours had appeared on the head and limbs, had increased in size, and been followed by others. At the first glance one's attention was attracted to an irregular flattened tumour the size of a five-shilling piece on the free portion of the right ear, the centre of which was excoriated and bleeding. The left ear, nose, cheek, tail, and all four limbs showed other new growths in the skin and subcutaneous tissue. On the limbs at least 100 could be counted. None were seen about the trunk or neck.

Except that on the right ear, all the tumours exhibited nearly the same characters. They appeared as little flattened, rounded, firm, slightly prominent, insensitive patches. Sections were hard, white, and dry, no liquid exuding even on pressure. Under the microscope they showed the histological characters of fasciculated fibromata.

Palpation, percussion, and auscultation revealed nothing abnormal in the abdominal and thoracic organs. The urine was albuminous. Examination of the blood showed it to be healthy.

I kept this patient for a time. At first it remained in good condition, eating well, and not appearing to suffer in any way. Later it became dull, lost its appetite, had attacks of vomiting, suffered from diarrhœa, rapidly lost strength, and died in very thin condition. At the *post-mortem* examination we found cystic degeneration of both kidneys; there was no new growth in the viscera, or in the different tissues.

The tumours were exclusively confined to the skin and connective tissue of the extremities, head, limbs, and tail.

For several weeks both patients received iodine and arsenious preparations given alternately. No improvement followed. I have often tried these drugs in other animals—horses and dogs—affected with various new growths, and in several cases of lymphadenoma; but always with the same want of success.

PART II.

MEDICAL PATHOLOGY AND PRACTICE.

XIX.—ACUTE ENDOCARDITIS IN THE HORSE.

For the past half-century acute inflammation of the endocardium in animals has been the subject of interesting researches, among which those of MM. Leblanc and Trasbot merit special mention. It is still generally regarded as a very rare affection, partly because it is frequently overlooked, partly because of the conditions under which it usually develops.*

The published clinical records on this subject refer to various forms of the disease, such as primary endocarditis, traumatic endocarditis, and endocarditis *à frigore*, and secondary endocarditis, especially of rheumatic character. In the horse, as in other animals, primary endocarditis when occurring must be of exceptional rarity. I have never seen a case; all that have come under my notice were examples of acute secondary endocarditis, the majority in animals suffering with or convalescent from pneumonia. I will describe two cases.

Last winter I had an opportunity of examining a case of pneumonia, in which the pulmonary disease was complicated with endocarditis. The history of the case is shortly as follows:

One morning towards the end of January the animal left a portion of its first feed, and, although it was put to work, the coachman noticed that it was dull, appeared tired, and stopped from time to

* In 1863, at the Central Society of Veterinary Medicine, Colin still disputed the occurrence of endocarditis and myocarditis in the horse. He declared he had never seen false membranes on the endocardium, nor valvular insufficiency. He referred the white patches formed by cicatricial tissue, which he had often seen in the horse, to partial ruptures of the muscular fibres.

time; expiration was accompanied by a moaning sound. On returning to the stable it only took a little food and refused its corn. Next day these symptoms were supplemented by cough, and slight discharge from both nostrils. A veterinary surgeon who was called in diagnosed the case as one of commencing pneumonia, bled the animal to the extent of 8½ pints, and prescribed tartar emetic and iodide of potassium. Up to the seventh day, although both lungs were attacked, no alarming symptoms appeared. Between the morning and evening of the eighth, however, the patient's condition became greatly aggravated. I examined it on the following afternoon. Both lungs gave signs of hepatisation; and on auscultating the heart (the action of which was rapid and feeble) I noted a slight soft murmur during the second sound and the pause, a murmur indicating aortic insufficiency. The history of the animal left very little doubt as to the significance of this symptom. Nevertheless, with due reserve—because this murmur might have been due to a valvular lesion anterior to the pneumonia; a not uncommon condition in hard-worked horses—with due reserve, I say, I declared that the endocardium was inflamed, and that the sudden aggravation in the animal's condition was caused in part at least by this complication. Some days later the animal died.

At the *post-mortem* examination we found, in addition to numerous centres of pulmonary gangrene, lesions of acute endocarditis, which I now submit to you.

On the upper surface of the mitral valves and lower surface of the aortic semilunar valves, principally towards their free margins, you will see little greyish vegetations; some fairly firm, others soft and friable. You will also note that these valves are slightly injected and infiltrated, and that they show no old-standing lesion.

Five years ago I saw a similar case, so far as concerns the ætiology and localisation of the endocardial lesions. In this case also endocarditis of the aortic valves had occurred during the course of pneumonia. The animal recovered, and although final proof that the aortic valves were attacked could not be furnished, as in the first case, it was clearly established by the subsequent symptoms. The pneumonia ended in resolution; but the endocarditis produced chronic lesions. After a short convalescence this horse returned to work. A year later I again examined him, when he was suffering from aortic insufficiency, clearly shown by a strong diastolic murmur. This valvular lesion neither disappeared nor diminished; on the contrary, it ended by producing complications, of which I shall speak in a subsequent lecture.

A fairly large number of cases of acute secondary mitral endocarditis have been published. You might read with profit those published

by M. Trasbot in the *Archives Vétérinaires* for the years 1878 and 1880.

Although the causation and pathology of acute endocarditis are complex, you may regard it as certain that the affection is always secondary, and produced by toxic infection; and furthermore, that it is much more frequently due to pulmonary inflammation than has hitherto been admitted. The endocardium is known to be particularly sensitive to the action of infectious processes, and to be easily injured by microbes and their toxins. In pneumonia, and especially in the contagious form, the lung is the seat of active microbic growth. Infectious agents passing into the still pervious pulmonary vessels have but a short distance to traverse before reaching the heart, and we well know that they are capable of producing disturbance in viscera much more distant from the lung. Suspended in the blood they necessarily pass through the left heart; they may adhere to the endocardium, appearing in such case specially to affect the irregularities, prominences, and folds in the serous coat, especially in that covering the valves, which, as we know, are the most common seat of the lesions of acute endocarditis. This localisation of the process on the valves is evidently due to incessantly repeated "quasi injuries," resulting from the heart's own action, the free edges of the auriculo-ventricular valves during systole, and of the semilunar valves during diastole being violently hurled backwards and forwards. This explains their vulnerability at these points, and the readiness with which they become inoculated when bathed in infected blood.

In addition to surgical infections, strangles, influenza, pneumo-enteritis resulting from bad fodder, glanders, and, in fact, all morbid conditions due to the presence of microbes in the lungs, may be accompanied by endocarditis. The blood may become infected through trifling lesions of the skin or mucous membrane—in fact the points of entry for pathogenic organisms are innumerable, and though sometimes easy to identify, are oftener undiscoverable.

At the autopsy of an old horse, M. Blanc found ulcerative endocarditis consecutive to inflammation of the biliary ducts. A less careful observer would have recorded this as primary in origin, or due to chill.

It should be remarked that the lesions are usually localised in the left heart, *even when the infectious agents enter the veins of the systemic circulation, and therefore first reach the right heart.* This commoner affection of the left heart has been explained in various ways. Some consider it due to the more active function of this part of the organ,

and the more intense strain and rubbing to which the serous membrane is subject. Others declare that, as endocarditis is usually caused by *aërobic* microbes, the superior richness in oxygen of the left heart blood constitutes a predisposing factor. In the horse the predominance of left endocarditis is probably a result of the frequence of pulmonary inflammation, during which the endocardium of the left side is particularly exposed to infection.

Acute endocarditis may be produced by different microbes. In man, where the subject has been much better studied than in animals, the lesions most commonly contain micrococci, staphylo- and streptococci, pneumococci, gonococci, and less commonly Eberth's bacillus, the *Bacillus coli communis*, and the *Bacillus tuberculosis*. MM. Gilbert and Lyon have noted a paracoli bacillus. Weichselbaum discovered a microbe never before seen in other diseases. The same species of microbes have been found in the principal anatomical forms of endocarditis—the vegetating and the ulcerating. The characters of the lesions seem, then, to depend especially on the degree of virulence of the infectious agents. In addition to these, one sees so-called cryptogenic endocarditis, from which pathological agents have not yet been isolated. In endocarditis lesions in the horse Penberthy and Fuchs found micrococci. In a case of tuberculosis I detected the specific bacillus.

Inflammation of the endocardium frequently complicates rheumatism, and is due to the same cause as the arthritis, synovitis, pleurisy, and pericarditis. Apart, however, from the pseudo-rheumatism which follows pneumonia, acute rheumatism is rare in the horse, and endocarditis arising from this cause is much less common than the forms of which I have just spoken.

At the present day we are all agreed as to the extreme rarity of acute primary endocarditis—what has been called endocarditis *à frigore*. Cold alone can no more produce it than can an aseptic injury; its action must be preceded, or accompanied, by some other pathological influence which plays the principal part, that is to say, the entrance of some microbe. Cold here acts as in pneumonia *à frigore*, by diminishing the resistance of the organism, thus favouring infection, the latent centres of which are numerous. Infection may occur through the uninjured membrane of the respiratory tract; experiments seem to have established that various microbes can traverse the pulmonary epithelium without any preliminary lesion, and pass into the circulation by way of the lymphatic channels.

It has been suggested that certain therapeutic or toxic materials, internally administered, are capable of producing acute inflammation

of the endocardium. Digitalis was said to have this effect, especially when given in large doses, intermittently, and for a long time. It is quite certain that such substances can do no more than favour infection.

Traumatic endocarditis, resulting from cardiac lesions produced by infected foreign bodies, is chiefly a laboratory disease. Endocarditis and myocarditis sometimes co-exist, and it has been sought to explain the former on the basis of extension to the serous membrane of inflammation of the heart muscle; but, in most cases of this kind, the muscular and serous tissues are simultaneously attacked.

Depending on its nature, and the species or virulence of the microbic agents which produce it, endocarditis may remain localised, soon lose its infectious character, become chronic, and only produce a few innocent fibrous lesions, being then described as benign (the form most commonly seen in the horse); or it may preserve its original infective, spreading character, when it is known as malignant endocarditis.

I need only rapidly recite the generally accepted symptomatology in order to convince you that this disease has been credited with effects for which it is in no way answerable, but which result from a general infection, of which the endocarditis is only an accompaniment. Profound depression, absolute loss of appetite, high fever, warmth of the skin, acceleration of the chief functions, dyspnœa, violent cardiac action, "purring tremor" (frémissement cataire), metallic heart sounds, sometimes irregularity of the heart, intermittencies, venous pulse, a murmur during the first or second sound; at a later stage, paresis or paralysis, albuminuria, and icterus (produced by visceral emboli); finally, loss of strength and collapse; such are said to be the principal symptoms produced by acute endocarditis, under the varying forms which it may assume.

In point of fact the condition generally passes unperceived, masked by the symptoms of the accompanying disease. When it occurs as a primary affection the general symptoms scarcely differ from those accompanying many other diseases of the viscera. The only special symptoms are those recognised on auscultation, and the sole symptom by which it is identified is the murmur.

This is sometimes systolic, originating in the auriculo-ventricular orifice—a feeble, soft sound, deep in some patients, strong and vibrating in others. In the latter case, which is exceptional, the "purring or vibratory tremor" may be detected by applying the hand over the præcordial region; but the symptom, though mentioned by all authors, is distinctly uncommon. Sometimes the murmur is

diastolic, produced by aortic insufficiency. Finally, at times one first hears a systolic, followed by a diastolic murmur; the diastolic sound always appears at a later stage than the systolic, the lesions of the semilunar valves being of slower development, or progressing less rapidly than those of the mitral. In certain patients the heart-beats occur at regular intervals, only seeming rather stronger than usual, and the pulse is normal or somewhat weak. In others the action of the heart is more or less irregular; intermittencies are rare, and always of brief duration. In the simple forms of acute endocarditis, true palpitation and dyspnœa are not seen at rest; the heart muscle being only affected to a very trifling extent, the lesions do not produce any noteworthy external symptoms. Nevertheless, mitral insufficiency may occur in consequence of weakness, or of paresis of the musculi papillares.

When endocardium and myocardium are simultaneously affected, or when endo-pericarditis exists, the symptoms are more complicated. The descriptions just referred to seem most suggestive of infective endomyocarditis, or of endocarditis preceded, or complicated, by grave pulmonary mischief.

When in vegetative endocarditis the inflammatory growths on the valves are of large size, the same train of symptoms occurs, but in a more marked form. To symptoms indicative of mitral and aortic insufficiency are added others suggesting stenosis of these orifices. And as, furthermore, the risks of embolism are greater than in simple endocarditis, symptoms pointing to obliteration of vessels in internal organs are more frequent. Cerebral embolism—rare in all animals—is rapidly followed by death, or by more or less extensive paralysis; renal embolism produces albuminuria and hæmaturia; intestinal embolism colic; that of an important artery in a limb, lameness, and sometimes, more or less extensive gangrene; that of the spleen, and of some other organs and tissues, gives rise to no visible symptoms.

Malignant ulcerative, or septic endocarditis is recognised, not only by the general signs drawn from auscultation, but by symptoms usually of an extremely grave character, similar to those of a rapidly progressive infection or intoxication, which point to general poisoning of the system by pathogenic organisms, or their toxins. Fever is intense; there is great prostration, rigors, sweating, diarrhœa, albuminuria, hæmaturia, colic, frequent groaning, cyanosis of the mucous membranes, rapid acceleration of the heart's action, loss of pulse, and sometimes local hæmorrhages. The symptoms soon become more marked, and collapse is followed by death. This endocarditis may be due to the presence of one or more species of organisms, but is always

exceedingly infective, and its real nature is often misinterpreted, until after death.

In animals, the changes shown by the endocardium after acute inflammation are very diversified. On reading reported cases of "acute endocarditis" in journals, it is clear that in many instances the changes noted do not justify the signification attributed to them. Cases have been published under this title in which the existence of endocarditis was in no way demonstrated, even by the lesions.

The diffuse reddening of the serous membrane, the ecchymoses, the irregular blackish patches, even the little fibrinous grains which have been found, are by no means sufficient indications on which to base the diagnosis of acute endocarditis. Diffuse reddening of the endocardium results from staining with altered hæmoglobin, derived from red blood-corpuscles destroyed during the course of certain infectious processes. The other lesions are not infrequently seen in horses which die from over-exertion, especially in extremely hot weather. They also occur when death is preceded by violent struggling and long-continued agony.

In the ordinary form of acute endocarditis the serous membrane is thickened or elevated in places, has lost its polished appearance, is covered with little, friable, greyish or reddish vegetations, at times capped with a fibrinous layer, and marked at the seat of these lesions and for some distance round them by fine branching vessels. There is nothing more. These lesions sometimes extend over a considerable portion of the endocardium; they commonly affect the valves, and are there always most marked. They are generally confined to the left heart. The mitral and aortic valves are swollen, irregularly thickened, often covered with little sessile vegetations adherent to and continuous with the membrane, some greyish in colour, others of a light red; sometimes very small, very numerous and almost confluent; they give the membrane a roughened appearance. In the specimen I exhibit, you see they are collected at a short distance from the free border of the valve. In many cases they first appear in the vascular portion of the valves, and extend thence towards the free margin; where they attain the free edge of the valves the endocarditis is termed marginal. The abnormal coloration is not removed by washing, and closer examination of the patches, especially of their circumference, reveals little vascular loops; but the reddish-brown or blackish tints which appear so rapidly in inflammation of richly vascular organs are rarely seen. The majority of these vegetations are covered with a fibrinous deposit seldom very adherent. On removing it the serous membrane appears superficially eroded.

At one time new growths on the endocardium were always regarded as fibrinous. They are really formed of embryonic cells and leucocytes, held together by a small quantity of structureless exudate. Beneath and around them the endocardium appears infiltrated with similar cells, the number of which diminishes in proportion to the distance from the vegetation. The persistence of the endothelium over the surface of certain deposits indicates that the process develops partly in the deep layer of the serous membrane; as a rule, however, the superficial layer is first loosened, and afterwards destroyed. There is little or no discharge from the point; acute endocarditis is proliferative, not exudative. When the chordæ tendineæ are invaded, or that portion of the endocardium into which they are inserted is affected, they may snap or become detached from their insertion—an accident sometimes followed by mitral insufficiency. When the inflammation extends from the deep layer of the endocardium to the heart muscle itself, it always remains limited to a very thin stratum. It is possible, however, as I before stated, for both the muscle and serous membrane to be simultaneously affected, and during infectious diseases this occurs more frequently than might be imagined from the few cases published.

Vegetative, or verrucous, endocarditis is characterised by the abundance and size of the granulations developed on the endocardium. The proliferation of cells and exudation of leucocytes rapidly produce luxuriant vegetations, varying greatly in size and shape. In this case, also, the valves show the maximum of development. Sometimes the growths resemble branching stalactites, covered with conical prolongations, the long axes of which correspond in direction with that of the blood-stream; those fixed to the mitral valve pointing towards the base of the ventricle; those on the semilunar valves towards the aorta. These large new growths are composed of cells, etc., similar in nature to those forming the limited vegetations of simple endocarditis. They usually show a superficial fibrinous, and a deep organised layer, the latter continuous with the endocardium; some, however, are organised nearly throughout; others are almost exclusively fibrinous. Such large new growths are rare in the horse, but are commoner in the dog. Not only do they diminish the size of the orifices around which they are situated, and thus produce functional disturbance, but they threaten embolism of internal organs. Incessantly agitated by the blood-stream, the fibrinous coagula covering these vegetations may become detached and carried to a distance, produce infarcts in the viscera and in various tissues, thus giving rise to symptoms of very varying gravity. Under the influence

of active microbic growth, or of degenerative changes, the vegetations may break down suddenly, throwing into the blood-stream large numbers of fragments, which produce multiple, simple, or specific embolisms, and in some cases rapidly progressive septicæmia.

In ulcerative endocarditis (which is still rarer than the preceding) the serous membrane shows loss of substance; true ulcers may develop on the walls of the ventricles, or on the valves; most frequently on the mitral. Starting in the endocardium, and at first limited in extent, these ulcers extend more or less rapidly in size and depth, and may perforate and partially destroy the valves. When affecting the parietal endocardium they sometimes extend beyond its deep layer, erode the myocardium, and produce a kind of aneurism.

Visceral complications due to emboli are frequent. The blood is charged with micro-organisms, masses of cells, and broken-down material from the ulceration, and is greatly changed in character. Pyæmic or septicæmic lesions are not infrequent.

In acute endocarditis affecting the valves diagnosis becomes possible as soon as a murmur develops. When, however, localised in the parietal endocardium or affecting the valves, but without causing insufficiency, detection is impossible. It is perhaps well to repeat that even when alarming general symptoms occur, suggesting acute endocarditis, the existence of a murmur is of doubtful significance, and may be due to old-standing heart disease, the accompanying disturbance resulting from some other affection, such as pneumonia. In most cases minute examination of the patient is necessary before giving an opinion, and sometimes a few days must be allowed to elapse for the condition to develop.

The prognosis of acute endocarditis is very grave; although in the horse it may not prove fatal, it produces lesions which are not only incurable, but which become more marked with lapse of time, and often make rapid progress when animals are put to heavy work soon after leaving hospital.

Treatment is of little value. Bleeding, counter-irritation, and the internal administration of digitalis, salicylate of soda, iodide of potassium, alcohol, and diuretics have been recommended.

When endocarditis appears during the course of another disease, a general infection or a microbic disease of any kind, it forms a menacing complication; but treatment should still be principally directed against the primary morbid condition, and not against the complication.

The belief that acute endocarditis can be cut short by any system

of medication is a pure illusion. Even rheumatic endocarditis, against which we have drugs of a specific character, always passes through its various phases, and leaves permanent lesions in the endocardium. In a certain number of cases we can diminish the intensity of the inflammatory process in the endocardium, moderate development of new growths, and consequently reduce the dangers of embolism and of visceral thrombosis; but that is the full extent of our powers. Even then success is distinctly problematical.

In primary and secondary endocarditis it is usual first to bleed and apply counter-irritants. Six to ten pints of blood are withdrawn, and a large mustard plaster applied to the lower half of the chest; or the left surface of the chest over the heart is blistered. Some authors claim to have had good results from continued irrigation of, or application of ice to, the præcordial region.

Internally the most useful agents are sulphate of quinine, given in electuary in doses of 2½ to 5 drachms per day; and in the rheumatic form, salicylate of soda in doses of 5 to 10 drachms.

Digitalis, empirically prescribed in all cardiac diseases, is here of real use if the rhythm of the heart is irregular, or if myocarditis has accompanied or followed inflammation of the endocardium; it regulates the action of the heart muscle. At the end of some days moderate doses of potassium iodide have a good effect, appearing to favour absorption of exudates. If fever is high antipyrin and cold enemata may be given; when weakness is marked, stimulants and antiseptics seem indicated.

In his *Leçons sur les Antiseptiques* M. Bouchard draws attention to the good effects produced by internal administration of antiseptics in many microbic diseases. In infectious forms of endocarditis the ideal method of treatment would consist in destroying the organisms in or on the endocardium. At present this is impossible, but by using antiseptics we can arrest or diminish many primary infectious processes, of which endocarditis only forms a complication.

XX.—AORTIC INSUFFICIENCY IN THE HORSE.

To-day we saw in the clinique a horse with very well-marked aortic insufficiency, and I mentioned to you in some detail the peculiarities shown by the animal. I have had opportunities of seeing a very considerable number of similar cases. To-day I intend to treat of this condition, and while describing certain cases, to point out the diagnostic symptoms.

In the horse aortic insufficiency is by far the most frequent of all heart diseases. It may be seen in animals of all ages, without distinction of sex or breed, though the majority of published cases refer to old animals slaughtered for experimental or anatomical purposes. In animals of this class M. Nocard and I found thirty-eight aortic and four associated aortic and mitral lesions in a total of forty-two cases.

Aortic insufficiency sometimes forms an isolated lesion, sometimes an accompaniment of other lesions of the endocardium, or of arterial atheroma. In man, where the latter condition is very common, aortic insufficiency of cardiac origin, consecutive to endocarditis, is distinguished from insufficiency of arterial origin associated with sclerosis of the arteries. In the horse valvular lesions are sometimes accompanied by atheroma of the aorta, but very generally atheroma is absent, and the valvular disease simple, or only combined with other valvular changes.

With very rare exceptions, it results from some infectious process, during which the endocardium has been injured by blood-borne micro-organisms, or their toxins. It may also follow acute inflammation of the lung, especially the contagious form, and the typhoid form of influenza. Rheumatism, which, as you know, is rare in the horse, also appears to produce it. In human medicine it has long been known that rheumatic lesions appear to have a decided predilection for the endocardium, etc., which they permanently affect. "Rheumatism," said a celebrated clinician, "licks the joints, the pleura, and even the meninges, but it gnaws the heart."

Whatever the determining cause, inflammation of the semilunar valves soon assumes a chronic character, and determines a series of

changes ending in insufficiency. These changes may assume very varying anatomical appearances. You may judge of this by examining the specimens I place before you. Sometimes the valves are simply thickened, rigid, wrinkled, and shrivelled; sometimes they show losses of substance, giving them a reticulated or fenestrated appearance; in some cases they exhibit aneurismal dilatations, projecting above the surface of the heart, the wall of the aneurism being either intact or perforated; in others, again, they are fungous and covered with pea-like or strawberry-like vegetations; finally, they may contract adhesions one with the other, or with adjacent tissues. Usually these lesions are unequally marked on the three valves; sometimes they

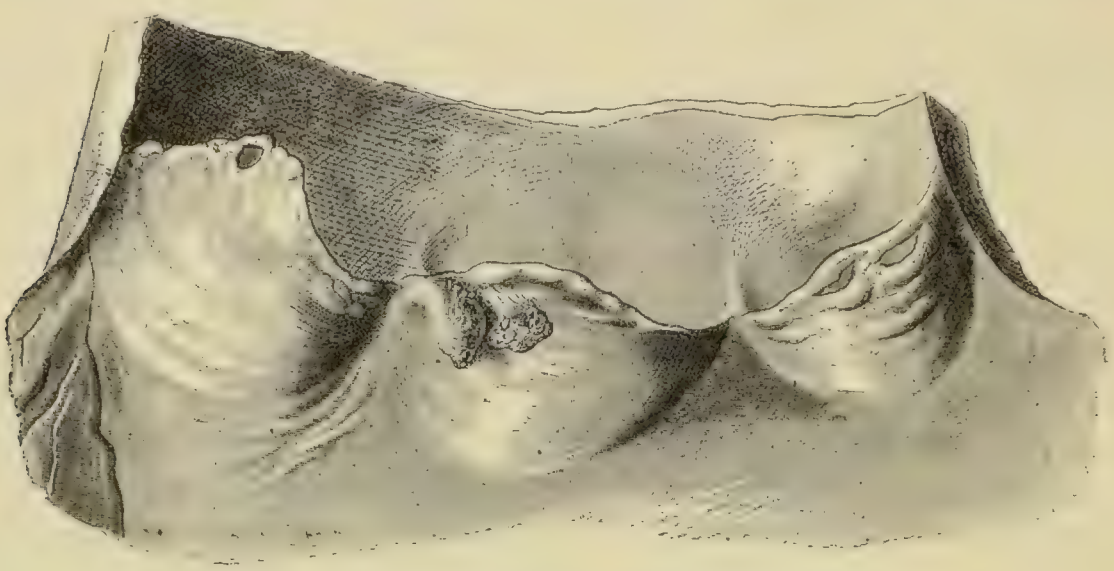

Fig. 16.—Chronic endocarditis of the aortic valves.

only affect one, though even in this case they may be very pronounced.

The valves never close completely, an opening of varying form and size remaining between them through which blood regurgitates. When the aortic ring has not been divided the insufficiency can readily be detected. After removing its lower third, one has only to place the heart in a vertical position, and to pour a little water into the aorta; the valves no longer closing exactly, liquid escapes by the space between the valves, and passes into the ventricle.

These changes in the aortic opening are always accompanied by a certain degree of hypertrophy of the left ventricle, consequent on insufficiency, and due to a very simple mechanism. After each systole, the blood injected into the aorta, which should be retained by closure of the semilunar valves, returns in part into the ventricle. This returned blood being added to that coming from the auricle, two abnormal conditions successively arise; the ventricle dilates excessively,

and then contracts with a degree of energy greater in proportion to the quantity of blood which it contains, and to the diminution in the arterial pressure in the common aorta. Now this more active contraction of the left ventricle is repeated about 50,000 times per twenty-four hours. The increase in work ends by causing hypertrophy of the cardiac muscle, which, for a certain time at least, renders the heart capable of overcoming the increased demand imposed on it by the condition of the valves, but which culminates in the period of asystole; the heart muscle, enfeebled by over-exertion, undergoes degenerative changes, finally leading to death. The heart may attain very great dimensions. Whilst the medium weight for a healthy heart is about $\frac{1}{125}$ that of the whole body, a heart with aortic lesions and insufficiency often attains $\frac{1}{100}$ to $\frac{1}{80}$ of this weight. Sclerotic changes of the muscular substance are rare, because most patients are slaughtered before they can develop. Nevertheless I have seen a certain number of cases in the school, one of which I will describe in a later lecture.

Aortic insufficiency is indicated by two principal symptoms: (1) a diastolic murmur, loudest at the base of the heart; (2) a strong pulse, readily perceptible in all accessible arteries.

The murmur commences with diastole, and continues during the second sound, and a portion, or the whole, of the pause; it immediately follows the short pause, at the moment when the semilunar valves have returned to their horizontal position, and continues until the first period of the following cardiac cycle, *i. e.* until the præcordial impulse produced by ventricular systole. I said that it was loudest at the base of the heart; it may also be heard, though less distinctly, as low as the apex, and more rarely in the region above the heart over the aortic trunk. The tone (timbre) of this murmur varies; usually it is soft and hissing; sometimes it is rough, grating, or musical. I may add that no close connection can be established between these variations in sound and the age, degree, or peculiarities of the valvular lesions.

The changes in the pulse are due to the energy with which the ventricle contracts, and to the low blood-pressure in the arterial system. The large wave of blood rapidly injected into relaxed vessels lifts their walls suddenly, and to a greater degree than normal; but, as considerable quantities immediately leak back towards the ventricle through the pervious valves, the vessels again collapse, a fact which gives the pulse its peculiar fugitive, elusive character. The pulse is readily discovered by the finger in all accessible arteries, but only in exceptional cases can it be *seen*. Few cases of "dancing of the arteries"

have been chronicled in veterinary literature, the most interesting being that by Polansky. To those recorded I could add several, one of which I saw here during the present year. My assistant will read you a summary.

CASE I.—A fourteen-year-old gelding. For some weeks the animal had fed badly, shown difficulty in breathing, and rapidly become fatigued during work. Examination of the digestive and respiratory organs revealed nothing abnormal. On auscultation of the heart, we heard on both sides, but more particularly on the left, a rough metallic murmur, beginning with diastole and extending throughout the whole pause; almost as distinct at the apex as at the base of the heart, and extending above and behind the latter as far as the middle of the chest. The first sound and the short pause were normal. The second sound was absent.

The arterial circulation was greatly disturbed. The pulse was very strong at the submaxillary, and could readily be detected at all the superficial arteries—the temporal, masseter, posterior auricular, submaxillary, radial, coccygeal, metacarpal, and digital. At the lower portion of the jugular furrow a distinct carotid pulse was seen at each systole. The small superficial arteries, but especially the temporal and metacarpal, bounded at each contraction of the heart; there was a true "arterial dance." Examination of the aorta only revealed violent pulsation, but no murmur.

With this patient we only received the following information:—"For some time it had eaten less than usual, and became fatigued on the least exertion." After glancing at the buccal cavity and conjunctiva, I examined the pulse at the submaxillary; it was strong and bounding. On auscultating the heart I noted during the second sound and pause a rough metallic murmur, most distinct at the base, but audible (though less clearly) towards the apex and along the course of the aorta for a height of about eight inches. The horse was suffering from aortic insufficiency. Up to this point the case revealed nothing extraordinary, but, while again taking the pulse at the submaxillary, I happened to glance towards the temporo-maxillary articulation, and then noted that each time the submaxillary dilated under my finger the subzygomatic visibly bounded. The other superficial arteries showed the same phenomenon, especially the two carotids, at the lower portion of the jugular furrows, and the metacarpals. On that day I was only able to make a rapid examination, and unfortunately the patient was not brought back.

Here, in very condensed form, are three similar cases observed among horses in hospital, or in the external clinique.

CASE 2.—Ten-year-old entire horse. When submitting this animal for examination the owner gave the following information. The horse was "soft" in work, soon got short of breath, and stopped when ascending hills.

On auscultating the heart we noted a remarkable change in the sounds. The first was strong, prolonged, and with a tendency to reduplication. The apex-beat was violent. The short pause was followed by a murmur which replaced the second sound, and was prolonged throughout the long pause. This diastolic murmur was soft, clearest opposite the base of the heart, less marked towards the lower parts of the chest and around the apex.

The pulsations were normal in number, the artery was tense, the pulse very strong, bounding, and slightly dicrotic. The pulse could be visibly counted at the subzygomatic artery. It was also very readily felt at the digital artery. Pulsation of the gluteal ? (*artère fessière*) arteries was visible towards the centre of the quarter on either side. Auscultation of the posterior aorta failed to reveal any abnormal sound. A jugular pulse could be detected. The animal was emphysematous.

CASE 3.—A twelve-year-old gelding. For some time the animal's appetite had been bad. The driver stated that it did not stop during work, but breathed very heavily. On examining the heart we detected a murmur during the second sound, and the pause was most distinctly marked opposite the base. Furthermore, each third heart-beat was followed by an intermittency lasting from three to four seconds. The pulse was strong and bounding. It could be seen at the subzygomatic artery, where the vessel passes under the ridge of the maxilla.

CASE 4.—A mare about fifteen years old. A week before, this mare, which usually had an excellent appetite, ate badly, and left a portion of her food.

Clinical examination discovered no disturbance of the digestive apparatus. On auscultating the heart a strong, rough, prolonged murmur was heard, to which succeeded a normal sound—at first regarded as the second heart-sound, but at the moment that the normal sound occurred the ear clearly perceived the sensation of systolic contraction. What had been regarded as the second sound was therefore in reality the first. I heard in succession the first sound,

the short pause, and finally the murmur which covered the second sound, and was prolonged throughout the long pause.

The pulse was very strong, but was not, however, visible at the superficial arteries. By placing a stethoscope over the carotid towards the lower part of the neck a diastolic murmur could be heard. On auscultating the aorta no abnormal sound was detected.

In horses suffering from aortic insufficiency the pulse is almost always strong. You will sometimes find it of normal volume, but rarely feeble. Only a moment's reflection on the changes produced in the heart by aortic insufficiency is required to show that the pulse cannot be feeble so long as the heart muscle continues its function actively.

Aortic insufficiency produces a number of other symptoms, though they are not special to it. Like all diseases of the heart, it is accompanied sooner or later by functional troubles, the most important of which are rapid loss of breath when at work, dyspnœa, pain (causing the animal to wear an anxious look), and a tendency to vertigo. When animals are kept sufficiently long, disturbance of the pulmonary circulation may be noted; passive congestion of the lung in consequence of mitral insufficiency, which again is due to dilatation of the left ventricle, and mechanical enlargement of the auriculo-ventricular orifice; later still, passive congestion of other viscera, resulting from degeneration of the heart muscle and exhaustion of the heart. But in few horses is the process allowed to reach its last stage, the animals usually being slaughtered as soon as they become incapable of sustained work.

Sudden death following arrest of the heart is rare in horses with aortic insufficiency, though it may occur. I will give you an instance. Five or six years ago a colleague asked me to examine an old cart-horse, which he considered broken-winded. At work the animal's breathing soon became embarrassed, especially when climbing hills and during hot weather, but the cough was not that of emphysema. On auscultating the heart I diagnosed aortic insufficiency, which was clearly indicated by a strong musical diastolic murmur. As other severe constitutional symptoms had existed for a considerable time, my prognosis was grave. The animal worked for a further period of three years. Several times it fell down, but at once rose again, gradually recovered, and after twenty-four hours' rest resumed light work. Finally, one hot day, it fell in the shafts and died in a few moments.

The diagnosis of aortic insufficiency is easy. The two symptoms

on which I have laid stress—the diastolic murmur and the bounding pulse—are absolutely characteristic. In certain cases, when the heart's impulse is weak and the murmur very loud, it may be regarded as systolic. I have often corrected this error. In order to avoid it one need only trot the animal for a few moments. The impulse of the heart becomes very marked, and no doubt can exist of the diastolic character of the murmur. The most useful indications may, however, be wanting. Some animals with valvular lesions and insufficiency continue work as usual without showing dyspnœa or weakness; it is not until later that functional troubles attract attention. Aortic insufficiency cannot well be mistaken for any other disease of the heart. In the horse insufficiency of the pulmonary sigmoid valves is extremely rare, and the pulse (which is sometimes small) differs entirely from that of aortic insufficiency.

The prognosis is grave, not only because the condition causes immediate danger and may produce death in a very short time, but because it generally interferes to a large extent with the animal's usefulness. As a rule animals suffering from it pass successively into the hands of poorer and poorer owners, who expect more and more work.

Some lose condition rapidly, others retain it for a considerable time. In all, the normal vigour and working powers steadily diminish; when the patients become incapable of further work they are usually slaughtered. Most of them, however, are sold and resold several times before death. This is evident from animals being brought here at intervals of a few weeks after having changed hands. In 1890 one was thus brought on three separate occasions during a single month. A little later we saw it again—this time amongst the animals purchased for surgical exercises.

Like all other chronic valvular changes, those of the aortic semilunar valves producing aortic insufficiency are incurable. Treatment is purely palliative. The principal drugs employed are the iodides of potassium and sodium, given for periods of two to three weeks; and when signs of cardiac failure appear, digitalis and diuretics.

XXI.—MITRAL INSUFFICIENCY IN THE HORSE.

At the present time we have in stable No. 4 a horse with mitral insufficiency of considerable standing, in which the clinical signs are so well marked as to leave no doubt regarding the prognosis. Although the horse is incurable, we have permission to detain it for some days. I have particularly drawn your attention to it, and profiting by the opportunity offered, I intend this morning to speak of chronic mitral endocarditis, and to relate an interesting case.

The principal symptoms shown by our patient may be summarised as follows :—A loud systolic murmur perceptible over an extensive area on both sides of the chest, of greatest intensity towards the middle portion of the heart, and very clearly audible on applying the ear over the caput muscles ; a feeble, irregular, intermittent pulse, cardiac intermittency alternating with two or three rapid irregular heart-beats ; finally, loss of breath and dyspnœa after a few moments' exercise. With these facts before us diagnosis is easy. We have to deal with a case of old-standing mitral insufficiency in which the period of compensation is past, and which is complicated by changes in the muscular tissue of the heart.

In the horse, chronic mitral endocarditis is less frequent than aortic insufficiency. Its ætiology is that of all valvular changes. With rare exceptions it results from acute endocarditis complicating certain infectious diseases. In solipeds these are generally represented by strangles, one of the various forms of pneumonia, or by the typhoid form of influenza, which almost always gives rise to acute endocarditis and to valvular changes.

Inflammation of the mitral valve produces changes which finally render it insufficient ; the flaps become irregularly thickened, contract, draw apart, and cease to entirely close the opening. The chronically inflamed mitral valves show less varied and less deep anatomical changes than the aortic valves ; it is exceptional to see centres of

degeneration, vegetations, aneurisms, perforations, partial ruptures, or adhesion between a flap and the ventricular wall. With the exception of a case of rupture of the principal valve, of two others where a small aneurismal depression existed, and of a few cases of rupture of one or several of the chordæ tendineæ, I have never met with anything more than sclerotic changes—thickening, folding, and more or less pronounced contraction of the valves of the auriculo-ventricular opening.

But the anatomical peculiarities which mitral lesions exhibit are not of great importance; what dominates the after consequences, the intensity of the symptoms, and the rapidity of their succession is the degree of insufficiency. Once insufficiency is established, the cycle of vascular troubles commences. What are these troubles?

The mitral valve incompletely closing the auriculo-ventricular orifice during ventricular systole, the blood makes its exit from the left ventricle by two orifices; (1) by the normal aortic opening, and (2) by the abnormal auriculo-ventricular opening, resulting from insufficiency of the mitral valve. At each heart-beat a portion of the blood which should pass into the aorta escapes by the auriculo-ventricular hiatus, and enters the left auricle. The first effect of this reflux of blood under pressure is to dilate the affected auricle, which, in order to overcome the distension, becomes hypertrophied. During a period of variable duration, termed the compensation stage, matters rest thus, and the primary lesion produces no functional disturbance likely to attract attention. At the autopsy of horses dead of accidents or internal disease, lesions of the mitral valve, sufficiently developed to cause insufficiency, are sometimes found, without during life having attracted any attention whatever. Up to the last moment the animals have been able to perform ordinary work.

Here is a case of compensated mitral insufficiency seen in a horse which died from rupture of the stomach.

A ten-year-old Percheron horse, which had worked very hard for some years, but the general condition of which had always been satisfactory and the health good, was brought to the College on account of impaction of the stomach, from which it finally died. At the *post-mortem* examination we found, in addition to ruptured stomach, an enlarged heart. The left auricle was greatly dilated and its walls thickened. On opening the left ventricle we detected old-standing mitral lesions. The anterior and the left valves were little changed, but the principal flap was thickened and contracted, and exhibited at its right extremity an irregular fibrous vegetation; the right valve was shrivelled, and showed near its free borders a large hardened area. The right heart was normal. These mitral lesions certainly caused insufficiency.

Nevertheless the animal had been able to regularly perform trotting work up to the day of its death. Although the mitral changes were of old standing, they had been compensated. The increased functional activity of the left auricle had proved sufficient to overcome the obstacle resulting from the valvular lesion, and to prevent the appearance of symptoms which would have betrayed the altered conditions.

As a rule, this phase of mitral insufficiency, where regurgitation of blood is confined to the left auricle, is not of long duration. The pulmonary veins soon become engorged and dilated; stasis gradually extends to the pulmonary capillaries, the main arterial trunks of the pulmonic circulation, and the right ventricle. In turn the right ventricle becomes distended, with or without its walls hypertrophying; then, on account of the tricuspid insufficiency which follows, the right auricle undergoes similar changes. These disturbances extend to the veins of the greater circulation, to the portal system, to the systemic capillaries and to the whole arterial system. The increased tension in the latter is finally felt in the left ventricle, which, being overworked, becomes dilated and to a certain extent hypertrophied.

Such is the cycle of troubles produced by mitral insufficiency. The heart is their point of origin, and the object on which in the last instance they react. But very rarely indeed are they allowed to develop in their entirety in working animals, the patient being almost always destroyed when incapable of further work, that is, as soon as blood-stasis in the pulmonary capillaries produces grave respiratory disease.

Let us now consider the changes which occur, first in the lung and then in the other viscera, under the influence of blood-stasis.

The effects produced by dilatation of the pulmonary vessels and retardation of the blood-current through them grow rapidly in importance. The capillaries become varicose, their walls thinned, and the nutrition of the cells composing them suffers. Congestion of the bronchial mucous membrane follows distension of the pulmonary capillaries, and by diminishing the calibre of the air conduits tends to produce dyspnœa. Blood-plasma filters through the thin vessel walls and becomes extravasated, partly into the alveoli, partly into the pulmonary tissue itself. In time pulmonary œdema increases; in places induration may occur, and disseminated centres of interstitial pneumonia appear. The respiratory surface is thus considerably diminished, oxygenation of the blood becomes very imperfect, and dyspnœa follows.

As soon as general venous stasis occurs internal organs become

congested, transudation takes place into the splanchnic cavities, and œdema appears about the lower portions of the body.

In consequence of its position close to the heart, and of the richness and peculiar arrangement of its vascular supply, the liver is the first of the viscera to be affected. Stasis in the posterior vena cava first reacts on the hepatic and intra-lobular veins, then on the capillaries and interlobular or perilobular vessels. In the first stage the changes are simply congestive; the liver is very large and engorged with blood, and incisions show a marbled appearance, a crowd of little blackish points being scattered over a lighter ground. All the lobules show the same abnormal appearance; the central portion, dark in colour, is formed by the enlarged orifice of the intra-lobular vein; the periphery is whitish or greyish white. To this peculiar modification of the hepatic tissue, seen in old-standing diseases of the heart, has been given the name of cardiac or nutmeg liver. The microscope shows dilatation of the intra-lobular veins, enlargement of the capillaries, and more or less pronounced compression of the hepatic trabeculæ throughout the entire area of the lobules. At a more advanced stage inflammatory supplement the preceding phenomena. Examined with the naked eye the liver is still large, consistent, and spotted. The microscope reveals diffuse sclerotic lesions, both in the inter- and intra-lobular regions, the walls of the intra-lobular veins are thickened, and appear as though surrounded by a connective-tissue sheath; the portal spaces are slightly enlarged by trifling hyperplasia of the same character, which in time may extend to the entire periphery of the lobules. Deformed first of all by dilatation of the hepatic capillaries, and then compressed by this double series of new growths within and around the lobules, the hepatic cells undergo fatty degeneration. Does hepatic congestion of cardiac origin in the horse ever end in rupture of the liver? This has been affirmed, and some cases have been recorded. In the *post-mortem* examinations I have made the liver has always appeared simply congested, or firm, consistent, and more or less cirrhotic. Where rupture has occurred in horses with heart disease it seems possible that special degenerative changes had existed side by side with those due to circulatory disturbance. This point has not yet been carefully studied.

Although much less pronounced than those of the liver, the changes undergone by the intestine and stomach are not less evident. As soon as the portal circulation is impeded the mucous membrane of these organs becomes passively congested, the muscular tissue loses power and acts less energetically, and gastro-intestinal catarrh may develop. Like the liver, the spleen first shows simple passive con-

gestion, but later inflammation occurs, producing new connective-tissue growth and sclerotic changes. The capsule becomes thickened in places, or covered with little fibrous tufts.

The kidneys are affected in their turn by the stasis in the vena cava, but at first, and for a certain time, only show congestive changes. They are slightly larger and of deeper colour than usual; but even at this stage the microscope may show proliferation of the epithelium lining the straight tubules. At a later period interstitial nephritis here and there produces atrophy of the uriniferous tubules, and formation of tracts of fibrous tissue, contraction of which renders the surface of the organ irregular and knobby. In sections of this "cardiac kidney" the Malpighian tufts appear injected and slightly prominent. At certain points the tissue is hardened, whitish in colour, and of lardaceous appearance.

A time arrives when the various organs, including the brain and spinal cord, and all vascular tissues feel the effects of this distension of the general venous system; but dropsy, œdema, and inflammation of the meninges, generalised hardening of extensive tracts of tissue and skin lesions are final complications which only appear at a very late period. Ascites, hydrothorax, and hydropericardium are usually too little marked to be recognised during life. Changes in the blood, such as diminution in red blood-corpuscles, and alteration of the plasma, also belong to the group of later complications. They slowly become more marked, and lead to cardiac cachexia.

Whether chronic mitral endocarditis follow acute inflammation, or appear as a primary condition, its onset is always insidious; even when the mitral valve is contracted and insufficient, no special disturbance may exist to attract attention, provided the insufficiency is compensated.

This latent period terminates as soon as the lungs become engorged. Then the patients rapidly lose breath at work, and show symptoms which are usually referred to broken wind. Many fail to come under the veterinary surgeon's notice until an advanced stage, when the symptoms are already so numerous as immediately to suggest heart disease. Moreover the animal's history is often sufficient to arouse such suspicion. When examining an animal apparently in health, but the history of which tells of weakness, diminished capacity for work, sweating, rapid loss of breath after moderate exercise, lying down immediately on returning to the stable, capricious appetite, or total loss of appetite; then, provided these symptoms have existed for a certain time, one should suspect heart disease whatever the animal's age.

The two principal signs of mitral insufficiency are a systolic murmur and feebleness and small size of the pulse. On auscultating the heart one hears a murmur commencing with systole, covering the short pause, and ending with the second sound; the latter and the long pause are usually normal. This murmur may extend not only over the base, centre, and apex of the heart, but over a considerable area of the surrounding parts. It is clearly a mistake to say that it is heard most loudly over the apex. Being due to reflux of blood from the left ventricle into the auricle, it is produced in the auriculo-ventricular opening, which is situated about one and a quarter inches below the aortic orifice, and about six to eight inches from the apex. The point of maximum intensity corresponds to the depression in the left pulmonary lobe, or to the mesocardiac zone. Like the aortic murmur, it varies greatly in strength and tone, depending on the degree of insufficiency and on the existence or absence of vegetations on the valvular flaps. The configuration of the margins of the valve changes as the process develops, and the character of the murmur may thus undergo modification at uncertain intervals. In one horse which I kept under observation the sound was at first soft, afterwards harder and vibrating. As in the case of diastolic murmurs, the modification in character of systolic murmurs bears no relation to the changes in the valvular condition as determined by *post-mortem* examination. All one can say is that soft murmurs usually denote either trifling or very large insufficiencies, and rough strong murmurs insufficiencies of moderate extent.

The pulse of mitral insufficiency contrasts with that of aortic insufficiency. Whilst in the latter the pulsations are strong and bounding, in the former they are feeble, often almost indistinguishable or uncountable. At the moment of ventricular contraction one portion of the blood contained in the left ventricle escapes by the mitral orifice; only a small wave enters the aorta, scarcely lifting the arterial wall, and the pulse is invariably small. For a long time no other change is apparent; but when the valvular lesion has reacted on the heart muscle a want of rhythm becomes apparent; the cardiac contractions and the pulse at first become unequal; later, intermittences occur, alternating with the series of normal heart-beats. In one of the patients of which I have spoken disturbance of the circulation could be detected, pointing to change in the heart muscle or to a cardiac complication of the mitral disease.

The other symptoms which occur result from stasis of blood in the viscera. Passive congestion of the lung produces oppression, dyspnœa, cough, and later bronchorrhœa. In some subjects reflex disturbance

is brought about through the medium of the pneumogastric nerve, as shown by irregular or complete loss of appetite, anxiety, somnolence, or depression. Transudates in the large serous cavities, œdema of the lower portions of the body, intestinal catarrh, icterus, and albuminuria only appear at an advanced stage.

I may repeat that chronic mitral endocarditis with complications due to stasis in the veins of the systemic circulation is rarely seen, the patients not being kept sufficiently long for such remote complications to occur. Last summer, however, we saw a case which I will recall to you.

In the month of June a farmer at Bonneuil sent us a horse, bought the preceding year, which for months had appeared in good health, but about six weeks before had begun to fall away in condition, and had up to that time lost about 100 lbs. in weight. One day an œdematous swelling was seen under the chest, but nothing else being observed no precautions were taken, and the horse drawing a heavy wagon set out from Bonneuil for Maisons-Alfort. During the journey it frequently stopped for want of breath, and was thrashed by the brute who drove it. On returning to the stable it lay down without touching its food.

The morning after it was brought to the clinique. It was very thin and depressed; the mucous membranes, and especially the conjunctivæ, were pale. The respiration was rapid, irregular, and showed a well-marked double expiratory effort; but the cough was strong and loud, in no way resembling that of emphysema.

Percussion of the chest revealed diminished resonance in the lower third, especially on the left side. On auscultation the respiratory murmur was feeble. The heart beat rapidly, and on examination two murmurs could be heard, one systolic, the other diastolic; while irregular intermittences lasting for one or two pulsations could be detected. Certain of the contractions were bounding, and gave a distinct impulse to the thoracic wall. The pulse was small, unequal, and intermittent. The pulsations of the posterior aorta corresponded to the beating of the heart, were unequal, and 70 to 76 per minute. Each heart-beat produced an aortic pulsation, but the more feeble were not transmitted to distant arteries. The jugulars were prominent, and showed a pulse synchronous with the heart. The swelling under the chest had almost disappeared. The temperature was normal. The urine contained neither albumen nor sugar.

These symptoms, the known frequence of left heart disease in the horse, the absence of the arterial sign of aortic insufficiency—

Corrigan's pulse,—and the signs of dyspnœa produced by a few minutes' exercise, led me to diagnose old-standing mitral endocarditis with insufficiency. On the other hand, the diastolic murmur, the very marked venous pulse, and the œdema indicated dilatation of the right heart, with reflux and stasis of blood in the vessels of the systemic circulation.

I kept this case for a time to afford you an opportunity of following the course of the disease. At the end of a week the hind limbs became swollen. The lower surface of the abdomen and of the chest showed extensive œdema.

The animal was slaughtered. The principal lesions found on *post-mortem* examination were as follows:—The abdominal cavities contained some quarts of a yellowish limpid serosity without fibrinous flocculi. The veins of the systemic circulation were dilated. Over almost its entire surface, but especially along the course of its vessels, the large colon showed abundant subserous œdema. The liver was very large; on incision the condition known as "cardiac liver" was seen to be well developed. The other abdominal viscera, especially the kidneys and spleen, were engorged with blood.

The pleural cavities contained 4 to 5 quarts of serous fluid, resembling that in the peritoneum. The lung was blackish, heavy, and congested; its tissue was in some places œdematous, in others dense and sclerosed. The heart was enormous; the right heart especially had become enlarged; its cavities were greatly dilated, the auricle being almost four times its normal capacity. The left auricle was also much dilated, and the walls of the corresponding ventricle (which were slightly hypertrophied) showed areas of sclerosis. The flaps of the mitral valve, more particularly the principal, were thickened, shortened, puckered, and at certain points of almost cartilaginous consistence.

The course of the morbid condition produced by mitral lesions is fatally progressive. Whether or not insufficiency be complicated by contraction, the circulation gradually becomes impeded, and the resulting symptoms more marked; the general condition steadily increases in gravity, until at last death terminates the case.

Chronic mitral endocarditis being in the long run fatal, how does death occur?

Mitral lesions usually kill slowly. Among the organs (which are all gravely affected) two, the heart and lung, still actively continue their functions. Though first affected, overloaded in the beginning, and in the last stages burdened with the ever-increasing arterial tension, the heart continues to struggle against the growing vascular

obstruction, which finally reacts on the left ventricle. In the lung the useful respiratory surface becomes more and more reduced; the œdema, inflammation, and obliteration of capillaries steadily diminishing the small number of pulmonary alveoli still capable of carrying on oxygenation of blood. Toxic blood completes the disorganisation produced by mechanical disturbance. The heart, already exhausted, is arrested by the increasing asphyxia.

At advanced stages of mitral disease death may occur rapidly by another process. On account of the slowness of circulation coagulation may occur in the arteries of organs essential to life. This explains how patients sometimes die in a few days, in a few hours, indeed in a few moments, either from thrombosis of the coronary arteries or from thrombosis or embolism of the pulmonary artery. Sudden death, however, is rarer than in aortic insufficiency.

The diagnosis of mitral insufficiency offers little difficulty in the horse. Tricuspid insufficiency (which is much less common) is almost always brought on by dilatation of the right heart, consequent on chronic pulmonary affections, especially old-standing emphysema. It is soon accompanied by a well-marked venous pulse, and the tricuspid systolic murmur, usually softer, less prolonged than the mitral sound, is also heard at a more anterior point. With a little practice, no mistake need be made between this and the diastolic murmur of aortic insufficiency. The presystolic murmur produced by mitral contraction is extremely rare.

What I have already said of the course of the disease will guide you in prognosis, which is of extreme gravity. No improvement is possible, nor can the development of the cardiac lesions or the accidents which follow in their train be arrested. You have seen that irregularities of the heart and pulse add to the gravity of prognosis. When they appear, the heart has undergone a secondary change, either in its muscular tissue or in its nervous apparatus.

The treatment of mitral insufficiency is of little interest. As soon as the compensation period is over, the animal is slaughtered, or passes into fresh hands.

Even when the disease is recognised in its eusystolic stage, before actual organic change has occurred, the various drugs recommended are useless. The most reasonable treatment consists of rest, moderate exercise, and good hygienic surroundings—treatment inapplicable to working animals.

At the asystolic stage the drugs indicated are those capable of

rendering the heart equal to its increased task. Digitalis is of service, but given before the proper time—that is to say, when the mitral lesion is still compensated—digitalis is often injurious; it increases the work of the heart without purpose, fatigues the muscular tissue, and may finally bring about degenerative changes. Under certain circumstances, bromide and iodide of potassium or sodium may be given to combat cardiac asthma and sclerotic changes—purgatives and diuretics are indicated in œdema and dropsy.

XXII.—MYOCARDITIS.

In animals, and particularly in the horse, inflammation of the myocardium, either acute or chronic, is much more frequent than might be supposed from the small number of published cases. Our present knowledge on this subject is still very defective, especially from the clinical point of view, because, as I shall almost immediately show you, myocarditis is characterised by less striking symptoms than endocarditis and pericarditis, and because many cases having only been diagnosed on *post-mortem* examination, the observers have necessarily been restricted to describing the anatomical lesions.

The specimens which I place before you may be separated into two groups: one, illustrating the changes in acute myocarditis, are derived from horses dead of various infectious diseases,—usually, however, contagious pneumonia; the others, showing lesions of chronic myocarditis, have almost all been obtained during *post-mortem* examination of animals used for the exercises in practical surgery.

Among these are two in which the anatomical and pathological characteristics of the two great varieties of myocarditis are typical, though excessively pronounced.

First of all I show you the heart of a horse dead of contagious pneumonia on the eleventh day, in which gangrene of both pulmonary lobes existed as a complication. It is very large—weighs more than eight and a half pounds, and has been the seat of acute diffuse myocarditis. It shows large yellowish patches, irregularly distributed, but principally occupying the left ventricle and auricle. On the left ventricle, starting from the auriculo-ventricular furrow, is a large zone of fatty degeneration, measuring from one and a half inches to three inches in width, according to the point selected, and sharply differentiated from adjacent tissues by its yellow colour. Sections through the wall and cardiac septum vary in colour from brown to red, grey, or yellow, according to the point chosen. Small hæmorrhagic centres also exist. Several large areas of degeneration extend through the entire thickness

Heart of a horse which died from contagious pneumonia. Acute myocarditis.

of the ventricular wall. The pericardium and endocardium are hardly affected. On macroscopic examination the valves show no appreciable lesion, but microscopic examination reveals lesions of acute diffuse myocarditis. Even where the myocardium appears least altered its fibres prove to have undergone granular degeneration.

In the other specimen we see advanced lesions of chronic myocarditis. This heart is moderately hypertrophied, and exhibits scattered, whitish, irregular, more or less depressed areas, some isolated, others united by narrow bands of the same colour ; the largest are seen on the left ventricle, principally about the auriculo-ventricular furrow. Sections through the wall of this ventricle reveal similar whitish areas, fibrous in appearance, star-shaped, isolated or united. At these points the myocardium has undergone a fibrous change and the muscular fibres have disappeared, having become atrophied or affected with granular degeneration under the compression exercised by the fibrous tissue. In addition the aortic semilunar valves show old-standing change.

Acute or chronic inflammation of the myocardium is usually diffuse, extends to the greater part of the muscle, and is in most cases unequally marked in the left and right hearts, the former being commonly the most markedly affected. This inflammation sometimes occurs as an isolated affection, without co-existent changes in the endocardium or pericardium ; more frequently myocarditis is accompanied by endocarditis or endopericarditis, facts explained by the general pathogeny of heart disease, the muscle and serous membranes covering it being simultaneously attacked by the same infectious or toxic agent.

Acute myocarditis has been divided into primary and secondary. The first is stated to be produced by cold, over-exertion, or mechanical injury. Apart from infection or rheumatism, myocarditis *a frigore* cannot be said to occur. Deeply placed in the thorax, the heart is one of the organs least susceptible to the action of cold, which, at the most, only favours other agents capable of injuring the myocardium. Some cases in man seemed to prove the occurrence of lesions of the myocardium and endocardium after excessive and prolonged efforts. Similar cases have also been observed in creatures used for draught, the horse particularly ; but although the horse is probably the hardest worked of all animals, it is very doubtful if it ever suffers from myocarditis due exclusively to excessive work. Recent investigations have explained the pathogeny of that form of myocarditis which follows excessive exertion of the cardiac muscle. Contrary to the views formerly held, we now believe that excessive exertion does not directly produce

inflammation of the muscular tissue of the heart, but only diminishes its resistance to the attacks of pathogenic organisms—a theory strongly corroborated by bacteriological experiments made during the past few years, especially by those of M. Roger. Myocarditis due to "over-exertion" is therefore included in the group of infectious myocardites.

Mechanical injury of the thorax over the heart only causes inflammation of the cardiac muscle when a penetrating wound is produced, or when the muscle itself is immediately injured, and the lesion becomes infected.

I have only observed acute myocarditis in the horse as a secondary affection; nor have I seen its characteristic lesions, except in animals which had died of toxic or infectious disease, and in which, consequently, myocarditis had occurred as a complication of the original disease. The various forms of pneumonia, the typhoid form of influenza, strangles, hæmoglobinuria, septicæmia, pyæmia, and other microbic diseases may be accompanied by myocarditis, either because of pathogenic organisms dispersed by the blood-stream arriving at the myocardium through the medium of the coronary arteries, and arrested there, producing embolism of more or less extensive tracts; or even more frequently because of injury to the myocardium by the toxins of microbes multiplying at a distant point. M. Charrin produced myocarditis in animals by injecting filtered cultures free of all living organisms; but, whether infectious or toxic, these forms of myocarditis are primarily due to the life processes of microbes.

Diffuse or localised myocarditis, whether limited to the deep or superficial layers of muscle, always results from the extension of inflammation from the endocardium or epicardium. They show that Stokes's law on extension of inflammatory processes from mucous membranes to subjacent muscles also holds true in regard to serous membranes.

The changes produced in the heart muscle by acute diffuse inflammation are usually well marked, and quite apparent on superficial examination, though seldom to such an extent as in the specimen I exhibit, where they are truly remarkable. Usually the heart is more or less enlarged, dilated, flabby, and decolourised. Sometimes its surface is almost uniformly pale greyish, or the colour of a dead leaf: sometimes it is marked with yellowish patches of varying form and size, the majority irregular in shape, with sharply defined margins, and usually more numerous and larger in size on the ventricles. Under the epicardium and endocardium little hæmorrhagic centres can be seen. Sections made through the myocardium appear of a dull

leaden colour, or the muscular tissue is slightly infiltrated, and of the same tint as the surface of the organ; on the more or less discoloured base are scattered greyish-yellow patches and a few blackish areas or points, the former corresponding to centres of degeneration, the others to hæmorrhages.

On microscopic examination, inflammatory and other degenerative esions are seen. Many of the fibres appear swollen, fusiform in shape, and slightly granular; their striation is less marked than normal, or may be altogether lost. Of the interstitial lesions, the chief is hyperæmia and infiltration with leucocytes. At a later stage the affected fibres undergo granular, fatty, or hyaline degeneration, become separated, more or less filled with fine granulations, or partly broken down, while signs of obliterating endarteritis, or periarteritis, and abundant cellular infiltration may be seen. As a rule these lesions are diffuse, and irregularly distributed; alongside degenerated fibres others are sometimes found which have remained healthy, or appear scarcely changed.

In purulent myocarditis section of the muscle exposes little abscesses disseminated throughout its substance. They are generally metastatic, and due to embolism, as in other viscera. They may also be the direct consequence of infectious inflammation of the cardiac muscle, in which case they are not found in other organs. The tissue surrounding them is markedly hyperæmic, infiltrated, and softened. Superficial abscesses may break into the interior of the heart, or into the pericardium. Cases of complete perforation of the septum between the ventricles, by abscesses developed in its thickness, have been published.

In a general sense the symptoms of acute myocarditis all point to enfeeblement of the heart. Nevertheless, at first symptoms of irritation almost always occur. There is a period of abnormal irritability; the heart beats faster and more strongly; sometimes the contractions are violent, rapid, and tumultuous; the pulse is accelerated and strong; the respiration short, and suggestive of dyspnœa.

The local changes gradually develop, and the vague early symptoms are exchanged for others of a precise character. The heart beats more slowly and feebly, and is often irregular or intermittent. Little by little the first sound diminishes in intensity until it becomes scarcely perceptible. The second sometimes remains normal, sometimes it also diminishes. In certain patients a slight systolic murmur can be heard, due to weakness of the papillary muscles. Percussion occasionally produces pain; at an advanced stage it is said to reveal

enlargement of the precordial area of dulness; but these are theoretical points difficult to determine. In common with the action of the heart the pulse becomes feeble, irregular, and intermittent. The functional disturbance produced by myocarditis is seldom pronounced during the first stage of the disease; and as the condition is almost always secondary, this functional disturbance cannot be differentiated from that due to the infectious disorder of which the heart trouble is only a complication. But the symptoms, especially the dyspnœa, are always aggravated by myocarditis.

Contrary to what one might imagine, considering the extremely important function of the heart, acute myocarditis terminates in a fairly large number of cases in recovery. This is the rule in the slight forms accompanying infectious conditions. Resolution slowly proceeds, the heart gradually becomes more active, and its contractions more powerful, until at length the sounds resume their normal character. Clinically recovery is complete, and if anatomically it remains imperfect the disease leaves few traces. In a proportion of cases the inflammation assumes a chronic form.

Death may occur at all stages; sometimes suddenly by syncope, sometimes less rapidly by asphyxia. When by asphyxia dyspnœa increases, the face appears extremely anxious, the apex beat of the heart becomes imperceptible, the pulse is lost, cold sweats cover the body; finally the patient, completely prostrated and unsteady on its legs, falls to the ground and dies in a state of painful collapse. During convalescence death is sometimes produced by granular or hyaline degeneration of the muscular tissue. If in purulent myocarditis an abscess opens through the endocardium, death results from purulent infection or cerebral embolism. Cases of this kind are seen in strangles. When myocarditis accompanies an infectious disease which has gravely affected the lung, kidney, or nervous centres, the lesions in these organs play a certain part in producing death.

The diagnosis of acute myocarditis is difficult. Many infectious diseases entail disturbance of the heart simulating myocarditis, and in addition certain of the local symptoms of myocarditis are also common to pericarditis. Nevertheless, if the practitioner follows the development of the latter disease, other symptoms will be detected which forbid confusion; and when pericardial effusion is abundant, the precordial dulness and weakness of the heart sounds are much more marked than in myocarditis.

Speaking generally, the prognosis is grave. Acute myocarditis may lead to sudden death; in point of fact it kills many animals suffering

primarily from pneumonia. You have also seen that it may assume a chronic form, and, after a varying period, render the animal useless.

As in most other heart diseases, treatment is of doubtful efficacy. We cannot stop the processes going on in the heart muscle by administering drugs. Moreover, the practitioner's attention is often exclusively confined to the primary disease. If myocarditis is recognised or suspected, treatment must be directed towards combating the weakness of the heart, and supporting the animal's strength.

The food should be fluid, consisting of mashes, gruel, hay tea, or milk. If the patient will eat nothing, beef tea may be given by the rectum. The drugs indicated comprise stimulants like alcohol, wine, and coffee given by the mouth ; caffeine, strychnine, and ether hypodermically ; and, if myocarditis is secondary to pneumonia, digitalis. Counter-irritation by means of a mustard plaster applied to both sides of the chest, or refrigeration of the precordial region, may also be tried.

In contrast with the acute form, chronic myocarditis often occurs as an isolated affection, apart from any other existing disease, or only associated with lesions of the cardiac serous membranes ; and inasmuch as it only produces vague functional disturbance, and very imperfectly recognised local symptoms, it often escapes notice altogether. No hesitation is felt in affirming the existence of cardiac disease when a murmur exists, but it is quite otherwise when the symptoms, though apparently due to heart trouble, are unaccompanied by any abnormal sound. When, however, the constitutional symptoms are supplemented by modifications in the action of the heart—irregularities, momentary arrests, or intermittencies—the patient in the majority of cases is suffering from a condition which, though insidious and of slow progress, is nevertheless extremely grave. Most frequently these symptoms are due to chronic inflammation of the cardiac muscle.

As a general rule, chronic myocarditis follows the acute form. Inflammation of the myocardium continues in a less degree, slowly producing degenerative changes, and later, functional disturbance. In certain cases this inflammation occurs spontaneously and indirectly, in consequence of cardiac or pulmonary lesions, which produce passive permanent congestion of the heart muscle. It is described as being produced directly by excessive functional activity of the heart, *i. e.* by over-exertion. Now in draught animals, and especially in horses, nothing is commoner than over-exertion, but the usual result is simply to produce hypertrophy of the heart, with or without dilatation of its cavities. Myocarditis due to this cause alone is very rare, if indeed it ever occurs. The cases seen are usually the consequence either of the

acute form or of valvular lesions; or, again, of some obstacle to circulation reacting on the cardiac muscle, and forcing it to work more actively—a condition which first produces hypertrophy, and sooner or later changes of the nature of degenerative myocarditis. In these cases functional hyperactivity is not acting alone, but is supplemented by permanent passive congestion of the cardiac muscle, consequent on the impediment to circulation. Under this double influence, changes occur both in the fibres and the sarcolemma. The latter, being continuously irritated, responds by active proliferation (hyperplasia), while the muscular fibres undergo granular degeneration, lose their striation and contractility, and finally disappear under the pressure of the new connective-tissue growth. Like the valvular lesions (of which it is a consequence) this myocarditis is oftenest seen in the left heart. The myocarditis following pulmonary emphysema, and specially marked in the right heart, is due to a similar mechanism. In consequence of stasis and increased pressure in the pulmonary artery, cardiac circulation is impeded; the blood escapes with difficulty from the coronary veins; the cardiac muscle therefore becomes congested, and the conditions for degenerative and hyperplastic changes are at once realised. But, I repeat, diffuse chronic myocarditis is almost always a deferred consequence of infectious disease, during which the heart has been affected; it is the last stage of inflammation of the muscle of the heart.

Partial or superficial myocarditis, developed by contiguity of tissue, *i. e.* by extension to the cardiac muscle of inflammation at first localised in the pericardium or endocardium, is sometimes seen. Though very rare in the horse, it is common in the dog.

In exceptional instances, myocarditis may result from the presence of sclerostomata (parasitic worms) in one of the coronary arteries. I reported a case in an ass suffering from chronic myocarditis, in which the left coronary artery had become thrombosed, and close to its origin showed an aneurism containing a dozen of these parasites.

The anatomical changes shown by the cardiac muscle when the seat of chronic inflammation result from two constantly associated factors, the effects of which, however, may be developed to any degree, and most frequently are unequally marked. In the majority of cases the dominant lesion is the proliferation of interstitial connective tissue leading to sclerosis of the myocardium; in others it is the granulo-fatty degeneration of the muscular fibres.

When the contractile tissue is specially affected, the heart usually remains of normal size, being simply softer and more relaxed, though it may have undergone preliminary hypertrophy. After recent attacks,

sections through its walls appear yellowish-red, marked with patches or stripes of a lighter colour. Examined microscopically, the fibres are seen to have lost their striation, and to be more or less infiltrated with proteid granulations, broken up and partially destroyed. In addition, there is often a slight increase in quantity of connective tissue.

These lesions are found irregularly distributed in both hearts, but especially in the thickness of the septum and of the wall of the left ventricle. They may be little marked at certain points, while well developed, or even of old standing, in others. Cases occur where the quantity of new connective-tissue growth is very small, and where the process appears to consist essentially in simple granulo-fatty degeneration of the muscular fibres.

In fibrous or sclerosing myocarditis, by far the most common form, the heart may be hypertrophied, of normal volume, or more or less atrophied. When increased in size the hypertrophy must not be ascribed to the myocarditis; it has preceded the latter, having resulted from excessive functional activity of the muscular tissue, necessitated by the presence of some obstruction to the free circulation of blood. The heart's surface is marked with irregular depressions, corresponding to portions of the cardiac muscle which have undergone fibrous transformation, followed by contraction of the new connective tissue. The sclerosis is of varying depth and area. In a general sense it is always of vascular origin, resulting primarily from proliferation of the cells forming the walls of small vessels, and gradually extending to the interfascicular tissue, producing fibrous new growths, which afterwards compress and destroy the true muscular fibres. This cardiac sclerosis is sometimes periarterial, related to arterio-sclerosis, sometimes perivenous, due to stasis produced in the last period of valvular disease, and peculiar to what M. Huchard has called in man "cardiac heart." Microscopic examination reveals patches, bands, and anastomosing networks of fibrous tissue, of varying size, between the muscular fibres, many of which, in consequence of their pressure, have undergone degenerative changes or have altogether disappeared.

The changes due to myocarditis when accompanying endocarditis or pericarditis, and developed by contiguity of structure, sometimes extend to the entire cortical layer of the muscle; the latter showing on section a zone, several millimetres in thickness, of a reddish pale yellow or whitish tint, depending on the stage and form of the disease. In this layer the muscular fibres have undergone granulo-fatty degeneration, or have become atrophied by pressure of the new tissue and fibrous networks. Instead of thus being spread over the entire surface of the myocardium, the lesions are in many cases circumscribed. In

valvular endocarditis they are almost always localised near the auriculo-ventricular or arterial openings. The process extends from the base of the valves into the adjacent zone of muscle, and thus may produce so-called "annular" myocarditis. Through the medium of the *chordæ tendineæ* it may extend to the *musculi papillares*, and end by transforming them almost entirely into fibrous cords. Similarly in pericarditis, secondary localised myocarditis is sometimes seen in certain parts of the superficial layers of the muscle.

Localised myocarditis, followed either by fibrous or fatty degeneration, may weaken the ventricular wall until it yields to the pressure of blood, and finally undergoes saccular dilatation, producing a partial chronic aneurism.

Bearing in mind the functional importance of the heart, and the grave nature of the lesions described, it might be expected that chronic myocarditis would produce very marked symptoms clearly indicating its existence. On the contrary, however, the disease often continues unperceived for months or even years, its stages succeeding one another very slowly. When chronic myocarditis appears as a primary condition, animals can often be kept at their usual work for a long time; and even when it succeeds to the acute form, they are able to return to work after termination of the latter.

In either case a time arrives when the previously latent disease produces disturbance which can no longer be ignored. The most ordinary is that complex condition known as broken wind, especially marked by dyspnœa. At work, difficulty in breathing soon occurs, the heart's action becomes strong and tumultuous, and true palpitation is perceptible on applying the hand over the precordial region. In some cases the horse stops suddenly during work, and is often thought to be suffering from colic, but in animals angina pectoris, like vertigo, fainting, and syncope, appears to be rare. During this preliminary period, which has been described as irritative, palpitation of the heart and acceleration of the pulse can be detected, even when at rest in the stable.

With the lapse of time, dyspnœa increases during work, occurring in paroxysms, while the heart's action becomes modified and the pulse weak, infrequent, and intermittent. Not only does palpitation cease, but the contractions of the heart may be weaker than normal, and, like the pulse, infrequent, irregular, and intermittent. On auscultation, the heart-sounds are rather attenuated in granulo-fatty myocarditis, but prolonged and accompanied by a rolling or double sound in sclerosing myocarditis, with hypertrophy of the left ventricle. In

neither of these forms of chronic inflammation of the myocardium is there a murmur unless a valvular lesion simultaneously exists, or unless the auriculo-ventricular valves are imperfectly controlled in consequence of weakness of the papillary muscles. In some cases percussion reveals enlargement of the area of cardiac dulness due to relaxation of the walls of the heart, and, in granulo-fatty myocarditis, to dilatation of these cavities, in fibrous myocarditis to hypertrophy of the left ventricle. But, as in the acute form, this symptom is difficult of detection.

If the animals are kept, the symptoms become continuously aggravated, and may be supplemented by respiratory and gastric troubles of reflex character. These are later complicated by disturbance due to slowing of the circulation and weakness of the heart, vascular stasis, engorgement of the lung and of other viscera, dropsy, œdema, and finally by changes which indicate exhaustion of the heart. Degenerative myocarditis marks the last phase in the series of disorders produced by valvular lesions. The successive changes seen during the disease originate in the endocardium; they end in degeneration of the myocardium.

Cortical or partial myocarditis produces much less pronounced and much vaguer symptoms. In the horse it is sometimes only indicated by intermittency.

Chronic myocarditis always takes a very slow course; it continues for years, gradually becoming more marked, though it may for a time remain stationary. It never tends towards recovery, however. If the patients are kept, death follows from increasing feebleness and wasting, or unexpectedly from syncope or rupture of the heart. The ass whose case I described was found dead in its stall, without having stopped work a single day, and without having shown any serious respiratory trouble, despite the fact that in its case myocarditis was complicated with disease and insufficiency of the aortic valves. Rupture of the heart is very rare in all animals, though it may occur under the influence of excessive excitement, or of a fall, or violent effort during work. The heart then contracts with excessive energy, the intra-cardiac pressure suddenly increases, and the muscular wall having undergone degenerative change yields at its weakest point—oftenest in one of the ventricles, at the seat of an aneurism, or of some fatty or fibrous alteration.

The diagnosis of myocarditis is surrounded with many difficulties. In all species of animals mistakes are difficult to avoid, and diagnosis should be delivered with great circumspection. The disease is sug-

gested by the history, by the visible symptoms, and especially by the attacks of dyspnœa which affect most patients during work. The cardiac symptoms must be viewed as a whole, particular attention being given to those detected on auscultation, and examination of the pulse; while other diseases capable of producing the functional disturbances noted must be disposed of by a process of exclusion.

The prognosis is very grave. If the disease is not immediately threatening it always ends by disabling its subjects, and sooner or later entails death.

The only useful treatment consists in endeavouring to control inflammation of the cardiac muscle by the administration of salts of iodine, and in stimulating those cardiac fibres which have escaped destruction. For this purpose heart stimulants and tonics like nux vomica and its derivatives, or caffeine, may be given; where, however, symptoms of broken wind exist and the myocarditis is little pronounced, arsenic and sometimes digitalis give better results.

XXIII.—OSSIFICATION OF THE CARDIAC AURICLES.

THIS morning I purpose speaking of ossification of the righ auricle, a lesion which is sometimes seen in the horse, and though not mentioned in the majority of classic works, has occasionally been reported in French and other periodical publications.

I will give you the details of a case. This specimen which I exhibit was obtained by M. Barillot, a veterinary surgeon practising in Paris, at the *post-mortem* examination of a pony. It is a greatly enlarged and almost completely ossified right auricle; its anterior portion is thickened and of bony consistence throughout, but the upper part has only undergone this change to a limited extent. It presents rounded irregular areas of spongy bone tissue, varying in size between that of a large pea and of a sixpence; almost all project more or less on both surfaces of the auricle.

In the *Compte Rendu des Travaux de l'École d'Alfort* for the session 1836-7, Renault mentioned in the following terms a case of the same nature seen in a glandered horse, whose age, however, is not given. "The right auricle was considerably enlarged and weighed 2 lbs., was thickened and ossified throughout nine tenths of its extent, and the muscular fibres had been compressed and atrophied by the bony new growth. The lesions on the convex surface of the auricle were as hard and resonant as bone. They were less developed in the interior, where they had the appearance and consistence of cartilage. Ossification suddenly ceased at the junction of the auricle with the ventricle, and at the upper part where the auricle becomes continuous with the venæ cavæ. At their junction the veins formed an accidental pouch with muscular walls, the substance of which was continuous with that of the auricle, and appeared to have assisted the latter in its function. The other portions of the heart were healthy." Renault adds that cases of partial ossification of the heart, and especially of the auricles, had previously been noted in men and animals.

In 1840 Bouley the younger, acting on behalf of Barthélemy, veterinary surgeon at Paris, communicated to the Académie de Médecine a case of hypertrophy of the heart, with complete ossification of the right auricle, in a six-year-old horse. The animal had been bought five months before, and was unable to do regular work. It did not cough, but rapidly lost breath after the least work; the respiration, while remaining regular, was sometimes extremely rapid, and suggested dyspnœa. As it was thought that improvement would follow a rest at grass, the animal was sent to a farm in the neighbourhood, where it remained for two months. On returning it was put to work, but found to be in nowise improved, and some time later died from pneumonia. The *post-mortem* examination revealed, in addition to recent and old-standing pulmonary lesions, hypertrophy of the heart and ossification of the right auricle, which was fixed to the pericardium by fibrous bands. The capacity of the auricle was at least doubled, and its walls, thickened to the extent of one inch and a quarter to one inch and a half, were completely ossified.

In this communication Bouley refers to Renault's case, mentions a case of complete ossification of one auricle seen by Barthélemy the elder, in a cow affected with pulmonary tuberculosis; and another, mentioned by Riquet, of partial ossification of one of the ventricles in a horse. He regards ossification of the auricles as extremely rare, inasmuch as Girard and Rigot do not appear to have seen a single case in the animals destroyed at Alfort for practical surgical operations and anatomical purposes during a period of nearly forty years.

In Godwing's case the horse's age is not mentioned, though we are told that it several times showed serious symptoms, which were referred to "disease of the liver, complicated by interference with circulation." It was finally slaughtered. The *post-mortem* examination showed the existence of fibrous pericarditis. The auricle was cartilaginous throughout most of its upper part, and its anterior sections were ossified.

Among the many horses examined after death at Alfort between 1848 and 1863, Colin twice found the right auricle completely ossified, and twice saw tracts of bony tissue of varying size.

The horse, whose case was reported in 1884 by Chouchou to the Société Centrale de Médecine Vétérinaire, was eight years old. For three years it had belonged to a firm of carriers, and had always worked well, showing no sign of disease. One day, without apparent cause, it appeared depressed, and had to be rested for a week. For a time it seemed to recover, but soon returned to hospital with œdematous swellings in different regions and marked enlargement of the hind limbs, symptoms at first regarded as due to purpura hæmorrhagica

and afterwards to glanders. Soon afterwards a sarcocele developed and was operated on. With a little pus taken from the end of the epididymis a guinea-pig was inoculated. The result was negative. The patient steadily became weaker, and was finally slaughtered. On incising the pericardium lesions of fibrinous pericarditis were found. The heart was very large, the ventricles dilated and their walls thinned. The right auricle was whitish and hard, its cavity diminished in size, and its walls ossified throughout almost their entire extent. It weighed nearly four pounds.

Veret's case was that of a seventeen-year-old trooper which died in consequence of a fracture. On *post-mortem* the right heart was found to be "calcified."

I pass over in silence some other cases reported abroad. They add nothing interesting to what I have just related.

Let us now return to the horse, in which M. Barillot found the specimen he has sent us. Its history can be given in a few words:—A pony bought in London, in October, 1895, attacked with some chest disease soon after its arrival in Paris. Became convalescent in a fortnight, and was sent to grass in the Ile Saint-Denis, for three weeks.

Before its illness this pony was very lively, and had good action, for which reason it cost a considerable sum. On being returned to its owner it had lost its vigour and pace, was "soft" in work, dull in the stable, hung back from the manger, and its extremities were cold. On the 5th January an œdematous swelling appeared under the chest. My colleague, who was at once called, carefully examined the animal, and diagnosed pleurisy, at the same time noting certain signs of heart disease. Treatment proved unsuccessful, and two days later the pony died.

On *post-mortem* the pleural cavity was found to contain an abundant exudate; the heart was hypertrophied; and the walls of the right auricle were thickened, hard, and ossified throughout the greater portion of their surface. The case, therefore, was one of ossification of the heart muscle. Sections showed the characteristic appearances of bony tissue, concentric bony lamellæ, and osteoplasts.

Ossification of the auricles is most common in aged animals, though sometimes seen in relatively young subjects. The pony of which I have just spoken was only five years old. A further curious point is that the right auricle is almost always the sole point attacked; even when it is completely ossified the left auricle is usually entirely free.

The causes of this peculiar change in the heart are unknown. In

most reported cases heart lesions have either been complicated by others like pericarditis, or by emphysema, glanders, or tuberculosis; while the cavity of the right auricle has been found greatly enlarged, owing without doubt to insufficiency of the tricuspid valve.

When limited to one part of the auricle and only affecting the roof or *cul-de-sac*, for example, ossification produces no appreciable symptoms, and is always a surprise on *post-mortem;* but when extended to the greater part, or to the entire auricle, particularly if the latter be dilated, and the auriculo-ventricular opening more or less enlarged—troubles occur which clearly suggest the existence of heart disease. They include dyspnœa, palpitation, venous pulse, and at a later stage swellings about the thorax and extremities. Even in presence of these complications, however, exact diagnosis is impossible. The most one can discover is that the disease is located in the heart.

The various drugs which have been used all appear equally useless. In point of fact no treatment is efficacious.

XXIV.—CARDIAC INTERMITTENCY IN THE HORSE.

For ten days past we have had in stable No. 6 a horse recovering from pneumonia, in which the day after entry we discovered by auscultation true cardiac intermittency, certainly of older standing than the pulmonary disease. I called your attention to this patient, and to the character of the intermittency. Allow me to-day to return to this variety of cardiac disturbance, which is common in the horse, but concerning which you will find very little in text-books and periodicals.

In a normal state, and under normal conditions, the heart beats with perfect regularity. In an animal of any given species it contracts the same number of times within the same period, though its sounds are not invariably of one character. In the horse especially it is not uncommon to find modifications in their intensity and tone, and a tendency to doubling of one or other. To convince yourselves of this, you have only to auscultate a number of the patients now under treatment.

The action of the heart is subject to an entire series of disturbances, some common and ephemeral, others produced by change in the organ itself, or in the nerves supplying it. The number of contractions may be modified, increased, or diminished by many pathological states. Sometimes the rhythm is slowed, a condition known as bradycardia; more frequently accelerated, tachycardia. Either of the two sounds noted during each heart cycle may be doubled or replaced by a murmur. The cardiac systole and the pulsations of the arteries may be of unequal force. In all these cases the regularity of rhythm of the heart and of the pulse are generally preserved, the pulsations succeeding one another at equal intervals.

But in some animals the cardiac systole and the arterial pulsations, whether equal or unequal in force, no longer succeed one another regularly. At more or less frequent intervals the heart's activity is completely suspended for a short period, or the contractions are feeble,

and in both cases one or more arterial pulsations may be absent. These troubles characterise both varieties of cardiac intermittency seen in man by Laennec. In true intermittency it seems as though the heart were really arrested for the moment, its contractions completely ceasing. In false intermittency a certain number of cardiac cycles, normal as regards strength, are followed by a feeble abortive contraction, which has no effect on the arteries, and which does not, therefore, cause their walls to rise; only the pulse is then really intermittent. In both these varieties of intermittency, therefore, the regular cardiac or arterial pulsation is merely interrupted, whilst in true irregularity (arythmia) the pulsations are irregular or unequal, and the period of the cardiac cycle is prolonged or shortened; in intermittency the heart usually beats normally save during the period of arrest. Both these conditions may be found associated.

I merely mention the false intermittencies usually seen during diseases of the heart and of some other viscera. In patients showing this condition the pulse is not only intermittent, but irregular, unequal, and frequently almost imperceptible.

In patients with true intermittency, auscultation of the heart reveals a regular succession of orderly and equal beats, followed by a long silence, coinciding with an abnormal prolonged rest of the heart, then a new series of normal pulsations, to which succeeds a further silence, and so on. Apart from these suspensions, which from time to time and more or less periodically break the series, the heart acts regularly. The frequence of the arrests varies greatly. Sometimes they are separated by unequal periods of time, and are repeated every second, third, tenth, twelfth, or fifteenth pulsation; sometimes they succeed at equal intervals, *i. e.* after the same number of pulsations, usually from two to six. One sees horses in which the pauses are rhythmical to a very remarkable degree; in others the periodicity is subject to variation. During the course of the day the same animal may at certain times show regular, and at others irregular intermittency. In some rare cases the series of pulsations are separated by long intermittencies, which again are interrupted by a false beat.

The duration of the arrests is generally in inverse proportion to the number of pulsations in the series. It usually corresponds to one or two cardiac cycles, though occasionally shorter or longer. In a case mentioned by Siedamgrotzky the heart beat sixteen to twenty times per minute, the beats occurring singly or in groups of two, three, or four, separated by arrests corresponding in duration to two, three, or four pulsations. At the *post-mortem* of this horse the heart was found

hypertrophied, and its muscular substance degenerated. Some months ago in the outer clinique we saw a horse in which the beats occurred in groups of three, four, or five, separated by pauses equal in length to two cardiac cycles.

Whatever the duration of the series of beats or pauses, the first contraction after the intermittency is almost always stronger than the others. Sometimes, and particularly when the animal has just been exercised, it is violent, recalling palpitation, while the second contraction always follows rapidly and at a shorter interval than the others.

In some instances the usual cardiac stimuli fail to act, or have little effect on the intermittency. If, in order to accelerate the beating of the heart, the patient is trotted for a few moments, they may continue as before; but in general the intermittencies noted during rest diminish in frequency, or temporarily disappear under the influence of exercise. Last month I examined a patient showing this peculiarity. The horse was five years old, had been bought six months before, and was at first a good worker. Two months before being brought here it began to lose its hard condition, showed difficulty in breathing, and was unfit for even moderate work, though it still appeared well-nourished. On watching the flank, expiration was seen to be double. On auscultation every fourth or fifth heart-beat was found to be followed by an intermittency equal in length to one or two pulsations. Both cardiac sounds were abnormal, the first being prolonged and the second double. After a few minutes' exercise the intermittency disappeared, the beats succeeding at regular intervals; but after a further few minutes the arrests recurred at first at rare intervals, then more and more frequently.

During the last few years I have noted true intermittency, certainly of old standing, in several horses undergoing treatment in hospital for external diseases, but which had never shown symptoms of heart disease. I will describe two cases.

In 1895 we had in the infirmary a horse suffering from picked-up nail, which showed intermittency of the pulse and arrest of the heart; neither condition, I need scarcely say, had any causal connection with the injury. The heart-beats occurred in series of three to six, separated by silent periods of uniform length, lasting as long as one pulsation. The first systole of each series was sudden, bounding, and immediately followed by a second much weaker contraction, then by others of diminishing strength. The violent struggles during operation, and the traumatic fever which followed it, had no effect on the intermittency. The animal left here in the same condition as when it entered; the periodicity and duration of the arrests were precisely the same.

Previous to the accident for which the horse was sent here no disturbance or symptom suggesting cardiac irregularity had been remarked. According to its driver's account the horse even seemed brighter and more spirited than the animals with which it worked.

In 1894 we discovered similar disturbance in a ten-year-old carriage horse, sent here from the department of the Maine-et-Loire on account of spavin lameness. This horse was very fast and powerful, and had never shown symptoms of heart disease. The pupil who attended it was instructed to keep me informed of the changes in the pulse and heart. The intermittency lasted as long as two complete heart cycles, and occurred after every three or six pulsations, long and short series succeeding one another in an extremely irregular fashion.

The ætiology of cardiac intermittency is complex, and its pathology even more obscure. In certain cases where it has been observed apart from any manifest organic change it has been attributed to overwork or digestive trouble; but, except when produced by excessive doses of digitalis, it usually indicates some heart disturbance.

Of the organic lesions it most frequently accompanies myocarditis, at times endocarditis and pericarditis. Its final cause always appears to be either primary or secondary disease of the cardiac muscle, or some disturbance of the nervous apparatus of the heart. On account of intermittency being usually due to myocarditis, it is often accompanied by other symptoms like dulness, rolling, and doubling of the heart-sounds, which indicate or at least suggest disease of the heart muscle.

Temporary intermittency, true or false, regular or irregular, often appears during various specific diseases in consequence of the heart being attacked by infectious organisms or their toxins. I have often observed intermittency during pneumonia, and those practitioners who auscultate the heart during such attacks have certainly had similar experience. In the *Bulletin de la Société Centrale de Médecine Vétérinaire* for 1894 I described a case. I may here mention a more recent instance.

At the commencement of last December I received into hospital a six-year-old horse with acute pneumonia of three days' standing. The disease was of moderate gravity, rather benign in character; the temperature did not exceed 40·5 ° C. (104·9 ° F.), and the fever declined on the sixth day. Every morning after having examined the state of the lung I auscultated the heart. During resolution, the tenth day of the attack, I noted intermittency; a pause, equal in length to that of one cardiac cycle, following series of six to ten contractions, normal in

respect of strength and rhythm. During the following days these intermittencies became more frequent, one occurring after each fourth or fifth pulsation. At the end of a week they could only be noted after a regular series of eight to ten pulsations. They did not change before the animal left the hospital; I may add that digitalis had not been given.

Usually ephemeral in character, but sometimes obstinate or even permanent, such intermittency is commonest in cases of pneumonia which at the onset have shown other cardiac disturbance like marked acceleration and violent action of the heart, or modification in the sounds.

The seriousness of intermittency depends on many conditions, but especially on its frequency, duration, and the presence or absence of other cardiac troubles. When recent, and occurring during the course of or during convalescence from acute diseases, it generally disappears rapidly, and does not return. When of old standing (whatever the primary disease to which it is due) it commonly indicates change in the heart muscle, or in its nervous supply, and caution must be observed in delivering an opinion. Though not necessarily implying the existence of any organic disease, or material change in the heart, yet in the great majority of cases it follows injury to the heart muscle or its nervous supply. Certain horses still continue useful for years, but are none the less affected in one of their most important organs.

The treatment resembles that of myocarditis, the principal agents being the iodide of potassium or sodium and digitalis. In old-standing intermittency drugs have little effect; they are only useful within a comparatively short time after the onset of disease.

In a patient which had suffered from strangles, and in which intermittency followed every three or four pulsations, I prescribed a $2\frac{1}{2}$-drachm dose of iodide of potassium daily, afterwards increasing it to $3\frac{3}{4}$ drachms. This treatment was only commenced three months after recovery from strangles, and was continued for six weeks, with two interruptions of a week, the animal being meanwhile kept at quiet work. At the end of two months the intermittency still continued, but at longer intervals, being separated by series of six, eight, or ten pulsations. It afterwards became less frequent and finally disappeared.

XXV.—PERICARDITIS IN THE DOG.

During the past few months we have seen a considerable number of cases of peritoneal dropsy in the dog, and I have shown you that in these animals ascites is very often associated with tuberculosis, pericarditis, or valvular endocarditis. This fact must always be borne in mind when giving an opinion and directing treatment. You will therefore understand why, when called on to treat dogs with abdominal dropsy, I do not confine myself, as was usually so long and is still the custom, to evacuating the liquid collected in the peritoneum and prescribing wine of squills or similar remedy; but always examine the heart by palpation, percussion, and auscultation, and submit the patient to the tuberculin test.

In order to estimate the gravity of the condition, and decide whether the patient is or is not amenable to treatment, it is not sufficient merely to show that the ascites depends on pericarditis, for, as I have already shown during a previous lecture, pericarditis in the dog is often of tuberculous character. When, therefore, dogs with pericardial effusion distinctly react to tuberculin, the pericardial disease is probably tuberculous; and although failure to react does not entirely eliminate the question of tuberculosis, it at least greatly strengthens our belief that a cure may be effected. It is this latter point which I wish to emphasise to-day. I shall first describe a case affected with pericarditis and ascites, which was cured by puncturing the abdomen and pericardium.

Towards the middle of last April a three-year-old sheep-dog, which had always enjoyed good health, was brought to hospital on account of disease of a fortnight's standing. Without doubt it had suffered from distemper, but of so trifling a character as to have escaped observation. At the beginning of April the dog lost its spirits; its appetite became capricious, and was afterwards lost; the abdomen increased in size; walking was painful, and soon caused loss of breath.

When submitted to our notice this patient showed all the external signs of some grave visceral disease. Apart from the emaciation and

weakness, three points immediately attracted attention—the rapid breathing, size of the abdomen, and presence of a swelling under the chest. The abdomen was largest about its lower part, which was dull when percussed and showed fluctuation, pointing to the presence of ascitic exudate. The respiration was rapid, short and sighing, numbered thirty-five to forty per minute, and movement and exertion of any kind like walking caused oppression. On auscultating the chest the vesicular murmur was only heard distinctly in the upper half of either lung. The heart-beats were difficult to feel, and the normal heart-sounds were obscure, distant, and smothered. The pulse at the femoral artery was very feeble, and about 130 per minute. The jugulars showed very clearly marked venous pulse. The temperature was 39·2° C. (102·5° F.).

On the same day we tapped the abdomen, and withdrew about two quarts of a slightly red serous liquid. During the evening and the next day the animal was spoon-fed with milk, and 15 cg. (2·25 grains) of calomel were given. Tuberculin produced no reaction.

On the following day, although fever was slight (the temperature not exceeding 38·9° C. = 102° F.), the condition had become more alarming. The abdomen, reduced after tapping, had again increased, and the swelling under the chest was somewhat larger. The impulse and beating of the heart were imperceptible; the arterial pulse was still feebler than on the previous day, but the venous pulse more marked. The respirations were forty-five per minute; the depression appeared greater, and death imminent. After morning hospital inspection I punctured the pericardium with an aspirator and fine needle opposite the fifth intra-costal space, about two and a quarter inches above the line of the sternum, withdrawing nearly six and a half ounces of slightly red-stained liquid similar to that obtained from the abdomen on the previous day.

Immediate improvement followed. The patient's face lost its anxious expression, the dyspnœa diminished, and the respiration became easier. During the evening and night the animal several times took milk.

Next day the improvement continued. The morning temperature was 38·6° (101·4° F.), the respiration 27, and the pulse 112. The heart-beats could be felt, both normal sounds were heard, and the venous pulse disappeared. I prescribed infrictions of antimonial ointment over the precordial region. Milk feeding was continued.

Within a few days disturbance rapidly diminished. At the end of a week the appetite and general spirits returned. Fed on meat, rice, and milk, the convalescent rapidly regained strength and condition.

When returned to its owner a fortnight after the second operation it was almost completely cured.

When, however, pericarditis in the dog results from tuberculosis, or has given rise to local or visceral lesions of a more or less permanent character, the results of tapping the pericardium are seldom as successful as in the above case. But in certain forms of pericarditis which develop slowly, rapid cure is possible even when the condition has existed for a comparatively long time. The following case bears witness to this.

During August, 1896, a four-year-old setter, which had been ill for nearly six weeks, was brought for examination. Though usually very bright and affectionate, this dog had become dull, had kept out of sight and remained continually lying down, while it scarcely touched food. On the few occasions when it accompanied its master, walking was followed by loss of breath, which forced it to stop, gasping for breath.

When brought here its emaciated state and enlarged abdomen at once arrested attention. Palpation of the abdomen revealed the presence of a large quantity of ascitic exudate. The respiration was rapid and painful, inspiration being slow and prolonged, expiration rapid. On auscultation the vesicular murmur was almost normal in the upper parts of both pulmonary lobes, but absent in the lower. On applying the hand to the left thoracic wall, over the cardiac region the heart's impulse could not be felt, and on auscultation both normal sounds were very feeble and difficult to detect. Percussion showed the zone of cardiac dulness to be much more extensive in front, towards the back, and in an upward direction than normal. The limits of this dull zone were practically the same whether percussion were performed with the animal in the ordinary standing position, lifted by its fore-limbs, or allowed to stand on its hind. The pulse was rapid, very feeble, and irregular. Both jugulars showed a marked venous pulse, especially in their lower portions. The pulse was 120, the respirations thirty-six per minute; the temperature 39° C. (102·2° F.). I diagnosed the condition as pericarditis, probably of tuberculous character complicated with ascites. Injection of tuberculin produced no reaction.

On the third day I successively performed, under antiseptic precautions, puncture of the abdomen and of the pericardium, using an aspirator. I slowly withdrew from the abdomen nearly three pints of a greyish serous fluid, and from the pericardium twelve fluid ounces of a similar liquid. A part of the left thoracic wall, as large as the palm of a man's hand, over the heart region, was rubbed with anti-

monial ointment, and the abdomen was bandaged. The food consisted of milk and a little raw meat.

This treatment gave immediate relief. Next day the respirations were only 30 and freer, the pulse was 100, and the appetite returned. The animal took a pint of milk and some meat. On the following days slow improvement continued.

Recovery was uneventful; no occasion arose for repeating the puncture, the liquid left in the pericardium and peritoneum becoming reabsorbed. A month later the animal returned home cured. It had quite recovered its appetite, was bright, walked and trotted without showing dyspnœa, and the impulse and sounds of the heart had become normal. We heard somewhat later that the animal had recovered its condition and strength.

In addition, however, to narrating these two cases, I wish to direct your attention to the principal varieties of pericarditis in the dog, and to teach you the lessons of my own experience.

Though very generally of secondary character, and due either to tuberculosis or some other infectious disease like pneumonia, rheumatism, or distemper, pericarditis is sometimes primary, the result of cold or injury. You will rarely see traumatic pericarditis, most of the cases we are called on to treat being attributed to chill. As in pleurisy, pneumonia, and endocarditis, cold is not, however, the sole factor in producing the disease, its action being confined to exciting general disturbance, congestion, etc., which favour and render possible infection of the pericardium by microbes brought from neighbouring or distant organs through the circulation. Pericarditis *à frigore* is certainly rare, and can only occur in animals predisposed to it by their constitutional condition, though its occurrence is indisputable. You will see it especially in water-spaniels and sporting dogs used in marshy country.

During March, 1895, I made a *post-mortem* examination of a little poodle, in which exudative pericarditis had been produced by baths prescribed for skin disease. A week after commencing treatment the patient suddenly showed very grave symptoms, which were attributed to pleurisy. Bathing was stopped, and the animal treated for the chest affection; but the treatment proved abortive, and death occurred on the tenth day. The body was brought here. The pleuræ and lungs were healthy, but the pericardium was acutely inflamed and contained abundance of a slightly reddish fibrinous liquid, in the precipitate from which I found streptococci. There were no tubercle bacilli, and no tuberculous lesions in any of the organs.

In the dog, exudative pericarditis occurs in the acute and chronic forms. Attention is always first attracted by the physical symptoms.

The acute form is indicated by loss of appetite, weakness, rapid breathing, anxiety, dyspnœa, and fever, amounting to 1·5°—2° C. Physical signs soon develop indicating its character. At the very commencement auscultation may reveal a rubbing sound, produced by friction between the two roughened pericardial layers; but this sound is fugitive, and can rarely be detected. Furthermore it is not constant, for exudation may accompany the onset of the disease. At this initial stage palpitation may also occur, particularly when the patient walks or makes any marked effort; percussion sometimes produces pain.

As soon as the pericardium contains a certain quantity of liquid, the heart is thrust upwards and a little forwards, the degree of displacement depending on the amount of exudate. The pericardial sac becomes distended, especially about its base, lifting the pulmonary lobes, and pushing them upwards towards the vertebræ, though to a much less degree than in pleurisy. Thus on palpation of the precordial region the heart's impulse appears weak, or seems lost. On auscultation the normal sounds, clearly detected in health even in very small patients, are dull, distant, and smothered, or completely inaudible. When the heart is but slightly compressed the pulse preserves its character; but as soon as pressure becomes marked the pulse grows small, fugitive, and weak, sometimes almost imperceptible and uncountable.

Compression of the auricles—the portions of the heart which collapse most readily—impedes the flow of blood, produces cyanosis, venous pulse in the jugulars, and mechanical dyspnœa owing to stasis of blood in the lungs. The symptoms of oppression at first seen are undoubtedly of reflex origin, due to the pain in the inflamed pericardium.

If not treated, acute pericarditis may rapidly lead to death, sometimes in less than a week. It may also (though exceptionally) terminate in recovery, the exudate becoming reabsorbed, the symptoms gradually diminishing and finally disappearing. In certain cases it assumes the chronic form.

The variety of pericarditis to which the term hæmorrhagic has been applied is characterised by a reddish, sanguineous exudate, and occurs somewhat frequently in the dog. During the course of the last two years I have seen five cases. In three the pericardial inflammation was of tuberculous origin, and in one there was no other tuberculous focus save in the pericardium. In two cases the disease was of a special character, independent of tuberculosis. The hæmorrhage occurring during the course of the disease originates in the very

vascular and fragile new membranes which develop on the surface of the pericardium, especially towards the base of the heart, at the point where the serous membrane is reflected. This form is always very grave. The five patients which I saw all died rapidly.

In 1894 I had sent to me the body of a bitch which had died from hæmorrhagic pericarditis, and in which the peritoneal exudate was very abundant. A year before I had tapped this animal for abdominal ascites, apparently curing her—at least for a period of six months. In this case, again, we found no tuberculous lesion, and animals inoculated with the exudate gave no result.

In a considerable number of instances, instead of following this well-marked course, pericarditis assumes a chronic character from the beginning. Its onset is insidious, its course slow; and until the exudate is sufficiently abundant to produce difficulty in breathing, it remains unrecognised. Then on methodical examination one notes, as in the acute form, certain signs furnished by auscultation and percussion. At a more advanced stage the physical signs become aggravated, and are supplemented by loss of appetite, feebleness, emaciation, and swelling of the limbs—final complications which you have seen in several patients.

The dog occasionally suffers from "dry" pericarditis of simple or tuberculous character, which ends by producing numerous adhesions between the two opposing layers of the pericardium. In this form functional disturbance is seldom much marked, and the disease sometimes remains unrecognised until *post-mortem* examination. Even in the first stages digital pressure over the intercostal spaces of the precordial region produces no marked pain. The only constant sign is the rubbing sound, which usually persists for a considerable time, and may occur either during systole or diastole, but is always synchronous with the movement of the heart—a character differentiating it from the pleuritic rubbing sound which is synchronous with respiration. When adhesions have occurred the heart's action seems feeble, or the cardiac impulse may be imperceptible on palpation. You noted this latter symptom in a tuberculous dog killed a few weeks ago, at the *post-mortem* examination of which we found very complete adhesion of the two pericardial layers. At a later stage adhesion between these layers may be complicated by degeneration of the heart muscle, producing cyanosis, dyspnœa, ascites, and œdema of the limbs.

In general, when the veterinary surgeon is called on to examine a dog affected with exudative pericarditis, the disease has already been in

existence for some time, occasionally for several weeks; and, provided he makes a complete examination of the patient, and does not forget the heart, a careful consideration of the signs furnished by palpation, percussion, and auscultation should enable him to arrive at a correct diagnosis. Ascites is often the most striking symptom, and puts one on the right path. It is usually easy to differentiate between pericarditis and pleurisy. In pleurisy with moderate exudation, resembling that of pericarditis, the zone of dulness changes with the animal's position. By standing the animal on its hind legs the heart-sounds and vesicular murmur become readily perceptible, while the upper part of the thorax is resonant; in the normal standing position the resonance disappears or becomes dulled.

Pericarditis having been diagnosed, the question remains whether

FIG. 17.—Chest bandage.

or not it be of tuberculous character. The patient's bodily condition, the clinical signs, and the history only form a basis for presumptions. But in most cases the matter can be solved by an injection of tuberculin; and even when this appears to fail, recourse may be had to inoculation of a guinea-pig with a little pericardial serosity.

As I said at the commencement, most of our patients are affected with pericarditis complicated with ascites. Unless the pericardial symptoms appear menacing, tapping may be deferred, and attempts made to assist reabsorption of exudate by counter-irritants, diuretics and purgatives. I am in the habit of rubbing the precordial region with antimonial ointment, and to prevent the animal licking it, I apply a bandage over the spot (Fig. 17). I prefer this to cold compresses or sinapisms. In addition to milk diet, I prescribe internally calomel or bicarbonate of soda and digitalis.

When, despite treatment, the exudate increases and the symptoms become more marked and alarming, or when even on first examination the general condition appears dangerous, I puncture the pericardium.

Operation is as follows:—The precordial region is prepared by clipping away the hair, and shaving the skin a little below the centre of the zone of dulness for a distance of two or three square inches. The parts are afterwards washed with alcohol, and with a ·1 per cent. solution of sublimate. I prefer an aspirator provided with an india-rubber tube, and I proceed as you saw in the case of our last patient. The air being exhausted from the cylinder of the aspirator, the instrument is passed to an assistant; I introduce the point of the needle at the centre of the prepared surface, through the fifth intercostal space three or four fingers' breadth above the lower margin of the thorax. As soon as its end has fairly entered the thoracic wall I open the tap connected with the aspirator; then I very gently push forward the needle until liquid appears in the glass index of the rubber tube. Operating in this way the needle need only just enter the pericardium, and with a short point, injury of the heart (which is always pushed upwards and shortened in its vertical axis) need not be feared. Furthermore, by using a small needle, fluid is very slowly withdrawn and danger of syncope prevented. In the absence of an aspirator, puncture may be effected with a fine trocar. After operation the wound is closed by painting with collodion, and the parts covered with a cotton-wool dressing.

Should the exudate again form, reproducing the symptoms, operation must be repeated. To prevent further recurrence in such a case, a few drachms of very dilute iodine solution or some other antiseptic liquid may be injected into the pericardial sac after removing the exudate.

During the following days the patient is fed on milk, milk preparations, meat juice, or fragments of raw meat. When appetite returns, more substantial food and tonics may be given.

When pericarditis is complicated with ascites I generally remove the peritoneal fluid by tapping the abdomen, but this is not always necessary. Once the pericardium is relieved, the peritoneal exudate tends naturally to become absorbed. Its disappearance is assisted by administration of diuretics.

The reason why treatment so generally fails is that, in the majority of cases, pericarditis is produced by tuberculosis. In such case, puncture, whether or not followed by iodine injections, can only produce temporary improvement. Even when tuberculosis is exclusively confined to the pericardium (I have seen a case of this kind) the liquid is reproduced, and the patient dies from complications of pericarditis, or from progressive emaciation.

XXVI.—PNEUMONIA IN THE HORSE.

At the present time we have in hospital three horses which have recently been attacked with pneumonia, affording us a particularly favourable opportunity for studying the disease. You have closely examined all three, and have seen that as regards the symptoms and course of the disease they present notable differences.

The first of these patients, a nine-year-old gelding, entered on the 14th April suffering from pneumonia of three days' standing. It was very dull, but still took note of what went on around it. The conjunctivæ were saffron-yellow in colour, the respiration and circulation accelerated, the pulse strong and regular. From both nostrils, and especially from the right, a little yellowish rusty discharge escaped. Percussion showed partial dulness in the lower third of the right lung. On auscultation a moist crepitant râle was heard; the temperature was 40° C. (104° F.).

We were informed that on the previous day the animal was seen to be ill. It had been at work from morning till night, and had been caught in several showers of rain. When placed in a box after examination the patient took some mash, hay tea, and a few oats. Treatment was as follows:—A mustard plaster was applied to the lower half of the chest, six ounces of ·8 per cent. salt solution were subcutaneously injected, and one and a half ounces of bicarbonate of soda were given internally. Food consisted of six quarts of milk per day, bran mashes, hay tea, and chilled water *ad libitum*.

Next day the general condition remained practically unaltered. The respiration, circulation, and temperature had undergone no marked change. On auscultation a tubal sound was heard opposite the centre of the left lobe. In the upper third of this lobe, and throughout the right lobe, the vesicular murmur was exaggerated.

On the following day the animal appeared distinctly better and brighter. I drew your attention to the tubal sound, which, being heard in the centre of an otherwise absolutely silent area, was unusually well defined. The appetite was good. The temperature had fallen half a degree (C.).

On the fourth day (that is the seventh of the disease) improvement was again marked. The animal was brighter and more lively, and ate all its food. The temperature was only 38·5° C. (101·3° F.), the tubal sound was feebler, and crepitation was returning.

The last symptoms soon disappeared, and the patient being convalescent left hospital. It had remained about twelve days.

This first horse illustrated in a remarkable degree the regular development of pneumonia; it was, in fact, a typical case of what is termed simple pneumonia.

The second patient, brought to the College on the evening of the 19th April, was a five-year-old entire horse, from a stable in which, during the preceding weeks, several cases of pneumonia had occurred. On the morning of entering hospital the horse had made a journey at a slow trot, and though it appeared less willing than usual, this was attributed to fatigue and the hard work of the previous few days. On returning at midday it refused food, and was seen to be dull and to be "blowing" slightly.

At six o'clock when we examined it the animal showed unmistakable signs of a grave morbid condition, which, according to the information furnished, would appear to have been pneumonia. The patient was greatly depressed, the conjunctiva injected, the mouth dry and hot, the pulse seventy per minute, the respirations forty-eight, and the temperature 40·3° C. (104·3° F.). Auscultation and percussion of the chest revealed no abnormal sound either in the lungs or the heart. All that was noticed was a certain exaggeration of the vesicular murmur, and impulse of the heart.

I prescribed mustard plasters to the chest, friction with mustard to the limbs, and the internal administration of six ounces of alcohol, four drachms of sulphate of quinine, and one and a half ounces of bicarbonate of soda. The animal was given gruel and milk every two hours. At a later stage we also had recourse to digitalis, calomel, subcutaneous injections of serum and of ether, and finally to warm carbolic enemata.

On the two following days the temperature remained between 40·5° and 41° C. (104·9° and 105·8° F.), the respirations thirty-five to forty, and the pulse seventy to eighty per minute. There was trifling cough and very little discharge. On the 22nd percussion revealed dulness over the lower half of both pulmonary lobes; on auscultation moist crepitus was heard. During the following days the area of dulness and crepitation increased, especially on the right side; respiration became difficult, expiration sighing, and the heart's action violent, while fever remained intense. Each afternoon the patient was well covered up,

taken out of the stable, and left for some hours in the open air. On the fifth and six days we noted on the right side a slight deep-seated tubal sound, although crepitation persisted in parts of the lower region of both lobes. On the eighth day the temperature still remained at 40° C. (104° F.). Next day it began to decline, but the general and local symptoms diminished less rapidly than in the first patient, only disappearing completely on the fourteenth day.

In our third patient the disease behaved very much as in the preceding. Both lungs were affected, the left more severely than the right. For several days there was marked depression and cardiac disturbance. The temperature rose to 41·4° C. (106·5° F.), defervescence only setting in on the eighth day. On the twelfth the more important functions had become normal.

Although these two patients showed no symptoms pointing to the existence of grave lesions in other organs than the lungs, they had suffered from contagious pneumonia, contracted in their own stable.

During the last few months you have seen a number of other cases of sporadic and contagious pneumonia. I called your attention to their special features. I showed you that in simple pneumonia the inflammatory centre is early revealed and limited, the course is regular and typical, the defervescence is clearly marked and occurs on a fixed date, complications are rare, convalescence is short, prognosis favourable, and recovery almost constant. On the other hand, in contagious pneumonia the pulmonary lesion is generally at first deep-seated, invades neighbouring parts, or occurs at several points—is, in a word, multiple; the course is atypical or protracted, the defervescence slow, and sometimes attended by relapses; complications are numerous; convalescence is slow, and the prognosis grave.

Future investigations may possibly establish the essential identity of these two conditions—the unicity of pneumonia in the horse; possibly they will prove that simple and contagious, benign and malignant pneumonias are all produced by the same microbe, the virulence of which becomes diminished or exalted under the influence of ascertained or occult conditions. But up to the present we have only vague guidance on these points, and although from simple clinical signs it is sometimes difficult, and even impossible to say to which variety a particular case belongs, I risk the chance of criticism, and consider it better to study the disease under the two forms of simple or sporadic, and contagious pneumonia. Let us begin with the former.

Acute Sporadic Pneumonia (also termed Fibrinous, or Croupous) is

a common disease in the horse. Its frequency is explained, especially in horses used for heavy work in large towns, by the changes of temperature to which they are exposed, by the very active function of the lung during work, and by the susceptibility to cold presented by those kept in ill-ventilated stables.

Liability to pneumonia varies with age. The disease is commonest in young unseasoned animals, which are particularly sensitive to the action of changes in the weather, and in which the lung has not yet become accustomed to active work. In them, and in old animals which have arrived at the decadent period, the disease is gravest. Among predisposing influences are close, low-roofed, badly ventilated stables; debility; sluggish circulation; and various other causes which commonly favour the development of visceral diseases.

The chief exciting cause of pneumonia is the action of cold. In this respect authors are unanimous, and in consequence the disease has often been termed Pneumonia *à frigore*. The largest number of cases occur during the first four and last three months of the year. It is particularly frequent at the seasons of greatest changes in temperature—at the beginning of spring, and in the autumn. Sudden changes of temperature, and rain or moist weather, appear more dangerous than prolonged uniform cold. Chills, thus produced, may be assisted by other influences, especially by functional hyper-activity of the lung. The most favourable conditions for producing pneumonia are found when animals have been clipped, and whilst sweating are wetted by a shower, or suddenly exposed to a current of cold air. It is said that since the custom of clipping has become general, pneumonia has diminished in frequence. Nevertheless cases occur where it clearly appears to have favoured inflammation of the lung. In one of our patients, which had not been overworked or exposed to showers, pneumonia developed ten days after clipping. Many similar cases have been observed amongst the horses of the great Omnibus Company of Paris, where clipping has been given up.

For a long time it was believed that the action of cold was alone sufficient to produce pneumonia, but this is erroneous. The constant failures which followed attempts to produce pneumonia experimentally were explained by a special resistance of the organism, and by the absence of conditions which predispose to the disease. Bacteriological experiments in man have, however, shown the existence of another factor, which is, in fact, the *causa causans*. They proved that pneumonia is an infectious disease, produced by the entrance into and growth within the lung of a special microbe—the pneumococcus.

The first experiments on this point date from 1877. Some years

later Friedländer discovered in centres of pulmonary inflammation an encapsuled bacillus, which he regarded as the cause of the disease. Talamon afterwards found that the microbe of the disease is a coccus occurring in the form of little elongated grains, isolated or arranged in couples, and enclosed in a capsule ; it colours readily with aniline dyes and by Gram's method. This pneumococcus had previously been discovered by Pasteur in normal saliva. It exists in the bucco-pharyngeal cavity, and has also been found in the nasal fossæ, Eustachian tubes, and even in the bronchi. Nor is its field of pathological activity limited to the lung. It may produce pleurisy. It is also capable of passing into the blood-stream and causing other visceral diseases like endocarditis, nephritis, and meningitis—only to mention the principal. Cultures of this pneumococcus injected into the blood produce pneumonia, sometimes complicated with pleurisy, endocarditis, and pericarditis.

In human pneumonia it is constantly present, and without it the disease does not develop. Invasion of the lung is favoured by cold, which, however, only acts as an exciting cause by producing vascular or cellular disturbance, and by momentarily diminishing the resistance of the organism. The pneumococcus does not always act alone, being sometimes accompanied by streptococci or staphylococci. Even when the pathogenic organisms are confined to the lung grave disturbance may be produced in other viscera or tissues by the toxins they elaborate—that is, by soluble poisons, the injurious effects of which are specially marked in the heart and kidneys.

Simple pneumonia in the horse is certainly an infectious disease also, but its microbe has not yet been satisfactorily identified. In hepatised areas various germs are found, among others a micrococcus which presents certain analogies with the pneumococcus of man, and a diplo-streptococcus which, according to certain authors, is only a modified form of the microbe of contagious pneumonia.

It is possible that, as in man, the microbe which produces simple pneumonia acquires greater virulence by growth in the favourable medium offered by the inflamed pulmonary tissue, and that, having gained this increased activity, it may unaided produce pneumonia in animals exposed to infection. Such infection might easily occur through the medium of the discharge, which always contains a certain number of the infective organisms.

Against this theory of the contagious character of simple pneumonia, suggested by Cagnat in 1884, have been advanced innumerable recorded cases where the disease remains isolated, and where, in spite

of the cohabitation of an affected patient with other horses of all ages, the latter successfully resist. Many continue to consider contagious pneumonia and simple pneumonia (or pneumonia *à frigore*) as different affections, chiefly because the latter has not the eminently infectious character of the former; but also because it generally shows special clinical and anatomical pathological characters. Nevertheless I repeat, that very often when examining a patient it is impossible to decide by the clinical symptoms alone what form of disease we have to deal with, and it is now known that lobar hepatisation is not an anatomical character peculiar to pneumonia *à frigore*.

Many authors state that a first attack predisposes to a return of the disease. This opinion, founded on the widely accepted belief that after inflammation the lung remains more or less injured and enfeebled, is in no way confirmed by clinical observation. Not only have I failed to observe this predisposition, but I believe, on the contrary, that a horse which has previously suffered from pneumonia is less exposed to the disease, and that it acquires a certain degree of immunity. I consider that in animals which have made a *good* recovery from pneumonia we should regard the traces left by blisters, etc., on the chest as an indication of greater resistance, instead of considering them, as many practitioners do, as signs of grave depreciation. And when the disease returns in such horses, the second attack is almost always benign in character.

Simple pneumonia is ushered in by general disturbance, often by rigors, soon followed by gradual rise in temperature. The animals tremble slightly; the majority are depressed and stiff, the appetite falls off, the mouth is hot and dry, the bowels are constipated; the conjunctiva is injected, or yellowish in colour, and the skin is warm and moist. The respiratory movements are less frequent, expiration is sometimes sighing, there is often more or less oppression, and a dry, painful, deep cough. The pulse is rapid, full and strong. On auscultating the lung the vesicular murmur is found to be diminished in the lower portion of one or other lobe, sometimes of both. Percussion reveals lessened resonance. These symptoms become gradually more marked, and in twenty-four to forty-eight hours others appear. A reddish or rusty-coloured discharge runs from the nostrils, the colour being due to blood elements contained in the pulmonary exudate. Drying around the nostrils it forms a friable crust, resembling saffron, sulphur, or iron rust in colour. As a general rule this discharge remains somewhat abundant for several days. Sometimes a sanguinolent discharge is seen from the outset.

Auscultation of the lower portion of the affected lung reveals a well-marked moist crepitant râle during inspiration, and immediately after the paroxysms of coughing. At this point partial or almost complete dulness is noted on auscultation; while in the upper zone, which has undergone no change, the vesicular murmur is increased.

Hepatisation commences on the fourth or fifth day. The fever persists, the pulse and respiration reach their highest point, at certain moments expiration is sighing; the pulse is usually strong and full, but sometimes small and soft; cough is less frequent and discharge disappears, because the exudate collected in the pulmonary alveoli coagulates there. On auscultation over the large bronchi and surrounding parts one hears during inspiration and expiration, or only during the first part of the latter, an abnormal sound, sometimes strong, sometimes feeble and deep-seated—the tubal murmur. On the diseased side the lower part of the lung is silent, or only abdominal sounds transmitted by the solidified lung are audible; in the upper healthy part the vesicular sound is increased; towards the borders of the hepatised zone the crepitant râle often persists. On percussion dulness is complete throughout the entire pulmonary area invaded.

The constitutional symptoms are usually most marked from the fourth to the sixth day. When the disease develops regularly and promises a favourable termination, diminution commences from about the seventh day, marking the crisis. The patient is livelier, takes note of its surroundings, shows better appetite, respiration is less rapid and painful, the pulse less frequent, and the temperature falls. The cough returns, or if it has persisted becomes more frequent, and discharge reappears—now usually mucous in character, greyish, sometimes rusty or streaked with blood. The mouth is cooler, the excretions are moister, occasionally diarrhœa occurs. The urine increases in quantity, and through it are eliminated certain of the toxic products accumulated in the body. In some patients sweating occurs, in others little subcutaneous abscesses, termed critical abscesses, appear in different regions. On auscultation the crepitant râle begins to replace the tubal murmur formerly heard, and gradually advances from above downwards throughout the entire pulmonary area invaded, being in its turn soon replaced by the vesicular murmur. The percussion dulness simultaneously decreases, and in a few days the sounds again become normal.

Comparison of a certain number of cases of simple uncomplicated pneumonia shows that in this disease the temperature curve is typical. It steadily rises from the outset, reaches its highest point with considerable rapidity, remains for some days with slight morning and

evening oscillations, then on the fifth to seventh day suddenly and rapidly falls. The temperature often diminishes two to three degrees in forty-eight hours. In exceptional cases it falls below normal, but soon returns to that point.

Convalescence is short. Animals can generally return to work at the end of a fortnight.

Such is the regular course of simple pneumonia. It falls naturally into three periods—invasion, hepatisation, and resolution, which succeed one another at almost fixed intervals. Provided the patient is kept quiet and under good hygienic conditions from the outset, the disease almost always assumes this regular form, independently of treatment.

In certain cases pneumonia does not pass through all the above stages. It may become arrested, and resolution occur before the period of hepatisation is arrived at. Under such circumstances recovery is exceptionally rapid. This variety has been termed ephemeral or abortive pneumonia. You saw a case in one of our patients; moist crepitation persisted in the lower part of the left lung for two days, and was then suddenly replaced by the vesicular murmur.

In some cases complications occur. Diffuse pulmonary congestion, œdema of the lung, or myocarditis may produce asphyxia and death. Endocarditis, pleurisy, synovitis, arthritis, and para- or meta-pneumonic localisations are rarer than in contagious pneumonia.

Suppuration in the hepatised parenchyma is undoubtedly due to secondary infection by streptococci or staphylococci, and forms a very rare complication. M. Trasbot has only seen seven cases in a total of 168 personal observations. It is marked by sudden aggravation of symptoms; the fever increases, the skin becomes hot and dry, or from time to time moistened with sweat. Signs of excitement may occur, but most frequently the patient is profoundly depressed. Appetite is completely lost; thirst is marked; the heart's action becomes strong and rapid, the pulse more and more feeble, the respiration very rapid, short, and tremulous. On auscultation a gurgling or amphoric sound can be heard; on percussion a "*bruit de pot fêlé*" (cracked-pot sound). In addition, there is often a purulent greyish or sanguinolent discharge. When the abscess breaks into a bronchus its contents may be discharged through the trachea, and recovery is possible. But usually the hepatised portions of lung become infiltrated with pus, or purulent pleurisy develops and the animal succumbs.

Pulmonary gangrene is scarcely commoner than abscess formation.

Among 190 patients treated in his clinique, M. Trasbot only saw twelve cases. It produces general symptoms resembling those of pulmonary suppuration, and almost always rapidly leads to death. The principal symptoms are intense fever, with marked oscillation of temperature; profound depression; violent heart's action; loss of pulse; coldness of the extremities, and double-sided putrid discharge from the nostrils. It is well to remember, however, that putrid discharge is not (as many believe) an infallible sign of pulmonary gangrene; it may result from putrefaction of exudate in the dilated bronchioles.

Simple pneumonia very seldom assumes the chronic form. When this occurs certain symptoms disappear, but the cough, discharge, and difficulty in breathing persist, and the animals remain thin, feeble, and incapable of any considerable effort.

Let us now glance at the anatomical changes during the different stages of simple pneumonia. I have said that the disease is usually localised in one lobe, of which a greater or less area is invaded; it never occurs at several irregular centres, as is often the case in contagious pneumonia.

During the period of engorgement the diseased portion of lung is hyperæmic, infiltrated, and œdematous. It seems swollen and deep red or violet in colour; its tissue is denser, firmer, less elastic, and less crepitant than usual. Sections are smooth, of a livid red or marbled appearance, and the cut surfaces discharge large quantities of reddish sanguinolent or frothy serosity. The alveolar texture of the lung, however, can still be distinguished. Microscopic examination shows the capillary vessels to be dilated, engorged with blood, or ruptured. The epithelium lining the alveoli is partly shed, and the spaces themselves are filled with a liquid exudate containing large numbers of leucocytes, red blood-corpuscles, and multinuclear cells of epithelial origin. A similar exudate is found in the interlobular spaces, which are thickened, infiltrated, and œdematous.

During the hepatisation stage the portion of lung affected is more markedly swollen and no longer crepitant; its colour is deeper; its density and compactness are increased, causing it to resemble liver, and its tissue has become friable, so that it breaks down readily under the pressure of the thumb, forming a reddish pulp. Fragments removed from the hepatised mass, and dropped into water, slowly sink to the bottom. Sections are dark reddish-brown or blackish in colour, but on close examination this coloration is seen to be irregular; from the dark ground formed by the inflamed pulmonary tissue numerous little greyish-white rounded points stand out, as though

"set" in the tissue, indicating small masses of exudate which have been poured into the pulmonary alveoli, where they have coagulated and become adherent to the walls of the air vesicles. Sections are less smooth than at the former period; they have a granular appearance due to projection above the general surface of fibrinous coagula. Moreover they no longer transude liquid, but on scraping yield small quantities of blood-stained serosity, holding in suspension small opaque whitish granules. One might be led to regard these modifications in appearance of the pulmonary tissue as indicating complete disorganisation, but such is not the case. Microscopic examination shows the following condition:—The air-cells are plugged by fibrous clots containing leucocytes, red blood-corpuscles, epithelial cells, and large migratory cells, exhibiting highly refractile granules; in many cases the epithelium is partly preserved; many capillaries are obliterated, but the alveolar ducts, though thickened and infiltrated, are seldom much injured.

In human pneumonia, pneumococci are almost invariably found in the affected area, whatever the stage of the disease. The lesions of simple lobar pneumonia in the horse contain various microbes, the pathogenic action of which has yet to be demonstrated.

When resolution occurs, the exudate contained in the air-cells is freed, detached, and liquefied; the resulting material, which is got rid of through the bronchi, forms the discharge seen at this stage; the hyperæmia disappears, the alveolar ducts regain their normal character; the liquid which filtered into them becomes reabsorbed; the epithelium is restored at the points where it had been lost, and the lung soon regains its function in an almost perfect degree.

The *post-mortem* examination of patients dead of pneumonia sometimes reveals generalised pulmonary congestion, pleurisy, or myocarditis, sometimes purulent or gangrenous centres in the hepatised tissue.

Pulmonary suppuration assumes several forms; in certain cases small abscesses are found scattered throughout a mass of hepatised tissue; in others there are present one or more large abscesses, which usually communicate with large bronchi. The contained pus is whitish, creamy, and odourless, or reddish in colour, resembling wine lees, and offensive.

Gangrene is oftenest represented by little greyish-yellow tracts scattered through the hepatised part. Sometimes it is "massive," and affects a large portion of the diseased lobe; it may assume various appearances, the dead tissue being soft, blackish, violet, greenish grey, or reduced to the condition of a granular mass. The periphery of

these gangrenous patches is not usually well defined, but shades off into the adjacent hepatised tissue, which is gradually invaded by the necrotic process.

During the course of the disease the bronchial lymphatic glands become swollen, but never of great size.

The diagnosis of pneumonia is easy. The veterinary surgeon is seldom called in until the second or third day after the onset. The somnolence, depression, rapid, painful, and often moaning respiration, and the yellowish colour of the conjunctiva are all significant. In many cases pneumonia can be surmised after examination of the conjunctiva and a glance at the flank. With a little practice in clinical observation one is rarely mistaken. The rusty discharge, when present, is pathognomonic. Auscultation and percussion indicate the position and extent of the inflamed area.

In bronchitis the cough is strong and paroxysmal, the discharge muco-purulent, the respiration less frequent, and the fever less active. From the point of view of their relative frequence pleurisy is rare as compared with pneumonia; and you know, furthermore, that differential symptoms exist. As to acute primary endocarditis, you may possibly never meet with it.

Provided the ordinary course and characters of pneumonia are known, complications should early be detected. In a patient in which resolution was deferred beyond the ninth day I discovered secondary pleurisy, the only case which I have seen during the course of the present year.

The prognosis of simple pneumonia is serious, on account of the functional importance of the affected organ; but except in the cases of old, feeble, and emphysematous patients, and those suffering from cardiac disease, pneumonia only proves fatal when followed by complications, such as diffuse congestion of both lungs, œdema, suppuration, gangrene of the lung, or inflammation of the heart muscle.

Careful treatment usually prevents such accidents. The mortality of uncomplicated cases is scarcely 5 per cent.

When simple inflammation of the lung develops regularly and is unattended with complications it tends towards resolution. Promptitude in treatment is very important. If the disease is not recognised at the beginning it may become greatly aggravated by work.

The animal is isolated in an airy box, which should be kept at a moderate and regular temperature, and is kept warm by abundant clothing. If appetite is retained, mashes, barley or oatmeal gruel, hay

tea, etc., may be given. The patient should have constant access to chilled water or gruel; perfectly cold water is sometimes injurious. If it eats little, and will not touch ordinary food, milk may be prescribed. Most horses take milk readily to the extent of six, eight, or ten quarts per day. Some, however, refuse it, and will not swallow even a mouthful, appearing to have a distaste for it; but, after a little patience, end by taking it well. The attendant should hold the animal's head, bring the bucket containing the milk near its mouth, and introduce a little by means of the hand. This may be repeated several times, and the milk then be offered in the bucket. If the horse will only swallow a little he very often ends by emptying the bucket at a draught, and afterwards makes no difficulty about taking it. To starve cases of pneumonia (as is still done by many practitioners) is a mistake. They should, on the contrary, be carefully fed and their strength sustained with such foods as they seem most to like.

A first case of pneumonia should not necessarily be regarded as sporadic, to the exclusion of prophylactic measures. It is always better to isolate the animal, especially if other young horses are in the same stable.

I do not recognise any specific treatment of pneumonia. The management of the case varies according to the animal's constitution, the intensity and stage of the disease, the degree of fever, and the predominance of particular symptoms.

Bleeding, again revived at the present day in the treatment of pneumonia in man, has never been entirely abandoned in veterinary practice. It may prove of real service by its double mechanical and chemical action. During the hepatisation stage of pneumonia especially the greatest danger is often to be found in the condition of the heart. In consequence of the obliteration of vessels in the hepatised area the right heart finds its work greatly increased; it may falter, and even succumb. The removal of three to six quarts of blood, depending on the animal's weight, diminishes the circulatory disturbance and assists the heart, which beats more easily. In addition to this purely mechanical effect bleeding has two others, not less valuable. In patients in which the blood is greatly vitiated by the presence of microbic poisons, bleeding before the crisis removes from the circulation a notable amount of these poisons, at the same time increasing the bactericidal power of the serum; and if supplemented by injection of the chemical solutions of which I shall shortly speak, this antitoxic action is favoured. Furthermore it is proved that bleeding increases oxidation processes, and thus assists in eliminating poisons from the blood and tissues. But to pretend that removal of blood can check the

infectious process itself is evidently an exaggeration. It never arrests the course of pneumonia, and I regard it as simply shortening its duration.

Counter-irritants almost always give relief, especially when early resorted to. Mustard is perhaps the best, and is applied in the form of a plaster to the sides and under parts of the chest. It may also be used for rubbing the limbs; but it is ill-judged to extend its application excessively. The plaster is left in position for several hours. The essential oil which it gives off produces smart irritation of the skin, and abundant infiltration into the subcutaneous connective tissue. During the hours succeeding its use the patient is less depressed, the breathing and circulation are markedly relieved, and there is often temporary diminution in the fever. Counter-irritation also renders phagocytosis more active. Essential oil of mustard applied with friction has the same effects as a plaster. In grave cases of pneumonia, where the hepatisation stage is abnormally prolonged or marked by serious heart symptoms, many practitioners use blisters. Not only is the effect of blisters mediocre and doubtful, but they have the disadvantage of rendering the patient uneasy, and of preventing the practitioner afterwards following the course of the disease by auscultation, etc. They often blemish, and are not without other grave drawbacks. In some cases absorption occurs, producing irritation of the kidneys.

The value of "issues" has also been exaggerated, and they are much less used than formerly, being now practically confined to the region of the chest. They produce acute suppurative inflammation around the points of insertion; similar results follow the subcutaneous injection of oil of turpentine, or of any irritant liquid. Such means of treatment, however, may even facilitate infection. Some practitioners claim to draw valuable conclusions from their action; if suppuration is free, the pneumonia is taking a favourable course; but failure in this respect always constitutes an unfavourable sign.

As in other infectious diseases, saline or alkaline solutions have an excellent effect. The resistance of the organism to infection is proportionate to the degree of alkalinity of the blood, but as this alkalinity tends to diminish I often utilise subcutaneous injections of different chemical solutions, particularly of ·7 to ·8 per cent. salt solution in daily doses of six to fifteen fluid ounces. These salines affect the blood-plasma, rendering it more alkaline and increasing its bactericidal properties, at the same time stimulating secretion and the elimination of toxins. Alkalinity of the blood may also be favoured by the administration of daily doses of one and a half to three ounces of bicarbonate

of soda, given in the drinking-water. Its effects are excellent at all stages of the disease.

Antimonial preparations—tartar emetic and sulphide of antimony—adopted from human medicine, have similar antiphlogistic effects to bleeding, though they act in a different manner. Tartar emetic is given in doses of one and a half to three drachms per day in the food. It renders the breathing easier, and slows the circulation, but in general its therapeutic value has been greatly over-estimated.

Dilute alcohol in the form of brandy, whisky, rum, or wine is much used, and not without benefit. It checks excessive tissue metabolism, supports the animal's powers, acts as a tonic, tends to lower temperature, and has the advantage of being readily taken in the drinking-water or in electuary. I frequently prescribe four to eight fluid ounces of brandy per day. It can be given from the commencement and continued until resolution begins, the dose being varied according to the symptoms.

Digitalis is of unquestionable value, especially when the heart muscle shows signs of exhaustion, as indicated by rapidity and feebleness of the pulse. It is given in doses of three quarters to one and a half drachms in electuary, and continued for several days. In many cases change in the heart's action and the condition of the vessels follows in a few hours, the heart beats becoming less powerful and sudden, and the pulse stronger and more regular. Doses of two to three drachms, given by some practitioners, are excessive. When long continued, digitalis produces change in the heart fibres, which appear to undergo fatty degeneration.

Iodide of potassium has been given at all stages of the disease in doses of one and a half to three drachms per day. Various good effects are attributed to it, such as those of moderating the circulation and respiration and of lowering temperature. Its value, however, is slight except during the period of resolution, when it favours absorption of newly formed tissue in the bronchial glands, and thus prevents compression and atrophy of the left recurrent nerve, one of the causes of chronic roaring.

Salicylate of soda may prove of value in lowering temperature, while as a general antiseptic it is preferable to salicylic acid, which irritates the gastro-intestinal mucous membrane. It has been strongly recommended during the period of resolution in order to prevent the attacks of synovitis seen during or after pneumonia.

Quinine salts, like the sulphate and hydrobromate, have recently been used by many practitioners. They temporarily lower temperature and slow the circulation, thus exercising an antifebrile and tonic effect.

They are also recommended where suppuration or gangrene is feared, and can be given in electuary in daily doses of one and a half to four drachms.

Sulphate of soda in doses of three to six ounces stimulates the intestinal secretion and favours free circulation of digested material. During the early febrile and hepatisation periods it is given like the bicarbonate in drinking-water or mashes.

Cold enemas to diminish constipation and fever, nourishing enemas to sustain the bodily strength when ordinary food is refused, and antiseptic enemas to prevent or limit suppuration or pulmonary gangrene, are also measures deserving of attention.

Suppuration and pulmonary gangrene, as I have said, almost always prove fatal. An abscess formed in the midst of pulmonary tissue may under exceptional circumstances open into a bronchus, its contents become evacuated and its walls cicatrised : a gangrenous fragment may similarly be got rid of or may become encysted, the patient in either case surviving ; but such endings are rare, and treatment is of little value. The patient's strength must be supported by milk, hay tea, and fluid nourishment to which has been added alcohol. Antiseptics are employed in the form of fumigations. intra-tracheal, subcutaneous, or intra-venous injections. Solutions of iodine or carbolic acid are often administered by the last method. Direct injection of antiseptics into the gangrenous centres has been little used in the horse, and on the several occasions I have performed it the result was unsatisfactory. Puncture of a purulent or gangrenous centre through the thoracic wall, followed by evacuation of the contents and drainage of the cavity, has been attempted as a last resource where the diseased lung was adherent to the wall of the chest.

XXVII.—PNEUMONIA IN THE HORSE (CONCLUSION).

In equine pathology the name of Contagious Pneumonia is given to a form of inflammation of the lung which was long confused with simple pneumonia, and with the abdominal form of influenza. More than half a century ago the horse was known to suffer from an inflammatory lung disease, which simultaneously affected numbers of animals, and differed in its course from pneumonia *a frigore*. It was described under the titles bilious pneumonia, adynamic or ataxic pneumonia, and stable pneumonia.

Veterinary journals contain reports regarding this affection, which are now more or less ancient history. The cases related are always referred to simple causes, especially to the action of cold on a number of patients placed under similar conditions of hygiene, feeding, and work.

The views at present held in regard to contagious pneumonia are founded on clinical observation and laboratory work, and only date back about ten years. In France, Cagnat, of St. Denis, published in the *Archives vétérinaires* for 1884, the first cases clearly establishing the occurrence of contagious pulmonary inflammation in the horse. Some years later Messrs. Benjamin and Brun adduced others. About the same time Siedamgrotzky and Dieckerhoff in Germany published essays on this affection, each observer regarding it from his own particular standpoint. In 1887 Schütz isolated and cultivated a micro-organism, which he considered the specific agent. Since then investigations have become very numerous. MM. Chantemesse and Delamotte, Galtier and Violet, have found in the lesions two microbes, which they considered different from that isolated by Schütz. MM. Cadéac and Leclainche have written good monographs on the subject. M. Trasbot, who described the disease in his lectures under the name of "Stable Pneumonia," penned a learned article on it in the eighteenth volume of the *Dictionnaire pratique de Médecine et de Chirurgie vétérinaire*. Finally,

we owe the history of several carefully studied epidemics to certain of our military colleagues.

Contagious pleuro-pneumonia of the horse results from the entrance into and development within the organism of a specific pathogenic microbe. Sometimes the animal is infected by contact with a diseased subject, at others infection is mediate. The disease is most commonly seen in large stables where the work necessitates frequent renewals of stock. One of the new-comers is first affected; a week to fourteen days later a second shows symptoms, and the disease successively attacks a number of animals, comprising one third, one half, or two thirds of the whole number, sometimes even more—in one of Cagnat's series twelve out of fifteen, and in some I have myself seen, seven out of nine.

The stables of horse dealers, omnibus companies, remount depôts, cavalry quarters, and veterinary infirmaries, are most commonly invaded. Once introduced the disease may continue for a long time in an enzootic form, diminishing and again reviving, the revivals almost always following the introduction of freshly bought horses.

It attacks young, adult, and old animals, though certain ages are more subject than others. Horses between four to eight years old, especially if recently brought into work, are those most commonly affected; aged animals are less subject. If during an outbreak of this form of pneumonia it becomes necessary to introduce fresh horses, aged animals should always be given the preference, young horses almost invariably becoming infected.

In stables where the disease was raging I have often noticed that horses which had previously suffered from an attack remained quite unaffected. Many other practitioners have made the same observation. An attack undoubtedly confers immunity for a certain period, sometimes during the animal's whole life; though in most instances this immunity diminishes and may entirely disappear with lapse of time. Instances of recurrence, adduced in opposition to this idea, in no wise weaken it, being readily explained by the many forms assumed by pneumonia, and by the gradual loss of acquired immunity.

Generally speaking, then, experience shows that one attack renders the subject refractory or little susceptible to a second. Cagnat well understood this, and with the courage of his convictions even went so far as to recommend that when purchasing preference should be given to horses whose chests showed traces of the counter-irritants applied during a previous attack of pneumonia. That is to say, he recommended exactly the contrary of what is usually practised.

In comparing contagious pneumonia and the abdominal form of influenza from the point of view of the subtlety of infection and rapidity of extension marked differences, however, are apparent. As Friedberger and Fröhner remark, the diffusion of the specific agent is usually slower in the former case, and its method of propagation different. Although in certain outbreaks among army horses contagious pneumonia affected ten, twenty, or thirty subjects within a few days, the occurrence is exceptional; whilst in the same period the abdominal form of influenza might have attacked hundreds of animals. Another difference noted by the same authors, confirmed by many practitioners, and again recently mentioned by M. Laporte, has reference to the mode in which the infection spreads. Contagious pneumonia attacks irregularly, often affecting animals far removed from the first case, while influenza is more frequently transmitted from one case to another, following a fairly regular line.

Direct transmission is the rarest method of contagion. The disease is generally spread by intermediate channels, such as the air, forage, manure, pails, or mangers, or even by attendants, grooms, owners, or veterinary surgeons. In one instance the disease was communicated to a mare, isolated far from the infected stable in a special place, by means of a mash taken from the manger of a horse suffering from pneumonia. In order to prevent it being "wasted" the groom had given this mare the bran left by the patient.

Many veterinary surgeons have seen enzootics of contagious pneumonia in stables without infection having been introduced by recently bought animals, and in towns or parts of the country where the disease did not previously exist. In these cases the locality and especially the soil have been blamed. In all probability the infectious organisms had been in existence, but had long remained dormant or continued growing as saprophytes, and afterwards, under the influence of undetermined conditions, recovered their virulence and primary activity, causing an outbreak of disease.

The contagious material enters by the respiratory passages suspended in the inspired air, or by the digestive mucous membrane along with food or drink. Schütz declared the specific agent to consist of a little ovoid bacterium generally arranged in twos, the biological characters of which he described. Though pathogenic in the horse, rabbit, guinea-pig, mouse, and pigeon, it is without action on the pig and fowl. Inoculation of a culture of this microbe into the horse reproduces the disease. If introduced into the parenchyma of the lung by transfixing the wall of the chest and the pleura with an antiseptic needle or trocar, the symptoms of contagious pneumonia appeared in

a few hours, developing in the usual way and producing necrotic lesions in the lung and degenerative changes in the viscera. In contradistinction to the pneumococcus of man, which is delicate and ephemeral, and sometimes disappears from the lesions after a very few days, the bacteria in question show considerable resistance to destructive influences. In patients which survive they may long preserve their vitality, multiplying in the necrotic centres surrounded by a zone of fibrous tissue, and when these centres are in communication with the bronchi being continually discharged, and rendering the nasal discharge virulent for months. Convalescent or apparently cured cases in which the lung contains such centres long remain dangerous. They perpetuate the disease in certain stables, or introduce it into other previously healthy quarters, where the first cases are naturally referred to the action of atmospheric changes.

Though admitted by some authors, the specific character of this microbe and the powers attributed to it by Schütz have been contested by others, especially by Hell and Baumgarten. In 1890 Hell undertook certain researches consisting in cultivating, staining, and inoculating with the organism, in order to determine the analogies and differences which existed between it and the several streptococci. From them he concluded that by the bacteriological methods then in use no clearly marked difference could be established between the microbe in question on the one hand, and the *Streptococcus pyogenes* of the horse and the streptococcus of erysipelas in man on the other; and furthermore, that these species are similar from the morphological and biological points of view, and from the manner in which they behave when inoculated.*

* Recent researches by M. Lignières seem to show that the microbe described by Schütz is the streptococcus of strangles, and that it only plays a secondary part in the ætiology of pneumonia in the horse. It is generally, but not always, found in the lungs of horses dead of pneumonia. The true microbe of pneumonia is said to be the "*cocco-bacille typhique*" of the order *Pasteurella*. This micro-organism, which grows as a saprophyte in forage, manure, water, and soil, and becomes pathogenic under the influence of causes at present unknown, appears as a monococcus, diplococcus, or as a little bacillus with rounded extremities. The last is the "true" form of the microbe; at the moment when it divides it appears as a diplococcus. The monococci result from complete and recent separation of the diplococci. Finally, under certain conditions these microbes take the form of "*streptococco-bacilli*." The organism is aërobic, produces no spores, and is killed in less than a quarter of an hour by a temperature of 65° C., but grows freely in peptonised bouillon and on gelatine at 20° C. It is pathogenic for the guinea-pig, rabbit, and horse, and rapidly kills these animals on subcutaneous inoculation. M. Lignières has found it in cases of pleurisy, infectious pleuro-pneumonia, in broncho-pneumonia, and in infectious sore throat, in pneumonia *a frigore*, in the abdominal form of influenza, in the pneumonia of strangles, and in "stable pneumonia." All these affections are said to be but varieties of "*Pasteurellosis*."

Infectious pneumonia is due to the "*bacille typhique*," which is able to multiply in

The symptoms of contagious pneumonia are by no means so constant or so uniform as has been suggested by certain authors. Among those regarded as most important some are susceptible of modifications in their expression and intensity, which are apt to deceive the practitioner who only looks for typical cases. As in the simple form, three periods may be distinguished: (1) onset and increase; (2) hepatisation; and (3) resolution, gangrene or suppuration.

The onset is usually sudden, and too well marked to be overlooked. A few patients remain fairly bright and lively, and continue to take part of their food; but the majority are dull and depressed, hang back from the manger, and do not touch anything. They show rigors, trembling fits, and signs of sore throat, bronchitis, or slight colic. In the play of symptoms now commencing two signs, however, overshadow all others, the acceleration of breathing and the fever. With rare exceptions the flank movement is already very rapid, and attracts attention. The respirations are from 20 to 30 per minute; sometimes inspiration is fairly free, sometimes very shallow. The temperature rapidly rises to a high point, often marking 40°, 40·5°, or even 41° C. (104° F. to 105·8° F.), before the animals are noticed to be ill. I twice noted the latter figure on first examining animals which only the evening before had appeared healthy both in regard to work and feeding. Where patients have been observed from the outset the temperature has often risen 3° C. in twenty-four hours.

The conjunctiva is usually reddish, sometimes of a yellowish tint, the

the lung chiefly in consequence of being associated with the streptococcus of strangles. At the moment when the "*bacille typhique*" affects the organism, the streptococcus of strangles (which is widely distributed) is often to be found in the upper air-passages, without, however, having produced any manifest indications of its existence. Thanks to the depression of the system produced by the "*cocco-bacille*," the streptococcus multiplies in the lungs, forms caseous centres around the bronchi, and then gradually invades the parenchyma of the lung and more or less completely the entire organism.

Inoculation of healthy animals with attenuated "*bacilles typhiques*" should render them proof not only against the abdominal form of influenza, but also against pneumonia of the same character. Hence the use of vaccination as a prophylactic measure in affected stables. Sick horses should be simultaneously treated with injections of protective strangles serum and of "*sérum antityphique*."

Experience has not yet pronounced on these laboratory suggestions. The first test of the protective method with the vaccine of "*Pasteurellose équine*," however, was made in the stables of the Compagnie Générale des Voitures de Paris. The result was as follows:

"From the 4th October, 1897, to the 12th May, 1898, 5007 horses were bought. All the odd numbers were twice vaccinated, whilst the even numbers were left as controls. Up to the 31st October, 1898, two hundred and fifty-four horses had died from chest diseases, one hundred and fifty-eight which had not been vaccinated,—that is to say, a loss of 6·01 per cent.; and ninety-six which had been twice vaccinated, that is a loss of 4·03 per cent. Seven horses were killed by the use of insufficiently attenuated vaccine."

mucous membrane of the mouth warm, the tongue coated, the ears and extremities are cold. Movement appears painful, and the patient is sometimes unsteady on its legs. In most the cough is deep, paroxysmal, and accompanied by discharge of a little greyish or rusty mucus, which may be streaked with blood. In some there is slight hæmorrhage from both nostrils, a symptom which may recur several times during the course of the disease.

Auscultation and percussion of the lung seldom reveal any modification in the pulmonary sounds or pulmonary resonance. The early lesions appear to affect the deeper seated portions of the lung around the bronchi, the superficial layers of the affected lung remaining unchanged, so that percussion and auscultation are only useful at a later stage. You have seen this in many of our patients. Exceptions, however, occur. In some animals various stethoscopic signs like disappearance of the vesicular murmur, or the existence of crepitation, may be noted soon after appearance of the first symptoms. In one case we heard the tubal murmur on the right side after the third day, the percussion sound over the corresponding lower half of the thorax being simultaneously dull. It must be remembered that cases of this nature—in which the auscultation and percussion signs resemble those of simple pneumonia—are somewhat frequent, because, as in that disease, the pulmonary lesions may be extensive, involving an entire lobe or the whole thickness of the lung almost from the first. Auscultation over the præcordial region reveals increase both in power and frequency of the heart's action, while the two normal sounds are slightly accentuated. The pulse is rapid, full, and strong, or may already have become distinctly weak.

During the stage of augmentation the first symptoms become aggravated or variously modified, and others appear. The temperature often exceeds 41° C. (105·8° F.), and shows daily oscillations to the extent of one degree or more. Respiration remains very rapid and shallow; occasionally it appears hesitating. In some patients auscultation and percussion still reveal no pulmonary change. Crepitation and partial dulness usually occur on the third or fourth day, murmurs and dulness twenty-four or forty-eight hours later. The circulation is always rapid; the heart beats violently, the sounds being either normal or modified in intensity and sometimes in rhythm; the pulse loses its strength and fulness. The conjunctiva is reddish yellow or icteric; sometimes hyperæmia is more marked, and accompanied by slight infiltration. Many animals still take mashes, milk and a little hay; some pass dry, hard, coated fæces; in almost all thirst is great; dulness and loss of strength are more marked, the gait is vacillating, and the tail hangs

limp. Some, however, appear much less depressed, and in entire horses erections occasionally occur.

During the period of hepatisation most of the preceding symptoms subside. Respiration, however, becomes more and more rapid, is painful, difficult, and sometimes moaning; when pleurisy occurs as a complication, inspiration and expiration are separated by a distinct pause. The cough and discharge usually disappear. In one of our patients I noted on three occasions discharge of blood from both nostrils, due undoubtedly to pulmonary hæmorrhage; but this is a rare occurrence. The pulse is very rapid, small and feeble, occasionally irregular or intermittent; sometimes there is a venous pulse. The temperature usually remains stationary except as regards the aforementioned daily oscillations, but it may rise to 41·8° or even to 42° C.* (107·2° F. to 107·6° F.); sometimes it is very irregular, and shows variations of 1° to 2° C. within twenty-four hours. After the fourth day pulmonary changes can usually be readily detected, though, as you have seen in one of our cases, they may remain concealed until the fifth day. Some months ago a colleague asked me to examine one of his horses which had been very ill for several days, and which he thought was suffering from endocarditis. On auscultation I certainly detected cardiac disturbance, but I also noted absence of the vesicular murmur on the right side, and slight crepitation at several spots. The diagnosis was clear. Next day there was a tubal murmur; the pneumonia had been in existence for six days.

Depending on whether pneumonia is lobular or lobar, the signs recognised on auscultation and percussion differ very greatly. In the lobar type the stethoscopic sounds are those of simple pneumonia; in the lobular the vesicular murmur is at several spots replaced by a crepitant râle; but if the centres of lobular pneumonia become confluent the signs noted are those of extensive hepatisation, a tubal murmur being heard with more or less complete dulness in the lower region of one or both sides.

At this period, if at all, pleurisy sets in. Its onset is insidious, and it remains unrecognised until exudate becomes abundant. Physical examination then reveals bilateral dulness extending to a varying height, and limited towards the centre of the chest by a horizontal line; loss of the vesicular murmur over the whole of this region; existence of a tubal sound; and disturbance in the respiratory movements of the chest and flank. When these phenomena coincide with diminution in the pneumonia symptoms, as you saw in one of our last patients, pleurisy is clearly indicated.

* M. Brun observed a rise in temperature to 42° C. in a horse which afterwards recovered. Professor Cadiot had a similar case where the temperature rose to 41·9° C.

Resolution, announced by improvement in the general symptoms, by return of appetite, sinking of temperature, polyuria, and sometimes by the appearance in different parts of the body of "critical abscesses," usually occurs a little later and rather more slowly than in simple pneumonia. As in the latter, the crepitant *râle* returns in the hepatised regions, and is everywhere gradually replaced by the vesicular murmur. For some days the patients have a loose paroxysmal cough, and muco-purulent discharge from both nostrils. Under suitable hygienic conditions relapses are rare.

A serious and unfortunately somewhat frequent termination is gangrene, produced by tissue-destroying toxins elaborated by the pneumo-bacteria alone or in association with other organisms. Gangrene is, therefore, either mono- or poly-microbic. The general symptoms then become still more aggravated, appetite is entirely lost, the heart beats tumultuously, the pulse becomes very feeble or is even lost, the temperature remains high, but with sudden oscillations, and a greyish stinking discharge sometimes containing fragments of necrotic tissue runs from the nostrils. On auscultation various sounds are heard: tubal murmurs, crepitation, gurgling, amphoric, or cavernous sounds, and sibilant *râles*. At certain points the percussion sound is dull, at others tympanitic; sometimes the *bruit de pot fêlé* ("cracked-pot sound") is well marked. As the gangrene and consequent septic intoxication progress, the general symptoms become more and more alarming. Rigors, trembling fits, and sweating occur; the extremities and skin become cold, weakness is extreme, and the face very anxious. At last the patient falls to the ground exhausted, struggles more or less, and speedily succumbs. Though gangrene is not always fatal, recovery is rare.

Abscess formation in the lung sometimes occurs as an original complication, or accompanies gangrene. It may be suspected, towards the end of the hepatisation period, if, while remaining high, the temperature oscillate markedly and be accompanied by rigors, trembling, sweating, groaning, and great loss of strength. So long as the abscess remains closed, auscultation and percussion give little information; but if one break into a bronchus a cavernous or gurgling murmur may be detected, while on percussion tympanitic resonance or the "cracked-pot sound" is heard. A more or less fœtid purulent discharge escapes from the nostrils. Whilst not invariably fatal, pulmonary suppuration, like gangrene, is extremely grave.

Among extra-pulmonary complications myocarditis occupies the chief place. Inflammation of the heart muscle occurs secondarily during the course of infectious pneumonia, and is clinically revealed, as I have told you, by disturbance of the heart and pulse. The cardiac contrac-

tions are at first violent and palpitating, afterwards becoming more and more feeble in proportion as the muscular fibres are more numerously affected with fatty degeneration. Intermittency is often observed. On auscultation a doubling, rolling, or prolonged first sound may be heard, or in exceptional cases a trifling systolic or diastolic murmur. The pulse is irregular, intermittent, and almost imperceptible.

Like the heart muscle, the endocardium may be injuriously affected by microbes suspended in the blood, or by toxins emanating from the pulmonary centres. Sometimes endocarditis accompanies myocarditis, sometimes it develops singly. It usually affects the mitral or aortic valves, and is generally accompanied by stethoscopic signs permitting of diagnosis. But too often during an attack of pneumonia the state of the heart is neglected, and this complication altogether escapes notice, being only recognised long afterwards when the valvular insufficiency produced by contraction of the injured valves, or by vegetations developed near their free borders causes grave functional disturbance.

Exudative inflammation of the pericardium is much rarer than that of the endocardium. Its presence is indicated by the usual signs. When trifling in quantity the exudate is only discovered on *post-mortem* examination, but when abundant it may be recognised by the increased area of præcordial dulness and by the diminution or absence of the cardiac sounds.

Nephritis is another fairly common complication, marked by colic, restlessness, difficulty in moving the hind limbs, and sometimes by hæmaturia. The urine contains red blood-corpuscles and renal casts in which microbes may be detected. When double, nephritis usually kills rapidly, though in occasional instances death is long deferred.

Enteritis first produces dull colicky pains, which gradually become more severe and are accompanied by diarrhœa, sometimes by blood-stained evacuations.

Meningo-encephalitis is rare. It gives rise to excessive excitement, convulsions, and epileptiform attacks, which may or may not alternate with periods of coma, and usually proves fatal in a few days. You saw this complication in a patient which died rapidly from bulbar hæmorrhage.

Meningo-myelitis and various forms of toxic paralysis may be seen affecting among other structures the recurrent and sciatic nerves, the bladder, rectum, and penis. The most frequent is paralysis of the penis; it almost always appears during the period of resolution; in a few days the organ may become greatly swollen and entirely beyond control.

Contagious pneumonia, like the abdominal form of influenza, is

sometimes followed by laminitis affecting the front, the hind, or all four feet. Certain myopathic paralyses, phlebitis, and purpura are also possible accidents. Finally, the disease may be complicated with ophthalmia or deafness.

Secondary inflammations of articular and tendinous synovial membrane may appear early or late in the disease. Sometimes they are deferred for several weeks or even months after the resolution period. The commonest are those of the sheaths of the great sesamoid, and of the carpus or tarsus. Their development was long considered due to retention in the body of injurious products resulting from reabsorption of pulmonary exudates, but like other complications of pneumonia they are produced by infectious organisms or their toxins.

The anatomical changes in contagious pneumonia are seldom limited to the lung and pleura, but extend to the intestine, liver, kidneys, heart, and sometimes to the serous membrane, nerve centres, or to other organs.

The lungs are almost always gravely affected,—sometimes, however, only over a very limited area. In the patient which died from brain complication you saw that the hepatised portion of lung was hardly as large as two fingers, and occupied the anterior part of the right lobe. Friedberger and Fröhner believe that the organism which usually produces pneumonia may affect a patient without in any way damaging the lung, but this is certainly very exceptional.

In general both lobes are partially invaded. Hepatisation usually occurs in the antero-inferior portion, extending upwards to a varying and unequal height in either lung. Not infrequently the middle (vertical) section of the lobe shows the greatest change, hepatisation extending higher there than in the anterior or posterior parts; sometimes the lesion is limited to the neighbourhood of the large bronchi, the superficial layers escaping. The hepatised parts are distinguished from the rest of the lobe by their deep blackish coloration, and by their much greater density and firmness, even when the healthy parts of the organ are more or less hyperæmic. Sometimes they form a single uniform mass, sometimes they show prominences and depressions somewhat resembling the condition seen in canine distemper. The bronchial glands are always enlarged and infiltrated to some extent.

The appearance of sections through hepatised parts depends on the duration of the condition, and on whether the pneumonia is lobular or lobar.

In recent cases of lobar pneumonia the areas of hepatisation are blackish in colour, rounded or irregular in outline, and separated by

tracts of less inflamed, less hyperæmic and still permeable parenchyma. Sections through these hepatised areas present a dry appearance, though elsewhere a considerable quantity of frothy or sanguinolent serosity escapes from the mouths of the bronchioles and vessels. Where hepatisation is still more advanced the section appears dotted with yellow, grey, or greenish points, and presents a marbled appearance resulting from the blending of these colours, which indicate pulmonary gangrene. Little necrotic areas undergoing delimitation, or already separated from the adjacent tissues, and bathed in greyish or blood-stained pus, may be seen. The bronchioles, and sometimes the bronchi themselves, are inflamed.

In the lobar form the lesions extend to the greater portion of one or both lobes. The non-hepatised tissue is more or less hyperæmic and firm, but not friable, becomes red on contact with air, and gives exit to an abundance of blood-stained serosity; the inflamed portion is firm, smooth, or slightly granular on the surface, and varies in colour. In the neighbourhood of the congested parts, that is to say in the last affected layer, sections are deep red with greyish points and lines; around the bronchi, towards the inferior margin and anterior extremity of the lung where the inflammation has longest existed, sections are less dark in colour; they exhibit an entire scale of colours, varying between pale grey and brownish yellow; little grey or yellow spots are seen scattered over a brownish ground, indicating necrotic fragments, some still in continuity with neighbouring tissue, some in process of delimitation and already infiltrated with pus. Whether or not suppuration exist, these necrotic spots always exhale a fœtid odour, which is absent from areas of simple hepatisation. Finally, cavernous spaces of all sizes between that of a small nut and of a man's fist may be seen. Destruction of pulmonary tissue is sometimes very extensive. At the *post-mortem* of a horse which died on the tenth day I found a large cavernous space filled with sanious material in the anterior portion of the right lobe. The pleura was thickened, much injected, and outwardly adherent to the thoracic wall from the second to the seventh rib; inwardly to the anterior mediastinum. The organs within this mediastinum were glued together by abundant exudate. Furthermore, in other portions of the lungs—particularly in the lower parts—similar cavernous spaces, multiple abscesses containing creamy pus, and necrotic areas were found. These lesions all contained many varying species of microbes. Bacteriological examination showed the presence among others of strepto- and staphylo-cocci.

The specimen obtained from our last case of pneumonia exhibited lesions indicating various stages of contagious lobar pneumonia. With

the exception of a strip as thick as a man's arm occupying the upper border, the entire left lobe was invaded and of a blackish tint. Vertical sections through the lung exhibited varying coloration. In the lower third, where the parenchyma was becoming or had in places become necrotic, the colour was greyish yellow marbled with darker lines and spots; in the middle third the tissue was firmer, blackish in colour, and permeated with little grey patches indicating gangrenous tissue; in the superior third, again, where hepatisation was recent, the appearance of the pulmonary tissue recalled that of peripneumonia (contagious pleuro-pneumonia) of the ox, exhibiting greyish tracts of irregular thickness, surrounding pulmonary areas of a pale brown, deep red, or even blackish tint.

Microscopic examination of the pulmonary parenchyma reveals more complex lesions than in simple pneumonia. We note first of all marked changes in the intra-lobular spaces, more intense hyperæmia, more abundant diapedesis of leucocytes, which have accumulated in the alveoli and around their walls; finally, considerable hæmorrhages at many of the points examined—hæmorrhages which result in entire groups of lobules being surrounded with red blood-corpuscles, and which by extending in all directions through the intra-lobular spaces produce a kind of dissecting effect.

The pleura, which is always attacked secondarily, appears affected with acute diffuse pseudo-membranous, exudative, or purulent inflammation. Two patients with this complication died. One showed lesions of exudative pleurisy, the other of empyema. At the *post-mortem* of the first we found in the pleural cavity about seventeen quarts of a yellowish-grey liquid holding in suspension fine fibrinous flocculi. In its lower parts, but especially over its visceral layer, the pleura was covered with a layer of fibrin, on removing which the serous membrane appeared dull, infiltrated, injected, and closely dotted over with fine granulations. In the other the exudate was reddish, unmistakably purulent, and rich in staphylococci. Sown on gelatine it produced white and yellow cultures, liquefying the medium.

Other changes are inconstant, and result from diffusion by the blood-stream of infectious organisms or their toxins. These changes can be found in most of the viscera and tissues. I shall only refer to the principal.

The heart is often affected. In certain cases the myocardium shows granular degeneration, is more or less swollen and softened, ecchymosed in places, its surface marked with greyish or yellowish patches, which also appear on the surface of sections; on microscopic

examination the striation of the fibres is ill-defined, their contour is irregular, and their substance infiltrated with fine granulations. If the endocardium is inflamed the valves are injected and infiltrated; sometimes they show a crop of little yellowish fibrinous deposits, especially near the free border. These changes almost always affect the left heart. Sometimes the pericardium contains a little greyish liquid, is dull, covered with a thin pseudo-membranous layer, or with fine vascular arborescent growths.

The liver is large, yellowish, friable, and permeated with little hæmorrhagic centres. The hepatic cells show fatty degeneration. The spleen is swollen or bosselated, its tissue congested and ecchymosed. The kidneys display signs of diffuse nephritis. On section (which reveals numbers of fine ecchymoses) the cortical layer is markedly hyperæmic, and apparently more extensive than normal; the medullary layer is reddish in tint. The microscope shows bacterial emboli and degenerative changes in the epithelium. The intestinal mucous membrane is sometimes hardly affected, sometimes greatly congested, infiltrated, and at certain points ecchymosed; at others its epithelium has undergone desquamation; the lymph follicles are hypertrophied and may be necrotic. The changes in the nervous centres usually consist in more or less intense hyperæmia of the meninges and of the nervous substance. In some cases the meninges contain a sanguinolent exudate, and occasionally fine ecchymoses are found disseminated through the brain and cerebellum, giving the nerve substance a "sandy" appearance. I have seen this condition in several animals; it has been noted by various authors; the first two instances were described by Laporte. In the patient of which I was just speaking we found two hæmorrhagic centres in the medulla, in addition to lesions of the brain proper.

Certain muscular groups may become acutely inflamed, the microscope revealing changes in structure similar to those of the myocardium. The synovial membranes of tendons and joints sometimes show signs of synovitis or of simple arthritis.

The blood, which carries the agents producing all these lesions, is itself more or less changed in character. Its coagulability seems scarcely diminished, but many of the red blood-corpuscles appear shrunken and in process of destruction, the number of leucocytes is increased, more than one species of microbes may be present, and the serum shows toxic qualities.

When infectious pneumonia develops regularly and terminates in recovery, the entire process may be complete within a fortnight. As a

rule patients become convalescent between the tenth and fifteenth days, and resume work a week or two later.

Instead of terminating in resolution, pneumonia may assume the chronic form. Sometimes a few areas of necrotic parenchyma become surrounded by an indurated zone, and produce centres communicating with the bronchi, into which they pour infectious material, facilitating the spread of contagion by animals to all appearance cured. In general, however, such animals show capricious appetite, cough, do not attain hard condition, and soon become exhausted by work—symptoms usually referred to broken wind. Such chronic lesions when limited in area may long persist without producing appreciable disturbance, though at last bringing about acute fatal pulmonary or pleural complications.

When the disease has already affected a certain number of animals, diagnosis offers no difficulty. Among the initial symptoms two are particularly important and significant, viz. the rapid onset of fever and the marked acceleration of breathing. A certain method of recognising the onset of disease is to note the night and morning temperatures of animals exposed to infection. The first cases may be mistaken for the abdominal form of influenza, but the regularity with which the principal symptoms appear in almost all patients, and the constancy of the pulmonary affection (whose symptoms dominate all the others), soon remove any uncertainty. I have drawn attention to the difficulty in differentiating between infectious and simple pneumonia. I do not share the opinion of authors who suggest that these two forms are at first clearly distinguishable one from the other. Apart from the history —which of itself is a useful guide in the absence of well-marked clinical symptoms—the contagious character of the one form is soon shown by the number of cases which occur. Diagnosis is confirmed by the course of the disease, and by its contagious or sporadic character, as the case may be.

At the present time the differential diagnosis of these two varieties of pneumonia cannot be finally established either by bacteriological examination or by cultivation methods.

The prognosis of contagious pneumonia is grave. The mortality varies widely according to the time of year, character of the outbreak, and surroundings of the affected animals, but not infrequently attains to 20 per cent. You have seen that numbers of secondary affections occur, rendering the outlook graver. Loss of appetite, prolonged intense fever (41° C.—105·8° F.), and continual lying down (decubitus) are all grave symptoms. Epidemics of pneumonia are not of equal

malignancy throughout. The greater number of deaths occur during the first half of the period, probably because young or very susceptible animals are first affected. Complex morbid conditions formed by association of contagious pneumonia with strangles or influenza are particularly grave.

Many different methods of treatment have been suggested. The most popular comprise counter-irritation and administration of febrifuges, antiseptics, and stimulants. As the general lines follow closely on those laid down when speaking of sporadic pneumonia I shall only indicate the modifications peculiar to the contagious form.

Free application of mustard to the thorax, abdomen, and upper parts of the limbs is always advantageous. Bleeding is most useful where depression is marked and dyspnœa menacing. Subcutaneous injections of chemical solutions and internal administration of bicarbonate of soda restore the alkalinity of the blood and hasten elimination of toxins. Fever is diminished by administration of sulphate of quinine,* antipyrin, antifebrin, or cold enemata.

Among antiseptics, creolin, carbolic acid, naphthol, and salicylate of soda are used. If refused in the drinking-water these drugs may be administered *per rectum*. To favour disinfection of the intestine salicylate of soda or benzoate or subnitrate of bismuth, in doses of $1\frac{1}{4}$ to $2\frac{1}{2}$ drachms, or 3 to 15 grains of calomel may be administered daily during the acute stage. Intra-tracheal injections of antiseptics have given encouraging results.

Alcohol is generally well taken, and its action at least compares favourably with that of most of the other substances recommended. In common with acetate of ammonia it is specially indicated when the strength shows signs of failing. Brandy in doses of 4 to 10 ounces may be given in drinking-water or electuary. Cardiac failure is combated by digitalis and by subcutaneous injections of caffeine or ether. Purgatives may be cautiously administered to relieve constipation.

The strength is sustained by liquid nourishment, especially milk, and if necessary by nourishing enemata. In this disease good hygiene is of primary importance. The animals must be carefully fed, and

* M. Leblanc recently drew attention to the value of quinine salts in the treatment of contagious pneumonia and the abdominal form of influenza: "At the commencement, when the temperature suddenly rises to 40° or 41° C. (104° to 105·8° F.), and other symptoms have not yet attained the gravity seen during the following days, administration of minimum doses of one and a quarter drachms of quinine sulphate night and morning rapidly produces in most cases notable diminution in temperature and in the later symptoms. Instead of the disease continuing for weeks convalescence begins on the seventh or eighth day, and never lasts beyond a fortnight."

encouraged to take food and drink at short intervals,—every two hours, or every hour during the day and night. If everything is refused, gruel, milk, or beef tea can be administered by the rectum. Intelligent nursing is of the greatest value. It is also very important to keep careful watch on healthy animals so as to detect the onset of disease at the earliest possible moment.

Volatile antiseptics, like oil of turpentine and carbolic acid solution, should be sprayed or scattered about the floor and over the walls of the stable.

During the last few years treatment has been enriched by two special methods of medication, hydrotherapy and serotherapy.

Hydrotherapy, already repeatedly tested during the present century, consists essentially in the use of the cold pack, that is the application to the chest of compresses moistened with cold water. To produce the most intense effects Woronzow used ice. In 1890 he published the results obtained in 250 cases of pneumonia. Specially arranged packs containing powdered ice were applied to the thorax, and renewed several times per day during the acute stage of the disease, the patients receiving in addition daily doses of 1½ to 3 ounces of sulphate of soda. Of 250 animals thus treated only 10 died, the mortality, therefore, being 4 per cent.—a proportion certainly below the average mortality of contagious pneumonia treated by ordinary methods.*

The seropathic treatment consists in injecting under the skin during the febrile and hepatisation periods serum obtained from animals which have recovered from pneumonia. The blood is collected aseptically in sterilised vessels by the usual method. Next day, or even two days later, the serum is distributed in sterilised bottles, containing 12½ to 25 fluid drachms. In use it is injected with aseptic precautions into the subcutaneous connective tissue of the neck. Each day five to ten injections of 5 fluid drachms each are made alternately on either surface of the neck, or into the chest region over the extensor muscles of the forearm. The liquid is rapidly absorbed without producing abscesses or induration.

Though Hell, Wittich, and some other veterinary surgeons have only obtained negative or doubtful results with this serum, Töpper, Zschokke, Jansen, and Jacquot credit it with immunising and curative properties. Granting that a previous attack of pneumonia really confers immunity (full or modified), the blood should contain antitoxic substances during convalescence. But to obtain any benefit from the

* During an outbreak of contagious pneumonia which attacked the horses of the Bon-Marché at Paris M. Brun obtained very good results by applying powdered ice to the thorax by means of india-rubber bags.

serum at least 25 to 60 fluid drachms should be injected daily during the periods of onset and hepatisation.

Complications must at once receive proper attention. If signs of suppuration or pulmonary gangrene appear antiseptics are indicated. Creolin or carbolic enemata and hypodermic or intra-venous injections of carbolic or iodine solutions should be given. I need not repeat what I have already said on this subject in speaking of complications of sporadic pneumonia.

The transmissibility of the disease by the various methods of contagion necessitates patients being isolated in a stable entirely apart from that occupied by healthy animals, while both localities should be thoroughly cleansed and disinfected, and a separate attendant provided for the diseased.

When contagious pneumonia appears in large stables, the affected animals should at once be placed as far as possible from the healthy. Even if immediately removed from the common stable to a neighbouring infirmary, isolation may be insufficient and illusory so far as checking the spread of disease. The patients should, if possible, be sent to a distant stable or to the country, for it seems clearly established that change of surroundings almost always has a favourable influence, provided the animals can be removed at the outset and without fatigue.

XXVIII.—CHRONIC PLEURISY IN THE HORSE.

LAST week a six-year-old horse with chronic pleurisy was received into hospital, where, however, it only remained a short time. It was sent because during work its breathing soon became distressed, a slight roaring sound being produced. The animal had just been bought. The purchaser noticed an abnormal respiratory sound, but referred the accelerated and oppressed breathing to broken wind.

The student who brought this case before me had not recognised the condition from which it was suffering from the usual rapid preliminary examination. You saw how I arrived at the diagnosis. The animal appeared bright and in good health, but breathed rapidly, with exaggerated movements of the flank and chest; there was complete dulness over more than one third of the lower part of the chest, and loss of the vesicular murmur over the whole of this region on either side; moreover towards the centre line of the chest a tubal sound could be detected. These symptoms sufficiently indicated that the horse was suffering from chronic pleurisy or hydrothorax. Of these two expressions, still used by many as synonymous, the first conveys the idea of a local disease, of inflammation of the serous membrane with pleural exudate; the second (hydrothorax) suggests simply dropsy of the chest, a non-inflammatory collection of fluid in the pleural sac produced by mechanical or constitutional causes, by tumours, by some disease of the lung, heart, or kidney, or by cachectic conditions. Now our patient shows no disease of this character. Its general condition is good, and, I repeat, at first sight appears perfectly compatible with health. We are, therefore, not dealing with hydrothorax, but with chronic pleurisy. The existence of roaring tends to confirm the inflammatory origin of the condition. It is, in fact, extremely probable that the pleurisy and roaring depend on one and the same cause, viz. a previous attack of pneumonia.

The principal symptoms noted on examining this animal were recorded as follows:—"When placed in a box the patient appears

rather dull and drowsy. It remains standing with the head lowered and the nostrils dilated. The conjunctiva is pale and slightly infiltrated. The submaxillary artery is tense, and rolls under the finger; the pulse is small, fifty per minute. The cough is infrequent, slight and dry. Percussion is painful; the animal threatens to kick, and if its head is firmly held, constantly backs away from the pleximeter hammer. The area of dulness occupies almost half the lower part of the chest on both sides, and is limited by a horizontal line. On auscultation the whole of this zone is absolutely silent, except over about eight inches of its upper part, where a tubal murmur can be heard. The rhythm of the heart is normal; the two sounds are, however, dull. There is no serous infiltration under the chest, or œdema of the limbs. The temperature is 39° C. (102·2° F.). The urine deposits a large quantity of sediment, but contains neither albumen nor sugar."

During the two days following this examination the condition remained stationary. On the door of the box being cautiously opened the horse took no notice, but suddenly lifted its head at the least sound. When excited its appearance became more animated, but in a few moments it again appeared somnolent, or began to gather a few fragments of hay from amongst its litter. The temperature varied between 38·8° and 39·3° C. (101·8° and 102·7° F.).

The owner would not undertake the cost of treatment. He consented to our tapping the chest to remove a portion of the liquid which was interfering with the lung's action, knowing, however, that improvement would only be temporary. We withdrew eight and a half quarts of liquid. On the following day the patient was removed.

Some years ago I several times saw an interesting case of chronic pleurisy in a horse which had previously suffered from acute pleuro-pneumonia. In spite of the use of mercurials internally and externally the disease had assumed a chronic form. The animal was bought by a small horse dealer. It was then rather thin and soon became "blown" at exercise, but when at rest showed no well-marked morbid symptom if we except a dribbling of saliva from the mouth, consequent on the action of the mercury. This, however, the new owner explained to us, was in a way an advantage in selling the animal, as he referred the trifling symptoms shown to injuries about the mouth. A buyer was soon found. The horse was five years old, and the price moderate. But from the first day this buyer noted that the animal showed little appetite, and soon had difficulty in breathing during work. He had its teeth rasped, but finding the condition did not improve he brought it here for inspection. We dispelled his doubts as to the animal's condi-

tion. It returned to the seller. The latter (as happens almost always under similar circumstances) after making a number of difficulties consented to an exchange, needless to say on terms advantageous to himself. He succeeded in successively selling this animal to two other persons, who brought it here at intervals of a few weeks. We immediately recognised it by its black colour, and by the discharge of saliva which the dealer took means to sustain.

The history of these two horses shows you how little marked may be the symptoms of chronic pleurisy even when exudate is considerable. In many cases the animal appears perfectly well. All that can be detected in the external appearance is a little dulness, trifling loss of condition, and that peculiar state of the coat expressed by the word "staring." Appetite is usually fair; at times capricious and irregular, hay especially being partly left. The conjunctiva is pale or clay-coloured and infiltrated; the pulse somewhat rapid, of normal force or rather weak. Fever is always trifling, and the temperature curve only shows slight oscillations. Some patients have an occasional dry cough, louder than that of broken wind.

However slight the exudate, work soon produces dyspnœa; the animal becomes distressed, and finally stops for want of breath. These symptoms grow more marked as the area of active lung is encroached on by fluid exudate. Even when the pleura contains a considerable quantity of liquid some animals, when at rest, show little change in the character of the respiration; but in the majority—especially when exudate is abundant—the breathing is rapid and the "discordance" striking. You have all noticed that in normal respiration the sides of the chest and the flank move simultaneously and in the same direction during both inspiration and expiration. The flank flattens slightly at the same moment as the ribs are depressed, and bulges when they rise. "Discordance" is said to exist when during expiration the flank bulges while the ribs fall, and *vice versâ*. This discordance is a common symptom in various affections of the lungs and pleura, and in some other very rare diseases,—in diaphragmatic hernia, for example. If very marked it almost always indicates pleuritic exudate.

Percussion of the thorax reveals the existence of a double-sided zone of dulness which extends upwards to a greater or less distance, reaching to—or even beyond—the centre line of the chest. Above this zone the sounds are normal or tympanitic.

On auscultation the dull area is usually silent, above this a tubal sound is heard, and above this again the vesicular murmur. In exceptional cases where pleuritic adhesions exist a tubal murmur and

liquid sound may be heard—a kind of splashing produced by the exudate striking against bands of fibrous tissue below the level of its surface (if the expression be permissible).

The phenomena discovered on auscultation and percussion almost always exist on both sides of the chest and to a similar height. Certain cases, however, prove that exudate may be confined to one pleural sac, and the fact that the physical signs are unilateral does not at once exclude the diagnosis of pleurisy.

As a rule the costal walls are not abnormally sensitive except as a result of repeated stimulating applications. In some patients the lower part of the chest shows trifling œdematous swelling, and infiltration of the subcutaneous tissues may be detected by pressing with the tips of the fingers over the intercostal spaces.

Chronic pleurisy usually persists and becomes aggravated, slowly if the patients are carefully nursed and fed, but rapidly if they are worked and exposed to chills or inclement weather. The dyspnœa increases in proportion to the increase of exudate. The cough, wasting, and loss of strength become accentuated, the heart-sounds and pulse weaker and weaker. When the increase of exudate is very slow signs of general debility appear; the limbs swell, and the animals finally die of exhaustion. In the contrary case respiration soon becomes very painful, the animals remain standing with the limbs spread widely apart, struggle for breath, and on falling die of asphyxia.

Chronic pleurisy in the horse may, however, terminate in resolution. In rare cases the exudate ceases to increase, and after an interval gradually becomes re-absorbed. The general disturbance and special symptoms recede, appetite and strength return, respiration becomes less frequent and difficult, the area of dulness diminishes, the bronchial sounds disappear, and the vesicular murmur returns in the lower parts of the chest. Recovery is almost always incomplete, the respiratory movements generally remaining irregular, and a little dry cough resembling that of emphysema persisting.

On *post-mortem* examination of horses which die of chronic pleurisy the pleuræ contain a more or less abundant, clear, transparent, or slightly yellowish serosity, with or without fibrous flocculi; sometimes the exudate is purulent. The pleura is irregularly thickened, whitish, rough with villous processes, and partially covered with masses of fibrous deposit of all shapes and sizes; sometimes the pulmonary and costal or diaphragmatic pleuræ are adherent. If death

results in consequence of a fresh acute attack, these organised new membranes are covered with fibrinous or purulent exudate.

Chronic pleurisy being sometimes curable, what are the best means of treatment?

Internal medication is of little value. In the acute form bicarbonate and salicylate of soda, given in the drinking-water, and pilocarpine or arecoline administered subcutaneously appear useful, but are of little value in the chronic stage.

Laxatives and diuretics internally, together with rubefacients and blisters applied to the walls of the chest, constitute the usual treatment.

Repeated mild blistering of both sides of the chest, as high as the line of exudate, is sometimes successful. When recent pleurisy is in process of becoming chronic these most probably act by favouring vascularisation of the new membrane, and thus multiplying the channels through which absorption may occur. They are less effectual in old-standing distinctly chronic pleurisy. In such cases they should be associated with tapping the chest. Many cases are said to have been permanently cured by this treatment.

In addition to their questionable efficacy in chronic pleurisy blisters entail serious disadvantages if tapping has afterwards to be performed. The purulent dermatitis they produce renders it difficult to disinfect the seat of operation, and exposes the patient to danger of pleural infection. When the methods are combined the chest should first be punctured, and if a repetition of the operation become necessary the parts should be very carefully disinfected.

Tapping the chest is unquestionably the most rational and efficacious method of treating chronic pleurisy.

As the two pleural sacs almost always communicate, puncture of one side results in withdrawal of most of the contained liquid. If the orifices in the posterior mediastinum are plugged (shown by the persistence of exudate in the side removed from that of operation), both sides must be tapped.

In chronic as in acute pleurisy operation should be resorted to as soon as breathing becomes distressed and exudate abundant. Very generally the two conditions march together, dyspnœa being proportional to the quantity of liquid in the thorax. Nevertheless exceptions occur, pulmonary or cardiac disturbance sometimes rendering breathing difficult even when the exudate is scanty. Conversely, cases occur in which dyspnœa is trifling, while the pleuritic exudate is considerable. You will see horses with double-sided abundant exudates,

which only appear to be suffering from broken wind. Although in practice these cases are seldom surgically treated, operation is justifiable and necessary, as large pleural exudates may cause sudden death by asphyxia.

A colleague recently described to me a case of pleurisy following pneumonia, in which the horse died in this way during the fifth week. Having recognised how abundant was the exudate, he had thought of tapping the chest; but as the breathing did not appear alarming he postponed operation until next day. The patient died during the night.

We may therefore lay down as a general rule that thoracentesis is indicated whenever exudate is abundant. When it approaches the middle line of the chest any temporising is dangerous, and operation should at once be performed.

The operation dates from the earliest historical period. In the case of man it was performed by the Cnidians and the doctors of Cos. At that time it was usual to incise the thoracic wall through an intercostal space, or to trephine a rib. The "hippiatres," predecessors of the first veterinary practitioners, applied this treatment to the horse, Lafosse indeed going so far as to declare that pleurisy could only be cured by operation. Following them, some veterinary surgeons, during the last and commencement of the present centuries, opened the pleura by passing the point of a knife through an intercostal space. Thus performed, operation produced immediate relief, but was too often followed by infection of the pleura and passage of air into the thorax, which almost always proved fatal.

The first improvement consisted in substituting a trocar for the bistoury. Even Lafosse, in his *Dictionnaire d'Hippiatrique*, gives a short description of thoracentesis by means of the trocar. He recommends passing the instrument between the lower portions of the seventh and eighth ribs, opposite the costal cartilages, drawing off about half the contained fluid, and afterwards injecting slightly stimulating liquids (liquides légèrement vulnéraires). He adds that the treatment is "almost always certain" when the condition is of inflammatory origin.

For a long time the trocars used were too large; complications were very frequent and success rare. The operation had almost been abandoned when it was rehabilitated by St. Cyr, who showed the good results obtained by using a fine trocar. To prevent air entering the chest Reybard suggested providing the cannula with a short tube of goldbeater's skin, which allowed liquid to escape but prevented air entering, the thin walls collapsing and closing the orifice when pres-

sure became negative. Despite these successive modifications the operation always entailed risk until the introduction of antisepsis. Though it produced momentary improvement it was often followed by aggravation of the disease, the pleuritic exudate becoming purulent, and patients dying of empyema.

Thanks to antisepsis, and possibly in some degree to the invention of M. Dieulafoy's aspirator, thoracentesis has become a comparatively innocent operation. Even without an aspirator the operation can be perfectly well performed, provided a slender trocar be used and antisepsis observed. The seat of operation having been shaved and disinfected, the trocar, covered by its cannula, is introduced at the lower part of the seventh or eighth intercostal space close to the spur vein; the trocar is next withdrawn, allowing the liquid to escape, after which the cannula is removed and the little cutaneous wound covered with a layer of iodoform or sublimate collodion. This constitutes the entire operation.

With the aspirator the wound in the thoracic wall and the danger of infecting the serous membrane are reduced to a minimum. The taps at the base of the aspirator are first closed, and the air exhausted from the barrel. A rubber tube, provided at its free end with a fine hollow needle previously sterilised by immersion in a disinfectant, or by passage through the flame, is then slipped over one of the aspirator nozzles. The skin having been prepared the needle is passed into the intercostal space at the point chosen, and the lower tap of the aspirator opened. The needle is then pushed forward until it enters the thoracic cavity. Under the influence of the vacuum in the aspirator, liquid rushes rapidly into the barrel. Exudate may thus be removed in a very short time, but it is better to proceed somewhat slowly. When the liquid contains fibrous clots the needle becomes blocked from time to time, but a little pressure on the piston expels the fragments, and the flow recommences.

It is not necessary to remove all the exuded liquid, as has been recommended by some. Four to twelve quarts are usually sufficient, depending on the size of the animal and the amount of exudate. Puncture may afterwards be repeated if necessary. Unless very abundant, the remainder of the exudate becomes absorbed spontaneously.

Resorption is favoured by administering alkalies, diuretics, or certain drugs which, like arecoline or pilocarpine, stimulate secretion. Last year you saw in hospital a horse with pleurisy following pneumonia, which was only tapped once, one month after the pleuritic affection had appeared, and was afterwards treated by alkalies and hypodermic

injections of pilocarpine, the chest not being blistered. The animal recovered.

When the operation is properly performed the general health always improves, breathing becoming easier and less frequent. The only accident really to be feared when the operation has been slowly performed is purulent change in the exudate, but this is avoided by antiseptic precautions. In another patient affected with pleurisy communicated from the lung, you noted on the third occasion of tapping that the liquid was clearly purulent, although on the second occasion it had only been slightly turbid, and on the first had appeared purely serous; but cultivations from the liquid first obtained showed pyogenic germs; the exudate was then already purulent, a characteristic which had simply become more accentuated. In this case tapping could not be held responsible for the change in the exudate.

Performed with proper precautions the operation is innocent. It is always useful, and has been found of the greatest service in treating obstinate cases of pleurisy.

XXIX.—THE ABDOMINAL FORM OF INFLUENZA* IN THE HORSE.

During a comparatively short period we have received into hospital eight horses suffering from an infectious disease which is almost always present in the Seine and neighbouring departments, and at times assumes the form of a true enzooty. I refer to the affection formerly known as gastro-enteritis, and now termed "typhoid disease," "typhoid fever," or influenza. It is a morbid condition special to the horse, and has nothing in common with the human disease known by the same titles.

On the 21st March last, five horses belonging to M. A—, carrier, Boulevard Soult, Paris, were suddenly taken ill. They were greatly depressed, and would not touch their food. My colleague, M. Moret, was called in next day, and finding them undoubtedly suffering from influenza had them sent to the School. On the 30th of the same month three further cases from this stable were sent here, and during the interval several more had been affected.

I will read you an extract from the notes made about these animals.

Case 1.—Four-year-old entire horse. Entered the 22nd March.

Symptoms.—Extreme depression and dulness, eyelids swollen and closed, eyes painful on exposure to light, conjunctiva cyanotic, mouth hot and dry, tongue slimy, a narrow violet-coloured stripe along the gums, active thirst, heart-beats rapid and violent; pulse 92, small and perceptible with difficulty; respirations 21. Nothing abnormal on percussing the thorax. On auscultation, strong vesicular murmur over the entire lung. Temperature 41·3° C. (106·3° F.).

* (*Maladie typhoïde du cheval.*) To distinguish this form of influenza, of which I saw a large number of cases in France, and have recently seen others in England, from "pink-eye," the form of influenza best known to English practitioners, I have ventured to adopt the above title, thus avoiding a long and cumbrous periphrasis.—Jno. A. W. D.

Treatment.—Application of mustard under the chest and abdomen, and over upper part of the limbs. Alcohol, digitalis, and salicylate of soda in draught. Carbolic enemas of a strength of ·5 to 1 per cent.

Next day the symptoms were little changed; the temperature, however, was only 40·6° C. (105° F.); the pulse still frequent and feeble; respirations 18 per minute. The animal took part of its food. After the 25th the condition markedly improved. The temperature did not rise beyond 39·6° C. (103·2° F.); the pulse was better and less frequent than on the previous day; the respirations 16. On the following days the symptoms gradually diminished. Recovery was complete on the 29th March.

Case 2.—Four-year-old entire horse, entered hospital 22nd March. The animal was very depressed and sleepy; the head was held low; the gait was rolling; the animal took no notice of its surroundings; the conjunctiva was reddish violet; the eyelids were swollen, hot, and very sensitive; the gums showed a broad bluish band; the buccal mucous membrane was dry; thirst was intense; appetite completely lost; the heart beat tumultuously; the pulse was thready, 82 per minute; respirations 20; temperature 40·8° C. (105·4° F.); nothing abnormal could be detected on auscultation or percussion of the thorax.

In the evening the temperature was 40·5° C. (104·9° F.); pulse 72; respirations 18. The fæces were soft. Treatment similar to that of the first case. Next day the general condition was stationary. Morning temperature 40·5° C. (104·9° F.); evening 40·8° C. (105·4° F.).

On the following days the symptoms diminished and the temperature fell. On the 31st March the animal had entirely recovered.

Case 3.—Six-year-old entire horse, entered 22nd March. This animal appeared externally like the others. The eyelids were swollen and painful, tears running from the eyes; the conjunctiva was injected, infiltrated, and of a very marked mahogany colour. The mouth was hot; the mucous membrane of the gums violet in colour; the fæces were dry. The temperature was 40·6° C. (105° F.); the circulation very rapid; the pulse 90 and difficult to detect; respirations 20 per minute.

Treatment as before with the addition of eight ounces of sulphate of soda.

The first three days the condition remained nearly stationary. Temperature 40·5° C. (104·9° F.); pulse 88; respirations 18. Subsequent course of the disease similar to that in the above patients.

CASE 4.—Seven-year-old entire horse, entered 22nd March. The animal was dull and stiff, and remained standing in a corner of its box. The eyes were weeping; the eyelids swollen, infiltrated, and painful; the conjunctiva of a reddish mahogany colour; the cornea had lost its transparency, and was encircled by a yellowish aureola; the anterior chamber contained a deposit resembling hypopyon. These symptoms were particularly marked in the left eye. The mouth was hot and dry, the tongue slimy, the gums marginated by a bluish line; appetite slight; thirst severe; temperature 40·6° C. (105° F.); pulse 78; respirations 22. Treatment the same as for the two previous cases.

On the following day trifling improvement was noted. The horse was less depressed, and ate the greater part of its food. Temperature 39·8° C. (103·6° F.), pulse 80, respirations 20. The fæces were small, dry, and shiny. Eight ounces of sulphate of soda were given in the drinking-water.

Marked improvement occurred on the following days. Recovery was complete on the seventh day, except that the circle around the cornea had not quite disappeared.

CASE 5.—Six-year-old entire horse, entered 22nd March. The following symptoms were noted:—The attitude suggested great fatigue, the face appeared sleepy, the eyes were half closed, discharging tears, and very sensitive on palpation; the eyelids were swollen, the conjunctivæ violet-red, the mouth hot and pasty. The patient took the greater part of its food, but would not touch the chaff; thirst was severe. The heart-beats were regular, the pulse feeble, temperature 39·7° C. (103·4° F.), pulse 56, respirations 20. Treatment expectant.

Next day the general condition was stationary. On the 24th improvement occurred and rapidly increased. On the 28th the animal was removed, cured.

CASE 6.—Eight-year-old entire horse, brought to the College 30th March. Had been ill since the previous night. The animal was depressed and somnolent, and carried the head low. The eyelids were swollen, the eyes weeping, the conjunctivæ reddish violet, the cornea was surrounded by a greyish œdematous circle, the mouth was dry, the tongue coated, the line along the gums well marked. The bowels were constipated, the fæces dry and covered with a layer of mucus. The temperature was 40·1° C. (104·1° F.), respirations 19, pulse 75, very small. Treatment similar to that of Case 3. Recovery in eight days.

CASE 7.—Five-year-old entire horse, recognised as ill on the 29th March; brought to the College on the afternoon of the 30th.

The animal was greatly depressed, and walked with a rolling motion, the muscular weakness being such that the limbs almost collapsed at each step. The ears and membranes were cold.

Placed in a box the animal stood constantly in one position, the head depressed, the eyelids almost completely closed, and tears running abundantly over the face; the conjunctiva was of a very marked violet-red tint; the gums were bordered by a stripe of the same colour, more especially marked in the lower jaw; the temperature was 41·3° C. (106·3° F.). The animal occasionally had paroxysms of coughing, the cough being strong and dry. On auscultation the vesicular murmur was absent from the lower part of both pulmonary lobes, being replaced by moist râles. The respiration was 22 per minute, the circulation rapid, the cardiac beats being strong though rhythmic; the pulse was 70, small and thready. Although appearing severely attacked the patient voluntarily took food. The fæces were normal.

Same treatment as for Case 1. Condition stationary for forty-eight hours. On the third day improvement was noted. The normal respiratory murmur had returned at points where it was previously imperceptible. Temperature 40·1° C. (104·1° F.), respirations 14, pulse 55. The improvement gradually continued without incident. On the 5th April the animal recovered its usual appearance, ate all its food, the stiffness had disappeared, the conjunctiva showed a yellowish tint, temperature 38° C. (100·4° F.), respirations 15, pulse 40.

On the 8th April the patient was sent home cured.

CASE 8.—Six-year-old entire horse, entered the School 30th March.

Principal Symptoms.—Very pronounced depression, somnolence and rolling gait; eyelids half closed and swollen; conjunctiva hyperæmic; mouth hot; tongue coated; gums bordered by a narrow violet-coloured stripe. Auscultation and percussion of the thorax revealed nothing abnormal. Temperature 40·2° C. (104·3° F.); respirations 26; pulse 70, difficult to discover in the arteries of the extremities.

Treatment.—Expectant.

The animal took a portion of its food. On the 31st March and 1st April the condition was stationary.

On the 2nd April the animal was less depressed, and the discharge from the eyes had diminished. The temperature was only 39·3° C. (102·7° F.). Recovery was complete on the sixth day.

These are typical cases of benign influenza, rapid in onset and in

development, and unaccompanied by any grave complication. Even in this form the disease appears suddenly, and soon reveals its presence by three clearly marked symptoms—extreme depression, high fever, and deep red or violet tint of the conjunctiva. If you have carefully observed and followed these cases you have noted other morbid phenomena. In all the mouth was hot and dry, its mucous membrane injected, and the gums showed the classical reddish-violet line. The majority showed no intestinal trouble. The fæces were of normal consistence. Three patients were constipated during the earlier period; only one had diarrhœa. In none was palpation of the abdomen painful. The circulation was greatly accelerated, the pulse often numbering 90 per minute, and the force with which the heart beat contrasted markedly with the weakness of the pulse, which was small and thready—in some patients so feeble as to be difficult to count during the first few days. Auscultation of the heart revealed no abnormal sound. The breathing movements were little affected, either in number or rhythm. Auscultation of the lung only showed a trifling exaggeration of the vesicular sound. In one patient, however, during the second and third days the lower portion of both lobes, and especially of the left, was the seat of moist râles and loss of the vesicular murmur—signs which were referred to congestion of the lower portion of the lung. This was the only animal which had any attacks of coughing. The skin of the trunk and upper portions of the limbs was hot. In most of the patients the ears and extremities were cold. In almost all the fever was marked, the temperature rising above 40° C. (104° F.), in several even above 41° C. (105·8° F.).

In two cases the eyes were specially affected. In addition to the epiphora, the violet coloration and infiltration of the conjunctiva, the cornea and deeper portions of the eye showed lesions. In these patients the cornea of both eyes was surrounded by a greyish œdematous circle, and in one of the two the anterior chamber of the eye contained a deposit resembling hypopyon. These troubles disappeared in a few days. The fear of light at first observed only persisted for forty-eight hours.

There was no œdematous swelling of the lower parts of the limbs, and no paralysis of the penis or other organs. The rapid diminution in symptoms, prompt and complete resolution, and short convalescence were particularly remarkable in all cases. The animals were put to work soon after leaving hospital.

Influenza, however, does not always present this benign character, and when it takes a malignant form many patients die of intestinal,

pulmonary, cardiac, or encephalic complications. Since it has permanently taken up its residence here it seems in a general sense to have lost some of its gravity. During 1890 and 1891 it is said to have produced many deaths in Paris and the neighbourhood, but the evidence is not entirely satisfactory as to whether the cause of these losses was influenza pure and simple. In great commercial and industrial centres, where circumstances favour the development and propagation of contagious equine diseases, several infections may simultaneously be active in one stable. Thus influenza sometimes co-exists with strangles, contagious pneumonia, or the pneumo-enteritis caused by bad forage. I have observed cases of the kind. You will therefore see how difficult it sometimes is to solve these questions, and how much more complicated the problems offered by practice really are than you might imagine by perusing text-books on pathology.

At the *post-mortem* examination of animals dead of influenza most of the organs exhibit extensive changes: congestion, ecchymoses, infiltrations, and degenerative changes only revealed by the microscope occur in varied combination, but the principal lesions are confined to the mucous membranes of the digestive and respiratory apparatus. The intestinal mucous membrane is hyperæmic, swollen, ecchymosed, and in places deprived of its epithelium. When incised it appears infiltrated with liquid which escapes from the cut surfaces, and coagulates in thin layers of gelatinous character. The submucous connective tissue is often engorged with greyish or amber-coloured liquid. The mucous membrane of the pyloric end of the stomach and sometimes of the pharynx shows similar changes.

Swelling of Peyer's patches is by no means constant, and I have never observed necrosis or ulceration, lesions characteristic of typhoid fever in man; moreover Eberth's bacillus, the causal microbe of typhoid, is never found either in these patches or at any other point in the intestine. The respiratory mucous membrane is affected to a varying degree. Often there is only reddening and slight swelling of the larynx and bronchi; in some cases pulmonary lesions, such as catarrhal or fibrinous pneumonia, or œdema of the lung, with or without pleural exudate, predominate. Disease of the myocardium and endocardium is rarer than in pneumonia. Even when nervous symptoms occur, change in the brain, spinal cord, or meninges is seldom marked; very often there is only trifling injection of the meninges and slight infiltration of the plexuses, the true nerve substance either of the brain or medulla being rarely ecchymosed or softened. When the disease is complicated with laminitis the podophyllous tissue is more or less congested.

The blood and affected organs may contain various microbes, but none of those at present isolated can be regarded as the specific agent of influenza. That remains to be discovered.*

Diagnosis is easy. The sudden appearance, rapid aggravation of symptoms, extreme depression, and the ocular symptoms constitute the principal indications. Any doubts which might at first exist are soon dissipated by the rapid spread of disease to large numbers of fresh subjects. In less than a fortnight one half or two thirds of the animals in a large stable may be attacked.

The disease can be distinguished from contagious pneumonia and from the pneumo-enteritis said to be produced by bad fodder.

Contagious pneumonia is recognised by the predominance of pulmonary symptoms; the rapidity of breathing from the outset; the slighter depression; the absence of epiphora; the yellowish colour and moderate injection of the conjunctiva, and the slow extension of the epidemic. The embarrassing cases are those where infection is of a mixed character,—influenza and contagious pneumonia, for instance, being both present in one stable.

The existence of pneumo-enteritis is usually announced by somewhat alarming symptoms, but in general the onset is less striking and the contagion less active than in influenza. The conjunctiva is less swollen, and lacks the violet or mahogany colour. If the colour, appearance, and smell of the hay and oats leave nothing to be desired, if they are clean, have been well got and carefully stored—if, in a word, they are of excellent quality, pneumo-enteritis may be placed out of the question. It is always easy to distinguish influenza from sore throat, or bronchitis affecting a number of animals.

The prognosis is usually favourable, but varies according to the character of the prevailing outbreak, the time of year, and the animals' surroundings. When the disease seizes on a locality from which it has long been absent, more animals are likely to succumb than in large towns where it exists, so to speak, permanently. This year we have seen little but benign cases which developed regularly and rapidly. All our cases of simple influenza recovered, but the mortality is sometimes severe, varying between 1 and 15 per cent., the medium being

* M. Lignières isolated and cultivated a microbe which he termed the *cocco-bacillus*, and which he regarded as the specific cause of influenza in the horse. He states that "inoculation of a horse with a culture of this microbe produces most characteristic symptoms of influenza." Suitably attenuated and inoculated into a healthy horse it produces no grave symptom and affords immunity. By vaccinal inoculation in the horse a preventive and curative serum was obtained.

from 3 to 5 per cent. The outbreaks in which losses rose to 25, 50, or 60 per cent. were not due simply to influenza, but were the result of double infection.

An interesting point to consider is whether the virus of influenza has immunising properties, and whether animals which have recovered are protected from fresh attacks. In this respect experience shows that the disease generally affords immunity for a period of twelve to fifteen months. In 1891 a stable of twenty horses was invaded by influenza, and I noted that two animals which had been attacked ten months before resisted.

Cases of more prolonged immunity have been mentioned, some extending to three, five, or six years. These are exceptional, even admitting that the disease has not been erroneously described as influenza.

Treatment consists primarily in good hygiene. In recent outbreaks where the number of cases is still small the patients should be isolated and their stalls disinfected; the stable should be kept well ventilated and very clean; the drains being flushed and the floor and walls moistened with carbolic, creolin, or turpentine solutions. In this way the epidemic may be arrested, but its contagious character is too pronounced for such measures often to succeed; nevertheless they should not be neglected. If the form of disease is severe and many animals are affected, it may be necessary to remove all. In warm weather they can be turned out to grass, living in the open air under a shed; at least they should be removed to a new stable and the infected stable thoroughly disinfected. By observing these precautions in grave outbreaks of influenza many practitioners have succeeded in checking the heavy mortality and the disease itself.

Patients which still drink freely should receive gruel, hay tea, or milk at frequent intervals. Milk is particularly valuable; most animals drink it readily; in grave cases it is alone sufficient to sustain their strength and carry them on beyond the dangerous period. As in pneumonia, patients which refuse everything should be fed by the rectum.

Medical treatment comprises various methods, the principal being bleeding, application of large mustard plasters to the chest and abdomen, and the internal administration of drugs. Those most commonly given are sulphate of soda in doses of 3 to 6 ounces per day, bicarbonate of soda $1\frac{1}{2}$ to 3 ounces, salicylate of soda $2\frac{1}{2}$ to 6 drachms, digitalis $\frac{1}{2}$ to $1\frac{1}{2}$ drachms, and quinine salts $2\frac{1}{2}$ to 5 drachms. The

eyes are treated with lukewarm fomentations and warm collyria containing atropine, creolin, or boric acid. If fever remains high antipyretics and cold enemata (to which 1½ to 3 drachms of carbolic acid per quart may be added) are useful. When influenza is complicated with laminitis, hypodermic injections of arecoline or pilocarpine are valuable; the feet should be surrounded with moist compresses, frequently saturated with cold water.

In the various forms of influenza, moderate doses of alcohol, and especially brandy, may be given either in the drinking-water or in the form of electuary. You have often seen valuable effects thus obtained. The mode in which alcohol acts has long been discussed, but whether it undergoes a series of transformations in the blood, whether it principally affects the nervous system or nutrition, is of little importance. What we do know is that it gives excellent results. In six of our patients treatment consisted in application of mustard plasters and the administration in mashes or gruel of sulphate of soda, bicarbonate of soda, salicylate of soda, and brandy. For several I also ordered ½ to 1½ drachms of powdered digitalis and cold carbolic enemata. All cases recovered very rapidly.

I wish to impress on you that in the benign form of influenza internal medication is only of secondary importance. I left two patients to take care of themselves, without assisting them in any way whatever, only watching them in case it should become needful to intervene. No necessity arose, and both recovered as quickly as those treated.

XXX.—A CASE OF PHARYNGITIS DUE TO STRANGLES.

We have just completed the autopsy of a horse which died of acute sore throat due to strangles, complicated by paralysis of the pharynx. Up to the last day or two we anticipated improvement and recovery; the symptoms never appeared alarming or likely to end in death, and in fact were even less pronounced than usual in such attacks. For that reason alone the case is of special clinical interest. The history of this patient will form the subject of my lecture to-day.

The animal was brought for advice on the 6th September. It was five years old, and had only been four days in the new owner's stable. On that morning, and even on the evening before, it left the greater part of its food, and seemed tired and depressed; the skin was hot, the eye injected; a greyish inodorous discharge mixed with fragments of food ran from both nostrils; saliva accumulated in the mouth, and escaped freely on introducing the hand. The throat was painful on pressure. The right submaxillary gland was slightly enlarged, the left formed a swelling the size of a walnut, and was surrounded by an œdematous zone; the centre showed obscurely fluctuation. A few small papules were noticed at different points, especially on the neck and sides. The patient's age and the fact that it had just been bought at once suggested to us the diagnosis of pharyngitis due to strangles. I opened an abscess under the jaw with the usual precautions, and collected a little pus, which I found to contain streptococci in short chains. Being left for treatment the animal was placed in my portion of the hospital.

My assistant will read you the animal's history from the time when it entered hospital until the day of its death.

"On entering hospital the animal was depressed and took no notice of its surroundings. It scarcely touched food. A greyish discharge mixed with small quantities of food ran from the nostrils, and long strings of saliva occasionally fell from the mouth; the conjunctivæ

were deep red in colour. The pulse was 70 per minute and strong; the respirations 32; the temperature 40·5° C. (104·9° F.). The vesicular murmur was loud over the entire area of both pulmonary lobes. The submaxillary glands were swollen, the left showing fluctuation. A papulo-vesicular eruption was visible on the neck, sides, flanks, and croup.

Treatment.—The abscess was opened and the cavity washed out with a watery solution of iodine. The sides and under surface of the thorax, throat, and limbs were dressed with mustard. Food as usual, hay tea, and milk. Fumigations: 2½ drachms of sulphide of antimony (Kermes' mineral), 5 ounces of brandy, and creolin enemas.

Until the 10th September the temperature remained at 40° C. (104° F.), the pulse varied between 55 and 70, and the respirations between 22 and 30; cough was infrequent. On auscultating the lung mucous râles were heard; the vesicular murmur appeared diminished over the inferior third of both lobes. The animal readily took mashes, etc., and 10 quarts of milk per day. The Kermes' mineral, alcohol, and creolin were continued. A daily dose of 2½ drachms of potassium iodide was added.

From the 11th to the 18th September the symptoms continued, though slight improvement occurred and slowly became more marked. On certain days the temperature fell to 39° C. (102·2° F.), the pulse to 48, and the breathing to 20. The patient occasionally attempted to eat oats and hay; it masticated them, but had great difficulty in swallowing the little boluses of food, so that although it continued to take gruel, hay tea, and milk, wasting occurred. On the 13th a second abscess developed under the jaw behind the previous one, and was opened. Bacteriological examination of the pus revealed the presence of streptococci.

On the 19th the general condition was distinctly better, and the discharge less abundant than on the preceding days. Saliva still ran from the mouth, but when the animal drank less water returned through the nostrils. The submaxillary space still showed inflammatory swelling occupying the posterior half and extending over the laryngeal region. A few oats given by hand were masticated, but not swallowed. On examining the throat nothing could be found to explain this inability to swallow. The parotid region was not swollen or more prominent than normal, and pressure over it only caused dull pain, the animal scarcely attempting to withdraw. Three little abscesses the size of hazel-nuts had developed in the subcutaneous connective tissue of the right shoulder. They were opened. Careful examination of the buccal cavity, especially towards the back and base of the tongue,

showed nothing abnormal. Nothing was discovered on rectal examination. Temperature 38·8° C. (101·8° F.), respirations 18, pulse 40. The urine contained no sugar, though a little bile pigment and traces of albumen were found.

"On the 20th the general condition was stationary. The penis had become relaxed and pendent. As slight signs of iodism had occurred and tears ran over the cheeks the potassium iodide was stopped.

"On the two following days the penis became more markedly paralysed. Emaciation also increased.

"On the 23rd the general condition was less favourable, and salivation more abundant. The patient showed greater depression, hung back from the manger, and touched neither gruel nor milk. At 8 o'clock the temperature was 39·3° C. (102·7° F.), respirations 32, pulse 54. There was no thoracic dulness, and on auscultation of the lungs no abnormal sound. On examining the throat externally nothing fresh could be detected.

"On the three following days the condition slightly improved. The temperature varied between 38·6° and 39° C. (101·4° and 102·2° F.): the breathing was calmer. The patient refused milk, but took a little gruel, hay, and oats.

"On the evening of the 27th the condition became aggravated. The temperature rose more than a degree. The apex-beat of the heart was violent, and could be heard on the right side of the chest. The small quantity of fæces passed was covered with blood-stained mucus. As the animal entirely refused food, six quarts of milk were given *per rectum*. In the evening it drank the liquid portion of its gruel, appeared more depressed than formerly, and lay down on its side. A subcutaneous injection of 15 grains of caffeine was given.

"On the 28th the animal was standing, and seemed rather less depressed than on the previous evening. It ate a few mouthfuls of fresh lucerne. Swallowing appeared easier. Temperature 39° C. (102·2° F.); respirations 30; pulse 45. Two small abscesses which had developed on the left shoulder were opened. Pus mixed with saliva ran from the second submaxillary abscess; a salivary fistula evidently existed on the left side. The same evening the animal readily took six quarts of milk. Temperature 39·2° C. (102·5° F.).

"On the morning of the 29th September the patient drank four quarts of milk, but refused other food. It showed difficulty in breathing; expiration was double. Percussion and auscultation revealed nothing new. The throat and parotid region were insensitive on pressure; the scapular muscles showed slight twitching movements. The animal seemed unsteady on its front legs, and at times sat down

like a dog. On passing the catheter only a small quantity of urine was drawn off. Temperature 38·9° C. (102° F.); respirations 39; pulse 48. At midday temperature 39·3° C. (102·7° F.); respirations 46; pulse 75. Breathing remained difficult, and trembling of the muscles attached to the olecranon was more marked. The horse drank a little gruel and then lay down on its chest. It rose in a few minutes, the face assuming an anxious expression, and again sat down on its hind quarters like a dog.

"Towards three o'clock it took a few mouthfuls of gruel, and once more lay down. Ten minutes later it died without a struggle.

"*Autopsy.*—Nothing in the peritoneal cavity; little food in the intestine; the mucous membrane of the small intestine was congested in places. The stomach contained a few quarts of liquid; its walls were contracted and wrinkled. The liver was large and yellowish brown in colour. The kidneys were pale on section; the pelvis of the kidney contained a little viscous yellowish liquid. With the exception of a small abscess in the anterior part of the right lobe the lungs were normal. The bronchial glands were slightly swollen. Nothing abnormal in the bronchi or trachea.

"The heart had stopped in diastole. The blood which escaped on section was liquid and blackish, but coagulated rapidly.

"The lower and lateral surfaces of the tongue showed several ecchymosed patches, over which the mucous membrane was denuded of epithelium. The epithelium covering the upper surface was at many points greatly thickened. At the entrance to the pharynx were several blind sacs (Morgagni's diverticula); the buccal mucous membrane showed nothing unusual.

"The mucous membrane of the pharynx was thickened, violet in colour, ulcerated in places, and covered with whitish spots indicating little abscesses developed in the submucous connective tissue. Gentle pressure caused them to discharge thick yellowish-white fœtid pus. The mucous membrane covering the anterior surface and base of the epiglottis was also thickened and violet in colour. The arytænoid cartilages were of similar appearance. The mucous membrane of the pharynx was in places three eighths of an inch thick; its superficial layer was hyperæmic, thickened, and infiltrated with offensive pus. The subjacent muscles were similarly thickened, discoloured, and whitish, and contained numerous small abscesses.

"The retro-pharyngeal glands were as large as a hen's egg, and contained purulent centres, some of considerable size; all were filled with whitish creamy stinking pus."

This horse, therefore, died of diffuse inflammatory pharyngitis

developed during strangles. Among the complications of this disease pharyngitis is one of the commonest and least dangerous. It is indicated, like other forms of sore throat, by loss of appetite, discharge from the nostrils of fluid mixed with food and of part of the drinking-water, by swelling and abnormal sensibility of the throat region. In pharyngitis resulting from strangles the lymphatic glands in the posterior portion of the intermaxillary space become inflamed, causing œdematous swelling, which is soon followed by abscess formation. In the majority of cases the only surgical treatment necessary is puncture of the abscess, recovery occurring in from a fortnight to a month.

The grave forms of pharyngitis due to strangles are those in which abscesses develop deep in the guttural region near the subparotid or retro-pharyngeal lymphatic glands. Functional symptoms are then more marked and often alarming, swelling of the throat and of the parotid region being sometimes enormous. To prevent rapidly fatal complications the pus must, as soon as possible, be evacuated.

Provided free drainage is secured, the swelling which accompanies these abscesses usually disappears rapidly. Unless expectant treatment is too long pursued, respiration seldom becomes so embarrassed as to necessitate tracheotomy. In any case, if dyspnœa become intense and the pus cannot be discovered even after several exploratory punctures, no hesitation need be felt in operating, as in the horse the method is very simple, never proves harmful, gives immediate relief, and removes one cause of aggravation of the pharyngitis.

[Operation is as follows:—A twitch having been applied, and the seat of operation cleansed and disinfected, an incision is made through the skin over the highest part of the swelling, and if possible below the edge of the parotid, the underlying fascia divided, and the forefinger inserted. The thick connective tissue or gland structure is now broken down, the free hand meanwhile pressing on the swelling and guiding the inserted finger towards the abscess, which, on being localised, is broken by a sharp, powerful thrust. A stream of pus escapes, often spurting to a distance of several yards. The opening may afterwards be enlarged, and a gauze or rubber drain inserted.—Jno. A. W. D.]

In our patient the pharyngeal inflammation was never really menacing. We could scarcely discover any swelling or pain on pressure over the throat region. The abscess beneath the jaw was the only complication in that neighbourhood.

The persistence of functional disturbance after the fifteenth day, and the absence of local lesions capable of explaining it, caused me to

suspect paralysis of the pharynx. Even when inflammatory symptoms are relatively slight this paralysis may occur, as proved by many recorded cases. During February last we had in hospital a five-year-old mare in which pharyngeal paralysis occurred as a complication of benign strangles. Cauterisation in points—the treatment usually recommended, and the daily administration of two and a half to eight drachms of potassium iodide until signs of iodism appeared, gave no beneficial result though twice repeated. Nor did greater success attend the opening and washing out of the guttural pouches on both sides—an operation which, however, has sometimes succeeded, and which probably acts in a different way from cauterisation.

I thought of performing this operation in the case of the first horse, but deferred interfering, always hoping for improvement. In this animal, however, opening the guttural pouches could only have favoured rupture of the retro-pharyngeal abscesses. Even supposing this had occurred we should not have saved our patient. The gravest lesions—those which proved fatal—occurred in the walls of the pharynx itself, and in regard to them we could do nothing energetic or directly beneficial.

Nevertheless I have no hesitation in giving the following advice:

If in pharyngeal paralysis resulting from strangles, or from inflammatory sore throat of any character, the classical treatment fail, one should before giving up the case as hopeless suggest opening the guttural pouches—hyovertebrotomy.

XXXI.—TUBERCULOSIS IN THE HORSE.

During the past week an eight-year-old Norman gelding was brought for examination with the history that six months before it had suffered from "inflammation of the lungs," from which it seemed to recover, but that at the commencement of last month it had again fallen ill without any apparent cause. Its condition gradually became aggravated in spite of treatment.

The animal was extremely thin, and its general condition suggested a wasting disease. Breathing was not very rapid, but appeared painful. I was only able to make a partial examination, but exploration of the chest having revealed extensive diffuse changes in both pulmonary lobes, I mentioned to you that this discovery, together with the chronic character of the disease and the debilitated condition of the animal, aroused suspicion of tuberculosis.

The patient was left in hospital. One of you made a note during the evening of the principal symptoms which it presented. I may briefly recapitulate them.

"The mucous membrane of the mouth is pale and cold to the touch, as are the trunk and limbs. The conjunctiva is whitish and slightly infiltrated; the pulse from 50 to 55 per minute, small and irregular; the respiration 20 per minute, accelerated, painful, and interrupted. On auscultating the lung the respiratory murmur is diminished in the lower portion of both lobes. In the middle portion, crepitant, sibilant, and cavernous râles are heard, and in the upper an increased vesicular murmur. On percussion the upper and middle zones are normally resonant, but the lower is partially dull. Palpation of the abdomen and rectal exploration reveal nothing abnormal. The anterior part of the sternal region is œdematous. Urine is passed frequently and in large quantities, saturating the litter and giving off a strong odour. The patient has taken a part of its food."

I purposed testing this horse with tuberculin, but it died during the night.

Autopsy.—"In the abdominal cavity the kidneys and supra-renal

capsules are the only organs which have undergone change. On incising the former, tubercles appeared scattered throughout both portions of the parenchyma. The supra-renal capsules are hypertrophied, and show on section several little yellowish softened tubercles, the pus from which contains bacilli. In the anterior portion of the sublumbar region, and adherent to the diaphragm, is a lymphatic gland as large as a walnut, the centre purulent.

"In the thoracic cavity disease is marked. Both lungs are large, dense, and firm to the touch; their surface is dotted over with greyish-white points and little patches. Palpation reveals hardened granules and a few small areas of fibrous consistence in the superficial layers.

"Vertical sections have a very diversified appearance, depending on the part of the lobe examined. The anterior part of both lobes shows fine greyish granules, varying in size between a grain of sand and a millet seed; at certain points these become confluent, forming narrow lines or slender irregular bands of lighter colour, which stand out prominently against the deeper tint of the adjacent unchanged tissue, where the vessels are simply engorged with blood. No softened centres are seen in these preliminary sections. Towards the base, and in the upper third of the lobes, a few small areas remain in which the lung has preserved its physiological characters. Sections through these are of similar aspect to the preceding. In other regions they show very numerous unsoftened miliary tubercles, at many points confluent, at others separated by hepatised or indurated pulmonary tissue. Certain sections which appear greyish, and of the same firm consistence as in chronic pneumonia, contain enormous numbers of whitish or yellowish granules, masses of broken-down tubercles and irregular cavernous spaces, varying in size up to two inches in diameter, containing pus rich in bacilli: the walls of several of these cavernous spaces are lined by a kind of yellowish diphtheroid exudate. Other sections again show irregular greenish-grey patches, indicating fragments of necrotic tissue. In most of the large bronchi the mucous membrane is inflamed and thickened.

"The right bronchial glands form a number of swellings the size of an almond. The left are fused together into an egg-sized mass, the centre of which contains a cavity filled with viscous, greenish-yellow pus.

"Immediately in front of the diaphragm, beneath the vertebral column, are several hypertrophied glands the size of hazel-nuts, with purulent centres. In the posterior mediastinum the supra-œsophageal gland is also swollen and has undergone suppuration; the chain of œsophageal glands and the lymphatic vessels connecting them are hardened."

Tuberculous infiltration of the lung. Section of the right lobe.

In the horse, as in other species of animals, tuberculous changes are sometimes generalised, sometimes—and most frequently—localised in the thoracic or abdominal viscera. Analysis of the cases published in France and other countries shows that the organs may be arranged in the following order with regard to the relative frequence with which they are affected :—lungs, bronchial glands, mesenteric and sublumbar glands, mediastinal glands, spleen, liver, pleura, peritoneum, intestine. The proportion of cases of pulmonary tuberculosis is about 70 per cent. ; of tuberculosis of the mesenteric and sublumbar glands and of the spleen about 40 per cent. ; of the liver, pleura, and peritoneum 20 per cent. ; of the intestine 15 per cent. Pleurisy has been noted in about a fifth of the cases. Ascites is more rare.

Tuberculosis of the kidney, though common in certain species, especially in the dog, appears to be exceptional in the horse. The pericardium, heart, bones, muscles, and other tissues are rarely affected. I have seen only two cases of tuberculosis of the endocardium, two of the pericardium, two of the bones, and one of the mammary gland. In one of his reported cases Mauri mentions tuberculous lesions of the pharyngeal glands, of the pharyngo-tracheal mucous membrane, and of the endocardium. Wolstenholme claims to have seen several cases of tuberculosis of the brain, but without furnishing any proof that the lesions were really due to tubercle bacilli. In one case showing pulmonary lesions and cavernous spaces, ossification of the right auricle of the heart was noted.

The changes in the thoracic organs, and especially in the lung, do not always present the characters found in our patient. Sometimes the pulmonary lobes are crammed with recent miliary granules, such as may be seen in the other specimen. These granules are whitish or yellowish in colour, dense, hard, and without central softening ; they are dispersed throughout the entire lung, isolated in most instances, confluent in a certain number, but always firm and unsoftened. In general, the parenchyma of the lung in which they are embedded is of normal colour and consistence.

In other cases tubercles have developed in considerable numbers in the connective tissue of the lung without producing signs of acute inflammation. Here is a specimen of such tubercular infiltration. The surface of sections appears almost entirely covered with whitish, very dense masses of tubercle, irregular in outline, united by bands of the same appearance and nature which run in all directions, intertwining and enclosing portions of apparently healthy or slightly hyperæmic parenchyma. You will note that such lesions are particularly large towards the upper part of the lung. On bacteriological examina-

tion we found very few bacilli, whether the rubbings or sections were treated by Ehrlich's, Ziehl's, or Kühne's methods. In this form, and in the preceding, the two pulmonary lobes may weigh as much as eighty-eight pounds or even more.

Finally the lung sometimes exhibits lesions which to the naked eye resemble sarcomata. Here are sections of lung from a twelve-year-old horse slaughtered during the surgical exercises, in which you may observe this form of lesion. Both lungs were at points bosselated, and quite deformed by spherical tumours, developed more especially towards their upper border. Five of these, three in the right and two in the left lobe, were as large as a man's fist, appearing externally as large hemispherical projections. Regularly rounded in outline and easily separable from the surrounding tissues, these swellings were built up of little globular masses, pale grey or slightly yellowish on section, with a few softened centres. At points, and especially towards the periphery of the lung, these growths were separated by bands or tracts of whitish fibrous tissue, denser and firmer than the substance of the lobules. The growths were surrounded by a thin fibrous layer; their surroundings showed no signs of acute inflammation or sclerosis, the pulmonary tissue immediately encircling them being of normal appearance, except at a few points where tubercles varying in size between a hemp-seed and a small nut were found. One, however, was surrounded by a layer of pulmonary tissue, between $\frac{3}{8}$ and $\frac{3}{4}$ of an inch thick, infiltrated with granules. Of these medium and small-sized masses some showed the same microscopic appearances as the preceding, others were dotted with yellowish points indicating softened granules, while still others were marked with little brownish, irregular spots; all were remarkably rich in giant-cells, but scarcely contained more bacilli than the larger growths. Bacilli, in fact, were only found in a proportion of the sections.

The tracheo-bronchial lymphatic glands sometimes form very large, dense, firm swellings of uniform fibrous consistence, or softened, caseous, or partially calcified growths, embracing the terminal portion of the trachea and neighbourhood of the bronchi. In exceptional instances such lesions may be found at the *post-mortem* of animals with healthy lungs. Nielsen has related a curious case of this nature.

Tuberculosis of serous membranes is less common than in the ox. It exhibits the same naked-eye appearances and very nearly the same microscopic characters as in the bovine species; sometimes granules and tubercles are found in large numbers with or without a greyish or

Sarcomatous form of pulmonary tuberculosis. Section through the left lobe of the lung.

sanguinolent exudate. It is usually confined to the pleura or peritoneum. Lesions of the pericardium, endocardium, and meninges are rare.

In that form of tuberculosis known as abdominal the sublumbar lymphatic glands are transformed into enormous bosselated swellings covering the terminal portion of the aorta and origin of its branches, and sometimes occupying the entire subvertebral groove from the diaphragm to the pelvis. These swellings are superficially of uniform consistence, but on section often show caseous or even calcified centres. Their weight may even exceed 65 lbs. The mesenteric glands are more or less hypertrophied and caseous, or partly calcified. The intestine may exhibit ulcerations or tubercles. The liver and spleen are always larger than normal, and may either be crowded with fine granules or bosselated, covered with whitish swellings varying in size between a hazel-nut and a child's head, uniformly dense, of the consistence of sarcoma, or partially calcified, especially in the case of the spleen. The common form of tuberculosis of the spleen can only be differentiated from sarcoma and lymphadenoma by microscopical examination and inoculation. In cases of old standing and extensive abdominal lesions the lungs usually contained large numbers of granules and tubercles.*

The statement of certain authors that calcification is not seen in tuberculous lesions in the horse is incorrect. This change has really been mentioned in a number of instances. I may add that atheromatous degeneration and calcification of the walls of the common and posterior aortæ are fairly frequent in tuberculous horses.

When infection has occurred by the respiratory passages lesions may be confined to thoracic organs like the lung, tracheo-bronchial and mediastinal glands, pleura, and pericardium, but usually the abdominal viscera, especially the mesenteric glands and spleen, are simultaneously affected. When the bacilli have penetrated by the intestine the abdominal organs, and particularly the mesenteric glands, liver, spleen, and peritoneum—sometimes even the intestine—show older and usually more extensive lesions than are met with in the thoracic cavity. Identification of the point of entry of the virus is not always so easy a matter as one might be led to believe. It is principally based on the size and age of the lesions in the abdominal and thoracic organs respectively, and on the existence or absence of centres of degeneration. When recent pulmonary tuberculosis is accompanied by extensive and old-standing changes in the abdominal viscera, the virus has certainly entered by the intestine; but when the pulmonary lesions are of old

* Bacteriological and experimental investigations have led M. Nocard to conclude that the pulmonary form of equine tuberculosis resembles human tuberculosis, and the abdominal form avian tuberculosis.

standing, and contain degenerative centres like those in the abdomen, it becomes difficult to decide whether they are primary or secondary.

The development of equine tuberculosis is usually slow, insidious, and accompanied only by disturbance common to a number of visceral diseases. The first indications consist in gradually increasing weakness, signs of fatigue, perspiration after slight exertion, capricious or diminished appetite, febrile attacks, and lastly wasting.

When the lung is invaded to a certain degree, signs of chronic broncho-pneumonia or broken wind may occur; the animal shows paroxysms of coughing, dyspnœa, acceleration of the respiratory movements, with a double, jerky, expiratory effort, and a mucous or muco-purulent discharge, sometimes fœtid or streaked with blood. On auscultation the vesicular murmur is usually audible over the entire area of both lobes, sometimes diminished, sometimes locally increased; crepitant or sibilant râles may be heard, but the tubal murmur is rare. The parts continue resonant on percussion, though small areas may appear partially or completely dull. At a later stage the swelling formed by the enlarged tracheo-bronchial glands may in some animals be seen at the entrance of the thorax and on the sides of the trachea. Pulmonary tuberculosis of rapid development may at first sight give the impression of pneumonia, or, if accompanied by pleural exudate, of pleuro-pneumonia.

The existence of abdominal tuberculosis is often scarcely suspected until the moment of death. In occasional instances visceral lesions may produce colic; or those of the intestine cause chronic enteritis with profuse diarrhœa, the fluid being blood-stained when the mucous membrane is ulcerated. When the disease is suspected rectal exploration very often reveals the presence of sublumbar swellings.

Specific glandular enlargement may appear externally in various regions, especially in the submaxillary space and in front of the chest. Those in the submaxillary space have often been mistaken for glanderous lesions. Ehrhardt followed the progress of a case which commenced with symptoms of sore throat and swelling of the submaxillary glands. For a time he suspected the animal of glanders, but three years later it died from generalised tuberculosis. In a horse mentioned by Johne a swelling resembling a cold abscess appeared in front of the chest, over the seat of the prepectoral glands, and was removed. The wound refused to heal. Shortly afterwards emaciation set in, the animal appeared feeble, and the symptoms seemed to point to lesions in the lungs and abdominal viscera. The nature of the disease was not recognised until *post-mortem* examination. Röbert published an almost

similar case. Multiple and bilateral swelling of lymphatic glands may at first glance suggest lymphangitis.

At a varying but usually late stage in the disease most patients show abundant polyuria, followed by rapid wasting, a fact to which M. Nocard called attention ten years ago in an "Étude clinique de la Phthisie tuberculeuse du Cheval." The urine contains large quantities of urea and uric acid.

In the horse tuberculosis usually follows a very slow course, certain patients continuing work for months, or even years, and showing little tendency to emaciation or to febrile attacks. The changes may long remain localised in the abdominal glands, but finally the subjects either become very feeble or the bacilli enter the venous circulation, causing general infection. Febrile symptoms are then seen. The temperature rises to 40° C. or 40·5° C. (104° F. or 104·9° F.), and wasting makes rapid strides. Sometimes the hind limbs become swollen.

In the horse tuberculosis may also assume unusual forms, liable to be mistaken for other diseases, which differ so widely from classical types as not even to suggest the idea of tuberculous infection. I will describe two cases from my own clinique.

The first was that of an eight-year-old horse brought for examination in April, 1889, by a contractor who had bought it three years before. Different points on the surface of the body showed indolent tumours of fibrous consistence and varying size, the largest about the diameter of a two-shilling piece and the thickness of a man's little finger. Some had developed in the skin, others in the subcutaneous connective tissue; both varieties were accompanied by disease of lymphatic glands. At certain points the largest swellings were connected with neighbouring lymphatic glands by corded lymph vessels.

The patient was left here for more thorough examination. Rectal exploration revealed nothing. The temperature oscillated between 39° C. and 39·5° C. (102·2° F. and 103·1° F.). The urine was of normal amount, but slightly albuminous. The proportion of red and white blood-corpuscles was normal. One of the subcutaneous swellings was excised for histological study. Its structure was that of a sarcoma. The horse was removed home and put to work, but grew more and more feeble. At a trot its breathing became steadily aggravated, and a loud roaring sound was produced. Certain tumours diminished and disappeared, but many others developed. Having become incapable of work the animal was slaughtered. On *post-mortem* examination we found numerous swellings in the skin and subcutaneous connective tissue, together with neoplastic and sclerosing infiltration of certain

groups of muscles, especially of the adductors of the hind limbs and superficial gluteal muscles; nodules in the liver and spleen, and hypertrophy of the sublumbar lymphatic glands. Bacteriological examination showed these lesions to be of tuberculous origin, though bacilli were very scanty.

Up to the present time only two cases of dermic and hypodermic tuberculosis in the horse have been published. Excluding the lymphangitis and inflammation of lymphatic glands, the symptoms are those of subcutaneous sarcoma—a disease which formed the subject of a previous lecture, but is also very rare.

The case I am about to mention is exceedingly instructive from the clinical point of view. It is shortly as follows.

At the commencement of May last we received into hospital a very well nourished seven-year-old entire horse, bought in 1894, which had done excellent service for nearly two years, viz. until February, 1896. It had simply shown swelling of the scrotum. As, however, the swelling increased in size until finally it interfered with the action of the hind limbs, the animal was brought here to be castrated.

On examination we detected chronic inflammation of the right testicle and its envelopes. The animal not having reacted to mallein, castration was performed. The testicle, enlarged to three times its normal dimensions, was removed with the écraseur; its parenchyma had undergone little change; the head of the epididymis was as large as an orange, its tissue whitish and sclerosed; the cord was healthy, except that its serous covering was dotted over with reddish granulations varying in size between that of a millet seed and a small pea. These granulations were regarded as innocent inflammatory products.

Considerable swelling occurred round the wound, but soon became absorbed, and the wound itself appeared to heal regularly.

At the owner's request the other testicle was removed fifteen days after the first operation, the écraseur again being employed. It was about one third larger than normal, the vaginal tunic contained a little lemon-coloured liquid, the cord was slightly swollen, and its serous covering partly dotted over with granulations like those seen on the former occasion.

During the following days the general condition and appetite were good. Nevertheless fever was marked, the temperature rising nearly to 40° C. (104° F.). The scrotal swelling was large. This condition persisted for a week without any appreciable change except that the animal became rather thinner. One morning, however, the horse was found dead in its stall. On the previous evening it had eaten all its food, and the student in charge had noted nothing alarming.

Tuberculous endocarditis in the horse. Left ventricle.

On *post-mortem* examination it became clear that the horse had died from tuberculosis. The spermatic cords were swollen, indurated, and covered with granulations. The liver, spleen, lungs, sublumbar and bronchial glands, peritoneum, pleura, and pericardium all contained numerous tubercles. The intestinal mucous membrane, and especially that of the large colon, was crowded with ulcerations, most of which were very rich in bacilli. The heart showed remarkable changes. Large tracts of the endocardium of the left ventricle were thickened, wrinkled, and contracted. Histological and bacteriological examination revealed the presence in it of tuberculous follicles containing very few bacilli. Situated slightly below the aortic orifice in the muscular tissue of the heart was a tuberculous abscess as large as a hazel-nut, the pus from which contained numerous bacilli.

A dog, a rabbit, two guinea-pigs, and two fowls were intra-peritoneally inoculated with an emulsion prepared by crushing a fragment from a sublumbar lymphatic gland and a tuberculous growth from the gastro-colic omentum in a little sterilised water. The dog, rabbit, and guinea-pigs became tuberculous, the fowls resisted.

Bearing in mind the varying forms which tuberculosis may assume in the horse, it is rare that some of the complex assemblage of symptoms fails to suggest the correct diagnosis. The final conclusion is assisted by auscultation, percussion, rectal exploration, and palpation of accessible lymphatic glands, and is confirmed by bacteriological examination, injection with tuberculin, or inoculation.

The clinical signs suffice to differentiate tuberculous inflammation of lymphatic glands from the simple form (adenitis); in the latter the swellings are always numerous, generalised, bilateral, and nearly uniform in each of a pair of glands.

Injection of 30 centigrammes of tuberculin is followed in tuberculous horses by a reaction, which usually attains its maximum about the fifteenth hour, the temperature rising 2 to 3 degrees C. In the stable attached to the surgical clinique you have seen a horse retained for experiments which developed tuberculosis after a double intra-peritoneal and subcutaneous injection of tuberculous material from a dog. After the lapse of more than a year tuberculin still produces a febrile reaction of 1 to 2·5 degrees C.

At the present moment there is no treatment for tuberculosis in large animals: diagnosis is followed by slaughter. The veterinary surgeon's function is limited to recognising the clinical forms and the anatomical and pathological appearances.

XXXII.—TUBERCULOSIS IN THE DOG.

Among the canine patients received into hospital during the past week two were entered as suffering from tuberculosis. Both were suffering from pulmonary lesions, and were capable of spreading the tuberculous poison throughout the places where they lived.

I will recall the history of the first. This was a fine two-year-old poodle, which was in the habit of accompanying its master each evening to the tavern, where a prolonged stay was often made. About three months ago this dog was noticed to leave portions of its food, to suffer from cough, and to be wasting. It was unsuccessfully treated with various tonic preparations. One morning, after having followed its master, who was riding a bicycle, it returned home, lay down, and refused food. Next day it still refused food, and would not leave its kennel. The day after it was brought to the College.

It was exceedingly dull and already much emaciated; the temporal muscles were wasted; the respiration was rapid and discordant; on percussion the entire lower half of both sides of the chest was dull. The chest was tapped on the right side, and a greyish turbid fluid drawn off, in which bacteriological examination failed to discover bacilli. But the thin bodily condition and the pleurisy left little doubt regarding diagnosis: the dog was tuberculous. The owner consented to leave it in hospital. The temperature was 39·8° C. (103·6° F.), nevertheless I injected 10 centigrammes of tuberculin; it produced a reaction of three tenths of a degree C. (·5° F.). During the next two days the temperature showed slight variations around 39·5° C. (103·1° F.), the respiration steadily becoming quicker and more difficult. In spite of a fresh tapping operation, in which more than one and three-quarter pints of fluid were withdrawn, the condition continued to grow more serious, and death resulted forty-eight hours later.

We found no tuberculous lesion in the abdomen. The chest cavity, however, still contained a certain quantity of greyish turbid liquid holding in suspension opaque particles. The pleura was

thickened, showed rounded elevations at certain points, granulations and tubercles at others. The mediastinum and its lymphatic glands were enlarged. Opposite the division between the diaphragmatic and cardiac lobes of the left lung was a small ulcerous wound due to the opening of a cavernous space. The diaphragmatic lobe contained an inflammatory centre as large as a nut, the central portion of which had broken down and was full of greenish-grey pus; around it the pulmonary tissue was dotted with little purulent centres. The right lung showed a few cicatricial patches, and its surface was adherent to the parietal pleura at several points. Bacteriological examination revealed numerous bacilli in the pus from the cavernous space.

Our second patient was a three-year-old sheep-dog bought at the age of six months by its present owner. It was allowed to run about freely in a restaurant patronised chiefly by workmen and shop assistants, and was in the habit of turning over the scraps of food from the plates and the heaps of rubbish. Six weeks before, the animal lost its appetite. From this time it became markedly thinner, and when examined could scarcely stand upright. The face suggested extreme depression; the eye was retracted within the orbit; the temporal and all the usually prominent muscles were wasted; the skin was dry and adherent to the subjacent tissues. Respiration was rapid and painful, and during expiration a portion of the air escaped from between the lips. On auscultating the chest crepitant and mucous râles were noted on either side. The percussion sound was partially dull. There was no discharge from the nostrils.

Suspecting tuberculosis, we insisted on the animal being left in hospital for observation.

The day afterwards we administered a dose of tuberculin; the temperature was 38·1° C. (100·5° F.) before injection, and five hours afterwards rose to 39·3° C. (102·7° F.). Tuberculin had therefore produced fever to the extent of 1·2° C. (2·4° F.). Three days later the animal was killed at the owner's request.

On *post-mortem* examination we found the mesentery covered with myriads of little tubercles between the sizes of a grain of millet and a pea. The mesenteric glands were slightly enlarged. The liver was increased in size and infiltrated with tubercles of all dimensions.

In the thoracic cavity the pleura was covered with granulations and tubercles. The mediastinum was greatly thickened, and appeared bosselated in consequence of disease of the lymphatic glands. The lungs contained numerous tubercles and some cavernous spaces filled with fluid rich in bacilli.

I have often mentioned canine tuberculosis, its different forms, the symptoms which it produces, and the peculiarities seen in certain patients. Furthermore, I have shown you that the disease may easily be mistaken even on *post-mortem* examination. As this morning occasion has again arisen for speaking of the disease, I will cast a rapid glance over the cases I have collected, and briefly describe some which deserve remembrance.

Before Villemin published his experiments, the existence of tuberculosis in the dog, though described by some authors, was still contested by most. The discovery that the disease was inoculable, and the later identification of the bacillus which produced it, showed that the dog was subject to tuberculosis, and allowed of distinguishing this infection from other morbid processes anatomically characterised by lesions of a tubercle-like character.

During a further period of nearly ten years—until 1891—canine tuberculosis was usually regarded as exceptionally rare. This opinion was founded on the few cases published in France and abroad previous to the latter date, despite the new power of confirming diagnosis, either during the patient's life or after death.

During 1891 I turned my attention to this form of tuberculosis. I looked for it at Alfort in patients in my own portion of the hospital and among those brought for consultation. I was soon convinced that it could not be considered rare, and that the reason for its continuing to be so regarded was because observers failed to differentiate it, because its pulmonary localisations were mistaken for chronic pneumonia, and its other lesions—especially those in the liver, serous membranes, and lymphatic glands—for cancer.

In 1893 I had collected statistics of forty cases. These sufficed for a description of the principal forms of the infection, its localisations, and its anatomical and pathological characters.*

Pursuing my researches on the patients brought to the outer clinique, and assisted by students who followed them up in the surgical hospital, I was able to collect 165 new cases in which diagnosis was verified by *post-mortem* examination.

In the dog the localisations of tuberculosis are as varied as in other species. Sometimes lesions are rare, limited to a few organs, or even to only one; much more frequently they are found in the majority of the viscera and lymphatic glands, and with a fair degree of frequency in the pleura and peritoneum. In the 205 cases at present collected the thoracic and abdominal viscera have been invaded in 140 cases, in

* Cadiot, 'La Tuberculose du Chien,' Paris, 1893.

53 the lesions have been confined to the thoracic, and in 12 to the abdominal organs. The figures are as follows:

Thoracic Cavity.

Tuberculosis of the lung		158	cases.
,,	,, bronchial and mediastinal glands	114	,,
,,	,, pleura	83	,,
,,	,, pericardium	39	,,
,,	,, myocardium	16	,,
,,	,, endocardium	3	,,

Abdominal Cavity.

Tuberculosis of the liver		119	cases.
,,	,, kidney	76	,,
,,	,, mesenteric glands	62	,,
,,	,, peritoneum	57	,,
,,	,, intestine	18	,,

The pleura, pericardium, and peritoneum are frequently the seat of serous or sero-fibrinous, and sometimes purulent or hæmorrhagic exudation. I have seen pleurisy in ninety cases, pericarditis in twenty-eight, and ascites in forty-nine.

I have laid stress on the frequency of pleurisy as a common accident in tuberculosis; specific inflammation of the pleura, with serous or purulent exudate, has been found in almost one half of the subjects examined. And just as pleural inflammation is common in dogs affected with tuberculosis, it is exceptional in non-tuberculous patients; so far as canine pathology is concerned, this is with me a fixed idea. Examining my last fifty cases of canine pleurisy from this point of view —I am now only speaking of cases in which diagnosis was checked by *post-mortem* and bacteriological examination—I found tuberculosis to be the cause in forty-one instances, that is to say in 82 per cent. of cases—a proportion approximately the same as that arrived at for man by the most recent researches.

Exudative pericarditis also is usually symptomatic of tuberculous infection, though, like pleurisy, it may be seen alone, without any other specific localisation.

Certain manifestations of tuberculosis in the dog are atypical, and sometimes very different from those usually seen, the lesions of the liver and epiploon being the most remarkable. You know that the tuberculous liver generally shows a large number of little whitish, greyish, or

yellowish nodules, of rather firm, uniform consistence, the majority varying in size between a hemp-seed and large pea. Many of those in the superficial layers of the organ are hemispherical or conical—their base resting on Glisson's capsule—with finely dentated circumference (Fig. 18). The largest have a whitish periphery and slightly depressed yellowish centre; a few of smaller size sometimes present a glistening

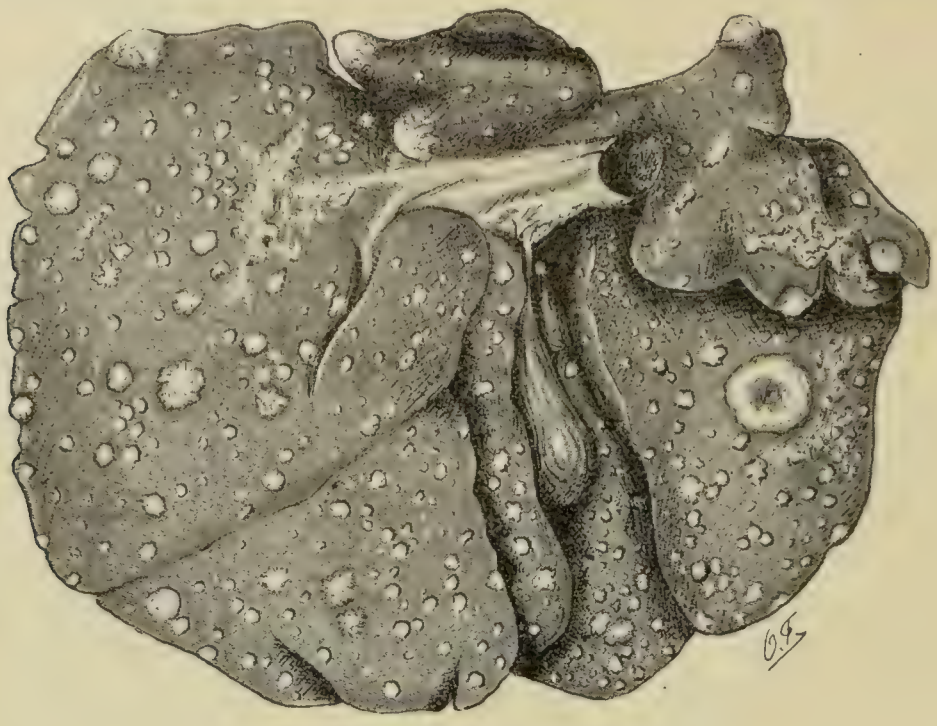

Fig. 18.—Tuberculosis of the liver.

nacreous appearance, and a central opaque, caseous point. In this form the lesions are somewhat similar to those seen in hepatic tuberculosis of fowls, and have often been mistaken for cancer. Straus himself, on examining the liver I sent him, at first thought I must have been mistaken, so similar were the lesions to cancerous nodules. In some subjects, instead of presenting this appearance, the liver is deformed by large yellowish-white tuberculous areas of uniform sarcomatous consistence, or softened and excavated at their centre by a more or less spacious cavity filled with greyish or lactescent fluid. In this liver, which was removed from a dog killed a few months ago, you see this atypical form of tuberculosis; the lesions appear as large yellowish-white cystic tumours, fluctuating throughout the greater portion of their area, covered with branching vessels, but firmer towards their margins, which are sharply defined (Fig. 19).

The mesentery and epiploon, which are sometimes thickened and indurated, are generally dotted over with granules and isolated or confluent tubercles. They may also be the seat of hyperplastic changes producing atypical lesions described as sarcomatous. The epiploon

especially may become so large as to be almost unrecognisable. In a dog dead of generalised chronic tuberculosis I found the epiploon had

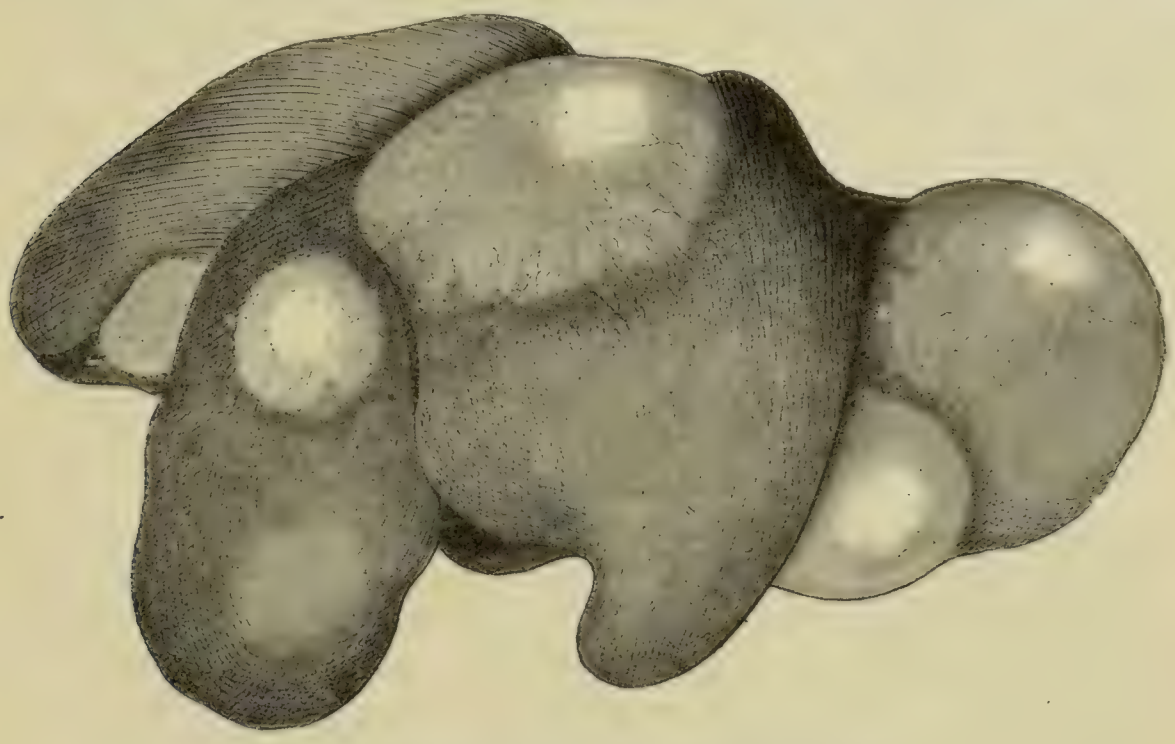

FIG. 19.—Tuberculosis of the liver (atypical form).

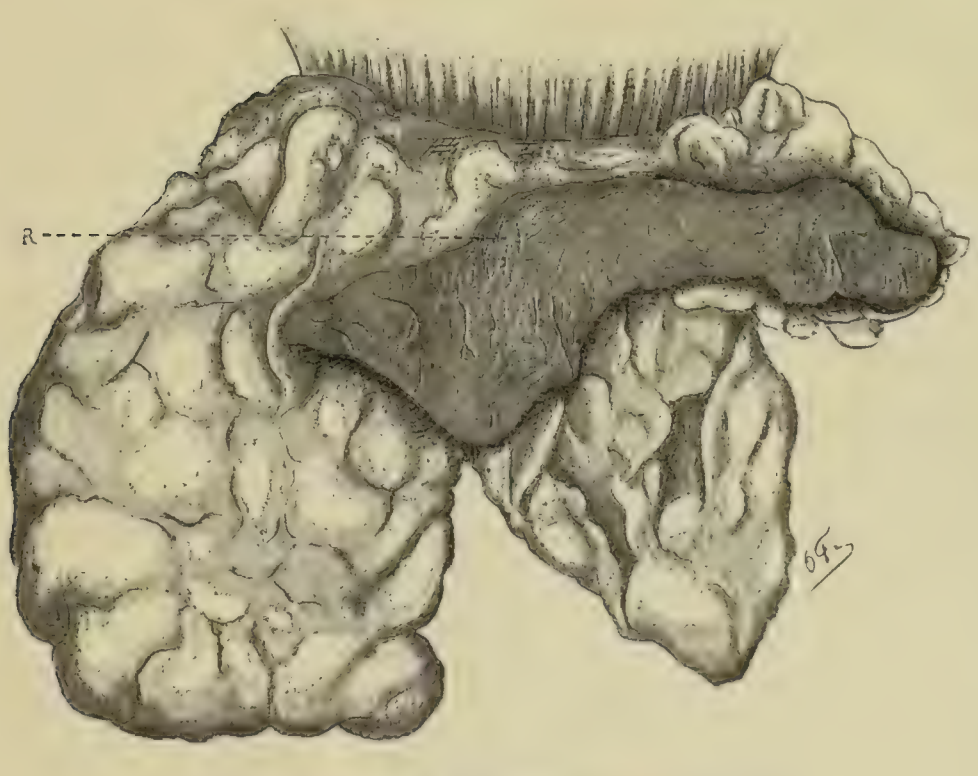

FIG. 20.—Tuberculosis of the epiploon. R, spleen.

assumed the form of a flattened rectangular, slightly incurved mass, with irregular, rounded projections, marked by vascular striæ; the

spleen, which rested on it, was absolutely unaffected (Fig. 20). Its tissue was very dense, of fibrous consistence, and creaked under the knife; transverse sections were nearly an inch in thickness, appeared whitish in colour, and were dotted over with caseous or cretaceous granulations, which could be shelled out without much difficulty.

In only two cases have I seen "tuberculous septicæmia," and in both the dogs were less than a year old. In one the blood had become infected from a pulmonary cavernous space; in the other, from an abscess in a lymphatic gland.

The latter case dates from September, 1893. It was brought here on account of steadily progressive emaciation and enlargement of the abdomen. On noting the ascites, and learning that the dog belonged to a wine-shop keeper, I suspected tuberculosis. The animal was left at the School to be tested with tuberculin. It died next day. The lesions found on *post-mortem* examination were of quite a different character from those usually seen in tuberculous patients. I preserved the liver and spleen. These organs were free of tubercles and granulations, and only attracted attention by their enormous size and the appearance of their tissue; the liver, which weighed nearly 2 lbs., was yellowish, and had undergone fatty degeneration; the spleen was blackish, its tissue very friable, and except for the difference in colour resembled a lymphadenomatous spleen. Both organs contained enormous quantities of bacilli, which on microscopical examination appeared as broad tracts, and were as numerous as in cover-glass preparations from a culture.

The diagnosis of tuberculosis in the dog may be founded on clinical signs and the use of tuberculin, and is confirmed by discovery of bacilli in the nasal discharge or in the pus, and by inoculation.

Although the usual symptoms are by no means characteristic they can scarcely be mistaken for those of visceral cancer (sarcoma or carcinoma); and the fact of their existence implies a great probability that the disease is tuberculous, for in the dog—contrary to the still widely held opinion—tuberculosis is much commoner than generalised cancer. In *post-mortem* examinations carried out during the last five years I have several times had series of ten, fifteen, and even twenty cases of tuberculosis for each case of generalised cancer.

As in other species of animals, tuberculin is a good test for tuberculosis. At the commencement of my experiments I injected many suspected dogs without producing any apparent reaction. But if tuberculin appeared so unreliable, it was because my method was faulty; I injected the dogs in the evening about 9 p.m., and only took the temperature every two hours after 6 a.m. next morning: in most

cases the characteristic temperature reaction had then passed. From the temperature charts of forty animals injected with tuberculin, I have found that the maximum reaction occurs between the fourth and eighth hours. In general it is quite distinctive. With doses of 5 to 10 centigrammes of tuberculin the temperature rises from 1° to 3° C. Tuberculous cases, however, do occur, especially among animals which are very feeble or affected with generalised lesions, in which the reaction is trifling or *nil*. Quite recently I saw a Danish boarhound, still in fairly good health, but proved by subsequent *post-mortem* examination to be distinctly tuberculous, which did not react in the smallest degree to two injections of tuberculin, although the initial temperature was on the first occasion 38° C. (100·4° F.), and on the second 38·3° C. (100·9° F.).

How does the dog contract tuberculosis? One fact at least appears certain, viz. that canine tuberculosis is of human origin. The numerous inquiries I have made leave no doubt on this point. Either the animal belonged to a phthisical patient or associated with a tuberculous person with whom it passed a portion of the day, or it accompanied its master daily to the wine-shop or eating-house—places where in very many instances the floor is soiled with sputum containing bacilli.

In the dog, also, there are two principal avenues of infection, the digestive and the respiratory mucous membranes. At first sight, having regard to the extreme frequency of pulmonary lesions and the difficulty of transmitting tuberculosis to the dog by ingestion of virulent material, it seems, as Straus has remarked, that infection occurs oftenest by the respiratory passages, in consequence of the dog inhaling infected dust. This is also the opinion I emitted in my work in 1893, but despite the negative results of experiments in which dogs were caused to ingest tuberculous material, despite the common absence of lesions indicating the passage of bacilli from the intestinal mucous membrane, and from the lymphatic glands originating there; finally, despite the predominance of pulmonary lesions, infection is caused at least as often by the ingestion of virulent material as by the inhalation of infective dust.

We know that many dogs have a propensity to lick up human sputa; some will even go to the spittoons. In 1893 I made the *post-mortem* examination of a young dog which became tuberculous under the following circumstances:—Its master, M. V—, living in the Boulevard de Picpus, in Paris, became affected with pulmonary tuberculosis. The doctor who treated him recommended the use of a special recipient for

sputum. In order to guard the dog against distemper Mme. V—, following the advice of some gossip, gave the animal from time to time the contents of the spittoon. This went on for several months. The dog ended by becoming tuberculous. Large lesions in the mesenteric glands and liver showed that infection had occurred through the intestine.

Without reference, however, to the source and channel of infection, the dog may become dangerous to man as soon as affected with lesions from which contagious material is externally discharged. A tuberculous dog which lives in or enters rooms inhabited by its master may there distribute such discharge. If it plays with, is petted, or looked after by children, this discharge may come in contact with their clothes, or even with their faces. Pet dogs may even infect the sleeping apartments or beds of their owners. In 1894 I was several times consulted by Mme. C—, living in the Rue Favart, at Paris, concerning a little terrier which for a long time had appeared thin, and at intervals had shown cough and nasal discharge. The dog was very closely watched, and without doubt had contracted tuberculosis in one of the watering-places in the south of France where Mme. C— annually resorted. I informed her that the dog was probably tuberculous, and suggested the necessary precautions to take, but only after some time would she consent to send it away. Though ill for a whole year the animal had passed most of its time in Mme. C—'s living room, and all its nights in her sleeping apartment. The *post-mortem* examination of this dog showed, in addition to other lesions, cavernous spaces in both pulmonary lobes and a tuberculous ulcer in the larynx.

My case-books contain a number of instances of this kind. I will only relate the most recent. On the 13th October last a dog, which the owner, a working man, thought pure-bred and of great value, was killed when in the last stage of emaciation. Its existence had been passed in two rooms, inhabited by this man, his wife, a three-year-old child, and the dog. The dog had been ill for five months, had had frequent attacks of coughing, discharge from the nose, and vomiting. It had not left the house except on the day when it was brought to Alfort. On *post-mortem* examination we found generalised tuberculous lesions; both lungs were full of tubercles, and in part destroyed by cavernous spaces.

You have noted that many tuberculous dogs show no discharge, or only a trifling running from the nose, and in the majority of those which do discharge the material is only seen at certain times. But

other secretions may disseminate contagion. Thus in animals with pulmonary tuberculosis the fæces are more or less charged with bacilli derived from the muco-pus ejected from the bronchi into the pharynx, and afterwards swallowed.

Several cases have been recorded showing that dogs with lesions of the kidneys or of the prostate also spread the virus by means of the urine. I published the first in 1897. It was that of a dog with generalised tuberculosis. The kidneys were crammed with tubercles which had almost entirely destroyed the cortical layer. The prostate was ten times its normal size, and its right lobe contained a cavernous space. On compressing the gland, after having incised the urethra, greyish pus, rich in bacilli, was seen to escape from its excretory ducts. Large numbers of bacilli were also present in the urine contained in the bladder. These renal and prostatic lesions were relatively old. For several months, therefore, the animal had been spreading tuberculous virus by means of the urine.

In one of our next lectures I shall speak of external forms of tuberculosis in the dog and cat, and shall show that these animals may become the subjects of tuberculous ulcers of the skin, hitherto mistaken for harmless lesions.

XXXIII.—TUBERCULOSIS IN THE CAT.

VERY much less has been written on the history of tuberculosis in the cat than in the dog. The cases hitherto reported are very scanty. I have only found thirty-one in special publications, either French or foreign, and the majority only mention lesions seen on *post-mortem* examination. Among these are comprised the twenty-two cases seen by Jensen while searching for tuberculosis among cats killed at the Veterinary School of Copenhagen during the thirteen months from November, 1889, to January, 1891, and the three cases previously collected by Bang, and published in Jensen's article. To these I can add ten other cases seen in the consulting clinique; in most cases the animals were given up by their owners, and either died of tuberculosis or were destroyed. This makes, therefore, a grand total of forty-one observations.

I have analysed these cases in order to show the relative frequence of the local lesions. The results are as follows:—Changes in the lungs, 29 cases; in the bronchial and mediastinal glands, 10; in the pleura, 3; in the trachea and nasal cavities, 1; in the pericardium and heart, 1; in the intestine, 4; in the mesenteric lymphatic glands, 22; in the liver, 5; spleen, 4; peritoneum (mesentery and epiploon), 5; kidneys, 8; testicles, 1; uterus, 1; submaxillary and cervical lymphatic glands, 2; muscles, 1; articulations, 2. Pleurisy was seen in 4 cases, and pericarditis in 2. Four animals showed tuberculous wounds.

On comparing these figures with those referring to similar lesions in the dog analogies are seen, but also notable differences. In both species the lung is the most frequently affected organ. In the cat lesions of the intestine, mesenteric lymphatic glands, and spleen are commoner than in the dog, while lesions of the liver and serous membranes, ascites, pleurisy, and pericarditis are rarer. Nevertheless it must be borne in mind that in a considerable number of cases the animals were killed, and the *post-mortem* examination only revealed

recent lesions. Could a large number of cases of advanced tuberculosis in both species be compared, the differences would probably be less marked.

The macroscopic and microscopic characters of tuberculous lesions

FIG. 21.—Tuberculous pneumonia. Section through the right lung showing cavernous spaces.

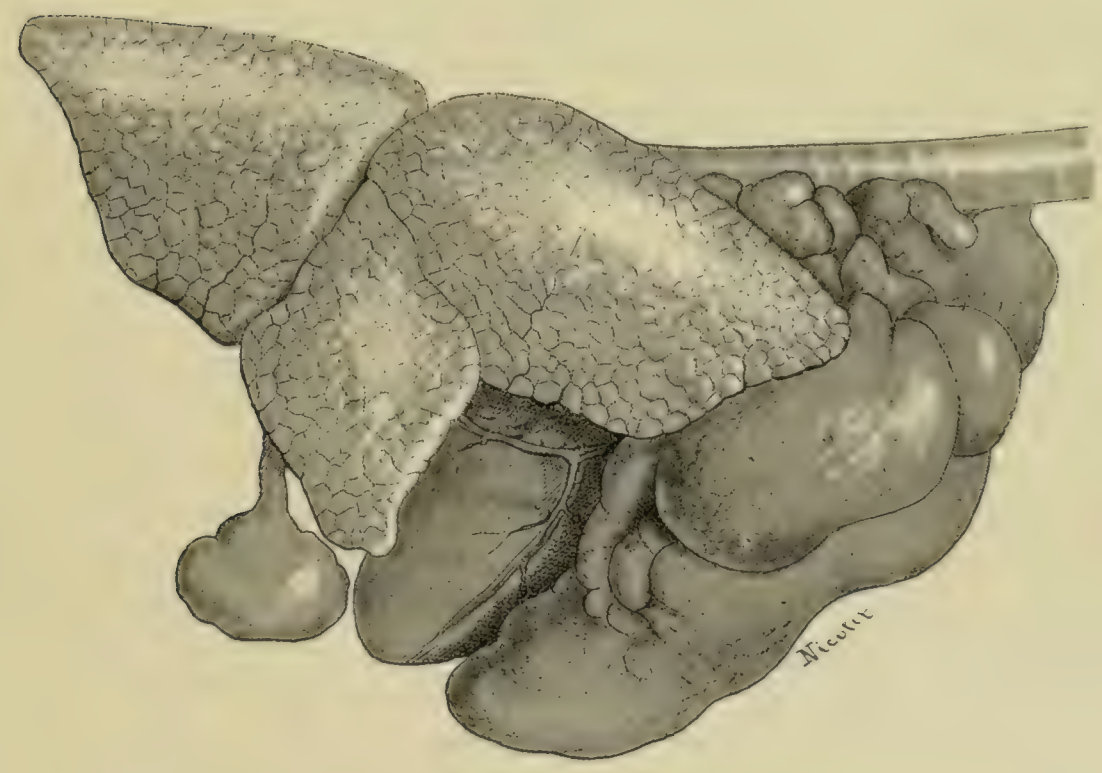

FIG. 22.—Tuberculosis of the tracheo-bronchial and mediastinal glands.

in the cat are very similar to those in the dog. The lungs show recent greyish granulations of homogeneous consistence, tubercles with softened purulent centres, yellowish-grey areas formed of agglomerations of tubercle, and more rarely diffuse chronic pneumonia with formation of

cavernous spaces (Fig. 21). In some cases only one or two large lesions may exist; in others both lobes are crammed with granules. Secondary lesions may also be seen, such as those of bronchitis and peribronchitis, broncho-pneumonia, bronchiectasis, emphysema, or pulmonary œdema.

The tracheo-bronchial glands, which are almost always affected in cases of pulmonary tuberculosis of any age, usually show moderate enlargement, appearing as a collection of little hardened masses the size of a pea, haricot bean, or almond. As in the dog, they may, however, become of large size, forming an ovoid or irregular mass surrounding the terminal portion of the trachea, the origin of the bronchi, the large vessels at the base of the heart, and the nerves traversing this region (Fig. 22); on section their tissue appears greyish or marbled with black lines, and dotted over with whitish, hard or softened caseous tubercles. They may undergo cystic transformation: the centre is then occupied by a cavity filled with greyish or slightly lactescent liquid.

In the majority of cases of pulmonary tuberculosis the visceral layer of the pleura is thickened, injected, and covered with false membranes opposite the seat of the pulmonary disease centres. Sometimes the costal and diaphragmatic portions of the pleura are covered with granulations; sometimes the mediastinum and its lymphatic glands show change. Finally, one or both of the pleural sacs and the pericardium may contain a varying quantity of serous or purulent liquid.

Intestinal tuberculosis is characterised by ulcerations of varying extent, depth, and number, which sometimes perforate the bowel. The mesenteric lymphatic glands are very commonly diseased. Opposite the cæcum they are usually confluent, forming yellowish bosselated masses, with caseous or purulent centres. The liver often contains a very large number of fine granules, isolated or massed together. Until now the voluminous cystic new growths occasionally seen in the dog have not been described in the cat. The spleen is simply enlarged or nodular on the surface; sections through its tissue show granulations and tubercles, the largest scarcely exceeding a pea in size. In tuberculosis of the kidney the external surface of the organ and the surface of sections sometimes show fine granulations, sometimes tubercles, or even greyish-white tuberculous areas, with cystic or purulent centres. Lesions of chronic nephritis are not uncommon. Bang claims to have seen a case of primary tuberculosis of the right kidney. As tuberculosis of the organs of generation is very rare I shall merely mention the case of primary tuberculosis of the uterus seen by Jensen in a female cat, and recorded by him as an example of infection *per coitum*—tuberculosis

of the testicle having been met with in the cat. Tuberculosis of the peritoneum is even less common than that of the pleura. The parietal layer is usually free; the lesions are limited to the epiploon and mesentery, which appear thickened and dotted over with fine granules. The peritoneal sac may contain more or less abundant, clear or purulent serosity, either poor or moderately rich in bacilli.

External tuberculous lesions, with and without ulceration, have several times been noted. I described two cases in a preceding lecture.

The paths of infection are multiple, but the two principal are the digestive and respiratory mucous membranes.

In most cases the bacilli enter the organism through the intestinal mucous membrane. In this way cats which ingest offal, milk, or other material derived from tuberculous animals, food infected by a tuberculous patient, or purulent sputum, may become infected. Nevertheless cats may also contract tuberculosis by living in rooms in which the atmosphere is charged with tuberculous dust. We know that in all species infection occurs readily through the respiratory mucous membrane. Passage of bacilli through other mucous membranes, and through the skin, is exceptional.

Contrary to the most widely held opinion, and to what one would be led to believe from the conditions of life and habits of the cat, tuberculosis in this animal is most frequently of human origin. In more than three fourths of the cases where the probable method of contagion could be traced, infection from man appeared indicated. The animals belonged to tuberculous subjects or lived in intimacy with them. In this connection the following interesting observation was made to me by my colleague, M. Darras, a veterinary surgeon in Paris:

"Mme. X—, *concierge*, had for four years owned a family of six cats, all of them superb, vigorous animals, in very good health. Towards the end of 1894 these animals began to grow thin and cough. The oldest one soon died. The *post-mortem* examination, made at Alfort, showed that death had resulted from tuberculosis. Both the thoracic and abdominal organs were affected. Shortly afterwards a female kitten, which had become very thin, showed multiple disease of lymphatic glands; the glands in the neck were especially large. It died at the end of a month. *Post-mortem* examination showed no intestinal or pulmonary lesion, but the mesenteric glands were enlarged, and the spleen (which was of great size) displayed very numerous granulations. No bacteriological examination was made. At the end of six months two other cats which had fallen away in condition,

although continuing to feed well, began to cough and to rapidly pine away. On my advice the worst case was killed. It showed abdominal tuberculosis, and bacteriological examination revealed the presence of bacilli in the lesions. The other, which was much troubled with cough, died two months later. On autopsy tuberculous lesions were found in the abdominal organs and lung. Finally one of the survivors showed symptoms which caused me to suspect it of tuberculosis.

"All the cats had enjoyed good health before the arrival in the house of a family containing several consumptives. The symptoms they showed, and the diagnosis given by several doctors, left no doubt as to the nature of the disease from which they were suffering. The members of this family (who were very fond of animals) used to allow Mme. X—'s cats into their rooms, and were in the habit of giving them the remains of their meals. In this way the animals probably became infected."

Contagion by tuberculous animals and their products appears less common than the preceding. In rural districts, where tuberculous cows are common, cats which live or pass the greater part of their time in the byre, and which consume milk from these animals, are exposed to infection. But in Paris (as in all large towns and their neighbourhoods) the cat is very rarely infected by animal products. Since 1892 I have bred thirty or more cats, feeding them on bread, a little chopped horse-flesh, but principally on raw milk from the Alfort cowsheds, the neighbouring localities, and the various parts of Paris. In most cases the feeding on raw milk was continued for five to six months, and in some for more than a year. None became tuberculous, and none showed any tuberculous lesion on *post-mortem* examination.

XXXIV.—HÆMOGLOBINURIA (AZOTURIA) IN THE HORSE.

THE day before yesterday we made a *post-mortem* examination of an eight-year-old stallion which had died after an illness of three days' duration. It was in good, even plethoric condition, and had been attacked while at work and apparently in full health, showing in a few minutes paralysis of the hind quarters and a number of extremely grave symptoms. The animal had for some years been regularly working for a firm of carters in Paris. On the 1st and 2nd January it had been left in the stable, which was badly ventilated. The morning of the 3rd January was cold, and after a quarter of an hour's work at a quiet trot the horse slackened his pace, sweated profusely over the hind quarters, showed weakness of the hind limbs, and while the driver (who thought the animal was suffering from colic) was wondering what he ought to do, the horse fell down in the shafts. It was unharnessed and helped up. It took a few steps, dragging the left hind limb along the ground, and again fell. It was then put into an ambulance to be taken back to the stable. A veterinary surgeon who was called in bled it, applied stimulant applications, and afterwards sent it to the School.

On its arrival we in vain attempted to place it on its legs. It had to be let down on the straw of the hospital theatre, where it lay struggling violently. The mucous membranes were injected, the circulation and respiration very rapid; the pulse 80; respirations 30; rectal temperature 39° C. (102·2° F.). The muscles of the croup and left quarter were swollen and hard, and the subcutaneous connective tissue covering them appeared infiltrated. On passing the catheter about a quart of brownish urine was drawn off.

The body was smartly rubbed, and ten centigrammes of eserine sulphate hypodermically injected, producing several evacuations. The animal was then covered up. It received milk and mashes, to which were added three and a half ounces of bicarbonate of soda. During the evening, in order to quiet it, I further prescribed a hypodermic injection of morphine and chloral enemata.

Next day, and the day following, the animal was several times lifted, but was unable to remain standing; it was therefore placed on a deep bed of straw and turned over morning and evening; food and drink were frequently offered; the urine was drawn off by catheter, and the rectum from time to time emptied. In spite of all our care the symptoms became aggravated. On the evening of the third day great excitement set in; the mucous membranes were cyanosed, the body covered with sweat, the respirations very rapid and embarrassed; the pulse rapid, small, and thready, and the temperature rose to 40·3° C. (104·5° F.). Death occurred during the night.

On *post-mortem* examination you were struck by the change in the muscular tissue. The muscles of the croup, quarter, buttock, and sublumbar region were swollen, discoloured, yellowish, infiltrated, and at points ecchymosed. The longissimus dorsi, pectoral muscles, and the extensors of the forearm showed similar though less marked changes. Both kidneys were slightly enlarged. On section the cortical layer appeared hyperæmic, infiltrated, and hæmorrhagic; the medullary layer, where in contact with the cortex, was injected, but towards the pelvis was of a yellowish tint. The bladder contained a little blackish urine. The nervous centres showed no important lesions, though the spinal cord was slightly congested, especially opposite the commencement of the cauda equina. The intestine was hyperæmic at places; the liver large and the colour of a dead leaf; the spleen swollen, deformed by several rounded enlargements, below which its tissue was softened and hæmorrhagic; the left lung hypostatically congested and infiltrated; the myocardium discoloured and yellowish; the endocardium marked with a few ecchymoses; the blood uncoagulated, blackish, and slightly gummy. But these latter are accessory lesions, and, moreover, inconstant.

Last week you saw an eight-year-old gelding belonging to a market gardener of Maisons-Alfort recover from the same disease. Like the preceding case, this horse had been kept in the stable for two days, and after breakfast on the 27th December was harnessed to draw some vegetables to Paris. The weather was cold, the thermometer marking 6 degrees below zero C. (22° F.). The horse walked from Maisons-Alfort to Alfort, about one and a quarter miles. In passing over Charenton bridge it relaxed its speed, and suddenly went lame on the off hind leg. A little further on it stopped, apparently suffering from slight colic. The driver let it rest for a few minutes, rubbed the abdomen with a wisp of straw, and then as the pain diminished resumed his journey.

Two hundred yards further on the horse fell down. Being immediately taken out of harness it was able to rise. After a few minutes' rest it was brought to the School, where it arrived bathed in sweat, with an anxious appearance about the face, and the off hind limb partially paralysed. It almost immediately passed a little thick, viscous, coffee-coloured urine. Although the body and hind quarters were smartly rubbed, paralysis of the hind limbs quickly increased. The animal lay down, its respiration became rapid and tremulous, the pulse accelerated and strong; temperature 39·1° C. (102·3° F.). Eight centigrammes of eserine sulphate were injected subcutaneously in the neck; the animal was warmly covered up, and given a lukewarm draught containing bicarbonate of soda. During the evening it took some mash, milk, and a little hay. It also received nearly 9½ ounces of bicarbonate of soda.

Next morning we found it in a fairly satisfactory state. There was little excitement, and the face appeared more natural. The respirations were from 16 to 20, the pulse 60 to 70 per minute, temperature 38·9° C. (102° F.). It was turned over twice during the day. As on the previous day, it took a little hay, some milk, and mashes, to which considerable quantities of bicarbonate of soda had been added. The rectum was cleared out, and the urine drawn off.

This treatment was continued for the next two days. The general condition seemed to improve, but the animal was still unable to stand.

On visiting it on the morning of the fourth day it was found able to stand, and was therefore kept up for a few minutes by passing strong bars of wood under the chest, while the body and hind limbs were rubbed. With assistance it was moved into a box and placed in slings.

Improvement followed rapidly, and in a few days the horse was able to leave hospital completely recovered. From the symptoms and lesions just described you will recognise a disease which was at first known under the titles of enzoötic paraplegia, congestion of the cord, then by the names of hæmoglobinæmia, or hæmoglobinuria *a frigore*, the latter distinctions being derived from human medicine, where they were applied to a disease which had some characters in common with hæmoglobinuria of the horse. Küssner called the disease paroxysmal hæmoglobinuria, and Mesnet hæmoglobinuria *a frigore*.

To-day I wish to go beyond a mere sketch of the clinical appearances, and to speak more fully of this disease, which has recently been the subject of interesting researches.

For a long time the conditions in which hæmoglobinuria usually

appears have been recognised. One cause—the action of which is certain—has been indicated by almost all authors, viz. cold. It is scarcely astonishing, then, that cases of hæmoglobinuria should be particularly frequent during the winter, towards the end of autumn, and in spring. Nevertheless it may also be seen at other seasons provided the temperature suddenly falls, or if other causes intervene.

In general the disease is favoured by a plethoric state of body and by rest. It may certainly affect animals in thin or moderate condition which work every day, not even resting on Sundays; but this is rare. It more particularly attacks fat animals kept in ill-ventilated stables, and which have rested for one or more days while receiving their ordinary working rations. Should an animal thus prepared be taken out or worked during cold weather, hæmoglobinuria may suddenly appear. Indeed, it is not even necessary that the animal should be taken out or directly exposed to cold; sudden lowering of temperature in the stable resulting in a chill is sufficient. Some years ago we had a horse affected in this way in stable No. 5. It first showed symptoms of colic, and the real nature of the disease was not recognised until a little later, when dark-coloured urine was passed. Horses of all breeds, classes, and ages are subject to hæmoglobinuria, though it seems particularly to affect heavy animals of plethoric temperament, which consume large quantities of oats, and animals during the most vigorous years of life.

This explains both the appearance of the larger number of cases of hæmoglobinuria during the morning hours when cold is most felt, and the enzoötic character which the disease sometimes appears to assume at times when frost or snow prevent working; large numbers of animals which have been subjected to the same predisposing influences being attacked almost simultaneously, or during the course of a few days. Hæmoglobinuria has even been regarded as an infectious disease, and the animals affected with it thought to have undergone some change of tissue or blood-plasma, tending to prepare the way for the supposed pathogenic agent. Experiments made with the object of verifying this idea have not carried it beyond the stage of an hypothesis. Following many others, I vainly attempted to transmit the disease to horses by injecting under the skin and into the veins and peritoneum defibrinated blood and preparations from the affected organs. The disease is not contagious, and cannot pass from affected to healthy animals. In the rare cases where contagion or external infection have been suspected, the patients which had been simultaneously or successively affected had also been under the same conditions of feeding, treatment, and work.

The symptomatology of hæmoglobinuria is somewhat complex, and this diversity in its clinical appearances has naturally given rise to equal divergence of opinion as to the nature of the disease. Nevertheless certain highly significant signs are never absent.

Let us first consider its general characters. As I have said, the disease usually appears during work. Invasion is sudden. At first the animal is more lively than usual in proportion to the length of the preceding rest, but suddenly becomes uneasy, and exhibits visibly increasing anxiety or colicky pains; its pace slackens; rigors, trembling, and localised or general sweating occur; respiration is quickened, sometimes groaning, or rather oppressed; the face appears anxious, the nostrils dilated, the eye brilliant; at this time, or very soon after, movement becomes difficult. In most cases these primary symptoms occur ten minutes or a quarter of an hour after the animal quits the stable; in others at the end of a quarter of an hour to one hour, sometimes even later. When the animal is attacked in the stable or while being harnessed, symptoms of excitement, stamping, rapid movement of the flank, and anxiety, followed by sweating, are noted. When the animal is started or walked about in order to ease the colic from which it is supposed to be suffering, it moves with difficulty, as in the preceding case.

The interference with movement, one of the two chief symptoms of the disease, is variable in form, localisation, and intensity. Sometimes it appears as generalised or localised stiffness in the hind quarters, like that due to muscular rheumatism; sometimes it resembles paralysis, usually limited to the hind quarters; the hind legs seem paralysed, yield under the body-weight, and are only moved with great difficulty, the toe being dragged or the fetlock even coming in contact with the ground. In a number of cases the hind limbs are unequally affected, or only one may be attacked. Some authors claim to have noted that the left hind limb is more often the seat of disease than the right. This, however, is only accidental: of eighteen cases of paralysis of a single hind limb which I examined, ten were of the right and eight of the left side. Sometimes, but much more rarely, one or both of the fore-limbs may be affected. The muscles neighbouring or antagonistic to those paralysed may show contraction. To such contraction is due the rigidity of the neck, the stiffness and lifting of the tail, and the painful tension in certain muscles of the abdomen and limbs.

Symptoms of paresis, however, predominate, and sometimes increase with alarming rapidity. When the hind quarters are affected paraplegia soon becomes more or less complete; the animals are unable to stand, appear excited, and vainly struggle to rise.

In the great majority of cases this failure of motor power, whether or neuropathic or myopathic origin, is accompanied by multiple localised inflammation of muscle, evidenced by circumscribed or diffuse swellings. In some a large portion of the muscular system is affected; in most the myositis is local, affecting either superficial or deep-seated muscles. No region is exempt, though change is most frequent in the muscular tissues of the croup, quarters, buttocks, lumbar region, back, shoulders, neck, and chest. The appearances are as follows:—Swelling of variable extent and size, produced by tumefaction of the muscles, which are felt to be dense, hard, painful, tense, and sometimes a little œdematous; the skin covering them is warm, sensitive, and adherent; sensation gradually diminishes, but complete anæsthesia is rare. These localised inflammations may persist and become accentuated, may gradually diminish and disappear without leaving traces, or may be followed by degenerative changes, producing atrophy of certain of the affected muscles.

The second chief symptom of hæmoglobinuria is melanuria—blackish or very deep coloration of the urine,—a change due to the presence of a certain quantity of hæmoglobin and of methæmoglobin. This symptom, which is almost always constant, corresponds in intensity with that of the disease itself. The urine may exhibit an entire series of intermediate tints between light red and black. Most frequently the first urine passed is brownish or black, like liquid manure, and in fatal cases remains in this condition; in others it gradually becomes lighter. This urine contains a varying quantity of hæmoglobin, and an excess of urea and various other metabolic products. It also shows a considerable proportion of albumen (as high as three drachms to the pint), desquamated epithelial cells, leucocytes, red blood-corpuscles, cylindrical casts, and sometimes a little glucose. It retains the normal alkaline reaction, though this becomes less when the kidneys are diseased. As long as the patient can stand, micturition occurs easily, but when the patient is lying helpless it is generally suppressed.

The changes occurring in other bodily organs are less important. I have mentioned colic, with or without the passage of soft fæces, which occurs at the outset; at a later stage the peristaltic action of the bowel diminishes in frequence and power; constipation may exist; defecation is suspended; the appetite is usually moderate, but thirst excessive. The respiration, which is more or less accelerated during the first minutes of the attack, soon becomes rapid, panting, and in most cases oppressed; in animals which struggle violently it may rise to 60 or 80 per minute. The circulation is sometimes comparatively

little disturbed, but struggling causes a steady rise in the pulse; the latter is at first full and strong, but later becomes feeble, and in cases almost imperceptible. The mucous membranes, particularly the conjunctivæ, are injected and purplish. In many patients the temperature remains normal, or only rises a few tenths of a degree; in twenty out of twenty-five cases Friedberger and Fröhner found no fever whatever. Nevertheless the temperature may rise considerably, sometimes more than 2° C. You must understand that the absence of fever in no way justifies one in regarding the disease as benign; very grave cases, indeed, may remain absolutely without fever.

Apart from the loss of power in the hind limbs and the local contractions mentioned, other nervous symptoms occur, including paralysis of the tail, rectum, and bladder. When the kidneys become gravely affected, and no longer perform their function of purifying the blood, symptoms of uræmia appear. The most striking are epileptiform convulsions, attacks of dyspnœa, and generalised cramp, alternating with periods of coma, and later, profound depression of the bodily forces and gradual sinking of temperature.

To this summary of the symptoms which may appear at various stages of hæmoglobinuria I wish to add a few words regarding the two principal clinical divisions of the disease. Considered from the point of view of its development, course, and terminations, we recognise (1) a rapidly progressive form, accompanied by paralytic symptoms; and (2) a benign form, in which the disease process quickly subsides without producing paralysis.

In the paralytic form, which is most common, paralysis of a limb, or of both hind quarters, may be noted within ten minutes, a quarter of an hour, or half an hour after the appearance of the first symptoms. Patients with paraplegia fall to the ground in spite of all their efforts to remain standing, and on attempting to rise are only able to lift the fore-parts of the body; the hind parts remain powerless. During the first few hours they show signs of excessive excitement; the skin is damp with sweat, and steams; the respiration is rapid and panting, the pulse frequent and strong, the conjunctiva purplish. Sometimes these symptoms persist; sometimes they gradually diminish in intensity; a quiet period occurs, the sweating ceases, the breathing and circulation are less rapid; everything points to real improvement.

When the issue is likely to prove favourable this calm period continues, and in from twenty-four hours to six or eight days—usually on the second to the fifth day—recovery takes place. Sometimes it occurs as suddenly as the attack. A patient which the evening before was lying helpless is next morning found standing at the manger.

The most frequent after-complications are bedsores, areas of dry gangrene over the most prominent portions of the body, consequent on the animal remaining too long in one position, and localised atrophy of certain groups of muscles, particularly of the crural muscles, consequent on myositis or neuritis. Sometimes the hind limbs show a kind of paresis due to myelitis or to spinal meningitis.

When the end is likely to prove fatal, the grave earlier phenomena persist with but slight and short remissions, or the improvement is soon followed by a return of the symptoms, which are prolonged until death occurs. The latter is produced either by slow asphyxia, consequent on pulmonary congestion, or by uræmia or cardiac syncope. In some cases the course is very rapid, the symptoms extremely alarming from the first; the animal struggles violently, the chief functions are greatly accelerated, the respiration especially being hurried and accompanied by frequent groaning; the mucous membranes become purple and the limbs cold. Before the end of the first day—sometimes after a few hours—death occurs during a violent attack of struggling, or preceded only by a few convulsions. Some years ago we saw these symptoms of acute hæmoglobinuria in a patient which died in ten hours.

The benign form, with or without myositis, is characterised only by trifling general disturbance and more or less marked difficulty in movement; the gait is stiff, awkward, and painful; the limbs are momentarily flexed; one or another sometimes shows temporary lameness. These symptoms very rapidly diminish and disappear. Resolution is generally announced by the passage of dark urine. Sometimes the urine is scarcely red in colour, or may even appear normal.

After recovery a predisposition to fresh attacks remains. In this respect hæmoglobinuria resembles rheumatic affections. One animal may undergo several attacks during a few weeks. M. Lucet mentions a horse which had three, separated by intervals of ten and five days. This recurring character has procured for the disease the name of periodic or intermittent hæmoglobinuria.

XXXV.—HÆMOGLOBINURIA (AZOTURIA) IN THE HORSE (CONCLUSION).

The most constant and important anatomical changes in hæmoglobinuria are to be found in the blood and muscles.

As a rule the blood is not coagulated, or is diffluent, blackish, and gummy. Even during life it appears to have undergone change; withdrawn from the jugular vein into a suitable vessel it usually coagulates slowly: sometimes the serum is reddish in colour, due to a certain amount of dissolved hæmoglobin; sometimes it contains crystals of hæmatoidin. Chemical analysis reveals a high proportion of urea and other metabolic products; the alkalinity is diminished. On microscopic examination most of the red blood-corpuscles show the usual physiological characters, but some are changed, deformed, and irregular.

The majority of the muscles affected with myositis are swollen, pale, whitish, or yellowish white, and more or less infiltrated with serum; those recently affected are hyperæmic. Incisions made parallel with the fibres demonstrate the existence of blood effusions or of ecchymoses. These lesions, regarded by some authors as primary and by others as secondary, are, as I have mentioned, specially marked in the muscles of the hind quarters. As described by M. Arloing in 1866, the muscular fibres show, on microscopic examination, the changes peculiar to acute degenerative myositis—cloudy swelling, loss of or diminution in the clearness of their striation, fragmentation of the fibres, hyaline or granulo-fatty degeneration; the interstitial tissue often contains masses of red blood-corpuscles. In most cases the kidneys seem affected with parenchymatous nephritis; they are large, hyperæmic, and ecchymosed; on section the cortical substance appears moderately congested, marked with hæmorrhagic streaks and points; the medullary substance is reddish yellow, and more or less infiltrated. These lesions, however, are sometimes far from pronounced. Under the microscope a granular exudate is seen in the glomeruli and uriniferous tubules; sometimes the epithelium of the convoluted tubes is much infiltrated with pigment. Without being absolutely constant,

congestive and hæmorrhagic lesions in the nervous centres, particularly in the lumbar portion of the cord and in certain nerves, notably the femorals, are rarely absent. In addition I should mention the congestive lesions in certain portions of the intestinal mucous membrane, the swelling and hæmorrhages in the spleen, the fatty degeneration of the liver and other glands, and the hyperæmia of most of the viscera and of the bone marrow.

These appearances are in great part consequent on changes in the blood, and on the uræmia which complicates prolonged cases.

The pathogeny of hæmoglobinuria is variously interpreted. The most recent work published on this question does not appear to have in any appreciable degree advanced it.

In the nervous or medullary theory, accepted by many writers and remarkably well described by M. Trasbot in the *Archives Vétérinaires*, the symptoms noted are referred to congestion of the spinal cord or to myelitis. Unquestionably the cord often shows hyperæmic and hæmorrhagic changes, but it may well be asked whether these are not due to the same causes as the secondary changes in the viscera; many persons maintain that they are not constant, and certainly they explain neither hæmoglobinæmia nor hæmoglobinuria. In two *post-mortem* examinations made during the last few years the cord appeared to me unchanged on naked-eye examination, and the microscope showed no important lesions.*

Authors have at various times traced the disease to congestion of the kidneys or to nephritis. The waste products usually excreted by the kidneys are said to produce general intoxication, changes in the blood-corpuscles, inflammation of muscle, and the train of symptoms which successively appear. M. Lucet, who regards hæmoglobinuria as a disease of renal origin, refers the benign cases to an ephemeral but excessively acute nephritis. But renal changes appear to be always secondary, consecutive to changes in the blood. Lesions in the epithelial cells lining the renal tubules, like enlargement and pigmentation, are said to be caused by the elimination through the kidney of products resulting from destruction of red blood-corpuscles, or the transformation of hæmoglobin. Experiments carried out in company with M. Roger have satisfied me that urinary intoxication produced by injecting fresh filtered urine into the horse's jugular produces none of the symptoms

* In his treatise on nervous affections in the horse, just published, Dexler regards hæmoglobinuria as a disease of the cord. He states that the dominant symptoms are those of a medullary affection, and he claims to have found in the anterior horns of the lumbar portion of the cord lesions which explain these symptoms.

of hæmoglobinuria. We likewise found that blood-serum from horses affected with this disease had no special effect in destroying formed blood elements. Injected into the veins of the rabbit, it did not seem more distinctly toxic than normal serum.

The theory that hæmoglobinuria is an infectious disease is not new. In France it was advocated by M. Signol, and particularly by M. Arloing. It better accounts for the phenomena occurring during the course of the affection than any other. These are said to result from auto-infection or auto-intoxication, due either to a ferment present in the food or to the abundant formation of metabolic products under the double influence of cold and movement in animals predisposed by long rest in the stable. It is to-day generally allowed that the cause, whatever it may be, produces change in the red blood-corpuscles, destruction of a greater or smaller number, with solution of their hæmoglobin in the blood-plasma, thus setting up hæmoglobinuria, from which all the other lesions are said to be derived. Against this theory it is urged that the disease behaves in no wise like an infectious process, that it is not contagious, that all attempts at transmission have failed, that blood removed aseptically during life does not always give a coloured or red serum; finally, that the metabolic products which, on the theory of auto-intoxication, should exist in large quantities in the blood, are at times only met with in normal proportion. However this may be, the disease certainly offers some resemblance to an infectious process, and it would not be surprising if one day this view of its pathology were bacteriologically confirmed. What was known fifteen years ago regarding the pathogeny of tetanus? that toxi-infectious disease which can never be transmitted, so to speak, directly, and the development of which, like that of hæmoglobinuria, is so favoured by cold.

The muscular or rheumatismal theory supported by Fröhner compares hæmoglobinuria of the horse with paroxysmal hæmoglobinuria *a frigore* in man. The principal cause of the equine disease is said to be the action of cold; the essential and primary change degeneration in certain muscles, the colouring material of which is liberated, and together with other substances passes into the blood, accumulates there, produces secondary lesions in the internal organs, and is then eliminated by various emunctories, especially by the kidney, whence the deep coloration of the urine and the nephritis. The partisans of this theory lay stress on the fact that grave lesions almost always exist in several groups of muscle, that the sudden action of cold is capable of rapidly producing change and discoloration of muscle; finally, that the blood of animals affected with hæmoglobinuria contains an excessive propor-

tion of hæmoglobin which might originate from the colouring material of the altered muscles.

The results following attempts to produce experimental hæmoglobinuria in no way favour the renal theory. Hæmoglobinæmia, with or without hæmoglobinuria, may be produced by introducing into the blood substances which cause destruction of a greater or less number of red blood-corpuscles, and thus set at liberty varying quantities of hæmoglobin, capable of conversion into methæmoglobin and many other still unknown metabolic products. If few red blood-corpuscles are destroyed, slight hæmoglobinæmia without hæmoglobinuria is produced: hæmoglobin is soon broken up by the liver, spleen, and bone marrow. The same result follows, even though destruction is more abundant, provided it occurs gradually; neither hæmoglobinuria nor visible changes in the kidneys are seen. On the contrary, if it is abundant and rapid, hæmoglobinuria appears, and the kidneys undergo more or less grave change. Hæmoglobinæmia, hæmoglobinuria, and disease of the kidney constitute the three stages of hæmoglobinuria experimentally produced. Spontaneous hæmoglobinuria is very probably marked by similar stages. What remains to be discovered is the cause or agent which in the spontaneous form sets at liberty the hæmoglobin.

The conditions under which the disease appears, the sudden invasion, preliminary colicky pains, and the multiplicity of organs almost immediately affected, suggest that it results from toxic infection of intestinal origin, of which the hæmoglobinæmia, hæmoglobinuria, and the changes in muscle and in the spinal cord are only the principal manifestations. Not only does the intestine present a vast cavity for the growth of pathogenic microbes; it is also a centre of manufacture for toxins. Overfeeding of horses while idle favours the production of intestinal poisons; and it is known that when associated, otherwise relatively harmless germs, like the *Bacillus coli communis*, the paracoli bacilli, and the streptococci, may produce deadly toxins. In processes of this nature intoxication may play an even more important part than infection.*

The diagnosis of hæmoglobinuria is usually easy. Nevertheless benign cases may at first be mistaken either for intestinal colic or for muscular rheumatism. Others, where the animal is lying down when examined, may suggest traumatic paraplegia or fracture of the vertebral

* M. Lignières found streptococci in the cerebro-spinal fluid of horses dead of hæmoglobinuria. This discovery, however, only shows that streptococci, without doubt originating in the intestine, had entered the blood-stream. It remains to be proved that this was not a case of organisms entering the circulation during the death agony.

column; but the history and red coloration of the urine remove any possible doubt. The atrophy of muscle afterwards seen in different regions, most frequently in the triceps cruralis muscle, can always be traced to hæmoglobinuria. The majority of other changes are of similar origin. In their case also the history constitutes a valuable indication. A few weeks ago you saw a case of atrophy of the extensor muscles of the right forearm. The history enabled us to trace this lesion to an attack of hæmoglobinuria which the animal underwent last winter.

The prognosis varies considerably according to the degree of acuteness of the disease, the localities it affects, and the constitution of the patients. Statistics show the mortality to vary between 5 and 70 per cent. Plethoric horses which eat large quantities of grain, and particularly of oats, are much more liable to die than animals accustomed to moderate feeding. This seems to me to explain the marked gravity of hæmoglobinuria in town horses, and the series of recoveries reported by veterinary surgeons who practise in country districts. It is also clear that certain authors have mistaken infectious forms of paraplegia which are seen in all countries, and everywhere cause heavy mortality, for hæmoglobinuric paralysis. Benign character of the first symptoms, slow development of the disease, preservation of the standing position, normal or but slightly modified rhythm of the chief functions of the body, and continuance of the evacuations, are signs justifying a favourable prognosis. On the other hand, sudden invasion, marked acceleration of breathing, abundant sweating, high fever, paraplegia, and cessation of the evacuations, leave little ground for hope. I should add that in some cases the disease develops insidiously, and that though at first benign it may at any moment be accompanied by paralysis. For this reason a certain reserve should be exercised in speaking of cases which even appear likely to recover. Prognosis is always unfavourable in cases affected with paraplegia. When this persists beyond the third day the issue is generally fatal.

Prophylaxis is founded on our knowledge of the ætiology. Avoid, as far as possible, leaving horses too long in the stable; exercise them for at least a few minutes night and morning on resting days; always proportion food to the work to be done; reduce the rations during rest, improve the animal's hygienic surroundings, paying especial attention to securing uniform temperature, sudden changes in which may have particularly injurious effects.

I have said that the disease generally appears during work, and is rapidly aggravated by attempts to draw a load even at a walking pace.

As soon, therefore, as the animal is seen to be ill it should be stopped, taken out of the shafts, and removed to a neighbouring stable, or placed in an ambulance and taken home. Arrived there it can be placed in a box, where it should be kept warm and quiet. Animals do better if able to stand, for which reason slinging may prove useful. If, however, the patient is totally incapable of standing even with slings, it should be given a thick bed of straw.

The present uncertainty regarding the nature of hæmoglobinuria renders treatment hesitating. As in all diseases in which the essential cause is unknown, a large number of methods and innumerable drugs have been recommended. Many are only injurious, but some are of real value. While combating the more marked disease symptoms, the general line of treatment should resemble that prescribed against toxic infections.

In the grave form—especially when dyspnœa is marked—bleeding may be practised, seven to fourteen pints of blood being removed according to the animal's size. This constitutes a first method of removing the poisons, microbic or cellular. Whether disease be trifling or severe, attempts should be made to secure an action of the bowels by administering a hypodermic injection of 2 to 4 centigrammes of hydrobromate of arecolin, 5 to 10 centigrammes of sulphate of eserine, or 10 to 20 centigrammes of hydrochlorate of pilocarpine. The body and limbs can afterwards be briskly rubbed with flannel or with straw wisps. If necessary the hypodermic injection can be repeated on the following days.

Lafosse, Colin (de Vassy), Jouquan, and some other veterinarians have recommended continuous refrigeration of the dorso-lumbar region by irrigation, or by applying wet cloths frequently moistened with cold water. This is one method of treating the myositis and congestion of the spinal cord.

Sometimes excitement is severe. The animal struggles violently, is covered with sweat, and the body is severely bruised by striking against the ground. This excessive excitement should be combated by narcotics and anæsthetics. If water is readily taken, laudanum should be added to it ; but if refused, morphine should be subcutaneously injected, or chloral given in a ball. The animal must be frequently turned over and provided with a good bed, both to prevent hypostatic congestion and the formation of bedsores on prominent parts of the body.

When appetite is preserved, or when it returns, the animal should be supported on gruel and milk. It may also be given green food, hay, and a small quantity of oats.

In addition to the alkaloids already mentioned, internal medication

comprises administration of purgatives and alkaline salts. Having succeeded at the outset in producing one abundant evacuation, the action of the bowel can be sustained by repeated doses of sulphate of soda. The fact that the alkalinity of the blood is generally diminished, as in infectious conditions, and in the various processes which lead to destruction of the formed elements of the blood, suggests the use of alkalies. Dickerhoff recommended bicarbonate of soda in daily doses of six to sixteen ounces, divided into several parts and given in the drinking-water; this dose was afterwards diminished to three or four ounces. The remedy is simple, cheap, and readily taken by patients, while it undoubtedly has a favourable effect. By rendering the fluids alkaline it increases their bactericidal and antitoxic powers, and by restoring to them what the infection had removed, it assists elimination of toxins, and fortifies the red blood-corpuscles.*

Stimulants are now almost abandoned, their action having been found to be highly injurious. Alteratives have no value.

When the animal remains recumbent for long periods it must not only be repeatedly turned over, but the rectum and bladder must be emptied. Needless to say, in passing the catheter full antiseptic precautions must be taken to avoid infecting the bladder.

During convalescence alkalies should still be continued even after the administration of tonics has been commenced.

Bedsores are treated with antiseptic lotions containing sublimate, carbolic acid, or iodine, and with applications of boric ointment.

Soon after convalescence is established the animals may return to light work, being guarded, however, against chills which might lead to relapse, and be very gradually brought into their usual work.

The muscular lesions seen after attacks of hæmoglobinuria seldom prove permanent. The affected muscles sometimes recover their normal size and strength under the influence of work. Should atrophy become more marked, however, the parts may be fired, or irritant solutions like those of veratrine or chloride of sodium injected over the affected region. The faradic current is worthy of trial.

The painful and obstinate lameness which follows paralysis of the triceps cruralis, and forms the commonest complication, may necessitate firing of the parts and continued exercise. By persevering in this way the muscle usually regains its power and the lameness disappears.

* M. Masoin found that alkaline salts exercise a prophylactic action against intoxications caused by substances which tend to destroy formed blood elements, and produce formation of methæmoglobin. At the same time they exercise a general antitoxic action. Their use is therefore indicated, not only in the curative treatment of hæmoglobinuria, but in its prophylaxis in conjunction with other preventive measures, the value of which has been recognised by observation.

XXXVI.—DIABETES MELLITUS IN THE DOG.

Among dogs brought for advice or left in hospital during the past few months you have seen several diabetic patients; one affected with diabetes mellitus, the others with simple polyuria or diabetes insipidus. While the second form is usually benign, the other—diabetes mellitus—is a grave affection, which almost always proves rapidly fatal. Up to the present time it has been but little studied in animals. I have chosen it as the subject of to-day's lecture.

Mentioned by Leblanc in the *Clinique Vétérinaire* for 1861, and seen in most of the domestic animals, including both ruminants and carnivoræ, diabetes mellitus is unquestionably a rare disease, though the chief reason that veterinary publications contain so few recorded cases is less connected with the rarity of the disease than with the fact that examination of the urine is habitually neglected, and hence the disease escapes observation. During the past few years the recorded cases of diabetes mellitus in the dog have increased. Fröhner at the Veterinary School of Berlin, and Schindelka at that of Vienna, have noticed several. Eber, who was specially entrusted with the clinique for small animals at the Berlin School, has made researches on the frequence of diabetes mellitus in the dog. Within two years about 20,000 patients were brought for examination or treated in the hospital, among which Eber noted twelve grave cases marked by well-defined clinical symptoms, that is about one diabetic patient among 2000 animals. The disease is, however, certainly more common than these statistics would seem to indicate; trifling and recent or obscure attacks of diabetes, unaccompanied by very evident disturbance, either fail to attract attention or remain unrecognised.

I will shortly describe our last case of this kind.

During the first week of May a person living in the Avenue Kleber, at Paris, brought a five-year-old bitch which had been ill for three months. Although she regularly ate her food with good appetite this bitch was distinctly thin. She drank often and copiously, sometimes vomited after having lapped a large quantity of water; and finally she

micturated frequently and in large quantities. M. Almy examined her carefully, and finding no signs of any organic disease which would explain the symptoms, suspected diabetes. The urine was analysed by M. Lesage, and found to contain 6·25 grammes of sugar per 100. The owner refused to leave the patient in hospital. As often happens, the special interest we showed in her aroused the suspicions of the owner, who feared that his animal would be made the subject of experiment.

I will give a summary of the cases published by Eber in 1897 in the *Monatshefte für Thierheilkunde.*

CASE 1.—A seven and a half-year-old water-spaniel. For six months had suffered from disturbance of vision, marked thirst, and excessive appetite.

Condition on Examination.—Moderately nourished; conjunctiva rose-red; pulse regular, of normal force, eighty per minute; respiration normal; appetite good; abdomen swollen over the hypochondriac region; margins of the liver perceptible two finger-breadths from the last ribs; double cataract; temperature 38·8° C (101·8° F.); polyuria; urine light yellow, pale, exhaling an odour of acetone, acid; specific gravity 1·042; contained 7 per cent. of glucose.

Treatment.—Meat diet. Three small doses of tincture of valerian daily. Died on the sixth day in a state of collapse.

CASE 2.—Cross-bred nine-year-old water-spaniel. Same history as the first patient.

Condition on Examination.—Very marked wasting; both lenses opalescent; margin of the liver perceptible behind the costal cartilages; urine pale yellow, acid; specific gravity 1·040; contained 6·5 per cent. of glucose.

Returned a month later. Despite careful dieting wasting had increased; urine contained 7 per cent. of glucose.

CASE 3.—Eleven-year-old Basset hound. Same history as in the preceding cases.

Condition on Examination.—Wasting; opalescence of both lenses; enlarged liver; urine clear, pale yellow, acid; specific gravity 1·036; contained 7 per cent. of glucose. Patient was not afterwards seen.

CASE 4.—Ten-year-old Basset bitch. Severe thirst. Three weeks ago both lenses became opalescent.

Condition on Examination.—Moderately well nourished; double

cataract; liver enlarged; urine light yellow, transparent, acid; density 1·036; contained 8 per cent. of glucose.

CASE 5.—Nine-year-old poodle. Usual history.

Condition on Examination.—Somewhat frequent coughing; chronic bronchitis; double cataract; no enlargement of the liver; urine cloudy, clay-coloured, bearing in suspension little yellowish-grey flocculi; specific gravity 1·024, acid, contained a little albumen; no bile pigments; 2·6 per cent. of glucose. On microscopic examination of the urine numerous epithelial cells, a few very granular cylindrical casts, some red blood-corpuscles, and leucocytes were discovered.

Case was not afterwards seen.

CASE 6.—Ten-year-old pug. Left in hospital. No history. Enlarged liver and cataract. The urine contained a large proportion of glucose. No quantitative analysis made.

CASE 7.—Twelve-year-old water-spaniel. Usual history. Blindness had been complete for a week.

Condition on Examination.—Bilateral cataract; lenses of a yellowish colour; liver enlarged; deafness; impaired sense of smell; urine pale yellow, acid, specific gravity 1·042; contained 2·5 per cent. of glucose.

Treatment.—Careful diet and administration of bicarbonate of soda.

Brought back four months later to be operated on for cataract. At this date the urine was albuminous, but only contained traces of sugar; heart normal. After operation on one eye the animal fell into a comatose condition, and died four days later.

CASE 8.—Nine-year-old pug. Polyuria; excessive thirst; wasting; vision impaired for the past six weeks.

Condition on Examination.—Opacity of both lenses; enlargement of the abdomen, resembling abdominal dropsy. The liver extended more than a hand's breadth beyond the last ribs; weakness and wasting; urine light yellow, slightly albuminous, slightly acid, specific gravity 1·031; contained 9·4 per cent. of glucose.

CASE 9.—Nine-year-old terrier. Usual history.

General Condition.—Badly nourished; diffuse cloudiness of both lenses; enlarged liver; urine straw-coloured, slightly turbid, and acid, density 1·039; contained a little albumen and mucin in addition to 8 per cent. of glucose.

CASE 10.—Six-year-old pug. Had fallen away in condition, and exhibited cough for a month. Appetite great and thirst acute. No disturbance of vision.

General condition bad. Slight diffuse cloudiness of both lenses; liver enlarged; urine light yellow, acid, with an intense smell of acetone, density 1·044, contained 7 per cent. of glucose; saliva alkaline; little albumen.

CASE 11.—Twelve-year-old Pomeranian bitch. For the previous four months had appeared depressed and tired; appetite had fallen off during the last few days; thirst very severe; polyuria; animal's skin exhaled a fœtid smell. No visual disturbance. Moderately nourished. Trifling opacity of both lenses. The liver was not swollen; urine pale, transparent, acid, and gave off an intense odour of acetone, density 1·033, contained traces of albumen, and 8 per cent. of glucose; saliva alkaline.

CASE 12.—Eight-year-old Basset bitch. Intense thirst; polyuria and general wasting. Appetite nevertheless good.

Condition on Examination.—Slight opacity of both lenses; wasting; enormous enlargement of the liver; urine clear, slightly yellowish, inodorous, alkaline, density 1·028, contained traces of albumen and 5 per cent. of glucose; saliva alkaline.

In five diabetic patients examined after death, Eber found degenerative changes in the liver. In one the pancreas was atrophied; in three it showed a few greyish nodules, the nature of which was not determined.

In man, in whom the ætiology of diabetes has been carefully studied, the principal causes are said to be improper or excessive food, abuse of sugary and starchy materials, sedentary life or insufficient physical exercise, gout; finally, advanced age. The disease is oftenest seen between thirty and seventy years of age, but may also occur before maturity, during adolescence, or even in infancy.

In the dog diabetes is almost always confined to animals of fairly advanced age. It is exceptional during the first half of life. Of Eber's twelve patients, nine were more than eight years old. The influence of special conditions of life is at least as marked as that of age. Almost all cases are in animals freely fed, leading idle lives, or in pampered pet dogs. Many of these are very affectionate and greatly attached to their owners; they become dull, ill-tempered, and

snappish, and although the history always fails to record the fact, it may be that excitement and emotional disturbance play a certain part in developing the disease. M. Gibier succeeded in producing transitory glycosuria in a bitch by means of psychic excitation. This bitch, which was four years old, and of a very affectionate, nervous, and jealous disposition, lived free in the laboratory with other animals of its own species. Its urine, examined for a period of several days, gave no reaction. Shut up in a cage the bitch appeared greatly excited. The urine retained its normal character for three days, but on the fourth contained 5·55 grammes of sugar per litre. The glycosuria persisted during the entire period the animal was shut up, but disappeared the day after she was set at liberty. Sex appears to have no influence in the ætiology; cases are as numerous in males as in females. Among Eber's twelve patients were six dogs and six bitches.

Diabetes in the dog at first develops insidiously, and for a considerable period may produce no marked disturbance. In a number of cases it exists for months before attracting attention. As in our patient, the disease is not remarked until the three principal symptoms, polyuria, polydipsia (excessive thirst), and wasting, are all developed.

Micturition is frequent and abundant. Certain patients pass one or even two quarts of urine per day. Pet dogs which become diabetic are greatly inconvenienced, and micturate on the carpets or cushions of the rooms where they are confined. The urine is usually limpid, pale, or light yellow, not infrequently albuminous, occasionally slightly turbid, of an average specific gravity of 1·030 to 1·040. It sometimes contains as much as 10 per cent. of sugar. In a twelve-year-old bitch seen by Penberthy the proportion was 10·62 per cent. As soon as the urine contains from 3 to 4 grammes of glucose per litre it acquires a sweetish, sugary taste.

Another important symptom is the insatiable thirst which troubles the patients. As a consequence of the polyuria thirst is constant, though more marked at certain times than at others, being especially acute during the night. The mouth is dry, and the saliva tends to become acid, so that the gums are often inflamed, and the buccal cavity exhales a disagreeable smell.

To the polyuria and polydipsia—the two principal symptoms of diabetes—are added weakness and wasting, which usually become rapidly aggravated. Without being absolutely constant, emaciation is common, sometimes appears early, and is the more striking inasmuch as appetite is preserved, or may even be excessive. Of Eber's twelve patients ten showed rapid wasting. Enlargement of the liver is

also noted in almost all cases. Usually very marked, it produces deformity of the abdomen almost simulating ascites, a condition from which it is differentiated by palpation. Some subjects show digestive disturbance, particularly vomiting and constipation, alternating with attacks of diarrhœa.

Cutaneous complications like erythema, furunculosis, or gangrene are occasionally seen, as are diseases of the respiratory passages, bronchitis, or pneumonia with a tendency to gangrene and tuberculosis. They are, however, distinctly rare. Disease of the eye, on the other hand, is very frequent. Three fourths of the dogs affected with diabetes suffer during the course of the disease from bilateral cataract, which often produces complete blindness in a few weeks. Deafness, loss of smell, paralysis, and comatose or apoplectiform attacks may also occur.

In diabetic dogs examined after death changes have been found in the liver and pancreas. In most cases the liver was greatly enlarged, hyperæmic, and undergoing fatty degeneration; in some cirrhosis was also seen, but the seat of the sclerosing process has not been clearly described; in a few cases mention has been made of atrophic changes in the pancreas. At the *post-mortem* examination of a bitch affected with wasting diabetes, Liénaux found the liver undergoing fatty degeneration, and the pancreas atrophied. The bitch examined by Penberthy showed similar lesions of the liver and pancreas.

I shall only say a few words on the pathogeny of diabetes. During the course of the present century, but especially after the discoveries of Bernard, and more particularly during the last twenty years, this question has greatly interested savants and experimenters. For a long time the conditions necessary to the appearance of sugar in the urine have been known. Being indispensable to nutrition, sugar exists normally in the blood and tissues. The arterial blood of the dog contains about 1·30 grammes, and the venous blood about 90 centigrammes per one thousand grammes. Manufactured by the liver at the expense of its glycogen, the sugar found in the blood is variously utilised by the organism: one portion is burned up, another is assimilated by the tissues. In health the proportion remains practically the same, but this physiological condition may be disturbed, either by excessive production of sugar, or by diminution in its consumption by the tissues: in either case hyperglycæmia exists, the necessary precedent to the appearance of sugar in the urine—*i. e.* glycosuria. The latter condition occurs as soon as the blood contains more than 3 grammes

of sugar per thousand; in certain diabetic patients the proportion rises to 5 or 6 per thousand. But an animal whose urine contains sugar is not necessarily a diabetic subject. The temporary presence of sugar in the urine—transitory glycosuria—is, in fact, a symptom common to various morbid states, to certain brain diseases, to auto-intoxications and infections. What particularly characterises diabetes is the constancy or permanency of the condition. Temporary glycosuria or diabetes can be experimentally produced by injuring the floor of the fourth ventricle below the origin of the pneumogastrics, by administration of various chemical substances, and by extirpation of the pancreas.

I shall not trouble you with the theories of diabetes. At the present time they number almost thirty. The majority are based on supposed disturbance in the glycogenic function of the liver, or on failure of the tissues to destroy the sugar present in the blood, due to disturbance in assimilation. M. Bouchard regards diabetes as a disease due to retarded nutrition. It results from nutritive disturbance primarily characterised by failure or partial inability of tissue elements to consume the sugar. MM. Chauveau and Kaufmann consider that variations in the proportion of sugar contained in the blood depend rather on hepatic production than on disturbance in consumption, and that production of sugar by the liver is regulated by the nervous system, the pancreas exercising a kind of retarding function and moderating the activity of the hepatic cells.

According to the rapidity of its development diabetes is described either as acute or chronic. Other forms have been distinguished, depending on whether the patients preserve their condition or undergo wasting. Some authors refer wasting diabetes to lesions of the pancreas, but in the dog it appears only to be an advanced stage of the first form; wasting, in fact, is always very marked, though lesions of the pancreas are rare. We also recognise traumatic diabetes, most frequently a result of injury to the cranium.

The progress of diabetes mellitus in the dog is usually rapid. Some patients may live for several months; under appropriate treatment the glycosuria diminishes, but improvement is only temporary. Sooner or later the symptoms become suddenly aggravated, and most animals die in a state of coma.

Diabetes in the dog is very apt to escape diagnosis. It may be suspected from the history, from one or other of the principal symptoms, such as the excessive urination, thirst, and appetite; and in certain cases also from the clinical signs—wasting, cataract formation,

and enlargement of the liver. Detection of sugar in the urine confirms the diagnosis. Fehling's solution, prepared so that one cubic centimetre is reduced by 5 grammes of glucose, forms an easy and rapid means of discovering glycosuria. You know the method of employing it; 3 or 4 cubic centimetres of the solution are poured into a test-tube and brought to boiling-point (it should remain blue and perfectly limpid); the urine is afterwards filtered and slowly added, being allowed to run down the side of the tube so as to form a separate layer above the solution. If it contains a considerable quantity of sugar the surface of contact will first show a greenish layer, which successively becomes yellow and red. In performing quantitative analysis it should be borne in mind that the urine of diabetic dogs contains a variable proportion of uric acid, and of other little known bodies which, like sugar, reduce Fehling's solution.

The cure of saccharine diabetes in the dog is undoubtedly possible, but up to the present no case has been reported. All the patients have died, the majority in a very short time. The cases said to have been cured really refer to diabetes insipidus.

In slight or recent attacks treatment may prolong life for a varying time. The animals should not be excited. The majority should not be taken into hospital, or separated from their owners. The food should be free of starchy and sugary materials, and is best confined principally to meat, light soup containing green vegetables or cabbage, milk, and combinations of these foods. The animal should be allowed whatever liquid it requires. Exercise must be given, but fatigue avoided.

Medical treatment comprises alkalies, particularly bicarbonate of soda, and when wasting is marked, preparations of arsenic or valerian.

It must also be remembered that diabetic patients are particularly predisposed to infections. Only urgent operations should be undertaken and the strictest aseptic precautions observed. In the comatose stage drastic purgatives, large doses of bicarbonate of soda, and hypodermic injections of ether and caffeine probably offer the greatest chance of improvement.

XXXVII.—EXOPHTHALMIC GOITRE.

At the beginning of the present week I specially retained in hospital a horse showing certain curious symptoms, to which I drew your particular attention. The animal was about fifteen years old, and had been its present owner's possession for five months. Until the last few days it had enjoyed good health and done regular work. We were informed that it then left a part of its food, that the fæces became small in quantity and hard, and that the animal seemed less active at work.

In this patient we immediately noted a two-lobed swelling formed by enlargement of the thyroid gland, and situated opposite the origin of the trachea; the left lobe was larger than the right. Both lobes were soft, elastic, resistent, slightly fluctuating, moveable under the skin, and somewhat adherent to the deeper seated tissues. The mouth was dry, but there was no dental disturbance. Palpation of the abdomen was not painful, and no signs of obstruction of the intestine could be detected.

There was no tachycardia (rapid action of the heart), no palpitation, no intermittency; in fact, no other trouble. The respiratory movements were not accelerated. The temperature hardly registered 38·5° C. (101·3° F.). Having noted these points you saw that I examined the eyes in order to judge of their size and prominence. In the letter sent me "slightly pronounced abnormal prominence of both eyes" was mentioned. In point of fact there was no visible exophthalmia. Although the animal showed goitre and a cardiac murmur its want of appetite was due entirely to enteritis. It was certainly not suffering from exophthalmic goitre. Nevertheless, since I have brought the question before you, I shall not allow it to pass without describing to you in what exophthalmic goitre consists.

In human medicine, for rather more than half a century, there has been described under the titles of exophthalmic goitre, Graves' disease, and Basedow's disease a morbid condition, the exact nature of which is still little understood, but which is clearly distinguished by three

principal symptoms—palpitation of the heart, goitre, and exophthalmia.

This disease had hardly been discovered when its essential characteristics were identified and well described in England by Graves, and in Germany by Basedow. Trousseau gives a masterly sketch in the second volume of his *Cliniques Médicales de l'Hôtel-Dieu.* Since that time it has been the subject, both in France and abroad, of many observations and interesting researches.

The first cases of exophthalmic goitre in animals were only announced in 1888. At this date the Russian veterinary surgeon Jewsejenko described two, one in a mare and the other in a bitch.

The first was that of a four-year-old thoroughbred mare which, when fatigued after racing, exhibited grave disturbance, at first referred to brain disease. For a fortnight she showed weakness, dulness, loss of appetite, excessive thirst, slight acceleration of breathing, rapid action of the heart, palpitation, strong pulse, hypertrophy of the thyroid gland, injection of the conjunctivæ, and slight infiltration of the eyelids. Suddenly, on the sixth day, exophthalmia became very marked. The globes of both eyes were fixed, and the eyelids could not be closed. The lobes of the thyroid gland showed pulsation, and continued to increase in size. The temperature rose to 40° C. (104° F.). The patient died of exhaustion at the end of a month. No *post-mortem* examination was made.

The second case was that of a seven-year-old bitch, which was reported as having once suffered from an epileptiform seizure while being exercised in hot weather. Psychic disturbance, agoraphobia (fear of open spaces), and symptoms of great irritability persisted, and were later succeeded by rapid action of the heart, palpitation, hypertrophy of the thyroid gland, and finally exophthalmia. The globes of the eyes projected prominently, preventing closure of the eyelids. An ulcer developed on the cornea of the left eye, and afterwards perforated the membrane.

After the appearance of the above, four new cases of exophthalmic goitre were published—two in the horse, one in the cow, and one in the dog.*

This is the only information we possess regarding this singular disease. It is certainly rare in animals, though the paucity of reported cases is certainly in some degree due to the attention of veterinary surgeons not having been called to it.

* A second case of exophthalmic goitre in the cow was published in 1898 by Göhrig in the *Deutsche Thierärztliche Wochenschrift;* and a third in the horse, in 1899, by Ries in the *Recueil de Médecine Vétérinaire.*

In man the disease is usually announced by palpitation, which occurs suddenly after a physical or moral shock, accident, violent emotion, fright, or exhausting work, though the onset may be insidious, and aggravation gradual. The heart-beats are sudden, and so violent as to be visible over a large surface of the chest or even over the whole body. On auscultation the normal heart-sounds are magnified, and have a metallic ring, or are accompanied by murmurs, the position and intensity of which vary, but are most commonly soft and systolic. The radial pulse is generally feeble, sometimes arhythmic; in certain cases it cannot be counted owing to its frequency; on the other hand, it may also preserve its normal character for a long time. The carotids beat strongly, showing bounding movements, resembling that "dancing of the arteries" seen in certain heart diseases. Auscultation with the stethoscope sometimes detects soft or rough murmurs. The superficial veins, those of the limbs, and the jugulars more especially are large and distended. Both jugulars show strong pulsation.

Hypertrophy of the thyroid gland is sometimes uniform, extending equally to both lobes; sometimes it is more pronounced in one than in the other. Goitre seldom appears rapidly. In most cases the gland gradually increases in size, remaining somewhat elastic, soft, and moveable under the skin. It is very vascular, and on auscultation sometimes reveals an arterial murmur isochronous with the beating of the heart. In time it may undergo hardening.

Exophthalmia—that is, excessive prominence of the globes of the eyes—is usually equally marked in both eyes. It may even develop sufficiently to prevent the eyelids closing, or to threaten displacement of the eyes; this accident has indeed been seen. In other cases displacement may be very slight, or fail to occur. In addition to undue prominence of the eye rupture of the cornea is sometimes seen; the animal's gaze becomes fixed, tears escape over the face, and the sclerotic is hyperæmic. The pupil is usually normal; sometimes, however, it is dilated or contracted. In most patients the chambers of the eye remain intact and vision is unaffected, but some show dilatation of the retinal vessels, myopia, or presbyopia.

To these three symptoms must be added trembling, an almost always constant sign, which is no less important than the preceding. This trembling is sometimes limited to the limbs, in the upper parts of which it is particularly marked. Sometimes it is general, all the muscles showing fibrillary movements.

Various secondary disturbances are seen. Appetite is lost; digestion is bad; attacks of diarrhœa occur; bodily condition and strength

diminish. In some patients there may be cough, oppression, and anxiety; in others the skin is warm, dry, and affected with obstinate pruritus; abscesses may develop in the subcutaneous connective tissue in different regions. Other troubles of cerebro-medullar origin may also be present: at first there is insomnia, in consequence of over-excitement of the brain; at a later stage there may be change in character and unusual irritability or depression. Polyuria, albuminuria, and glycosuria are frequent.

Basedow's disease is not invariably characterised by all the appearances I have just mentioned. In some instances even the triad of symptoms which are usually so suggestive fail to appear. In the obscure forms enlargement of the thyroid and prominence of the globes of the eyes are little pronounced, or absent; in one variety goitre is little marked, and abnormal projection of the eyes altogether wanting; in another there is marked hypertrophy of the thyroids, and exophthalmia is scarcely noticeable; in others again only tachycardia and trembling movements are seen. Cardiac disturbance is constant; it constitutes the first and predominant symptom of the disease.

In by far the greatest number of cases exophthalmic goitre is a chronic affection. Its development is slow, interrupted by paroxysms in which palpitation and hypertrophy of the thyroid are particularly well marked. At the very outset development may be acute; the disease may appear suddenly, and almost immediately be accompanied by palpitation, hypertrophy of the thyroid, and exophthalmia; but its after progress is slow. Rapidly progressive cases are rare.

After continuing for a period varying between a few months and ten, twelve, or fifteen years, the disease may terminate in recovery, or prove fatal. Death sometimes results from cerebral hæmorrhage, sometimes from exhaustion, usually preceded by intractable diarrhœa, or from intercurrent infectious disease.

The *post-mortem* examination of persons who have died of exophthalmic goitre does not always show lesions in the more important organs sufficiently explaining death. The heart is normal, dilated, or hypertrophied; in the last case hypertrophy may either be total, or limited to the left ventricle. The valves are normal or thickened; sometimes the calibre of the carotids is increased.

The thyroid arteries are dilated and sinuous. The thyroid gland is enveloped in a layer of connective tissue, penetrated in all directions by large venous channels; its tissue varies in consistence and colour, but is usually of a deep tint, very vascular, and in exceptional cases fibrous or sclerosed.

Even the ophthalmic artery is often dilated. The membranes of the eye, particularly the choroid and retina, are hyperæmic; the retinal arteries and veins have been found dilated, the retina infiltrated with blood and pigmented, the choroid strongly injected.

Other lesions may exist in the principal viscera. The stomach, intestine, liver, spleen, kidneys, and brain are sometimes hyperæmic. In many cases hypertrophic cirrhosis has been noted; in others renal lesions, similar to those of Bright's disease. Such lesions, however, are of secondary importance, for in most cases the viscera show nothing special.

Exophthalmic goitre is characterised by very special features, and forms a well-defined condition. But what is its nature?

One theory regards it as a disease of nutrition, a cachexia. In the obstinate and persistent form, in that which kills, the blood at length undergoes change, nutrition languishes, anæmia sets in, and becomes more or less rapidly accentuated. In the case I related nutrition was evidently affected, wasting and visible weakness were extreme; œdema had occurred in the lower parts of the body, diarrhœa was permanent, and finally, numerous purulent centres developed in the subcutaneous connective tissue of different regions. In this form death generally occurs from progress of the cachexia, though the nutritive change is only an effect and not a cause of the disease. It is not seen in trifling cases which develop slowly, remain stationary, or diminish. The disease itself is therefore not a cachexia.

Many persons still regard the disease as of nervous origin, and consider it principally due to causes acting on the brain, such as severe nervous excitement, depressing circumstances, or violent emotion. Physiology, they say, has shown that local congestions may be caused by purely nervous impulses. The congestive phenomena occurring in the thyroid gland and in the eyes are said to result from "nervous paroxysms," which, through the medium of the sympathetic, provoke disturbance of circulation. They thus claim to prove that the three main symptoms result from one cause, that is to say, from primary disturbance in the brain. They describe the disease as a "cerebro-medullary disease, a congestive neurosis, which progresses by paroxysms."

At the present day the tendency is to regard it as an auto-intoxication, produced by excessive activity or functional disturbance of the thyroid gland itself. Certain symptoms, or even the entire group of symptoms, peculiar to exophthalmic goitre can easily be produced in animals by injecting certain toxic substances. M. Bouchard has

shown, for example, that exophthalmia may be determined by injecting injurious substances excreted by the kidney. MM. Ballet and Enriquez exhibited at the Société Médicale des Hôpitaux a dog in which the symptoms of exophthalmic goitre had been produced by long-continued feeding on extract of thyroid gland. Toxic principles poured into, or retained in the blood in excessive quantity act on the nervous centres, and thus excite the complex disturbance recognised as exophthalmic goitre.

When clearly marked and accompanied by the essential symptoms exophthalmic goitre cannot be mistaken for any other disease. No other produces excessive prominence of the eyes, enlargement of the thyroid gland, palpitation, and trembling movements. Nevertheless in ill-defined or incomplete cases mistakes are easy. Even in man the disease has sometimes been mistaken for slowly developing typhoid fever, or for tuberculosis. Until recently its occurrence in animals was not recognised; it formed one of that group of unnamed diseases the nature of which can only be discovered by clinical and anatomico-pathological investigations. When recent it may be mistaken for true palpitation, for "diaphragmatic chorea," or for heart disease. But simple cardiac palpitation and spasm of the diaphragm are usually temporary affections; and even when they persist for a certain time they at least diminish in intensity after a few days, while the other symptoms of exophthalmic goitre fail to appear. Similarly in true heart disease there is neither enlargement of the thyroid, protrusion of the eyeballs, nor trembling.

The prognosis is grave. In most cases, as I have said, the disease steadily progresses, and leads to death after a varying period; in others it may become arrested. Sometimes it disappears almost completely; sometimes cure is incomplete, enlargement of the thyroid and exophthalmia persisting in a modified degree.

Treatment includes administration of drugs and surgical intervention. Patients should receive nourishing food, should live in the open air, and be rested or very moderately exercised. Electricity, especially in the form of the continuous current, has been recommended, the terminals being applied on either side of the heart. Hydrotherapy also has its supporters. Medication is chiefly symptomatic, and comprises the administration of iodine, iodides, bromides, digitalis, valerian, and arsenic. A new method of treatment, which has been attended with improvement, and even with cure in some unlooked-for cases, consists in administering thyroid extract, or tabellæ of iodothyrin.

Encouraging results have also followed surgical intervention in

connection with the thyroid gland and resection of the cervical sympathetic.

I have made this short incursion into the domain of the other medicine in order to draw your attention to a disease which has scarcely been observed in animals, cases of which, however, if closely studied and carefully reported, would be of great interest from the point of view of comparative pathology.

XXXVIII.—ECZEMA IN THE DOG.

Of all domestic animals the dog most frequently suffers from skin diseases. Dogs so affected are received into hospital at all times of the year, and a day never passes without your seeing a certain number in the clinique.

The study of these diseases has been greatly neglected. Until a comparatively recent time, although the microscope had become a common instrument, the number of practitioners who used it to confirm their diagnosis of cutaneous disease in the dog was distinctly small. The progress made in the field of human dermatology induced M. Mégnin and some other veterinary surgeons to make a special study of diseases of the skin in domestic animals. At the present day the majority of such diseases in the dog are well recognised, and diagnosis is usually easy.

Eczema, which was first separated from the various forms of mange, then from the dermatomycoses and the several varieties of dermatitis, still comprises a number of diseases, dissimilar as regards their appearance and course, but which will undoubtedly be differentiated later. At the present moment the word eczema cannot well be applied to a simple morbid condition, but refers to a group of dermatoses, of acute or chronic course, differing as to symptoms and lesions, usually rebellious to treatment, apt to return, and usually seen in combination with a special diathesic condition.

Clinically, eczema appears as an eruptive dermatitis, commonest in animals with the above-mentioned predisposition, directly produced by external or internal causes, sustained by pruritus and the consequent scratching or rubbing, variable in character, development, and gravity. According to the degree of intensity it has been divided into acute and chronic forms. In many cases the former is only the first stage of a process which afterwards develops slowly, producing obstinate and often permanent lesions.

It affects animals of all breeds and ages, seems almost equally

frequent in both sexes, but is particularly common during the second half of life. Apart from the eruption of distemper, young dogs seldom show more than ephemeral vesicular outbreaks quite different from the eczema of aged animals. The disease does not attack all regions with equal frequence, appearing to have a preference for the upper parts of the body like the head, neck, back, loins, and croup, and for the point of the elbow, groin, scrotum, tail, and interdigital spaces. When chronic and of old standing it may be more or less generalised. Then it is usually exceedingly rebellious about the back, elbows, hocks, in the ear, and at the extremity of the tail.

At the beginning of any summary of the conditions favourable to the outbreak of eczema must be mentioned that important idea that eczematous eruptions are often subordinate to a constitutional condition or diathesis; in the case of young dogs to a lymphatic temperament, in adults and the aged to a gouty diathesis, to obesity, and sometimes to diabetes. This general condition largely determines the occurrence of the disease, and demands special treatment: in certain subjects it produces disturbance in the functions of the stomach, intestine, and liver, mal-assimilation accompanied by auto-intoxication; conditions which favour the development of eczema, render it liable to appear under the influence of trifling causes, and may even constitute the primary factor. Many animals with rebellious eczema are also affected with chronic bronchitis, emphysema, or asthma; and eczematous attacks not infrequently alternate with certain affections of the digestive or respiratory apparatus. Feeding also plays a part in the development of eczema: depending on the conditions under which the animal lives, attacks may be produced either by an exclusively vegetable or exclusively meat diet.

Eczematous eruptions are generally preceded by cutaneous irritation of variable character and intensity. They may be caused by clipping, repeated rubbing, pressure of the collar, the action of alkaline or acid solutions, or by external parasites affecting the parts which most commonly become diseased. Want of cleanliness and accumulation of dust or sebaceous secretions on the surface may readily bring about outbreaks. In certain cases, on the other hand, they may result from excessive use of soap and warm or cold water. During the summer they are not infrequently produced by the action of the sun's rays on the skin.

The part played by the circulatory and nervous apparatus in the genesis of eczema is still obscure. In dogs the symmetrical, slowly developing eruptions, apparently of nervous origin, are rare.

Heredity exercises an unquestionable influence. It depends on the transmission of a tendency to changes in the bodily fluids, or to general nutritive disturbance.

Bacteriology had scarcely been raised to the rank of a science before attempts were made to found a parasitic theory of eczema. Eczematous patches exhibit a complex flora of micrococci and bacteria, whose *rôle* in the pathogeny of outbreaks is still undetermined. In point of fact, organisms may be found as abundantly, and in as great variety, on the healthy skin of neighbouring parts. Nevertheless the microbes which multiply on eczematous spots are not without influence on the course and changes of the disease. They aggravate acute eczema, and partly contribute to the obstinacy of chronic forms. Nowadays the tendency appears to be in favour of admitting that human vesicular eczema results from the action of various cocci which occur massed in twos, fours, or larger numbers, and which either occupy the intercellular spaces, or are included within the cells forming the vesicle; to these Unna has given the name of morococci. In impetigo, a disease now regarded as contagious and inoculable, pyogenic microbes, especially the *Staphylococcus pyogenes albus* and *aureus*, appear to be the true agents of transmission. Whether it succeed to certain suppurating skin lesions or originate in trifling superficial solutions of continuity in the skin, this form essentially consists in infection of the papillary layer, and is characterised by pustulation, followed by more abundant secretion than that of ordinary eczema. But further research is necessary to determine the part played by microbes in the pathogeny of eczema.

The chief causes of eczematous disease in the dog are cutaneous irritation, disturbed nutrition, improper feeding, and abnormal conditions of life. Ætiologically these skin diseases may be divided into two groups, under the titles of essential and symptomatic eczema. Essential eczema is directly induced by external irritation of any given portion of the skin. In dogs with fine skin it may be caused by mechanical, thermic, or chemical agencies; by rubbing or repeated pressure; by solar irritation; and by the action on the skin of any of a large number of topical irritants. It soon disappears, without spreading. It appears to have no hold on the organism, and does not return unless the causes which have produced it are repeated.

The pathogeny of symptomatic eczema is dominated by some internal causes, either of constitutional, alimentary, or nervous origin. Various changes in the body fluids resulting from previous morbid conditions, or from mal-assimilation, may produce it. Sometimes these internal influences are alone the cause; sometimes, while giving

rise to an excessively irritable condition of the skin, they are seconded by direct irritation, such as pressure, friction, or the action of cold or heat.

What are the clinical anatomical characters of acute eczema?

The eruption appears in the form of little red spots, varying in size between that of a lentil and a pea, very closely massed together, and sometimes almost confluent. These hyperæmic patches increase in size, their centres become thickened and prominent, and fresh patches form; this stage constitutes papular eczema. When all parts of the diseased surface are inflamed and red the eczema is termed erythematous. In this case there is severe pruritus, which provokes incessant scratching. In some rare cases the papules disappear, the epidermis desquamates, and the congestion of the skin vanishes; but almost always a little drop of serous fluid collects above the papule, which is then transformed into a vesicle; the eczema has become vesicular. Almost as soon as formed the phlyctenæ are ruptured in consequence of scratching; resorption of the contents of vesicles is quite exceptional. The diseased surface is then more or less denuded of hair, the epidermis destroyed, and the papillary layer inflamed; the exuded liquid is first serous, afterwards purulent; it soon forms a viscous layer which exhales an offensive smell: at this stage the eczema is known as moist or secreting. Common eczema rubrum is only a variety of moist eczema characterised by marked redness of the skin, which is deprived of its epidermal covering.

At this stage, which persists for some days, animals are usually brought for advice. Over the eczematous patch the hair is glued together by transuded liquid; in long-haired dogs it forms a felted mass covered with a pseudo-membranous exudate; the papillary layer is inflamed, swollen, red, finely granular, and extremely sensitive. The least touch produces pain; quiet animals avoid examination, others may threaten to bite. On carefully examining the skin around the discharging patch, vesicles of recent formation may be seen. By formation of such vesicles in concentric zones the eczema spreads from the spot where it originated to adjacent parts. Having arrived at full development it may persist with these characters for three to six days, sometimes longer, after which the stages of recovery commence. But this regular course is not infrequently disturbed by various accidents which impart a special character to the cutaneous lesions. When inflammation is aggravated by rubbing, it may affect the deeper layers of the skin, which granulate, crack, or become wrinkled.

In ordinary cases the liquid transuded by the papillary layer becomes

converted into greyish or yellowish crusts, sometimes tinted brown by admixture of extravasated blood; the eczema has become crustaceous. In some animals the superficial layer of the skin is infiltrated with pyogenic microbes and covered with yellowish crusts, beneath which suppuration continues; these crusts presently become lifted and cracked across, allowing the pus to exude; the eczema is then known as impetiginous. Sometimes suppuration is scarcely apparent; the crusts at first formed remain adherent, then dry up and fall away. In either case, once the crusts are shed the skin is seen to be still slightly swollen, reddish, and the seat of more or less abundant desquamation; the eczema has become squamous. Finally, if recovery occur, the swelling, hyperæmia, and exfoliation disappear. In a short time the dermis resumes its normal condition, and hair commences to grow.

We may summarise the successive stages of acute eczema as follows:—Redness and swelling of the skin; papules; vesicles, which may or may not become transformed into pustules and rupture; discharge; crusts; desquamation. Development always follows a certain order, but in reality no skin disease offers more diversified appearances; a series of eruptive attacks may occur at very short intervals; sometimes the symptoms characteristic of these different stages are all present in one patient, and even confined within a very narrow area; a discharging patch may be surrounded by vesicles, papules, or red areas; the eruption may be localised, disseminated, or almost generalised, while secondary lesions not infrequently accompany those just mentioned. The acute pruritus seen during eruption causes continual rubbing or scratching, sometimes leading to severe cutaneous inflammation and more or less extensive destruction of the papillary layer. If exposed and excoriated, the lymphatic vessels opening on the diseased surfaces, and the groups of lymphatic glands in which they terminate, may become inflamed.

In generalised eczema—and by this term I wish you to understand not an eruption simultaneously affecting the entire skin, but the existence of disseminated, isolated, or partially confluent centres, varying in age and characters, on the body, head, and limbs,—in this form, I say, one may see febrile symptoms and loss of appetite, the exacerbations coinciding with fresh extensions, and finally complications due to visceral lesions.

An erythematous affection occurs, which in France is known under the name of *rouge* (red), but which has no connection with sarcoptic or follicular mange. It is, in fact, a form of eczema. The eruption affects parts where the skin is fine and almost bare, or where hair is scanty, especially the elbow, groin, and inner surface of the upper parts of the

limbs, sometimes even the lower surfaces of the thorax and abdomen. It is principally seen in young or adult animals, but the suggestion that it specially affects certain breeds is erroneous; all are subject to it.

It is characterised by reddening of the skin and acute itching; where the hair is white the skin shows a reddish tint. On the inflamed skin little vesicles develop, which rupture, and are sometimes followed by superficial ulceration and trifling discharge. In the more obstinate cases a series of vesicular eruptions may occur; the layers of the skin become swollen and covered with a layer of thickened epidermis marked by crusts and folds. Cases occur where this erythema, though at first localised, gradually extends along the sides of the thorax and abdomen behind, along the perinæum as far as the anus; anteriorly along the lower surface of the neck as high as the head. In most patients the inflammation is particularly acute in the folds of skin around the elbow and groin, where the two surfaces of skin in contact become excoriated, and sometimes discharge rather abundantly.

Apart from the common form of eczema, accidental cases occur of what Unna described in man ten years ago as seborrhœic eczema, characterised by a special inflammatory condition of the skin, epidermis, and sebaceous and sudoriparous glands, and by depilation of regular, sharply defined surfaces which gradually extend, and sometimes heal at the centre. This seborrhœa is dry, squamous, or crustaceous. As a rule the orifices of the sebaceous glands are obliterated in consequence of excessive growth of the epidermis, the glands themselves being hypertrophied and the capillary follicles atrophied.

Attacks of eczema have, as I said, a well-marked predilection for certain regions, though they may be found everywhere; no portion of the skin is exempt. Some present special characters due to their position, such as eruptions on the eyelids, ear, scrotum, and interdigital skin. Eczema of the eyelids causes marked swelling, depilation, acute itching, and conjunctivitis, with rather abundant discharge, which sometimes glues together the lids. That of the ear produces an offensive discharge, and gives rise, like the preceding, to acute pain, expressed by continual movement of the parts; sometimes the skin of the external auditory meatus is much swollen, and the conduit itself obstructed. Eczema of the scrotum is remarkable on account of the swelling and very acute hyperæsthesia of the inflamed surface, and the abundance of the discharge. That of the plantar region and interdigital space produces lameness; sometimes it is followed by suppurating dermatitis of the paw, which may become complicated with sinus formation difficult to cure.

Many cases of eczema at present under treatment in hospital are

localised on the body, neck, and ear. In one the upper surface of the neck, shoulders, and back presents a large inflamed patch partially denuded of hair, and almost entirely covered with a viscous, yellowish, purulent material; the skin is thickened, infiltrated, and shows transverse folds; the periphery of this patch is sharply circumscribed by a deep red sinuous line, outside which is a narrow hyperæmic zone. In another the lower surface of the neck is the seat of an eczematous zone offering nearly the same characters. A third showed a few days ago a discharging and very painful area on the back. The process has now arrived at the period of desiccation; the skin is covered with thin crusts, is no longer so sensitive, and is hardly swollen. In a poodle affected with double otitis externa, marked by abundant discharge and great sensitiveness, the integument lining the external ear is still swollen and red, but the discharge has greatly diminished, is no longer offensive, and the itching has disappeared. Another case shows auricular eczema complicated with othæmatoma (œdema of the flap of the ear); the incessant shaking of the ears has caused separation of the skin from the subjacent tissues, and the formation of a cyst prominent on both surfaces of the flap of the ear.

Histological study of the lesions of acute eczema shows that the process is generally limited to the superficial layer of the dermis. The rete mucosum is the seat of œdematous inflammation, and of a more or less abundant immigration of lymphatic cells; the epidermis is swollen and softened by the exuded serosity, vesicles form, and the epidermis becomes detached or exfoliated. The vesicles develop between the rete mucosum and the stratum corneum; they contain a serous liquid, leucocytes, large polynuclear epithelial cells, and micrococci. The more intense the inflammation, the greater the amount of exudate and the more abundant the infiltration of leucocytes. The inflammatory changes extend to the entire thickness of the corium, in which purulent centres may develop, partial destruction of tissue occur, and portions of the papillary layer be lost in consequence of external irritation. To sum up, acute simple eczema is an exudative inflammation affecting the dermis and epidermis, and producing lesions comparable to those of a superficial catarrh of the skin.

XXXIX.—ECZEMA IN THE DOG (CONCLUSION).

Chronic eczema, which is very common in old dogs, succeeds to acute attacks; or may develop as a primary condition, and then presents the characters of the squamous form.

It also most frequently affects the upper regions of the body; in some patients it is confined to the limbs, and more particularly to the elbows and hocks. It may continue in the dry stage indefinitely, though, as pruritus is generally severe, certain spots are apt to become irritated by scratching or rubbing, and moist discharging areas develop in consequence. For this reason most animals with old-standing eczema show recent areas alongside others of much older standing.

The affected surfaces in chronic eczema present an appearance resembling lichen; the hair is shed, or the sparse covering left is rigid and patchy; the skin is thickened, dry, and squamous, often has a granular or verrucous appearance in consequence of hypertrophy of the papillæ, and is usually deeper in colour than that of neighbouring parts.

The process produces hardening (sclerosis) of the skin, and leads to hyperplastic and atrophic changes; the cells of the dermis, the glands, and the capillary follicles gradually undergo change, and may partially disappear. In spite of exfoliation of the superficial layers of the epidermis this portion of the skin remains of considerable thickness.

As in the acute form, circumscribed patches are sometimes seen which remain obstinate, and very rebellious to treatment. In the dorso-lumbar region eczema often extends over very large spaces, and in old-standing cases produces excessive thickening and folding of the skin. In the limbs the disease affects the elbows, hocks, and digital region; in some animals it ends by producing suppurative dermatitis, marked by the formation of numerous little abscesses containing blood-stained pus, and offering almost the same appearance as follicular mange. Eczema of the tail sometimes extends to the greater part of this region, or appears as a large number of small disseminated areas, but is most frequently localised at the extremity, the skin covering which is inflamed and swollen, and its superficial layer ulcerated, whence the

name "cancer of the tail;" the remaining hairs at this point are stiff, dry, and fragile, and the end of the tail is often indurated for a distance of an inch or more. The diseased parts are often bitten or otherwise injured, causing bleeding and acute recurrences of inflammation; in this way the disease may be prolonged for months. In exceptional cases eczema may produce marked thickening of the epidermis covering the caudal extremity, and the growth of little confluent horny patches. Chronic eczematous inflammation of the auditory meatus produces thickening of the lining membrane, sometimes ulceration or hypertrophy of the papillæ, and vegetations which obstruct the passage.

The symptoms of eczema are sufficiently characteristic in most cases to permit of diagnosis solely by clinical examination. If there is any doubt, it becomes necessary to carefully examine all the affected parts, their appearance and character frequently allowing of an opinion being given without recourse to microscopic examination. Eczema can always be differentiated from the eruption seen during distemper, from favus and tinea tonsurans, and from various traumatic lesions of the skin; but certain forms may be mistaken for sarcoptic, and others for follicular mange. We recently saw a dog which showed a patch of impetiginous eczema on the neck, closely resembling follicular mange, and eczematous areas often simulate recent sarcoptic mange. In these cases the question can only be decided by microscopic examination of material obtained by scraping the diseased surfaces with a scalpel.

The prognosis of eczema is more serious than that of other skin diseases of the dog, except follicular mange and suppurating dermatitis. It is not particularly difficult to temporarily cure animals, but the disease frequently reappears after a varying interval. Although all forms of eczema are not equally grave, the majority imply the existence of a constitutional condition which dominates the appearance of disease. The prognosis is more favourable in acute than in chronic eczema, and in localised than in the more or less generalised forms. Eruptions on the ear, foot, and tail are difficult to completely cure in certain animals, especially in those beyond middle age. Various complications are possible. Thus eczema of the ear may be accompanied by ulceration of the base of the conchal cartilage—auricular canker; by othæmatoma, by abscess formation at the base of the ear in consequence of rubbing, and later by deafness; eczema of the eyelid is sometimes complicated by entropion, or even by ulcerative keratitis; and eczema of the scrotum may be followed by orchitis due to rubbing, by which the animal seeks to allay pruritus. Whatever the seat of

the eruption, intra- or hypo-dermic abscesses and loss of substance of the skin aggravate the eczema and leave cicatrices. Finally, the animal's mode of life plays a certain part; in lapdogs eczema is more rebellious, and relapses more frequent than in others.

The treatment of eczema is complex. Many practitioners confine themselves to local treatment, but in most patients durable results can only be obtained by internal medication, and change in the method of feeding.

The local treatment of acute eczema is best commenced as follows:—The hair should be clipped from the diseased surface, and if the eczema is extensive and generalised the animal should be shaved; the skin is next washed with soap and water, or with warm boric solution, dried carefully, and afterwards protected as far as possible from irritation; in pet dogs the rug usually may require to be removed, and in no case should a collar be used if an area of eczema is developed on the skin of the neck.

In moist eczema, once the diseased surfaces are cleansed and disinfected the best local treatment usually consists in topical dressing with powders, with which the parts are dusted two or three times per day. Among such are starch, talc, subnitrate of bismuth, oxide of zinc, or a mixture of these substances. In pet dogs these powders may be slightly perfumed, and rice powder substituted for starch.

If the skin irritation is very acute, warm lotions containing chloral hydrate, or 3 to 6 per cent. bicarbonate of soda solution; or, again, very dilute alcohol, with the addition of 1 per cent. of carbolic acid, may be used; and the parts afterwards dressed with a preparation of glycerine, or an ointment containing the same proportion of carbolic acid. In the limbs, and other regions which the animal can reach, eczema is often kept up and aggravated by licking. The diseased surface must then be protected with a cotton-wool dressing.

Slight cauterisation of the inflamed surface has sometimes been practised, for which purpose either 10 per cent. nitric acid or 5 to 6 per cent. nitrate of silver solution may be used. The spots are swabbed with one of these preparations by means of a brush. This produces a superficial eschar, and leads to the formation of a thin protective crust, under which the skin dries and the epidermis is renewed.

In acute eczema especially, lotions and repeated baths are inconvenient; water irritates the skin, keeps up or even increases the inflammation, and may produce fresh eruptions.

In impetiginous eczema the pus collected under the crust may be gently squeezed out, the crusts themselves removed with small tampons

of cotton wool, and an antiseptic dressing applied. One may also use with advantage 5 per cent. aqueous solution of carbolic acid or of formalin; pure glycerine, or glycerine containing a trifling proportion of iodine; zinc ointment; vaseline, or lanoline. The three latter can either be used alone or with the addition of small quantities of talc, oxide of zinc, boric acid, salicylic acid, or resorcin. The following are useful formulæ:

(1)	℞	Vaseline	100 parts
		Wax	20 ,,
		Oxide of zinc	20 ,,
(2)	℞	Vaseline or lanoline	Equal parts.
		Oxide of zinc	
(3)	℞	Vaseline	100 parts.
		Talc	50 ,,
		Oxide of zinc	50 ,,
(4)	℞	Vaseline	100 parts.
		Oxide of zinc	50 ,,
		Salicylic acid	5 ,,
		Resorcin	$2\frac{1}{2}$,,

In the squamous forms of eczema tar and creolin are the applications commonly used. The tar may be applied either dissolved in alcohol or mixed with green soap.

(1)	℞	Tar	100 parts.
		Alcohol	50 ,,
(2)	℞	Tar and green soap	Equal parts.
(3)	℞	Creolin	50 parts.
		Green soap	50 ,,
		Alcohol	25 ,,

The chosen preparation is applied in a thin layer to the diseased parts; crusts form and crack, and can be removed at the end of a week. The appearance of the skin indicates whether a second application is necessary. When the skin is moist these preparations are inferior to powder dressings.

The seborrhœic form is treated by the application of glycerine of starch and oil of cade in equal parts; by ointments or glycerina containing 5 per cent. pyrogallic acid, 5 to 10 per cent. salicylic acid, or 10 per cent. of sulphur.

In treating chronic eczema the chief points consist in softening and detaching the crusts or scales, disinfecting the diseased surfaces, and protecting the hyperæmic skin from irritation. The crusts are softened and cleared away by applications of vaseline, and by washing

with Castile or glycerine soap. The skin is afterwards dressed with a warm solution of bicarbonate of soda, or better still with one of the liniments just mentioned in speaking of squamous eczema.

The parts are occasionally washed with soap and boiled water, to which has been added 1 to 2 per cent. of creolin, or with the solution of bicarbonate of soda.

Many other preparations, and certain new drugs like ichthyol, anthrarobin, chrysarobin, and pyoctanin, have been recommended during the last few years, but are in no wise superior to the applications usually employed.

Internal medication is useless against eczema resulting from purely local causes, but in practice it is impossible to clinically distinguish between such attacks and those of constitutional origin; when the disease is chronic and rebellious internal medication is always indicated. In eczema there is no unique general treatment, and no drug can lay claim to the character of a specific. Neither alkaline nor arsenical preparations suit all cases. Although the former are valuable at various stages of the disease, they are particularly useful in fat or obese dogs; bicarbonate of soda may be given in the food in doses of 15 to 90 grains per day. Purgatives are useful in acute eczema; under their influence the cutaneous patches dry more readily. Arsenical preparations, especially Fowler's solution, are valuable in the chronic forms. Fowler's solution is given in doses of 1 to 6 drops per day. Mineral waters like Vichy, Evian, or La Bourboule, may be prescribed, especially for pet dogs, and can be given pure or mixed with milk. Sublimed sulphur in daily doses of 15 to 30 grains, cod-liver oil and iron salts also have their use.

Finally, it must be borne in mind that hygiene, diet, and healthy surroundings have an unquestionable influence on the development of eczema. Depending on its constitution or bodily condition, the patient should either be confined to light nourishment, to meat, boiled milk, or to various preparations of milk, or may receive a mixed diet. In general the number of meals should not be diminished, but the total daily nourishment should be cut down. If the patient is fat it must be reduced to a minimum diet. Pastry, etc., should be forbidden. Animals leading a confined life should receive regular exercise.

In the dog good hygiene and carefully regulated diet often have at least as much effect on the course of eczematous attacks as any drug. Many of our patients are under unfavourable conditions for complete cure, so that when their condition can only be improved it is usually better to return them home, arrangements being made for steady exercise, open-air life as far as possible, carefully regulated diet, and every week or two internal treatment.

XL.—ECZEMA IN THE HORSE.

A FEW days ago you saw in the clinique a horse with recent skin disease, indicated by symptoms resembling those of granular dermatitis. This peculiar appearance had struck the veterinary surgeon who sent the animal to me. He pointed it out, and suggested that the disease resembled the "heat spots" seen during warm weather.

On examining the patient we found three swollen patches covered with yellowish-grey broken crusts, from between which a sticky, serous fluid escaped. One of these patches, situated between the elbows, was oval in shape and a little larger than a man's hand; another on the near fore-leg was limited to the external surface of the canon-bone and fetlock; the third, in a similar situation on the off hind leg, was rather larger in size. I will give a summary of the clinical history of this animal.

Bay brown, seven-year-old gelding, of lymphatic character, brought for examination and left for treatment on the 6th March.

Being attacked with bronchitis towards the middle of last January, this animal was rested for nearly three weeks. Since convalescence it has worked little. The skin affection originated about a fortnight ago. Three patches, from which the hair fell away and discharge occurred, successively appeared, one on the near fore-limb, one on the off hind, and one on the chest.

State on Examination.—The patches are situated as follows:—The first on the outer surface of the fetlock and pastern of the near fore-limb; the second between the elbows; the third on the antero-external surface of the right hock. The latter has the most striking appearance. At the present moment almost its entire surface is denuded of hair and discharging. At certain points the exudate is serous and trifling in amount; at others there are little erosions covered with a thin, sticky, yellowish layer formed of dry exudate; when exposed the dermis is of a more or less bright red, and appears finely punctated. In other places.

where inflammation is more intense, granulations have developed, rising a few millimetres above the level of the skin, and secreting a sero-sanguinolent liquid, which, together with the epidermal cells, etc., forms a material gluing together the hairs surrounding the patch. The patch itself is encircled by a band of skin covered with vesicles resulting from a fresh attack. Sensation is not specially acute at any point, but there is intense pruritus, which the animal betrays by biting or continually rubbing the parts. Despite the use of a cradle it still attempts to bite, and has several times rubbed the diseased spots, causing them to bleed. There is no lameness.

The patch on the near fore-limb is less bare than the preceding; its upper part is becoming dry, but its lower still discharges. At first sight the disease recalls horse-pox, or a recent attack of grease, but the offensive odour and the vegetations characteristic of the latter are absent. Examined more closely, this surface shows the same characters as the patch on the right hock. There is a certain degree of itching and of local swelling, but no lameness.

The third patch occupies the entire space between the elbows and the upper internal surface of both fore-limbs. It is covered with pale yellow, thin, sticky crusts, while the skin is swollen, infiltrated, and shows a series of broad folds separated by depressions in which secretion is abundant. Like the two others, this patch is the seat of extreme pruritus. The continuous movement of the limbs keeps up acute inflammation.

The general condition is good. The principal functions are normal.

The characters of the patches, the presence of isolated vesicles around them, their almost simultaneous appearance in several separate spots, and their mode of development, leave little doubt as to the diagnosis. The negative result of inoculation with the exudate clearly shows the condition to be moist eczema.

Treatment consisted in clipping away the hair from around the patches on the limbs, disinfecting the surfaces with warm creolin solution, drying, and applying a powder composed of four parts starch and one part oxide of zinc; finally, administering internally sulphate and bicarbonate of soda.

Considerable improvement was noted from the third day. The patch on the near fore-limb discharged less, except under the pastern, where in consequence of movement the granulations had been torn through. In the off hind limb the disease had extended to the lower portion of the canon-bone and fetlock, developing with great rapidity; eruption, vesiculation, and rupture of the vesicles occurring in twenty-four to forty-eight hours. The patch between the elbows was much

less swollen; the crusts were thinner, and on being removed revealed a rose-coloured granulating surface.

On the 13th improvement continued. The diseased surfaces on the fore and hind limbs were almost completely dry, and in a fair way to heal. Nevertheless around the flexures of the pastern and hock the continued movement had resulted in formation of superficial cracks. These were dressed with boric vaseline.

On the 15th these two patches were entirely healed, and the third discharged less abundantly.

On the 20th the surface between the elbows had become dry.

The foregoing gives an exact idea of the characters of the skin lesions in our patient. Certainly they in no way resemble those of granular dermatitis. Apart from the fact that this disease neither appears nor returns at the present time of year, the superficial lesions that you saw had not the essential characters of this parasitic dermatitis; the skin was only moderately swollen, the diseased surfaces were only granular at certain points in consequence of mechanical irritation, and the pruritus rapidly diminished. Nor was the disease like urticaria or any form of mange, which usually occupies positions and shows symptoms entirely differing from those we noted. As to horse-pox, the cutaneous lesions of which often simulate acute eczema, we eliminated it by the negative results attending inoculation of several horses.

The disease was a simple eczematous eruption, the most striking features of which were its position and the small extent of the affected surfaces.

During two of our preceding lectures I devoted considerable attention to the stages of development and different forms of eczema in the dog. To-day I wish to speak of the same disease in the horse, in which, however, it is much less common than in the dog. The forms seen include acute and chronic, sometimes generalised, sometimes confined to certain regions.

The disease is usually more or less generalised. A discrete papular eruption appears, accompanied by itching; the points soon become more numerous, the itching increases, and the papules are converted into vesicles and burst spontaneously, or are ruptured by rubbing. Where the skin is fine the eruption is often vesicular from the first. The contents of the blisters spread over the skin, glue together the hairs into little tufts, and afterwards dry, forming small yellowish or greyish crusts, sometimes deeper tinted on account of the blood

present. Trifling suppuration occurs, raising and detaching the crusts, which carry with them a portion of the hairs covering the skin at that point, and thus produce the bare surfaces seen during the final stage of the eruption. The crusts having fallen suppuration ceases, the dermis again becomes covered with a thin dry layer, under which the epidermis re-forms, and the skin gradually resumes its normal appearance.

Some weeks ago you saw in an eight-year-old cart-horse a remarkable outbreak of generalised eczema. The skin of the trunk was dotted over with small greyish circular crusts a few millimetres in thickness, over which the hairs were glued together in tufts. The disease had appeared about ten or twelve days before. This horse first showed loss of appetite and depression, followed by the sudden eruption of vesicles over a wide surface. When brought here we noted nothing abnormal save the cutaneous disease; neither the animal's general health nor the various functions were in the smallest degree disturbed; not even the mucous membranes showed anything unusual.

Successive attacks of an acute or subacute character may develop, a fresh eruption occurring before the disappearance of the preceding, so that lesions of varying age are often associated and combined, forming a complex polymorphic clinical picture. In some cases the skin finally becomes almost entirely covered with crusts.

Instead of thus extending, eczema may be limited to certain regions. It is commonest in those exposed to mechanical irritation, like the head, withers, front of the shoulders, back, croup, and girth, where the different portions of the harness exercise pressure and continual friction; behind the elbow, or in the groin, where the folds of skin, which are frequently covered with sweat, produce mutual friction during movement; on the flexion surfaces of the joints of limbs, especially the lower joints, where the skin forms folds and is exposed to the action of wet or mud, or is covered with scurf, dust, or manure; on surfaces covered with long hair, such as the upper margin of the neck and tail (parts specially affected by parasites, like lice and trichodectes), and at points where the skin is kept moist, or is not cleaned. Circumscribed eczematous patches show the same features as the generalised form. Once the vesicles rupture, the skin, as in exudative dermatitis, is seen to be swollen and discharging, while the margins of the inflamed areas still exhibit a few vesicles.

Instead of terminating in recovery eczema may assume the chronic form. The skin becomes thickened, wrinkled, irregular, and squamous; sometimes it is covered with thick crusts, or shows superficial cracks.

This chronic eczema produces permanent changes in the skin. The chief consists in more or less abundant cellular infiltration of the corium, especially around the folds; dilatation of the lymph vessels; hypertrophy of the papillæ; and sometimes a fibrous change in the dermis, with atrophy of the glands and hair follicles. The changes, in fact, are those of sclerosis.

Eczema especially tends to become chronic in parts irritated by harness and in the flexures of the knee, hock, and phalangeal joints. For a long time all transverse cracks in the skin over the flexures of joints were wrongly considered simple accidents, due to physical, chemical, or thermic causes. Undoubtedly many cases are due exclusively to local influences—during cold weather to the action of snow, mud, or water; but the transverse cracks which develop in these regions and prove so obstinate (mallenders and sallenders) are often eczematous in character. Their ætiology is dominated and their persistence and chronic character explained by some peculiarity in the animal's constitution. Last month you saw in the external clinique a seven-year-old Norman horse which had been ineffectually treated for nearly a year for numerous comparatively superficial cracks under both front pasterns. The choice of applications had certainly not always been happy. Previous to coming here the parts had been dressed with an ointment containing lard, which had formed a layer of decomposing irritant material, contributing in no small measure to the continuance of the disease. We prescribed local antiseptic treatment and internal medication. The horse returned here a few days ago, and you saw that already great improvement had occurred. I have collected a number of similar cases in which success appeared due, in part at least, to internal treatment, a fact which shows how far these attacks are dependent on the general state of health, or on some disturbance of nutrition.

In the horse cases of essential as well as of symptomatic eczema are seen, but almost all obstinate attacks depend on some disturbance in the general health.

As I said before in speaking of canine eczema, it is probable that microbes living on the skin, or at least some of them, play a part in producing certain forms of eczema, though even in "grease" this part is at present ill-defined.

In the horse certain eczematoid diseases of the foot and lower parts of the limbs are remarkable both for their clinical appearance and obstinate character. Chronic exudative and hypertrophic dermatitis of the pastern—vulgarly known as "grease"—is characterised by a dis-

charge, by staring of the hair, and by verrucous growths due to hypertrophy of the papillary layer. Chronic vegetating dermatitis of the foot—canker—produces similar hypertrophic changes in the horn-secreting structures of the sole, principally in the velvety tissue, at the same time destroying a greater or less area of the horny sole. Chronic dermatitis of the coronet—inflammation of the perioplic ring—produces disturbance in the secretion of periople and increases and hardens the superficial layers of skin around the coronet.

Whilst the latter disease is principally seen in plethoric or nervous patients, the two former (whose development is favoured by the local action of moisture and of urine, etc.) are almost always confined to lymphatic animals, and may be regarded as special morbid conditions having a distant connection with the usual forms of eczema.

The prognosis of the various forms of eczema in the horse is favourable. In the acute forms recovery is easy and almost always rapid. The chronic forms generally yield to suitable local and general treatment. Mallenders and sallenders, which may also involve lameness, are the most obstinate complications.

In acute eczema the first indication is to thoroughly cleanse and protect the diseased surfaces from irritation. If secretion is abundant, absorbent powders, like simple starch powder, or starch powder with the addition of a little bismuth or oxide of zinc, may be used. Glycerine, iodine-glycerine, more or less strong antiseptic solutions, and a large number of ointments have also been successfully employed. The good results obtained from all these agents are easy to explain, inasmuch as we know that in acute eczema recovery occurs spontaneously in a period seldom exceeding three weeks to a month. Where itching is very severe, ointments or glycerina containing 1 per cent. of carbolic acid, or analgesic preparations like solutions of cocain may be tried, though the latter require frequent application.

If the attack is prolonged or recurrent, internal treatment becomes necessary. Arsenious acid, Fowler's solution, alkalies, or even iodide of potassium may be used. In certain cases the diet requires to be changed.

In chronic eczema the diseased surfaces must first be cleansed, either with water alone or with soap and water, and the process repeated sufficiently often to keep the skin perfectly clean. After drying, the parts may be dressed with vaseline, containing carbolic acid or creolin, or with one of the liniments recommended for the dog. Occasionally it is very useful to apply a surgical dressing for several

days, in order to protect the diseased skin from irritation. This method is particularly valuable when animals affected with eczema about the lower parts of the limbs are obliged to work in wet weather or on muddy roads.

Internal medication comprises alkalies and arsenical preparations, which may be given alternately for periods of a fortnight ; bicarbonate of soda in daily doses of one to two ounces, followed by arsenious acid in daily doses of seven to fifteen grains. Between the two courses treatment should be suspended for intervals of one week.

Chronic vegetating dermatitis of the pastern (grease) is treated by cleansing the skin with warm antiseptic solutions, and applying astringents or slightly caustic preparations daily, or at intervals of several days. Villate's solution, 5 to 6 per cent. solution of sulphate of copper, 2 per cent. solution of chromic acid, and ·2 to ·3 per cent. watery or alcoholic solutions of sublimate, or of formalin, appear to give the best results.

Chronic dermatitis of the coronet is dealt with by applications of tar, of tar and vaseline, or of slightly caustic solutions, and by thinning the wall of the hoof opposite the diseased spot.

Vegetating dermatitis of the foot—canker—necessitates exposure of the entire invaded surface of the sensitive sole and excision of the vegetations. The parts are then dressed with antiseptics, astringents, or caustics, care being taken, however, not to destroy the dermis and subjacent tissues.

In these forms of dermatitis it is also well to administer some preparation of arsenic. The drug is given for periods of a fortnight, treatment remitted for a week and again continued. In this way arsenic may be employed for long periods.

PART III.

CLINICAL CASES.

I.—HEAD AND SPINAL CORD.

A.—*CRANIUM, BRAIN, AND SPINAL CORD.*

SUPERNUMERARY TOOTH IN THE TEMPORAL REGION—OPERATION—SUPPURATING MEDIAN OTITIS.

1. THREE-YEAR-OLD gelding, left in hospital 23rd January, 1897.

About two months previously a gradually increasing swelling had appeared at the base of the left ear. On the 20th January a long streak of pus was seen running over the face. A veterinary surgeon who was consulted spoke of operation, and recommended the animal being sent to Alfort.

Condition on Entry.—A hard swelling, as large as a hen's egg, and of bony consistence, was seen a little in front of the base of the left ear. On the anterior surface of the scutiform cartilage was a sinuous orifice, which discharged considerable quantities of greyish pus.

Diagnosis.—Supernumerary tooth (dental ectopia).

Treatment.—On the 25th January the animal was cast by means of Daviau's table. After clipping away the hair and preparing the parts the sinus was explored, and found to be about 4 inches in depth, and to terminate over a dental prominence. The skin was incised for a length of $3\frac{1}{2}$ inches over the swelling, parallel with the long axis of the head. The margins of the wound were drawn apart, and the supernumerary tooth exposed by a second slight incision. The tooth, which was fixed in the temporal bone over the origin of the zygomatic process, could not be removed with the strong dental forceps used. It was therefore left in position. The wound was cleansed and a plug of iodoform gauze applied, over which the lips of the wound were reunited by a few sutures. The tampon was removed next day.

During the next few days the cavity was washed out with an antiseptic night and morning. At the owner's request a further operation was undertaken on the 2nd February.

The animal having been cast the tooth was again freely exposed,

though a fresh incision was not necessary. The wound having been disinfected a groove was cautiously excavated around the tooth by means of a gouge and hammer, and unsuccessful attempts made to loosen it. As, however, the tooth was very deeply implanted, and extraction might possibly have caused injury to the brain, the operation was stopped. The wound was cleansed and plugged with iodoform gauze, the skin brought together with a couple of sutures, and the horse allowed to rise. Although every precaution had been observed the animal showed grave symptoms. The head was held pendent, a little inclined to the left; movement was very difficult; the fore-limbs were planted wide apart, and yielded on movement, allowing the animal to fall on its knees. It at once rose, but was unsteady on its legs. A deep bed of straw having been spread around it, the patient lay down. It rose in half an hour, and was then placed in its box. During the evening it took some sloppy food.

Next day it was found standing but greatly depressed; the head was held low and still inclined to the left; the fore-limbs were planted widely apart. The animal was led out and moved a few steps; the gait was slow, uncertain, and vacillating. At certain moments rolling of the eyes occurred. The wound was washed and plugged with iodoform gauze.

On returning to its box the animal attempted to eat. It took some sloppy food and a little hay. At first we suspected intra-cranial hæmorrhage, but as the circulation and respiration became more rapid, and the temperature rose to 40·3° C. (104·5° F.),* we concluded that the mechanical injury was complicated with meningo-encephalitis. Affusions of cold boric solution were made to the head, the wound was washed with 2 per cent. creolin solution, iodide of potassium was given, and the food confined to mashes and milk.

On the 4th February the respiration was rapid and short, 36 per minute; temperature 39·8° C. The pulse was very small and uncountable.

On the 5th the respiration was still rapid and the pulse feeble. The animal was sleepy, had no appetite, and only seemed able to masticate its hay. Although held very low the head was less inclined to the left, and movement was less painful. Temperature 39·4° C. Treatment as before. The evening temperature rose to 41° C.

On the 6th the condition remained the same; temperature 40° C. Next day there was slight improvement; temperature 39·6° to 39·9° C. Respiration was less rapid; appetite fair; difficulty existed in swallowing.

On the 8th the general condition was a little improved. The patient left the corner of the box in which it had been standing, moved about with some freedom, and ate its oats and mash. Hay and straw were slowly chewed, the food dropped out of the mouth and again picked up; occasionally a little was swallowed, but with

* As the Centigrade scale is now largely used, and the constant addition of the Fahrenheit temperature would prove very cumbrous in these clinical records, I have printed in the Appendix a comparative chart showing the exact equivalent on the Fahrenheit scale of any given Centigrade temperature. To this readers are kindly referred.—Jno. A. W. D.

great difficulty. The eyelids were swollen, the eyes discharging, the mucous membranes injected, the pulse 48, respirations 24, temperature 39·5° C. That evening the animal was greatly depressed; it even left its mash. Pulse 60; respirations 20; temperature 40·2° C.

From the 9th to the 12th the condition became aggravated, and the comatose symptoms more marked. The temperature varied between 40° and 41° C. Death occurred during the night between the 12th and 13th February.

Autopsy.—The lung contained several metastatic abscesses as large as a hazel-nut, and a considerable number of smaller sized gangrenous spots. The guttural pouches were full of a liquid grumous pus. On sawing through the mesial line of the cranium its internal surface appeared healthy, and the meninges of the brain were only slightly injected. The left ear showed deep-seated suppurative otitis; the middle ear was full of fœtid pus. In spite of the precautions taken during operation the petrous temporal bone had been fractured and the wound infected. Pus collected from the ear and from the pulmonary abscesses contained streptococci.

The tooth passed obliquely downwards and slightly backwards through the entire thickness of the temporal bone.

[An interesting article on dentigerous cysts will be found in *The Veterinarian* for 1899, p. 309.]

TUMOUR OF THE RIGHT HEMISPHERE OF THE BRAIN.

2. A five-year-old entire horse, brought for examination on the 18th August, 1896. For some time past this horse had shown signs of "immobilité" (ventricular dropsy of the brain). It became useless for work, no longer obeying the rein and stumbling over obstacles in the road.

On first examining the animal we were struck by its peculiar attitude. The head and neck were stiff; the neck was slightly concave on the right side; the head was inclined downwards and towards the left.

At rest the animal appeared unsteady on the limbs of the near side. When alone in its box it brought the legs closely together, half flexing the fore-limbs as though about to lie down; then it began to turn towards the right in an ever-decreasing circle until it pivoted on the hind limbs; finally it swayed and fell on the right side. It showed great difficulty in rising, and had to be assisted. The hind limbs appeared almost helpless. If the fore-limbs were crossed the animal remained in this position, like a horse with "immobilité."

It was quite unable to walk in a straight line, but continually turned towards the right, and could not be made to trot, though it was able to back with ease. The lumbar region was excessively sensitive, and pressure over it caused the animal to fall.

Vision was abolished in the right eye; the eyelids were mobile; the pupil was dilated; the various media of the eye showed no disturbance. Examined with the ophthalmoscope, the papilla appeared markedly hyperæmic; the vascular striæ were very visible, especially towards the margins. Hearing seemed less acute than normal.

The lips and tongue were not paralysed. Mastication and deglutition were normal, and the appetite was perfectly good. General sensation was diminished, except in the region of the head and limbs.

The animal was moderately nourished. Temperature 37·5° C.; pulse 56; respirations 14.

During the few days the horse was under observation the symptoms remained without notable change; there was no vertigo or excitement. On the evening before the animal was slaughtered it fell on the right side, and was unable to rise again.

Autopsy.—The lesions were confined to the brain, the surface of which, however, showed nothing abnormal. On the inner surface of the right hemisphere, in the white substance, was a large softened area occupying almost all the upper part of the ventricle; it measured $3\frac{1}{4}$ inches from front to back, about 2 inches transversely, and about $\frac{3}{8}$ to $\frac{3}{4}$ of an inch in thickness, depending on the spot measured. It was not clearly circumscribed, and penetrated in various directions into the grey substance. Throughout its entire extent the nervous substance was of a reddish-grey tint, resembled jelly, and of semi-liquid consistence; the surface of sections showed a few small hæmorrhagic spots.

Studied after hardening in chromic acid, the morbid tissue seemed formed of cells with large nuclei and a small amount of protoplasm, isolated or united in little groups, and provided with long processes forming a kind of reticulum, the meshes of which contained round-cells. The growth was, therefore, not produced by degeneration, as we had at first supposed, but was a true tumour, the particular form being that known as glioma.

TUMOUR OF THE RIGHT HEMISPHERE OF THE BRAIN.

3. A seven-year-old greyhound bitch, left in hospital 7th October, 1893.

Like most of such animals, this bitch was very irritable. As testified by her own owner, in whose possession she had always been, her health had until the commencement of 1892 been uniformly good. At that time a tumour had been discovered in the mammary gland, and had been removed by a veterinary surgeon. The operation wound healed rapidly. During October another tumour appeared in the gland, and in July, 1893, was removed. The wound closed rapidly.

Some weeks later the animal showed a hoarse, dry cough, which occurred in prolonged attacks, and was followed by attempts at vomiting: the attacks became progressively more frequent. The patient soon lost breath when walking, and was regarded as asthmatic. During August and September she was taken to the sea-side by her owner. There, we were told, her condition improved, until one day during a walk in the country she came too near a cow, and began to run, yelping loudly; suddenly she stopped, her limbs became stiff, she fell senseless, and remained in that condition for twenty minutes. Although no trace of injury could be seen on the surface of the body, it was thought that she had been kicked. Having been taken home, she

several times during the evening showed signs of violent excitement. Next day she had regained her usual condition.

A fortnight later fresh attacks occurred without any evident cause. When they came on, the patient, if standing, was taken with cramp; the fore-limbs were stretched out to their fullest extent, then the hind limbs collapsed; the animal fell towards the left and remained prostrate, the entire body trembling; sometimes she howled as though in pain. During these attacks, which lasted from ten minutes to a quarter of an hour, the head was strongly inclined to the left.

Towards the end of September the disease became aggravated; the appetite, which had previously been good, gradually diminished, the animal remaining for whole days without taking food. She no longer barked; urine and fæces were passed in her kennel. During the night she often seemed subject to great excitement. Nevertheless on certain days the disturbance was much less marked. One morning she was walked nearly two miles without showing unsteadiness, without stopping, and without any apparent disturbance of movement.

Such was the history given when the animal was brought here.

She was left in hospital. The symptoms noted on the first examination were as follows:—The face was dull and expressionless; the animal reeled on her limbs; movements were slow and irregular; the fore-limbs showed irregular contractions; the head was extended on the neck, and inclined towards the ground or to the left; the back was arched. Sometimes the animal walked in circles towards the right; at times the hind limbs collapsed, the animal fell towards the left, and had great difficulty in rising. The respiration was painful and catching, the circulation slightly accelerated. Examination of the head revealed nothing particular except inequality of the pupils, the left being larger than the right. Sensation was normal. Temperature 39·5° to 39·8° C.

During the first few days the patient still ate a considerable portion of her food. Twelve grains of iodide of potash were given daily. After a short time she would only take a few spoonfuls of milk. She remained lying quietly in her kennel, occasionally lifting her head and whining. Death occurred on the 14th October.

Autopsy.—The lungs showed numerous tumours, the majority the size of a hazel-nut, but some as large as a walnut. These were whitish in colour, sharply delimited, and consisted of a friable tissue, generally light in colour, though reddish in places. Some contained a central cavity filled with liquid.

The external appearance of the brain was at first sight normal. On more attentive examination a greyish area, which showed up clearly against the neighbouring parts, was noted in the anterior half of the right hemisphere. On incising this part a little greyish liquid exuded. An ovoid tumour, measuring one inch and a quarter from before backwards and three quarters of an inch across, had developed in the wall of the hemisphere. Its periphery was sharply defined, and its centre had undergone transformation into a cyst; its tissue appeared reddish grey.

No new growth of any kind was found in the neighbourhood of the scars resulting from removal of the mammary tumours.

The tumours of the lung and brain showed the histological characters of sarcoma. They were exclusively formed of small cells, the greater number rounded and flattened at certain points by mutual pressure. All showed a strongly marked nucleus and vessels of embryonic character.

TUMOUR OF THE CEREBELLUM.

4. Ten-year-old chestnut mare, sent to Alfort on the 13th March, 1897, by M. Laurent, veterinary surgeon, at Bar-le-Duc.

History.—The disease from which this mare was suffering dated from September, 1896. It had not developed in consequence of violence. Nothing noteworthy was known as to the animal's previous history.

Disturbance in movement was the first symptom noticed; the gait was irregular, vacillating, and at certain times rolling. The animal was unable to walk in a straight line, but turned to the right or left; movement was not co-ordinated, the limbs were excessively extended, and most frequently flung outwards. At the least excitement the animal lifted its head high and started back. If harnessed with another horse it could still be used in the carriage. On returning to the stable it did not appear unwell, and began to eat.

These first symptoms gradually became aggravated. During the later period the animal, if approached in the stable, hung back, appeared terrified, rolled about on its legs, then stopped suddenly, with the hind legs thrust far under the body. Left to itself it gradually reassumed the normal position, lifted its head, and remained still. If loosened from the manger and forced backwards it pivoted on the hind legs. There was great difficulty in bringing it out of the stable. At first it refused to walk, then it made a few steps, but seemed about to fall. During these movements the head was extended and carried towards the right. Circulation and respiration were normal.

A blister was applied to the vertebral column from the withers to the tail; cold douches to the back of the head were prescribed, and sulphate of strychnine was given internally.

The patient had great difficulty in walking from the station at Maisons-Alfort to the College. Placed in a box it lay down on the right side. Breathing was very rapid and difficult. Motor power appeared to be preserved; there were frequent movements of the neck and limbs. Sensation was diminished: on pricking the skin in different parts of the body no reaction resulted. Temperature 39·7° C. The animal was assisted into a standing position and made a few uncertain steps, but showed generalised trembling movements and soon fell. At the end of a few hours the respirations were 64, the pulse 80 per minute. The conjunctiva was cyanotic. Death occurred during the night.

Autopsy.—No change could be detected in the thoracic or abdominal viscera, or in the spinal cord and brain, nor did the exterior of the cerebellum show anything abnormal. But on incising the latter we found in the lower portion of the vermiform process, and right lobe

of the cerebellum, a tumour, the size of a small nut, developed particularly in the white substance, from which it was clearly differentiated by its greyish colour and firmer consistence. Its right portion assisted in forming the roof of the fourth ventricle. The growth had not invaded the peduncles of the cerebellum.

Histologically examined after hardening in chromic acid, this tumour presented in some respects the characters of glioma, but its predominant features were those of embryonic sarcoma.

TUMOUR OF THE BRAIN IN THE HORSE.

5. A well-nourished sixteen-year-old cart-horse.

History.—Had always appeared nervous. Six months before death was seen to carry the head inclined towards the left and the poll towards the right, as though the ear were diseased and the animal dreaded it being touched. When pushed sharply away from near side appeared about to fall, and indeed did sometimes fall. Had formerly been used for ploughing, but was latterly unable to walk steadily in the furrow. Had always been able to back, though latterly had difficulty in controlling hind limbs. Could lie down and rise without assistance. Urine and fæces were passed normally. Appetite good. Walked three miles to slaughterer's yard.

Autopsy showed brain to be normal except for presence of irregular grey body, about the size of half a walnut, between the cerebellum and medulla on left side. This body was partially blended with plexus choroides of fourth ventricle, was somewhat soft and greasy in consistence, and seemed on microscopic examination almost entirely formed of crystals of cholesterin. The cerebellum and medulla were slightly depressed for reception of the mass.

Messrs. T. and W. Fletcher's case, *Journ. Comp. Path. and Therap.*, 1891, p. 261.

BRAIN DISEASE—TUMOUR IN NEIGHBOURHOOD OF CEREBELLUM AND MEDULLA.

6. A Light Cavalry horse, seen 2nd August, 1886. No record of any previous brain disease.

State on Examination.—This animal staggered as if drunk, crossed its legs, its eyes had a vacant stare, the extremities were cold, mucous membranes pale, pulse rather small, 46, respiration and temperature normal.

Slight improvement during succeeding days. On the 10th symptoms returned as before; the horse fell when picking up some hay from the floor, and was lifted with difficulty.

On the 14th constant twitching of eyelids and hyperæsthesia of limbs; no improvement followed administration of atropine, which was substituted for strychnine previously given.

By the 24th the animal had become extremely nervous and frightened at the slightest sound; if startled it would twitch and quiver all over for some minutes, nearly falling in consequence; the lips and eyelids continued to tremble markedly for a long time afterwards; if

moved while limbs were trembling, it would blunder across its box, and if avoiding a fall would stand with the legs spread wide apart like props. Course variable until 20th September, when aggravation occurred. Killed on 23rd.

Autopsy.—Foramen lacerum basis cranii of right side almost double size of left. Adherent to the pia mater, lying behind the cerebellum and between it and the medulla, was an elongated, nodular, firm tumour, constricted at its centre, and studded with numerous glistening particles of cholesterin. Tumour bright red or pink on section, and very vascular, but showed no recent hæmorrhage and no degeneration or calcareous deposit. Pia mater congested throughout, especially behind the cerebellum. Brain normal.

Veterinary Captain Rutherford's case, *Journ. Comp. Path. and Therap.*, 1893, p. 72.



FIG. 23.—Position at rest.

CEREBRAL HÆMORRHAGE IN THE HORSE.

7. Eleven-year-old bay gelding, 16·3 hands, seen February 5th, 1896.

History.—Had shown "staggers" on day previous to examination, and been taken home. The head was carried to one side (see Fig. 23);

the animal seemed weak in its hind quarters, and threatened to fall if urged beyond a slow walk.

State on Examination.—Pulse 36, respiration 16, temperature $100\frac{1}{5}^{\circ}$ F. The neck was turned to the right side, it rotated on the head, and the chin was directed towards the middle line. Slight paralysis of muscles of right side; lip and nose turned towards the right; right nostril more dilated than left, especially when horse was excited. The skin of right nostril was more sensitive to pin pricks than that of left. The right eye was turned downwards, inwards, and forwards, was sensitive to light, and the fundus appeared normal. The left was turned upwards and outwards, the cornea appeared unduly convex and the whole eye prominent, the pupil was widely dilated, the retina was insensitive to light, the eye was immoveable and did not follow the light, and the membrana nictitans projected some distance over it. There was slight ptosis. The eyes were held in asymmetrical positions; the right seemed less under control than the left. Slight noises

FIG. 24.—Brain seen from left side. Cerebellar tumour shown lighter shaded.

seemed more alarming on left than on right side. The left ear was moved freely.

The hind limbs were moved with difficulty, the toes dragging along the ground; when turning the horse almost fell down. Noises, etc., especially on the left side, greatly aggravated the symptoms. The neck was then jerked away to the right, the head twisted on the neck until its sides were almost horizontal, the squinting increased, and the animal staggered, lifted and put down its feet spasmodically, and seemed about to fall.

Diagnosis.—Brain lesion. On account of sudden onset and extensive area involved is apparently due to hæmorrhage; the symptoms shown point to injury in the fourth ventricle, slightly to one side of middle line and almost directly over corpora quadrigemina.

Improvement was slow, and owing to the uncertainty of cure the animal was destroyed by intra-tracheal injection of one ounce of prussic acid. Death only occurred after seven or eight minutes.

Autopsy showed no important lesions in the thorax or abdomen.

On examining the brain a tumour the size of a hen's egg was found on the left lobe of the cerebellum (see Fig. 24), extending from the extreme outer margin of the left lobe to a point considerably beyond the middle line. It resembled in shape a peg-top; the point was thrust under the right lobe of the cerebellum; the body had replaced a large part of the left lobe of the cerebellum. In substance it was moderately firm, nodulated and encapsuled. Microscopical examination showed it to be a glioma. On cutting through the central line of the cerebellum a small hæmorrhage was found at the base above the fourth ventricle.

On dividing the brain by successive slices another hæmorrhage was

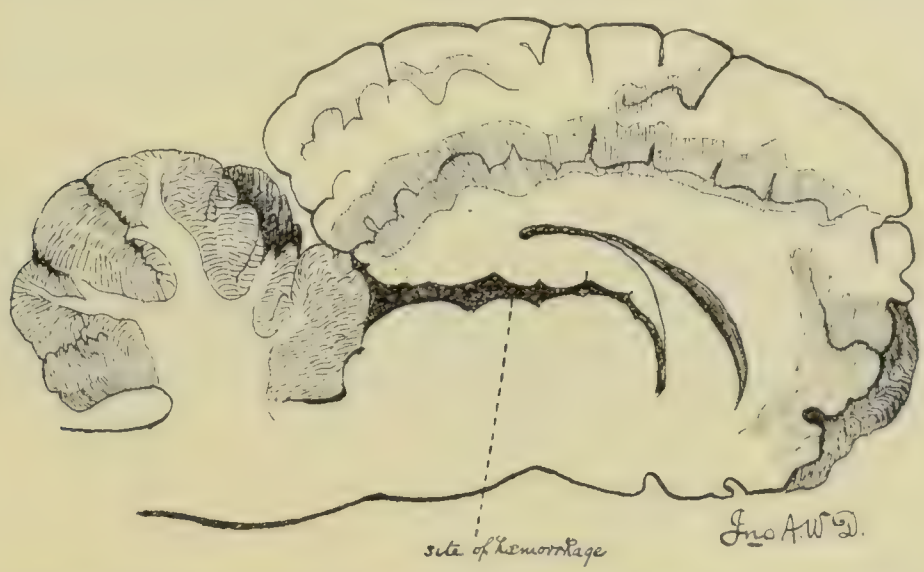

FIG. 25.—Vertical section through brain about half an inch to the right of the middle line.

found at the point indicated in the figure, about half an inch from the median commissure and in the right side. Hæmorrhage was slight, but the brain showed many small pink spots in this neighbourhood.

Note.—The inability to co-ordinate movement was probably due to the hæmorrhage at the base of the cerebellum, the facial lesions to the cerebral hæmorrhage. The part played by the tumour appeared to be secondary, as the growth had existed for a long time previously without producing symptoms.

Mr. Jno. A. W. Dollar's case, *Veterinarian*, 1896, p. 393.

CEREBRAL INJURY AND CHEYNE-STOKES RESPIRATION IN A HORSE.

8. A four-year-old brown gelding.

History.—When hunting, came down at a fence and pitched on its head; for the rest of the day it did not jump as well as usual. Coming home its action seemed exaggerated, the fore-legs being thrown outwards. It stopped as though to stale, but did not succeed; it then seemed to stagger and go wide behind. From this time it was led. On arrival in the stable it was amaurotic, and stood with the head against the wall.

State on Examination.—Seemed in some abdominal pain; lay on the

near side, bathed in perspiration, and struggled violently and incessantly. The pupil was dilated, pulse about 60. No hardness of gluteal muscles. One hour after hypodermic injection of morphia was sufficiently quiet for the catheter to be passed; urine moderate in quantity and normal in colour.

Diagnosis.—Brain injury, due either to fracture or blood-clot.

Two hours after first examination the breathing began to assume the Cheyne-Stokes character; for about twelve seconds respiration was suspended, the pulse meanwhile becoming slower and weaker, all movements of limbs suspended, and the animal appearing in a deep sleep; pulse about 70. This interval was followed by a feeble inspiration, followed by others of increasingly greater force, the sixth being the deepest and most marked. With each the pulse increased in frequency and force, as did movements of the limbs. The third period was marked by decline in amplitude of respirations until the sixth, which was almost imperceptible; the pulse decreased in strength, the number falling to 70, and all movements gradually ceasing. The second and third periods occupied twelve seconds.

The number of respirations in each period afterwards lessened, though still occupying the same time. The apnœal periods increased in duration to nearly twenty seconds. Movement of the fore-limb ceased, and the hind limb moved but slightly.

Six and a half hours after first examination the respiration assumed the form of a single deep gasp, followed by a deep expiration and one or more shallow movements with a long apnœal period. Death occurred seven hours after first examination.

Post-mortem Examination.—All internal organs healthy; some bruising on the frontal bone. A large blood-clot at the base of the medulla, on the right side, just over origin of the pneumogastric nerve. The whole of the pia mater was much injected.

Mr. F. W. Evans' case, *Journ. Comp. Path. and Therap.*, 1895, p. 83.

TUMOUR OF THE VERTEBRAL COLUMN.

9. Nine-year-old sheep-dog. Entered hospital on the 17th May, 1894.

A fortnight previously this dog, whose health had always been good, showed difficulty in walking, especially in moving the hind limbs, a difficulty which rapidly increased. One morning the animal was found paralysed in the hind limbs.

State on Examination.—Paralysis of the hind limbs was complete. If the animal was forced to move the legs were dragged along the ground. Sensation was not abolished, pricks with a pin causing struggling. Respiration and circulation were normal, appetite was good, and no difficulty in defecation or micturition had been noted. Temperature 37·8° C.

Rectal exploration threw no light on the case, and, in fact, nothing could be detected to account for the paralysis.

Treatment consisted in administering iodide of potassium in doses of 15 to 30 grains per day. Milk diet. No improvement. Death occurred on the 31st May.

Autopsy.—On the body of the first lumbar vertebra was found a hard spherical tumour, the size of an egg, measuring two and a quarter inches from before backwards, and two inches across. It chiefly occupied the right part of the vertebra, the transverse process of which it entirely surrounded, and was formed of two lobes, one developed on the right surface of the body of the vertebra, the other (which covered the inferior surface from one transverse process to the other) extended beyond the left transverse process, above which on the vertebra a large osteophyte was visible. The upper lobe of this tumour was in contact with the last dorsal vertebra, which it had thrust backward and somewhat to one side. Its lower lobe covered a portion of the lower surface of the second lumbar vertebra.

On exposing the spinal cord in the lumbo-sacral region the cha-

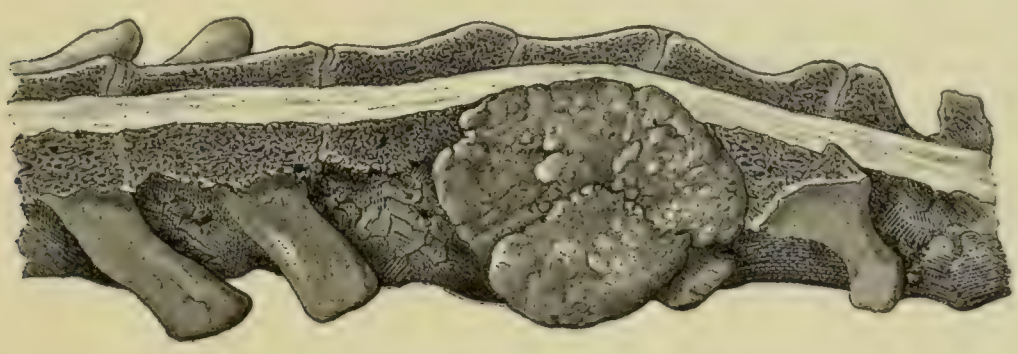

Fig. 26.—Sarcoma of the vertebral column.

racters and relationships of the tumour could be clearly made out. It formed in the spinal canal a distinctly marked prominence about one and a quarter inches in length, above which the spinal cord was compressed and reduced to half its normal thickness. Its consistence varied according to the point chosen: the part within the neural canal was relatively soft, yielded to pressure, and was easily divided with the point of the bistoury, but towards the centre the appearances were those of bony tissue.

On microscopic examination the tumour appeared formed of fusiform cells and tracts of osteoid tissue, pierced with branching cavities provided with canaliculi, and offering the appearance of osteoblasts.

B.—*EYE AND EAR.*

CANCER OF THE LOWER EYELID AND GLOBE OF THE EYE.

10. Eleven-year-old gelding. Entered hospital on the 18th July, 1898. Four months before the eyelids of the right eye were found to be glued together each morning by muco-pus. A veterinary surgeon who was consulted thought this due to simple conjunctivitis, and prescribed boric acid lotions. The discharge continued, the lower eyelid became thickened, vegetations developed on the conjunctiva, thrusting aside the eyelid and soon extending beyond the free margin.

The patient was first brought for examination in June, and was then regarded as suffering from granular conjunctivitis. The vegetations were removed with scissors, and the parts curetted. At this time the eye was still intact. A 1 per 2000 sublimate solution was prescribed as a collyrium.

The parts did not heal. Further vegetations developed and rapidly increased in size.

When the horse was left in hospital a reddish, flattened, transversely elongated tumour, somewhat resembling a strawberry, projected from between the eyelids. The upper lid remained soft and moveable; the lower, from which the tumour sprang, was everted. The globe of the eye was partly covered by the new growth, and to some extent pushed back into its cavity. The right side of the face was denuded of hair, and soiled by a purulent discharge.

Operation.—Once the animal was cast it was discovered that the tumour had invaded the globe of the eye. The cornea was opaque and perforated at two points. It therefore became necessary to remove the whole of the eye and a part of the lower eyelid, preserving as far as possible the skin covering the latter.

The orbital cavity was cleared out and filled with gauze, and the eyelids were brought together with three sutures. This dressing was removed next day, and treatment was afterwards confined to antiseptic injections.

The tumour was the size of a walnut, elongated in its transverse diameter, slightly flattened, rounded on the surface, and of firm consistence. The surface of sections appeared dry, but pressure caused filaments or little grains to exude, which were exclusively formed of epithelial cells.

The histological appearance of the tumour showed it to be an epithelioma of the pavement epithelium type. It was formed of a connective-tissue stroma and of epithelial cells disposed in lobules, which were massed closely together or united by tracts of the same character.

The animal left on the 1st March, but was brought back two months later for the application of an artificial eye of hardened india rubber. The tumour did not return.

MALIGNANT CARCINOMATOUS INTRA-ORBITAL GROWTH WITH DESTRUCTION OF THE EYE IN A COW.

11. A well-bred shorthorn cow; first seen March 20th, 1893.

History.—Two years before the animal had suffered from "chaff in the eye," followed by a cold. Nothing was done.

State on Examination.—The right eye was totally destroyed and its place occupied by a fungoid mass, which protruded two inches beyond the palpebral fissure. The surface of this mass was covered by a scab, on removing which the tumour appeared formed of broken-down tissue and new capillary vessels.

Despite antiseptic treatment the growth continued, and attained enormous dimensions. In June it was removed, and the wound dressed

with saturated solution of zinc sulphate. Improvement was only temporary; in a few weeks the eyelids and surrounding subcutaneous tissue became involved. During the succeeding weeks masses of extremely fœtid new growth were several times removed. Owing to continued spread of the growth the animal was at length killed.

Autopsy.—The orbit was occupied by a foul, stinking mass of broken-up tissue of a dirty brown colour, the eyelids were enormously thickened, and the eyelashes replaced by a border of cicatricial tissue. The extruding mass measured five and a half inches in diameter, and the surrounding swelling about nine inches. Beneath the skin was a layer several inches thick of repulsively smelling necrosed new growth, presenting the characters of carcinoma. The cranial bones were absolutely healthy; the growth appeared to have originated either in the eyeball itself or from the peri-orbitale.

No visceral metastasis or septic infection was noted on *post-mortem*, and the cow's continued good health until a fortnight before slaughter contra-indicated such a condition.

Microscopical examination confirmed the diagnosis of carcinoma.

Mr. Breakall's case, described by Prof. McFadyean, *Journ. Comp. Path. and Therap.*, 1893, p. 365.

TRAUMATIC CATARACT.

12. Four-year-old English terrier. Brought for examination on the 29th July, 1897.

Two days before this animal while playing had torn the right eye on a piece of iron wire projecting from a grating. The wound was treated with dilute acetate of lead lotion.

At the time of our examination the eye was closed, weeping, and very sensitive. After applying cocaine we were able to estimate the gravity of the injury. The cornea was perforated a little below its centre by a narrow opening, from which escaped aqueous humour. The margins of this opening were fairly regular, and slightly swollen. In the lower portion of the anterior chamber was a reddish hæmorrhagic deposit, but no foreign body was present.

Treatment.—Careful disinfection of the cornea, conjunctiva, and eyelids by warm creolin solutions, and frequent instillation into the eye of a warm solution composed as follows:

Creolin	50 minims.
Boiled water	1 pint.

The patient was brought back each week. The extravasated blood in the anterior chamber gradually became reabsorbed. In spite of considerable granulation around the margins of the perforation in the cornea healing occurred rapidly, and without acute complications. The opacity of the cornea and wound gradually diminished, and finally completely disappeared; but, in proportion as the cornea grew clearer, we were able to detect another change in the deeper portion of the eye, viz. the formation of a cataract. This change proceeded rapidly. Three months after its appearance vision on this side was destroyed.

By the following May there only remained a very trifling depression

in the cornea, and even here the parts were as transparent as other portions of the eye.

CATARACT—OPERATION.

13. Six-year-old poodle affected with double cataract. Left in hospital 16th April, 1898.

The first signs of disease in the eye had occurred two years before. The lens of each eye gradually became opaque, though that of the left eye was more rapidly affected than the right.

State on Entry.—The lens of the left eye was completely opaque. On the whitish ground formed by the lens a few striæ, arranged in the shape of a star, could be seen, and towards the centre several little greyish spots. The right lens was opaque throughout, but the opacity was a little less marked and more uniform than in the left lens.

Vision was completely abolished. In unfamiliar spots the animal continually ran against obstacles.

Treatment.—We were asked to operate, and decided to deal first with the left eye. For three days the eye was prepared by bathing with warm solutions of 3 per cent. boric acid, and with 1 in 3000 sublimate.

On the 19th the animal was anæsthetised with atropomorphine and chloroform. The operation chosen was that in which the lens is depressed, and was performed by the usual method. Trifling hæmorrhage occurred under the conjunctiva at the point of puncture, and a little blood also passed into the anterior chamber of the eye. During the night the eye was several times fomented with wadding saturated in warm boric solution. The animal's kennel was covered so as to keep it in semi-darkness. The patient readily took milk and a little meat.

The same treatment was continued during the following days: a little opacity appeared in the anterior chamber, but in a week it had entirely disappeared, together with the effused blood and the ecchymosis under the conjunctiva. Even at this stage there was marked improvement. The dog saw sufficiently to choose its path and avoid obstacles. It had no difficulty or hesitation in entering its kennel, whilst previous to operation it always struck against the step in front.

Remark.—The observations of Berlin, Möller, Randolph, and Contejean show that in the dog accommodation is soon restored. In practice it is well to restrict operation to discission for soft cataracts, and to depression for others. Without doubt these methods are very inferior to extraction, but they have the double advantage of being less dangerous and capable of performance by most practitioners.

SYMBIOTIC ACARIASIS AND ECZEMA OF THE EAR.

14. Six-year-old Havanese bitch, entered hospital 30th December, 1898.

History.—During April, 1898, this bitch, which lived in its owner's rooms, suddenly presented a concourse of symptoms apparently due to

some nervous affection. In addition to restlessness, loss of appetite, and depression, it showed at varying intervals paroxysms of trembling and slight rigidity of the body muscles.

These symptoms gradually became more marked. One morning the patient was seen to turn in circles to the right, the head inclined towards the same side and slightly depressed.

A specialist who was consulted regarded the symptoms as due to a brain lesion. He prescribed friction with antimonial ointment over the upper part of the neck and base of the brain. This treatment giving no result he passed a seton behind the head. In spite of the suppuration produced by leaving the seton in position for a month the disturbance persisted.

Towards the end of August the animal one evening had an epileptiform attack, the head being markedly turned towards the right, and the animal falling on the same side.

Three weeks before entering hospital it had another more violent attack, and again fell on the right side. Bromide of potassium was prescribed. On the 29th December a further epileptiform attack occurred similar to the preceding. On the evening of the next day the bitch was sent to the School.

State on Examination.—The patient held the head inclined towards the right side, was depressed, and took no notice of what passed around it. Although it had suffered from these attacks for several months it was still in fairly good condition. There was no rigidity of muscle and no interference with movement. At times the animal shook its ears and scratched them with the hind limbs. It had scarcely been placed in a kennel before it was taken with a fit. It fell forwards, the head being turned towards the right side, its long axis inclined downwards and towards the left, the right temporo-auricular region resting on the straw; howled loudly, and made convulsive circular movements from left to right around the head, which acted as a pivot. This attack lasted for three minutes. The animal rose, remained stupid for a few moments, and then resumed its former appearance.

During the night it ate some fragments of meat given by hand. Five minutes later it was seized with nausea and vomiting attacks.

At next day's visit I made inquiries as to the animal's history. Examining the interior of the ears I noted at the entrance to the auditory meatus an abundant deposit of brownish wax, which I directed to be microscopically examined, with the result that it was found to contain numerous symbiotes (*Symbiotes ecaudatus*, var. *canis*).

Treatment.—Washing out of the ears with soap, cleansing of the external meatus, drying with wadding, injection of 1 per cent. solution of sulphide of potash, and light friction around the base of the ear, so as to favour the penetration of the liquid, drying of the entrance to the meatus and application of a few drops of balsam of Peru. The injection of sulphide of potash solution and the after application of Peruvian balsam were repeated every day until the 15th January.

On the 6th the patient was less depressed; it took a little nourishment. The inner surface of the fore-limbs showed an eczematous eruption, accompanied by severe itching. After clipping away the hair

the diseased skin was disinfected with warm creolin solution and powdered with starch.

On the 8th the disturbance due to the acari was markedly diminished, but the two eczematous patches on the inner surface of the fore-limbs were transformed into wounds, which the animal incessantly licked and gnawed. The discharging surfaces were disinfected and a cotton-wool dressing applied, covering the limbs as high as the shoulder.

Next morning the dressings were found torn. Fresh ones were applied, which were left undisturbed for three days, when they were renewed.

After the 15th the animal showed no further epileptiform symptoms nor digestive trouble.

On the 20th the wound on the left leg was dry; a portion of that on the right was still moist, but by the 27th it had healed.

On the 3rd February the animal was cured both of the acariasis and of the eczema.

Remark.—Acariasis of the ear—the pseudo-epilepsy seen in packs—occurs with some frequency in dogs kept in living rooms. Seldom a year passes without our seeing cases. In that just described the method of contagion remained doubtful. According to the owner's statement the animal was very carefully looked after and never came near other dogs.

C.—*NOSE AND NASAL CAVITIES.*

NECROSIS OF THE NASAL SEPTUM.

15. Seven-year-old entire horse. Entered hospital 29th October, 1894.

Two months before the animal had received a kick on the forehead. The part became swollen, respiration difficult and noisy, and discharge occurred from both nostrils.

State on Entry.—The passage of air through the nose was obstructed; even at a distance a roaring sound could be heard. The face was deformed; over the lower portion of the nasal bones, and extending as far as their extremity, was a swelling which was painful on pressure and equally marked on either side of the median line. Both nostrils discharged a little purulent liquid. On the septum, near the entrance to the nasal cavities, and on either side, was a narrow wound with hardened reddish margins, forming the entrance to a sinus about three inches deep. Higher up—towards the roof of the cavity and on the septum—could be distinguished an oval prominence, elongated in the direction of the long axis of the head, formed by separation of the mucous membrane from the subjacent tissues. Pressure with the finger caused a discharge of greyish pus from the sinus. The submaxillary glands were swollen and hard, the condition being rather more marked on the right than on the left side.

Diagnosis.—Partial necrosis of the nasal septum. As the animal was useless for work, on account of the difficulty in breathing, we were asked to perform tracheotomy.

Treatment.—The nasal bone was trephined over the most prominent portion of the swelling and along the median line, disclosing a fragment of necrotic tissue on the cartilaginous septum. The opening was enlarged, the edges rounded off, and the necrosed cartilage removed by curetting. The wound thus produced was washed out with carbolic solution, and its margins touched with tincture of iodine. A gauze drain was passed into each of the nasal cavities.

During the next few days the wound was cleansed night and morning with 1 per cent. creolin solution, and the drains occasionally renewed.

Treatment ceased on the 1st December. The animal returned to work. Cure became complete after a time. Respiration was only slightly interfered with, the diminution in size of the nasal cavities opposite the old necrotic centre being trifling.

NECROSIS OF THE CARTILAGE OF THE LEFT NOSTRIL.

16. A nine-year-old gelding brought for examination on the 20th October, 1895, with the following history: About two months ago the animal, while in the same stable, had been bitten on the nose by another horse. Treated with carbolic lotion the cutaneous wound

FIG. 27.—Necrosis of the nasal cartilage.

healed rapidly, but the inner part of the nose became swollen and a more or less abundant discharge continued.

State on Examination—A little purulent discharge ran from the lower portion of the left nostril. The inner wing of the nostril throughout its entire extent—but especially towards its upper part—

was swollen and indurated. On examining the nasal cavity the swelling was seen to be limited to the anterior portion, that is the part corresponding to the cartilaginous plate. The skin covering this, and a narrow layer of the pituitary membrane, were swollen, thickened, and somewhat prominent. At the margin between the middle and upper thirds of the upper wing of the nostril appeared a fungous, reddish, soft mass of granulations, from which pus discharged when the lower part of the swollen nostril was pressed with the finger. The left submaxillary gland contained a somewhat hard swelling the size of a small nut, moveable under the skin, but adherent to the deeper seated tissues. In the right nasal cavity the pituitary membrane was neither swollen nor injected, and the internal wing of the nostril was of normal flexibility.

Having cast the animal on the right side probing revealed the presence under the granulations of an open sinus about one and a quarter inches in depth, running obliquely downwards and inwards. This sinus was laid open throughout its entire extent, and the walls swabbed with tincture of iodine, by means of a probe covered with wadding.

The patient, which continued to work, was only dressed very irregularly. In consequence it became necessary to expose the parts a second time. The swelling of the nostril and suppuration greatly diminished, but recovery was not complete until after four months.

Remarks.—Necrosis of the nasal cartilage marked by muco-purulent discharge and enlargement of the submaxillary gland of the corresponding side, may at first awaken suspicion of glanders. Differential diagnosis, however, is easy without recourse to mallein. On examining the nasal cavity the inner wing of the nostril shows a hard, circumscribed swelling, which usually occupies the entire extent of the wing; and a fistula, whence on pressure over the swollen area greyish, ill-formed pus, sometimes streaked with blood, escapes. The swollen parts are often rough, prominent, or folded. Fig. 27 shows the appearances in a case brought for examination during September last as suspected of glanders. The inner wing of the right nostril showed throughout its entire extent a considerable, sharply circumscribed, rounded swelling, most extensive below, where it was irregular and exhibited several narrow folds. From its posterior border projected a mass of soft, bleeding granulations, which masked the sinuous tract.

SEBACEOUS CYSTS IN THE FALSE NOSTRILS.

17. A seven-year-old mare, left in hospital 1st February, 1898.

Was suffering from sebaceous cysts of the false nostrils, which first appeared several years before. By their progressive growth these tumours had finally interfered with breathing; the mare soon lost breath, and made a snorting noise during work. In September, 1897, the swellings were punctured, their contents evacuated, and the interior washed with an antiseptic solution, but they soon formed again.

On entering hospital this mare showed in each false nostril, an inch or two from the external opening of the nose, a spherical, yielding,

non-fluctuating, cool, painless swelling; the right was rather larger than the left and the size of a hen's egg.

On the 2nd February, after washing and disinfecting the skin the cysts were punctured with a trocar, giving exit to a greyish, thick, granular material. The cavities were injected with pure tincture of iodine, and after manipulation the excess of injected fluid was removed. On the following days the parts showed inflammatory swelling, particularly on the left side. On the 15th February the left cyst had almost completely disappeared, but the right had resumed its former dimensions. Ablation was therefore decided on.

On the 18th February the mare was cast on Daviau's table. The parts having been prepared, two curved incisions were made enclosing an elliptical piece of skin, three quarters of an inch wide at the centre, which was removed, together with the wall of the cyst. The deep portion of the latter had to be left, dissection being a delicate matter, and the animal struggling violently. The interior was swabbed out with a tampon saturated with 10 per cent. chloride of zinc solution. The margins of the wound were brought together over a drainage-tube. During the following days weak warm carbolic solution was injected.

On the sixth day the drainage-tube was removed, and the parts treated as an open wound. A week later complete healing had occurred.

CHRONIC INFLAMMATION AND NECROSIS OF THE POSTERIOR (MAXILLARY) TURBINATED BONE.

18. Four-year-old mare, suffering from a tumour of the left nasal cavity.

History.—Seven or eight months ago the left side of the animal's face showed a swelling, which gradually increased; discharge occurred from the left nostril; some time later breathing became disturbed and snoring, and during movement a loud nasal roaring sound was produced.

M. Audebert, veterinary surgeon at Vailly (Cher), who diagnosed the existence of a tumour in the left nasal cavity, sent the animal to me on the 5th February, 1899.

State on Examination.—Animal moderately well nourished. The left side of the face showed a diffuse, rather prominent, hard swelling, slightly painful on percussion. From the left nostril a greyish, mucopurulent discharge continually escaped. On examining the entrance to the nostril nothing abnormal could be seen, but a short distance within a swelling could be felt which appeared formed by the enlarged maxillary turbinated bone. The submaxillary glands were slightly swollen. Breathing was markedly embarrassed. At a walk the mare made a loud roaring sound.

Treatment.—Ablation of the tumour. On the 9th February the patient was cast on the right side. The parts having been prepared, an incision an inch and a half in length was made over the left false nostril in the angle formed by the nasal and premaxillary bones. A portion of the swelling could then be examined with the finger, but extraction by this orifice appeared impossible.

The left nasal cavity was therefore trephined, an incision about three quarters of an inch long being made opposite the centre of the nasal bone; at each end two circular trephine openings were made, and the intervening portion of osseous tissue removed with scissors. It then became evident that the anterior part of the maxillary turbinated bone was markedly hypertrophied. On being trephined the inferior maxillary sinus was found healthy. The anterior part of the diseased turbinated bone was first removed with strong forceps through the lower opening, the remainder being excised through the nasal opening. The nasal cavity and sinus were plugged with gauze.

The mare was returned to her box. Temperature 38·6° C. For about half an hour blood dripped from the left nostril.

All the extirpated portion of the turbinated bone was inflamed, thickened, and violet in colour; it measured four inches in length and two to two and a quarter inches in diameter. Its upper half was hard and for the most part ossified. Towards the centre it appeared necrotic, and contained a cavity filled with caseous pus; the lower portion formed a kind of ovoid tumour measuring two inches in length and an inch and a half in diameter, firm and homogeneous in consistence, and of a whitish-red tint on section. In the lower portion of the turbinated bone the histological characters were those of inflammatory hypertrophy, with numerous small osseous tracts dispersed through the newly-formed fibrous tissue.

On the 10th the tampons were removed, and the nasal cavity washed out with warm boric solution, which brought away clots and a few fragments of necrotic tissue. General condition and appetite excellent. Temperature 38·5° C. The nasal cavity was left open. During the night it was washed out with boric solution.

On the 11th the expired air had the smell peculiar to caries. The boric injections were alternated with creolin solution. Temperature 38·4° C.

From the 12th to the 16th similar treatment. Discharge remained somewhat free. The submaxillary glands increased in size. Temperature normal.

On the 17th the pus was less abundant and less fœtid. The warm creolin solution was continued.

On the two following days the patient showed symptoms pointing to mechanical pneumonia. The temperature was 40·2° C.; the respiration 48 per minute, whilst the pulse was only 44.

On the 20th discharge was less abundant, and the general condition had greatly improved.

On the 21st all unfavourable symptoms had disappeared.

From the 22nd to the 27th the injections were continued; suppuration was trifling. The opening in the maxillary sinus had entirely closed; that in the nasal bone was still open, but had greatly contracted. The discharge from the nostril had considerably diminished.

From the 28th February to the 5th March treatment continued the same. The opening in the nasal bone had then nearly closed. Discharge was very trifling. Expiration and inspiration were normal, and scarcely any interference with inspiration could be detected.

On the 6th March the mare, which was on the way to complete recovery, was returned home.

TUMOURS IN THE NASAL CAVITIES.

19. Five-year-old terrier dog. Left in hospital on the 14th March, 1896.

About two months before deformity of the face had been noticed. On the right cheek, almost midway between the eye and point of the nose, was a circumscribed, slightly painful swelling. A muco-purulent discharge, streaked with blood, ran from the right nostril. Mastication seemed difficult; the dog ate slowly, and frequently attempted to scratch the nose. The swelling gradually became more marked.

State on Entry.—The right side of the face showed a swelling as large as an egg, apparently developed in the superior maxillary bone; over its centre the bone was destroyed, and throughout the rest of its extent the external table appeared elevated.

The tumour extended above as high as the eye, which however appeared unaffected; posteriorly as far as the lower maxilla; it had invaded the mouth and destroyed the right side of the hard palate; several loose molars were surrounded by the new growth. The buccal portion of the tumour was in most places fairly firm, but showed local ulcerations.

Autopsy.—With the exception of its ends the right superior maxilla was almost destroyed. The tumour extended about one eighth of an inch above the level of the bone. After sawing through the centre of the head the nasal septum was seen to be thrust towards the left by the growth, which had destroyed the mucous membrane and turbinated bones, and had completely filled the right nasal cavity. Within the mouth it extended backwards as far as the base of the cranium; the anterior portion of the zygomatic and palatine bones and the body of the superior maxilla, together with the right half of the hard palate, were destroyed. Four molars (the crowns of which retained their white colour) were only held in position by the new growth. The anterior wall of the orbital cavity had disappeared, and the fibrous membrane lining it had been thrust back, though it remained intact.

The buccal and maxillary portions of the tumour were somewhat firm; the remainder was soft and friable. It was of an epithelial nature, formed of a connective-tissue stroma containing irregular cavities filled with small polyhedral cells. At certain points these cells tended to assume a cylindrical form, and to run at right angles to the stroma. In certain alveoli the central cells were large, contained no nuclei, and were arranged in epidermal nests.

20. Four-year-old sheep-dog. Brought for examination on the 15th December, 1892.

Had been ill for eight months. The first symptoms consisted of difficulty in breathing, frequent sneezing attacks, and discharge from both nostrils. The animal scratched the nose with its paw, as if attempting to remove some foreign body from the nostrils. Though

previously fond of the water and a very good swimmer, it now avoided entering or soon returned, breathing with difficulty and through the mouth.

The face gradually became deformed, the anterior wall of the nasal cavities projected, especially on the left side, the skin became ulcerated over the swelling, and the tumour finally appeared externally.

When the dog was brought here a blood-stained discharge ran from both nostrils. The nasal cavities were obstructed. Over the middle of the nose was a projecting, reddish, bleeding tumour, which had perforated the bones and was surrounded by a swollen depilated zone.

Autopsy.—Both nasal cavities were entirely filled by the tumour, which was adherent over a large surface to the mucous membrane covering the floor of these cavities, whence it appeared to have originated. It had destroyed the nasal septum and the turbinated bones. Below it had advanced close to the nostrils; posteriorly it appeared bilobed, the lower portion being attached to the side of the palate, the upper portion extending towards the entrance to the sinuses, which were filled with ill-smelling pus.

The tumour was greyish, and in places somewhat reddish in colour.

Fig. 28.—Sarcoma of the nose.

Its tissue was very soft and friable, and contained large numbers of vessels.

In the posterior lobe of the left lung was a tumour the size of a hazel-nut, projecting slightly above the surface. Its tissue was friable and reddish, resembling that of the new growth in the nose.

On microscopical examination this tumour appeared almost entirely formed of round-cells and of vessels; the cells were of small size and contained a strongly-marked nucleus, but little protoplasm; in places a fine reticulated stroma could be distinguished. Most of the sections showed throughout their extent the histological characters of encephaloid sarcoma.

21. Five-year-old bull-dog. Brought for examination on the 7th January, 1893.

Had been ill for ten months. At first the passage of air through the nose seemed obstructed; the animal sneezed, showed discharge, and continually scratched the nose, the base of which gradually became swollen. Ulcers next formed at two points, discharged a sticky, greenish pus, and gradually increased in size, the exposed tissues projecting prominently and forming mushroom-like growths. The end of the nose became twisted towards the left. A considerable swelling, more marked on the right than on the left, appeared between the eyes over the region of the sinuses, and on opening the mouth the hard palate was seen to be affected, the mucous membrane being perforated in two places.

Autopsy.—The tumour filled the nasal cavities and three fourths of the frontal sinuses. The palatine plate of the superior maxilla and the body of the palatine bone were destroyed for a distance of one and a half inches in the longitudinal and three quarters of an inch in the transverse direction. At the back, between the sphenoid and pterygoid and the wing of the palatine bones, the tumour formed a thick, transverse prominence which projected into the pharynx. On either side of the median line of the face, the nasal bone, the upper portion of the maxilla, and the internal surface of the frontal bone were destroyed. At certain points the bony tissue enclosing this area was penetrated by the new growth. In others, however, the two were simply in juxtaposition.

The nasal septum was almost entirely destroyed. In front only a fragment three quarters of an inch in length and one sixteenth of an inch in depth remained, fixed to the intermaxillary bone, and behind a sickle-shaped piece attached to the vomer and ethmoid. The turbinated bones were also destroyed, the only vestiges remaining being composed of little parchment-like lamellæ surrounded by the tumour. The ethmoid cells were only represented by fragments of their base.

The tumour had originated in the pituitary membrane lining the floor of the nasal cavities. Thence it had extended towards the base of these cavities, next into the sinuses, whence it spread to neighbouring tissues, radiating in all directions, and perforating the bony partition separating the nose from the mouth and the mucous membrane of the palate.

The tissue of this tumour was greyish, very friable, and contained numerous small vessels. Histologically it showed the same characters as that of the tumour in Case 15. It was, in fact, a round-celled sarcoma.

22. A five-year-old spaniel, which had been ill for six months. Brought for examination on the 13th February, 1894.

Difficulty in breathing was the first symptom noted, followed soon afterwards by double-sided purulent discharge, sometimes streaked with blood, and swelling of the nose, particularly towards the left lower part. This swelling rapidly increased. During the early part of February the disease made rapid progress. The swelling extended to the

entire nasal region, towards the centre of which a second sinus opened, and suppuration became abundant.

On examining the patient symptoms were seen analogous to those noted in the preceding case, except that deformity of the hard palate and nasal lesions were more marked on the left than on the right side.

Autopsy.—The left nasal cavity was completely obstructed by the tumour, the posterior portion of which extended as far as the entrance to the pharynx and into the sinuses. The nasal bone, upper portion of the maxilla, and internal table of the frontal bone were at points thinned and perforated. The nasal septum and ethmoid cells were partially destroyed. In the left cavity the tumour had not advanced so far posteriorly and upwardly. As in Case 16, the new growth appeared to have started in the mucous membrane of the lower wall of the nasal fossa.

On section the tumour appeared whitish-grey and fairly vascular. Microscopical examination showed it to consist of sarcomatous and mucous tissue (myxo-sarcoma).

23. Three-year-old setter, brought for examination on the 6th August, 1894.

A year before the animal had been attacked with sneezing fits, which became more and more frequent. Greyish muco-pus, occasionally streaked with blood, ran from the nose. Some months later the face began to swell, and gradually became more deformed. Finally, the skin ulcerated over the most prominent part of the swelling. For a fortnight previous to entry blood-stained pus escaped in considerable quantities by the wound at this point.

When brought here the animal was very thin and appeared in severe pain. The deformity of the face and the existence in this region of a sinuous wound discharging greyish pus clearly pointed to the nature of the affection. On the examiner attempting to touch the wound the animal threatened to bite. The nasal cavities were completely obstructed, and breathing was carried on through the mouth.

Post-mortem Examination.—On being opened along the middle line the nasal cavities were found entirely filled with the tumour. The sinuses were invaded; one portion of the septum, together with the turbinated bones and ethmoid cells, had disappeared. In front the tumour extended to the nostrils, behind to the pharynx. The sinuses contained sticky, greyish, offensive pus.

This tumour, like the two preceding, appears to have originated from the pituitary membrane lining the floor of the nasal cavities. The macroscopic and microscopic characters were similar to those of the new growth in Case 17.

Remarks.—The majority of tumours of the nasal cavities in the dog are myxomatous polypi, which tend to undergo conversion into sarcomata. When recent they can be removed through an incision in the nasal bone and a permanent cure effected, but, as a general rule, disease has made such progress before the patients are submitted to examination that intervention is entirely useless.

PURULENT INFLAMMATION OF THE SINUSES—MENINGO-ENCEPHALITIS.

24. Seven-year-old mare, affected with double-sided purulent inflammation of the sinuses. Left in hospital on the 2nd January, 1899.

The left inferior maxillary and frontal sinuses had been trephined, despite which the affection of the sinuses became complicated with brain disease. The mare was sent to the School on the evening of the 2nd January, and had travelled a distance of five miles at a walking pace.

State on Examination.—The trephine openings in the left frontal and inferior maxillary sinuses were still open; their margins were soiled with pus, and from both nostrils escaped a purulent ill-smelling discharge, more abundant on the left than on the right side. The left submaxillary gland was swollen, lobulated, and the size of a small nut. When placed in a box the mare appeared exceedingly depressed. The eyelids were swollen and half closed, and vision was interfered with, principally on the right side. During the night the animal took only a little mash.

Next morning the condition was more serious. Prostration was even more marked than on the preceding evening. The mare moved with great reluctance; the gait was slow and uncertain, movements were irregular, and the limbs became flexed at every step. When returned to its box the animal suddenly showed alarming symptoms without any apparent cause; it rolled about, recovered itself, and leaned against the wall with the front limbs crossed. In about ten minutes it made a few more uncertain steps, again dropped back against the wall and fell heavily, stretching itself on the left side, and showing great excitement, which was succeeded by a period of coma. At this time the temperature was 39·2° C.; respirations 22; pulse 78 per minute.

For some hours phases of excitement alternated with periods of coma. During the former the animal sometimes lay on its chest, the front of the head pressed on the ground; sometimes completely on its side, the head and limbs being constantly in motion.

Treatment.—Hypodermic injection of morphine and chloral enemata. During the afternoon the coma was only interrupted by passing fits of excitement. Respiration and circulation became more and more rapid, the temperature rose to 39·8° C. The animal died during the night.

Autopsy.—The abdominal viscera showed nothing abnormal. The right lung, however, contained two small centres resulting from chronic pneumonia.

The head was detached from the body and sawn through longitudinally near the middle line. On examining the sinuses the mucous membrane was found inflamed, thickened, and covered with yellowish-grey putrid pus.

In the antero-inferior part of the cranium the meninges were inflamed, infiltrated, thickened, and bathed in a sero-purulent exudate

The corresponding surface of the brain was injected and covered with a similar fluid, in which streptococci were discovered on bacteriological examination.

Both guttural pouches were inflamed, that of the left side being full of blood-stained offensive pus.

D.—*LIPS.—CHEEK.—JAWS.—MOUTH.—PHARYNX.*

PSEUDO-CANCROID OF THE LIP.

25. Four-year-old female cat, brought for examination on the 21st April, 1894.

Had been ill for a year. On the centre of the free border of the upper lip this cat had shown a little flattened, hard tumour, which afterwards became ulcerated. The wound gradually extended on either side as far as the labial commissures, and above to the nostrils.

It was of a regular, concave shape. The base exhibited a thin indurated layer. The surface was reddish or greyish in colour, according to the point chosen. On examining it more closely the red areas were seen to be regular, moveable, and to resemble cicatrices; whilst the greyish points were formed by little crusts covering shallow depressions, apparently caused by extension of the lesion.

The ulcer was sharply defined, and the skin marginating it covered with hair. Where it joined the mucous membrane there was neither swelling nor induration. The incisor and both canine teeth were exposed.

On either side of the upper part of the neck were two hard inflamed lymphatic glands the size of large peas.

A particularly interesting feature was the existence at the base of the dewclaw of each front foot of an ulcerated wound showing the same appearances as that on the upper lip, and only extending to the papillary layer of the skin. The greater portion of the surface was rose-red, though greyish points could be seen similar to those on the ulcer of the lip. The wound on the right paw measured a little more than three quarters of an inch in length, and about three eighths of an inch in width. It was crescent-shaped, and surrounded the paw. That on the left paw was slightly smaller, but situated at exactly the same point.

These two ulcers occupied the part which cats are in the habit of licking with the tongue when cleaning themselves. They were evidently developed by auto-inoculation, in consequence of repeated contact between the skin and the labial ulcer.

The patient was not left in hospital. We prescribed dressing the ulcers with a 20 per cent. solution of iodine.

The animal was not brought back.

26. Six-year-old male cat, left in hospital on the 20th May, 1895.

Two years before had suffered from an ulcer of the lip. Recovery occurred spontaneously after some months. On the 15th April, however, a new ulcer was noted.

This growth, situated on the upper lip, slightly to the right of the middle line, was about a quarter of an inch in length, and one eighth inch in depth, its margin appearing as though cleanly punched out; its base was slightly hardened, and its surface covered with a thin, greyish, dry, adherent crust. The right submaxillary gland was slightly swollen.

Treatment.—The parts were dressed daily with a 4 per cent. solution of chlorate of potash, and every third or fourth day were swabbed with a 10 per cent. solution of methylene blue (methylene blue, ten parts; alcohol, fifty parts; glycerine, fifty parts).

The animal was very gentle, and made no opposition to the dressing. By the beginning of June the slight induration about the base of the ulcer had disappeared, the extremities and the cutaneous and mucous margins were seen to be healing, while the submaxillary glands were less hard.

Treatment was stopped on the 15th June. Ten days later recovery was complete, except for the notch produced by ulceration.

27. Two-year-old female cat, brought for examination on the 19th April, 1896.

Was suffering from ulcer of the lip. This ulcer had developed on the right side of the upper lip, causing a crescent-shaped loss of substance, about three eighths of an inch in depth at its centre, and extending as far as the right labial commissure. It was very sharply defined, its base a little indurated, but not painful on pressure; the surface was greyish in colour, and marginated by a narrow, pale red line; examined more closely it appeared stippled with a large number of minute depressions.

On examining the jaw the right submaxillary gland was found inflamed and multilobular.

Treatment consisted in dressing the ulcer with methylene blue.

This animal was not brought back.

28. Three-year-old female cat, left in hospital 4th September, 1897.

Suffering from labial ulcer. In October, 1896, it had been brought here on account of a similar lesion, which, however, healed in a few weeks.

On examination a large superficial ulcer was seen covering all the left side of the upper lip; the lower lip of the same side close to the commissure was also invaded over a surface three eighths of an inch in length.

Treatment.—Daily application of methylene blue solution.

Up to the 10th there was no change, but during the following days fine granulations appeared.

On the 30th the ulcer had healed.

Remarks.—In the dog the lips, especially the upper, are sometimes the seat of ulcers of an apparently cancroid nature which, however, are not in reality due to new growths but probably to lesions resembling labial ulcer in the cat.

In a four-year-old watch-dog, which showed an ulcer about one and a half inches in length near the centre of the upper lip with inflammation of a lymphatic gland in the neck, the base and margins of the wound were hardened, and the microscopical characters of the lesion were found to be as follows :—On section of a fragment removed from the ulcer and cut perpendicularly to the surface no epithelial new formation could be detected. At a certain point in these sections the cells were necrotic and could not be stained with carmine, though cells in the neighbouring (healthy) parts absorbed it readily.

PAPILLARY SARCOMA OF THE CHEEK.

29. Six-year-old entire horse, left in hospital on the 30th December, 1896.

The disease first appeared as a kind of wart growing from behind the left labial commissure. Other tumours soon appeared and covered a considerable surface.

State on Examination.—The tumour occupied the greater portion of the cheek. It extended backwards from the commissure of the lips to within about four inches of the ramus of the lower jaw, upwards as high as the forehead, and downwards into the intermaxillary space. According to the point inspected its thickness varied between three quarters of an inch and two inches. It was sharply defined at its periphery, where it met the healthy skin, and was formed of two distinct masses separated by a narrow depression running parallel to the lower row of teeth, and somewhat obliquely from behind forwards and downwards. The shape of both masses was irregular; their surface rounded and bleeding. The interspace was filled with fœtid pus. The submaxillary gland was slightly swollen, hard, insensitive, and adherent to the deeper structures, but not to the skin.

The sheath also showed warty growths, the largest the size of a hen's egg.

Treatment.—On the 31st December the horse was cast on Daviau's table, the tumour removed with the knife, and the base carefully curetted. Hæmorrhage was checked by the cautery.

On section the morbid tissue was greyish, firm, and contained little fluid. Histologically it resembled fasciculated sarcoma. It was composed of large fusiform cells containing one or several nuclei, and grouped in bundles running in various directions.

During the next few days the eschar became detached. The wound was afterwards touched with dilute tincture of iodine and covered with tannin. On the 12th January, when the animal left hospital, the greater portion of the wound was healed.

When seen again two months later the cicatrix was flat, and there had been no return.

FRACTURE OF THE LOWER JAW.

30. Eight-month-old poodle, left in hospital 16th April, 1892.

Whilst playing in the stable it was kicked, and on being examined

the jaw was seen to be pendent and blood to be running from the mouth. It was immediately brought to the School for treatment.

State on Examination.—The mouth was open, and discharged blood-stained saliva. Manipulation caused pain, shown by the animal yelping. Slight movement of the lower jaw produced crepitation; the bone was fractured through its neck. The left branch was also fractured under the masseter muscle. The jaw was swollen and very painful, and traumatic fever pronounced. The pulse was 120; respirations 34; and temperature 39·8° C.

Treatment.—A dressing formed of layers of linen smeared with pitch was applied. This bandage covered the whole of the lower jaw, and a few turns were passed behind the nape of the neck. The fractured bone was also kept in position by a band of tarlatan rolled round the jaws and neck, several of the turns crossing under the larynx. The patient was spoon-fed with liquid food. The mouth was washed out with boric lotion.

The dressing had to be readjusted several times, and as the animal continually tried to remove it a muzzle was used.

On the 10th May the bandage was removed. The maxilla had united, and the fragments were solidly fixed together. The dog was fed with bread and chopped meat (without bone).

On the 15th it was able to take its usual food. The lower jaw was slightly deformed by the presence of a callus, but showed no abnormal tenderness.

OSTITIS OF THE INFERIOR MAXILLA—NECROSIS—(SEQUESTRUM).

31. Six-year-old gelding, left in hospital on the 26th October, 1897. Disease had been caused by the bit. The mucous membrane of the mouth had been seen to be wounded, and the lower margin of the maxilla swollen. The injury was first treated by firing, but the swelling increased. An operation was afterwards performed, but gave unsatisfactory results, a fistula remaining. Six weeks later, as the animal was difficult to handle, it was sent here.

The outer margin of the left branch of the inferior maxilla, opposite the bars, exhibited a bony tumour the size of a hen's egg, the centre of which was pierced by a fistula about two inches in depth. In the cavity of the mouth could be seen the cicatrix left by the incision made two months before on first operating.

On the 29th October the horse was cast on Daviau's table. The fistula was enlarged with a gouge, revealing a sequestrum as large as a hazel-nut in the depth of the bone. The inferior wall of the cavity containing it being very thick and hard, we decided to operate through the mouth. The jaws were opened with a gag, and the tush and corner tooth of the corresponding side removed. Through the opening thus made the sequestrum was easily removed. The margins of the wound were lightly cauterised, and the wound itself plugged with gauze through the cutaneous orifice. Each day the dressing was renewed and the wound washed out with dilute iodine solution. Recovery occurred in three weeks.

CANCER OF THE INFERIOR MAXILLA.

32. A ten-year-old gelding sent to Alfort on the 9th June, 1897, by M. Candelot, Veterinary Surgeon at Viarmes (Seine-et-Oise).

Five weeks before, during the early part of May, a swelling as large as a hen's egg was seen to have formed under the jaw. A veterinary surgeon who was consulted regarded it as a cold abscess, applied a blister, and a few days afterwards fired it in four places. A week later

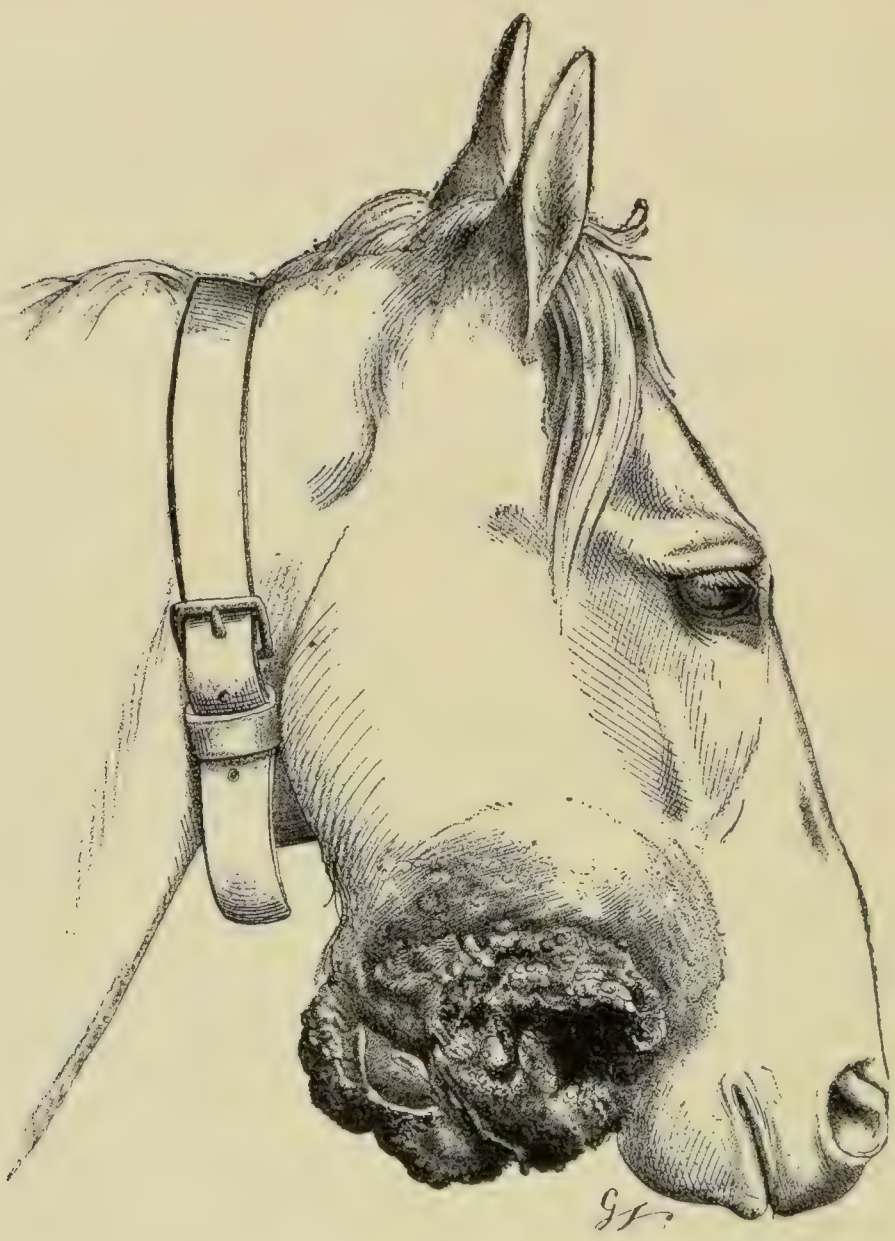

FIG. 29.—Cancer of the inferior maxilla.

this swelling had become five times its original size, and another had developed on the lower surface of the cheek which soon ulcerated and became fistulous. The disease grew rapidly aggravated, without, however, producing general disturbance. The animal preserved its appetite and showed no difficulty in mastication.

On entering hospital it was still in good condition. The lower

portion of the right cheek, the jaw, and the intermaxillary space were occupied by a large new growth, the outer part of which was ulcerated, fungous, and bleeding. Owing to the animal rubbing the parts the chest, shoulders, and forearms were covered with pus and blood.

The tumour in the intermaxillary space was only of metastatic origin. It covered 8 inches in length and 10 in width, and its centre projected about 5 inches. It was very hard, bosselated, and adherent to the skin, but moveable in relation to the jaw and the tongue.

The tumour on the face occupied the lower portion of the cheek, from the middle third of the masseter to the chin. In front it extended beyond the zygomatic ridge; behind it projected 3 inches to 3½ inches above the general surface, and was in contact with the tumour in the intermaxillary space. It was somewhat sharply defined, showed a peripheral zone covered with skin, to which it was adherent, and a central ulcerated, vegetating, cauliflower-like centre 4 inches across, in

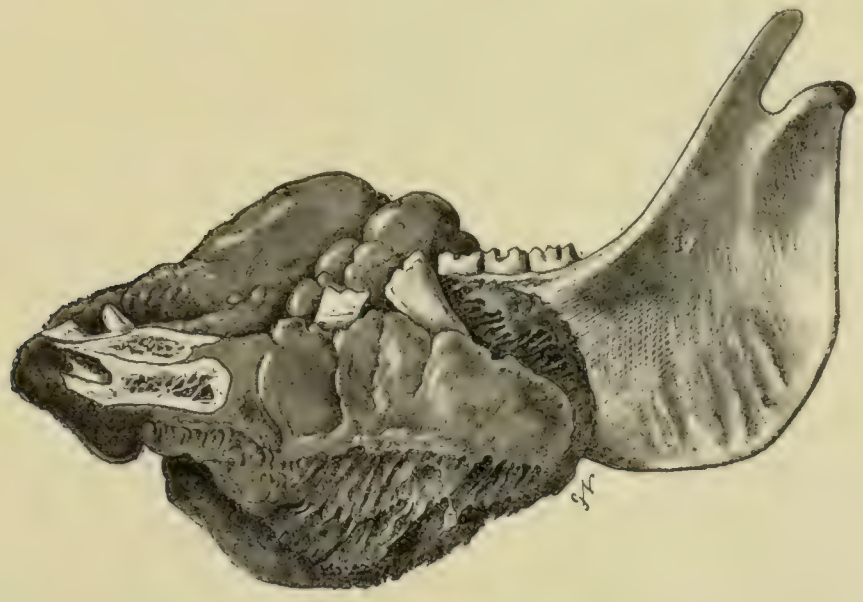

Fig. 30.—Internal surface of the right branch of the maxilla.

the depths of which probing revealed softened, crepitant bone. The masseter was distinctly atrophied.

On examining the buccal cavity (which was offensive) the tumour was found to have perforated the inner table of the maxilla and the mucous membrane, and filled up the depression between the gums and tongue, forming an elongated reddish mass, which covered the first molars.

The characters of this new growth, but especially its point of origin in the maxilla, and its prompt extension to the lymphatic glands and tissues of the cheek and mouth, indicated its epithelial character. Histological examination of a fragment removed from the margin of the ulcer on the face proved it to be an epithelioma of the lobulated pavement variety.

The animal was left in hospital as a subject for clinical study. No surgical treatment was possible, and none was attempted. The cancer

made rapid progress, as shown by wasting, loss of appetite, and paleness of the mucous membrane. Death occurred on the 23rd June.

Post-mortem Examination.—General wasting. No growths in the viscera. The head having been sawn through along the middle line, the left branch of the lower maxilla opposite the first molars appeared destroyed throughout its entire depth. Around this area of destruction the branch of the maxilla was swollen, enlarged, its two layers thrust widely apart, and its tissue softened. The first and third molars had fallen from their alveoli; the second, surrounded by granulating tissue, was quite loose. The tumour in the intermaxillary space weighed 4 lbs. 6 oz. The buccal and facial portions of the other new growth, which occupied the entire depth of the maxilla and extended beyond its margins, weighed nearly 6 lbs. 6 oz.

This case is remarkable for the rapidity with which the cancer developed. In two months it destroyed the central portion of the right branch of the lower maxilla, produced great disturbance, and caused troubles ending in general decline and death.

DENTAL CARIES.

33. Five-year-old mare affected with caries of the second left upper molar. Entered hospital on the 10th November, 1896.

For some time this animal had been noticed to eat very slowly. It masticated oats badly, ate hay with difficulty, and seemed to prefer mashes and easily masticated food. It had also been observed that considerable quantities of fœtid saliva mixed with food material ran from the mouth, and that the left side of the face exhibited a swelling, painful on pressure.

Condition on Entry.—The left side of the face in front of the small maxillary sinus exhibited a diffuse, slightly painful swelling. Large quantities of viscous stinking saliva, mixed with food material, ran from the mouth. A greenish muco-purulent discharge escaped from both nostrils, but especially from the left. The submaxillary gland appeared as a small, hard, indolent swelling, not adherent to the base of the tongue. The mouth was offensive. Opposite the second molar was a depression in the line of teeth, around which food had accumulated. The gum and inner surface of the cheek were inflamed.

At exercise the animal produced a peculiar abnormal sound during respiration, pointing to deformity of the left nasal cavity, a condition verified by exploration with Gunther's catheter.

Diagnosis.—Caries of the second left molar, with swelling of the floor of the corresponding nasal cavity.

Treatment.—Removal of the tooth by punching. On the 11th November the mare was cast on the right side, and the jaws having been widely opened by a gag, a V-shaped incision was made over the root of the tooth, the subjacent tissues reflected, and the maxilla trephined, giving exit to a quantity of grumous fœtid pus mixed with food.

After cleansing the cavity the punch was applied to the root of the tooth, which was displaced by a few gentle blows, an assistant mean-

while controlling the progress of operation by passing one hand into the animal's mouth.

The tooth having been removed the opening was cleansed with warm carbolic solution, and plugged with gauze. That evening the temperature was normal.

Next day the dressing was renewed. The animal ate freely and seemed to have suffered little from the operation. Temperature 39·2° C. Discharge was less abundant, but breathing was still noisy.

The same treatment was continued on the following days. The wound showed no special feature.

On the 18th discharge had ceased. The external wound was clean, and there were no splinters or necrosis.

Treatment was continued until the 25th. Swelling of the face had gradually diminished, the alveolar cavity rapidly filled up, and the abnormal breathing disappeared.

DENTAL FISTULA.

34. Eight-year-old entire horse suffering from dental fistula. Brought for examination on the 19th January, 1899.

History.—The disease had first appeared nearly two years before. At that time the horse showed a slowly increasing enlargement over the anterior portion of the left upper maxilla, which was several times unsuccessfully blistered and once punctured. On the last occasion pus escaped, but the enlargement continued and the wound became fistulous.

Condition on Examination.—Opposite the roots of the second and third molars, and at its junction with the cheek, the left side of the face showed a swelling measuring three and a quarter inches in diameter, the centre of which was pierced by a fistula discharging greyish, putrid pus. A probe entered for a distance of one and a half inches, and at that point appeared to be checked by contact with the root of a molar tooth.

External manipulation of the parts produced little pain, but the introduction of a probe into the fistulous tract caused the animal to struggle violently.

The left line of molars showed nothing abnormal, no caries or tumour, no fistula or gingivitis; and the buccal cavity was perfectly sweet.

The long duration of disease, the fistula formation and other attributes of the swelling, the character of the pus, and the absence of lesions within the mouth pointed to the existence of alveolitis confined to the space around the root of the tooth, or of caries of this root.

Treatment.—On the 21st January the animal was cast on the right side by means of Daviau's table; the maxilla trephined over the root of the second molar (which was found to be separated from its alveolus and the point of origin of the fistula) and the tooth punched out with the usual precautions.

After operation the wound was cleansed and the alveolar cavity plugged with cotton wool surrounded by layers of gauze.

The root of the tooth when examined was found to be carious; the anterior portion had been destroyed, and the tooth itself penetrated by a deep narrow fistula, into which a wire penetrated to within about three eighths of an inch of the grinding surface; the table itself, however, was intact.

No exact information could be obtained as to the cause of this dental fistula. It was probably produced by injury to the maxilla opposite the second molar, leading first to ostitis, then to formation of a necrotic area, followed by alveolitis and caries of the root of the tooth.

There being no spare room in hospital the horse was placed at livery near the College. During the following few days it was brought to the external clinique. Every morning the dressing was renewed; the alveolar wound was exposed, cleansed, and again plugged. At the end of a week a small necrotic area was noted in the maxilla in front of the trephine opening. It was swabbed with tincture of iodine, and the little necrotic patch soon separated.

From the beginning of the second week the dressing was only renewed each second day. The external wound and that of the alveolus gradually closed. On the 1st March they had become reduced to a narrow channel from which only a little pus escaped; and in the mouth the breach had almost entirely closed.

At this date the animal was returned to work, recovery being assured.

35. A five-year-old water-spaniel left in hospital on the 17th August, 1898.

For nearly a year this animal had shown at the base of the lower eyelid, slightly in front of and below the eye, a fistulous wound discharging fœtid, greyish, sometimes blood-stained pus, which had irritated the skin of the cheek and produced a bare patch. It had been unsuccessfully treated by antiseptic injections, and by exposure and cauterisation. During the previous few months the patient had fallen away in condition.

On exploration the fistula was found to terminate over the root of the last molar, around which the gum was inflamed and retracted.

Under proper control the molar was extracted with dental forceps. It was partially carious. The alveolus, however, showed no necrosis, and was disinfected with iodine solution, and plugged with cotton wool.

During the four following days the dressing was renewed daily. Afterwards the cavity was washed out night and morning with warm boric solution.

On the 30th the fistula on the face had closed, and the alveolar opening to a great extent filled up. Next day the animal returned home.

36. A three-year-old cat, with dental fistula opening on the right side of the lower jaw. Brought for examination on the 31st March, 1896.

The fistula had been in existence for about eight months. The owner stated that it had followed a rat bite. It opened on the right side of the lower lip, and was masked by the surrounding hair; the track was narrow, its opening level with the skin, and its margins not indurated. A fine stilette introduced into the wound was checked by contact with a necrotic fragment of bone.

The animal having been fixed on the table, and the jaws opened by means of two pieces of tape, the gum was seen to be swollen, red, and retracted opposite the right canine tooth, the base of which exhibited a thick deposit of tartar. The tooth was removed, and the wound and fistulous tract cleansed with a 30 per cent. solution of tincture of iodine.

In ten days the cutaneous and buccal wounds had healed.

SECTION OF THE TONGUE.

37. A four-year-old Arab horse, brought from Marseilles to Paris in a horse-box, in which it was fastened by means of a rope passed through the mouth.

When receiving the horse the owner noticed that the loop of rope was soiled with blood. On attempting to examine the mouth the animal struggled violently, but the tongue was seen to exhibit a transverse wound extending over its entire width, slightly in front of the first molars.

The patient was brought to the school three days afterwards. The angles of the mouth were soiled with blood-stained saliva; the lower lip and chin showed a semicircular superficial wound, produced like that of the tongue by pressure of the rope. In order to examine the oral cavity a twitch had to be applied. On opening the mouth a fœtid odour was observed. The left side of the free portion of the tongue appeared slightly swollen and red; the right was greenish in colour and gangrenous. At that time, however, the two parts were still in perfect continuity throughout their entire extent, though the line of demarcation could be clearly seen. It extended exactly through the centre of the tongue, except in front where it curved towards the right, attaining the free margin about an inch from the central line.

This line of demarcation, though superficial in the left half of the tongue, extended throughout the greater part of the thickness of the right half. The inequality in depth explained the persistence of circulation in the left half of the organ and the gangrene of the right.

The animal was fed on liquid food, like milk, gruel, and mash, the mouth being frequently washed out with cold fluids.

On the animal's return ten days later, the gangrenous portion of the tongue was seen to have become separated and lost. The entire surface of the wound was granulating.

The contraction which resulted was most marked in the direction of the thickness of the tongue, the free extremity of which was only drawn slightly towards the right; there was no subsequent trouble either in prehension or mastication.

38. A Norman mare, brought from Caen to Paris in a horse-box, and, as in the preceding case, tied up with a rope passed through the mouth.

The tongue had been divided transversely throughout the greater part of its depth, a little in front of the first molars. The bars, inner surface of the lips, and labial commissures were severely injured. The rope had rubbed away the hair and injured the skin about the chin, and had entirely cut through the lower lip of either side towards its free margin. The animal was fed with gruel, and the buccal cavity frequently washed out with cold water.

Fig. 31.

At the end of forty-eight hours the anterior portion of the tongue had become gangrenous. It separated six days later. The stump healed rapidly, and the animal was returned to ordinary work. At first it had difficulty in prehension, but soon became capable of consuming its ordinary food consisting of oats and hay.

When seen two months after the accident it was in good condition. The lingual cicatrix was flexible and fairly regular, although the tongue itself was drawn slightly to one side. The stump extended about two inches below the first molars. Opposite it the depression normally existing between the gums and lips had disappeared, the two structures having become adherent.

Despite the mutilation, there was no difficulty in grasping or masticating food.

FOREIGN BODY IN THE MOUTH.

39. A one-year-old Bordeaux dog brought to the School on the 30th November, 1898, during the afternoon, by a lady who was only able to give vague information. She said that the animal had not eaten anything for several days, that saliva dribbled from the mouth, and that a veterinary surgeon who had examined it prescribed treatment which proved unsuccessful.

This dog was bright and did not appear in pain. From the corners of the mouth a viscous fœtid saliva streaked with blood escaped in considerable quantities. The animal would not take solid food, but was able to swallow warm milk given by spoonfuls.

On examining it next day, I suspected the presence of a foreign body in the mouth or pharynx and ordered these cavities to be examined.

The dog was placed on the operating table and the mouth widely opened by means of a speculum. With the exception of abundant secretions of saliva nothing abnormal could at first be discovered. The odour, however, was excessively offensive. Several

molars of darker colour than the others attracted attention, but there was no caries, or inflammation of the gums, and some other cause had to be sought. On pressing down the tongue with a spatula and moving it from side to side a cord was noticed in the space between the tongue and gums, the centre portion surrounding the base of the tongue, and the ends traversing the pharynx and entering the œsophagus. It was seized with the fingers and removed. The appearance it presented is shown by Fig. 31.

This cord measured 13 inches, the loop alone being about 8 inches in length. Its free end formed an irregular mass the size of a man's little finger, in which were entangled some fragments of shavings.

The loop had slipped under the tongue, and been caught on the frænum linguæ, the free portion passing backwards and entering the pharynx. It could not be swallowed, and could only have been expelled by vomiting, which, however, did not seem to have occurred.

Scarcely had the cord been removed than the animal began to eat. On returning to its kennel it soon cleared out its feeding trough.

In spite of the stomatitis which had occurred, recovery followed promptly, and the animal was able to return home on the 3rd December.

CHRONIC PHARYNGITIS—DOUBLE HYOVERTEBROTOMY (OPENING OF THE GUTTURAL POUCHES).

40. A fifteen-year-old gelding. Entered hospital on the 30th June, 1896. Had been left at Alfort to be treated for pharyngitis in December, 1895, and been removed before complete recovery. A slight discharge from both nostrils had continued, and after some time increased in quantity.

On returning to hospital this horse was in rather thin condition; appetite was normal, but swallowing difficult. A muco-purulent discharge containing fragments of food ran from both nostrils, and part of the drinking water, which was at first mixed with muco-pus, returned by the same channel. Violent attacks of coughing occasionally occurred. The throat was neither painful nor swollen. The parotid region appeared normal. It was difficult to produce coughing by pressing on the larynx. The submaxillary glands contained two small hard multilobular masses. The chief functions were regular. The lungs revealed nothing abnormal.

On the 4th July the guttural pouch of either side was opened and a mass of gauze saturated with dilute tincture of iodine was passed to act as a drain.

Up to the 25th July antiseptic injections were made daily and fresh strips of gauze saturated with iodine solution were passed. After that time drainage was stopped.

The discharge and difficulty in swallowing gradually diminished. On the 28th the animal was almost completely cured, and returned home. Trifling disturbance remained for a time, but finally disappeared.

COLD ABSCESS IN THE RETRO-PHARYNGEAL GLANDS.

41. A five-year-old mare, left in hospital the 11th June, 1897.

History.—About three months before the stableman had noticed in the submaxillary and laryngeal regions a swelling, which extended on either side over the parotid. Though at first little marked, this swelling gradually increased. A little whitish, mucous, inodorous discharge, which appeared oftenest during work and when the animal began to swallow liquids, ran from the nostrils. Deglutition was difficult, and the mare ate and drank slowly.

No useful information could be obtained as to the animal's antecedents. We simply learned that it was of American origin, and had been bought four months before.

State on Examination.—In spite of the difficulty in eating, the mare was in good condition. The swelling of the throat and parotid regions was considerable, was hard, resistent, without fluctuation, and almost painless on pressure. The head was held extended.

The submaxillary gland was slightly swollen, the swelling being ill-defined and rather œdematous towards its periphery. From time to time, and especially when the animal drank, a whitish, inodorous discharge ran from both nostrils, though rather more abundantly from the left, although the swelling appeared equal on either side of the throat.

Treatment.—After a week of observation the upper part of the right guttural pouch was opened and a counter opening made in the usual way. No pus escaped, but a drainage-tube was nevertheless introduced. A similar operation was performed on the other side with like result.

The animal was left at liberty in a box. During the afternoon it appeared dull and hardly touched food. The guttural pouches were washed out with a warm solution of iodine and iodide of potassium.

On the following days the parotid regions increased in size and became very tender. Mastication and deglutition appeared painful, and there was difficulty in flexing the neck. The temperature only rose a few tenths of a degree. Each morning the drainage-tubes were replaced. The patient was fed on gruel and milk.

On the 22nd creamy pus escaped by the drainage-tubes; the swelling decreased, especially on the left side; difficulty in swallowing was less marked; discharge ceased; and the extension of the head and stiffness about the neck diminished.

During the following week the swelling due to operation lessened in the upper half of the parotid region, but persisted in the lower. Immediately above the origin of the trachea a swelling formed, and steadily became more clearly circumscribed, giving the impression of a deep-seated cold abscess or of a tumour. During the first week of July these local symptoms remained unchanged. Further operation was decided on.

On the 9th the mare was cast on Daviau's table. The head was firmly fixed in a position of extension, and the skin covering Viborg's triangle washed, shaved, and disinfected. A cutaneous incision about 6 inches in length was then made immediately above and parallel to

the external maxillary vein. By careful dissection the skin, subcutaneous fascia, parotid gland, and subjacent aponeurosis were reflected. On passing the finger behind the left guttural pouch a large, rounded, uniform, resistent swelling, without the least fluctuation, was detected. For the moment it was doubtful whether this represented a new growth or a cold abscess in the retro-pharyngeal glands. The end of a grooved director was introduced, guided by the left index finger, and was pushed in the direction of the centre of the swelling. It appeared to enter, and some whitish laudable pus escaped. The tract was enlarged, and about a pint of similar pus evacuated. The abscess cavity was washed out, a rubber drainage-tube inserted and fixed to the skin, and the animal allowed to rise. On entering the stable it at once began to eat some oats, which it swallowed without difficulty. The swelling about the throat had almost entirely disappeared, and the head and neck were moved freely. During the evening and following days the abscess cavity was washed out with antiseptic solutions. Suppuration was trifling.

On the 14th the drainage-tube was removed. On the 20th the guttural region had resumed its ordinary appearance, except for the cicatrix of the operation wound. Respiration was unaffected, and appeared normal at all paces.

II.—NECK.

WOUND OF THE NECK.

42. A nine-year-old gelding suffering from a wound in the region of the neck, left in hospital the 18th November, 1898.

On the 16th November when out for exercise this horse had reared up when passing close to a man carrying a scythe, and the cutting edge of the implement had entered the neck, producing a large wound (Fig. 32).

State on entering Hospital.—The patient was brought to hospital

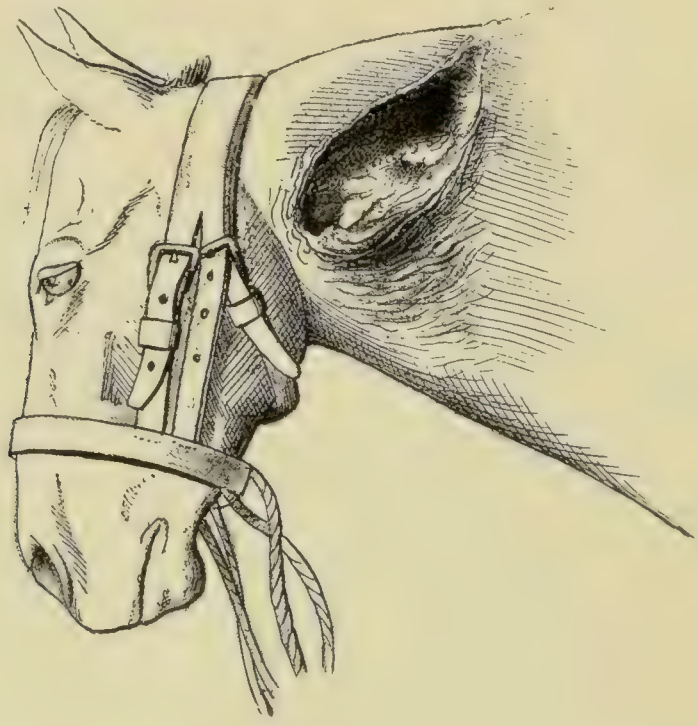

Fig. 32.

two days after the accident. On the left side of the neck was a wound about twelve inches in length, running obliquely forwards and downwards, extending from the upper border of the neck to within an inch and a half of the jugular furrow. Its anterior extremity was almost in contact with the lower jaw. Above, it passed across the upper margin of the neck, and for a further distance of three inches over the right

side. The tissues covering the upper part of the neck were completely, and the ligamentum nuchæ partially divided, especially on the left side.

Towards its centre the wound was six inches broad and three to three and a half inches deep. Opposite the line of the vertebræ it was two and a half inches in depth, and extended through the muscular tissues. The upper part was somewhat shallower. The greater portion of both surfaces of the wound was covered with dried exudate, and the deeper portions contained masses of blood-clot. The animal was depressed and feverish; it only ate a portion of its food; the temperature was 39·5° C.

Treatment.—Thorough disinfection of the wound with a warm one per thousand solution of sublimate, insertion of deep-seated sutures, and application of moist antiseptic compresses.

November 20th.—The wound had become clean. Some fragments of dead tissue had been shed. Suppuration was trifling. Temperature 39·2° C.

During the following days the wound granulated over its entire surface. The muscular layers became united. The depressions filled up and suppuration remained slight. In spite of the extent and depth of the wound the neck was easily moved in all directions. The appetite was good, and the temperature normal.

On the 5th December the use of moist compresses was discontinued, the wound being simply washed out night and morning with an antiseptic solution. On the 20th it had almost filled up; the margins were nearly in contact, and at the widest part were only separated by a distance of an inch and a quarter.

POLL-EVIL.

43. Fifteen-year-old gelding, sent to the School from the Pasteur Institute on the 27th February, 1898.

It had first been treated at the infirmary of the Institute for an open sinus on the left side of the head. Carbolic and sublimate injections had proved unsuccessful.

On the 28th the horse was cast on the right side. The sinus, which opened almost on the median line, extended obliquely downwards and backwards parallel to the ligamentum nuchæ, and was about six inches in depth.

Treatment.—The sinus was exposed and a counter-opening formed. A gauze drain was inserted, and the parts washed out night and morning with 30 per cent. tincture of iodine, and with Villate's solution. A prophylactic injection of antitetanic serum was given.

Though continued until the 15th March this treatment by drainage and injections produced no improvement. Operation for poll-evil was then decided on.

The animal was cast on the table, and the cordiform portion of the ligamentum nuchæ removed up to the point where it becomes inserted into the occipital bone, the latter being scraped. The wound was cleansed with warm sublimate solution, powdered with iodoform, and

covered with compresses of iodoform gauze, over which was applied a compress dressing of cotton wool kept in position by three bandages.

On the second day after operation the dressing was removed and the wound washed out with warm sublimate solution. A fresh gauze and cotton-wool dressing was applied. The dressings were changed every second day until the 3rd May, when the wound was granulating throughout.

SINUS OF THE NECK.

44. Eight-year-old gelding, left in hospital the 27th August, 1898.

For the previous three weeks this horse had shown a diffuse, very tender swelling in the upper part of the neck, the centre of the swelling being occupied by a large partially detached slough, which appeared to extend deeply towards the ligamentum nuchæ.

Treatment.—The greater part of the dead tissue was excised. Two incisions in the shape of a cross were made, one in the axis of the neck, the other transverse to it; and in addition a counter-opening was made on the right side, in which a strip of gauze was placed to act as a drainage-tube. Night and morning the wound was disinfected, the margins powdered with bicarbonate of soda, and the parts covered with compresses saturated with warm 5 per cent. bicarbonate of soda solution. This treatment was continued for a week. Suppuration remained abundant, and the swelling large and painful.

From the 5th September the parts were dressed with a weak solution of formalin and a mixture of calomel and iodoform. This treatment proved very successful. The wound soon assumed a better appearance. The pus became thicker and less abundant, while the parts lost their extreme sensibility.

On the 30th September the necrotic portions of the ligament had separated, and the entire surface of the wound was actively granulating. The neighbourhood of the wound still remained very sensitive in consequence of irritation of the skin.

MOIST GANGRENE IN THE NECK REGION.

45. A thirteen-year-old entire horse, left in hospital 28th April, 1893.

This animal had been injured a little in front of the withers by the collar. The neighbourhood of the wound and the upper margin and sides of the neck became much swollen. A veterinary surgeon punctured the swelling on both sides with a pointed firing-iron, but tumefaction increased during the following days.

State on Examination.—Depression; loss of appetite; anxious appearance of the face; mucous membranes cyanotic; respiration and circulation rapid; temperature 39·6° C. The whole of the neck was enormously swollen; sloughing had occurred in the upper half, and the lower was œdematous. At the centre of the upper margin was a sinus into which almost half a litre of liquid could be injected. On the right side the necrotic parts were beginning to separate.

Treatment.—Attempts were made to check the extension of gangrene on the left side of the neck by applying about thirty deep punctures with the firing iron, into which was injected 30 per cent. tincture of iodine containing iodide of potassium. The parts were sprayed with carbolic solution. Alcohol, carbolic acid, and bicarbonate of soda were given internally. The evening temperature was 40·2° C.

April 30th.—The general condition had improved. The mucous membranes were less injected; the pulse and respiration less frequent. The animal took a part of its food. The general symptoms were no longer alarming. Separation of the dead parts had begun on the left side. The eschar measured fourteen inches in length and varied between four and seven inches in breadth. The parts were sprayed with carbolic solution three times daily and covered with a thick compress saturated in one per thousand solution of sublimate.

May 3rd.—Improvement was progressive. Appetite had returned, and each day delimitation was more marked.

May 6th.—The eschar not yet being completely delimited, the greater portion was excised. A mass weighing nearly six pounds was removed. In front a gangrenous patch about four inches in length remained. To prevent necrosis extending in the funicular portion of the ligament cervical desmotomy (division of the cordiform portion of the ligamentum nuchæ) was performed. Antiseptic treatment was continued.

May 9th.—The remaining necrotic patch was excised. It weighed a little more than two pounds.

May 10th to 27th.—The wound became clean, and granulated actively. The loss of tissue was gradually replaced. Up to the 10th June a sinuous tract remained, originating from a necrotic fragment of the ligamentum nuchæ.

The animal left hospital on the 15th June. The wound was granulating throughout, and recovery was certain.

PHLEBITIS OF THE JUGULAR VEIN.

46. Five-year-old entire horse, left in hospital on the 30th December, 1896.

The animal had been bled, and in consequence a large thrombus had formed.

From the site of the operation wound up to the parotid the jugular furrow was swollen, hot, œdematous, and painful. The wound was sinuous, and a director could be passed into the vein.

The sinus was laid open for a long distance in the axis of the vessel; its walls were curetted, disinfected with strong carbolic solution and tincture of iodine, and plugged with iodoform gauze.

During the succeeding days the dressing was renewed daily, the wound cleansed by spraying with carbolic solution, and dusted with calomel. Suppuration was trifling, and healing regular.

On the 8th January a little perivenous abscess, which had developed about an inch above the wound, was punctured. The cavity was cleansed and treated with antiseptic injections.

Cure was complete in a fortnight.

47. A seven-year-old in-foal mare, left in hospital 18th February, 1897.

About six weeks before the animal had been bled from the left jugular. Phlebitis resulted, and was treated by laying open the parts and cleansing with disinfectant lotions. Recovery appeared to be taking place when the parotid region became inflamed.

On examining the animal on the 11th February we discovered a subparotid abscess developed between the middle and upper thirds of the gland. It was punctured and washed out with 30 per cent. iodine solution. The condition becoming aggravated, the animal was left in hospital on the 18th February.

State on Entry.—The entire left parotid region was greatly swollen and very painful. The swelling extended from the wound in the vein to the temporo-maxillary region and back of the neck, passing round the base of the ear. The subparotid abscess communicated with the wound in the vein. The animal discharged from the left nostril. It refused part of its food.

Treatment.—Drainage of the vein and injection of the sinus with 30 per cent. solution of iodine and iodide of potassium.

On the 19th February two small abscesses had developed above the first, and were opened. They contained little pus.

On the 22nd two more abscesses were opened; one, of considerable size, had developed behind the parotid, the other near the base of the ear. The cavities were cleansed, and the sinus irrigated with iodine solution. A fragment of the gland tissue was removed. When feeding saliva escaped by the parotid wounds.

On the 25th a deep-seated abscess opened in the pharynx, and pus escaped by the nostrils.

On the 28th another parotid abscess was opened, and a counter-opening made in Viborg's triangle.

From this time onwards improvement was steady.

On the 17th March drainage of the vein was stopped.

A week later the wounds had healed. The parotid region and upper part of the jugular furrow remained slightly swollen, but the swelling soon afterwards disappeared.

48. Six-year-old mare, left in hospital on the 11th January, 1897.

A month before the animal had suffered from strangles, and had been bled from the left jugular.

The patient was brought in an ambulance, and was so thin and feeble as to require support when walking. Scarcely any weight was borne on the near hind limb. On being placed in a box it soon fell into a comatose state, remaining quite still, the eyes half closed, the head depressed, the limbs brought together under the body; from time to time the animal was obliged to lean for support against the wall.

The mouth was hot and dry; the conjunctiva yellowish in colour; the pulse 80, small and thready; respirations 22; temperature 39·5° C.

The hair had been removed from the left parotid region by the action of vesicants. In the upper part of the jugular furrow was a warm, slightly painful swelling, extending over the parotid, and show-

ing a sinuous wound which discharged blood-streaked pus. Another wound existed about the centre of the parotid region.

In the œdematous tissue filling the left side of the submaxillary space, a large, irregular, slightly sensitive swelling formed by the submaxillary gland could be felt.

A large swelling covered the region of the sternum and extended beyond the ensiform cartilage.

The left haunch was atrophied; the right showed a cool, slightly painful swelling, specially marked over the region of the coxo-femoral joint. The left hock was swollen, denuded of hair by blistering; and exhibited on the lower and inner surface a small wound discharging whitish pus.

Nothing abnormal could be detected on percussing and auscultating the chest. Rectal exploration failed to discover signs of intra-pelvic abscess.

Treatment.—The wounds were washed with antiseptics, creolin being used in the fistulous portion of the jugular; and warm creolin enemata were administered during the evening. Milk, hay tea, brandy, and bicarbonate of soda were given internally. The patient readily took gruel.

Next day the animal seemed less depressed. The local symptoms remained unchanged. Discharge of pus was facilitated by inserting drainage-tubes in the fistulous portion of the vein. The swelling under the chest showed fluctuation, and on being opened discharged a pint of pus; it was washed out and disinfected several times during the day. The swelling in the coxo-femoral region was stationary. In order to prepare for operation the hair was shaved and the skin disinfected over an area the size of a man's hand, but exploratory puncture was deferred, as the position of the abscess was uncertain. The internal treatment was continued. The evening temperature was 40·5° C.

On the 13th there was little improvement though the vein suppurated less than on the previous day. In order to check extension towards the base of the jugular a few deep punctures were made with the firing-iron in the upper part of the parotid region. Antiseptic injections into the fistulous vein and into the purulent cavity beneath the sternum were continued. Temperature 40° C. Internal treatment continued. Evening temperature 40·3° C. Respirations 20.

On the 14th January temperature 40·6° C; respirations 26. No striking change except a diminution in size of the swelling in the coxo-femoral region. During the evening the mare lay down and groaned a good deal. She received an enema containing chloral. Temperature 40·5° C. Died during the night.

Autopsy.—The peritoneum, ecchymosed in places, contained a little yellowish serous fluid. The liver, spleen, and kidneys were congested. In the depths of the right haunch was a collection of pus surrounding the hip-joint.

The left pulmonary lobe contained about fifteen little purulent centres; the pericardium about one pint of yellowish serous fluid. The myocardium showed no lesions, though the endocardium exhibited a few ecchymoses.

On dissecting the parotid region phlebitis was seen to have extended a considerable distance beyond the parotid fistula. The subzygomatic and internal maxillary veins had become affected.

On dividing the head along the middle line the meninges appeared inflamed, thickened, and bathed in a purulent exudate, in which bacteriological examination revealed the presence of strepto- and staphylococci.

EXTENSIVE LACERATED WOUND IN NECK OF HORSE; RUPTURE OF THE TRACHEA; RECOVERY.

49. Light van horse, seen 23rd July, 1896.

History.—Had been struck about the middle of the neck by the pole of a two-horse van (see Fig. 33).

State on Examination.—The animal showed two wounds in the neck and one in the pectoral region. The largest was on the off side of the



FIG. 33.—The larger wound is shown white; the position of the smaller is indicated by the arrow; the pole head is shown within lines.

neck, about midway between the angle of the jaw and point of the shoulder. A large irregular fragment of skin about three and a half inches in either direction had been entirely torn away, and on inserting the finger into the wound two channels could be detected, one

about three and a half inches in length passing downwards and backwards, following the direction of the levator humeri muscle; the other upwards and forwards, and towards the opposite (near) side of the neck. As the finger penetrated more deeply the rough broken edges of a tracheal ring could be felt, and during inspiration and expiration air rushed in or was forced out, producing a loud bubbling sound. The tissues were extensively bruised, and the skin torn away from subjacent structures for a considerable distance. The wound on the near side of the neck was three to four inches below the angle of the jaw, and measured two and a half inches by half an inch. It communicated with that of the opposite side by a channel running downwards and backwards, so that by standing in front of the animal and gently passing the forefingers in from either side they could be caused to meet just in front of the trachea.

Treatment.—The wounds were thoroughly explored and cleansed, care being taken to avoid the use of much fluid which might have passed into the trachea. To facilitate the freest possible drainage no stitches were inserted. The parts were cautiously injected three times daily with 5 per cent. "Sanitas" solution, care being taken to reach the bottom, and the neighbourhood of the wounds was carefully cleansed. Low diet.

On the 24th July the wounds and surrounding parts were greatly swollen, but discharge was not offensive. Until the 29th the wounds and neighbouring parts were much swollen, but on that date swelling began to subside. There was slight fever and rather high pulse rate for the first few days, but this soon subsided. Appetite was preserved throughout.

On the 8th August both wounds had closed and were granulating freely. A week later the horse returned to work. A year afterwards the horse showed very slight traces of the accident, and breathing was normal.

Mr. Jno. A. W. Dollar's case, *Veterinarian*, 1896, p. 672.

FOREIGN BODY IN THE ŒSOPHAGUS.

50. A seven-year-old entire horse, left in hospital on the 18th February, 1897.

When being taken out of harness this horse passed near a heap of sliced carrots, and picking up a few pieces hastily swallowed them. Almost immediately it showed grave disturbance, violent excitement, efforts to swallow, and abundant salivation. It was brought to hospital during the evening.

The animal made continued attempts to swallow. A little saliva ran from the mouth; the head was slightly extended on the neck; respiration was increased, and cough frequent. In the jugular furrow a little below the larynx was a well-defined swelling. Palpation left no doubt as to the nature of the condition, viz. obstruction of the œsophagus.

The animal was cast on the table and chloroform administered. The jaws were opened with a gag, and the first portion of the œsophagus examined. No foreign body could be detected. Taxis was employed,

and the probang passed without success. As the obstruction might probably become softened in a short time further surgical intervention was deferred.

The animal was allowed to rise, and placed in a box from which the litter had been removed, in order to prevent it attempting to eat, thus introducing material into the trachea. A hypodermic injection of pilocarpine and eserine was given.

For half to three quarters of an hour salivation was very abundant, and swallowing efforts very frequent; then the symptoms suddenly disappeared; the foreign body had passed onwards into the stomach. The point at which it had been arrested remained sensitive for some days, but there was no subsequent difficulty in swallowing.

51. Two-year-old sheep-dog, left in hospital on the 2nd January, 1899.

This animal was in the habit of fetching and carrying, and was fond of playing with objects given it for this purpose. During the last few days of December it had appeared very dull, had refused to eat, and shown swelling of the throat.

Condition on Entry.—The dog was dull, held the head depressed, and refused food. The guttural region showed a hard, cool, insensitive swelling, the size of a small egg, without local fluctuation. This was first regarded as a cold abscess in course of formation.

On the two following days there was no local change. The animal refused all food, and had to be spoon-fed with milk.

On the 5th January the hair covering the centre of the swelling was glued together by pus, and the skin seen to be penetrated by a small opening. To evacuate the contents of the abscess slight pressure was exercised over the swelling on either side of the wound, when the end of a fragment of knitting-needle, two and a half inches in length and covered with sanguinolent pus, was seen to be projecting.

The fistula having been laid open a director was passed nearly two inches in a direction almost perpendicular to the surface of the region. The wound in the œsophagus healed. When the animal drank, no liquid escaped by the fistula.

As often happens when sharp objects are swallowed by dogs, this needle had become implanted in the walls of the pharynx or commencement of the œsophagus, had passed through them under the influence of the swallowing movements to which it gave rise, and become implanted in the tissues of the neck, where it had produced the above-mentioned swelling; and had finally attained the skin, causing ulceration.

The next day, in spite of the needle having been removed, the animal appeared dull, moved slowly, and refused food. Milk diet was therefore continued.

On the 7th the condition was the same, and the bowels were constipated. No fæces were passed. An ounce of castor oil was given, and warm water enemas administered. During the day some dry, earthy fæces, streaked with blood, were voided.

On the 8th the warm water enemas were continued. Suddenly the

animal made violent expulsive efforts, and passed by the anus a ball of worsted. By the evening it was bright, and ate some of its ordinary food.

During the following days improvement increased, the animal became brighter, and appetite returned.

On the 10th the swelling about the neck had disappeared, and only a narrow fistula remained, discharging a trifling amount of serous pus.

The wound had closed on the 15th, when the animal left hospital.

FŒTID PURULENT ABSCESS IN THE NECK OF A CAT CAUSED BY A NEEDLE.

52. *Subject.*—A five-year-old male tabby cat.

History.—Had suffered from catarrhal fever in April, 1892. For a fortnight before examination had appeared restless and in pain, appetite was capricious, and at times there was slight vomiting; the right side of the neck from the jaw to the shoulder became swollen.

State on Examination (on September 3rd, 1892).—The swelling in neck was painful and fluctuating, and had commenced to point.

Treatment.—The abscess was opened an inch below seat of pointing to afford freer drainage; about six ounces of fœtid pus escaped. The cavity was irrigated with weak creolin solution, and the parts covered with a sublimate cotton-wool dressing.

Until September 6th appetite and general condition improved, the abscess cavity diminished, and healthy granulations formed.

On September 7th the animal appeared worse, and on the 8th was again brought for inspection. A piece of grey worsted three inches in length was removed from the cavity, and on search a needle was discovered to the right of the splenius muscle; its eye was uppermost, level with the superior border of the muscle, and about two inches distant from the head; the needle was inclined obliquely from above downwards and forwards towards the pharynx; it was two inches in length, and black in colour. Evidently it had penetrated from the mouth.

The patient died on the 10th September.

Autopsy.—The pleural cavities contained eight ounces of offensive hæmorrhagic purulent exudate, in which floated a few flakes of lymph; this exudate formed a jelly after a few minutes. The pleura pulmonalis showed a few flakes of slightly adherent lymph; the mediastinal pleura was inflamed, thickened, and friable. The centre of the right lung was consolidated. Petechiæ were visible on the epicardium. With the exception of a cheesy gland near the inferior ligament of the liver the abdominal viscera were healthy. No tubercle bacilli were found on microscopical examination.

Mr. H. Gray's case, *Journ. Comp. Path. and Therap.*, 1892, p. 381.

SURGICAL TREATMENT OF CHRONIC ROARING—HEMIPLEGIA LARYNGIS.

53. A seven-year-old Norman mare belonging to M. M—, 232, Faubourg St. Honoré, Paris, affected with intense chronic roaring.

This animal came to a standstill after trotting 100 yards. Left in hospital the 16th September, 1895.

Exercised in the riding school on the morning after arrival it almost immediately began to roar loudly. Respiration soon became painful, and dyspnœa so marked as to prevent it continuing.

Operation was performed on the 18th. The animal was placed on its back, the head firmly fixed in a position of extension. The region of the larynx having been prepared by clipping away the hair, and shaving and disinfecting the skin, the skin and subcutaneous muscular layers were incised from opposite the body of the thyroid as far as the second tracheal ring. After checking hæmorrhage I opened the larynx in the median line, dividing the crico-thyroid ligament, cricoid cartilage, crico-tracheal ligament, and first ring of the trachea. The larynx was then widely opened, and the left arytænoid seen to be completely paralysed. It remained motionless during both periods of respiration, whilst the right moved to the normal extent. Having introduced into the trachea a cannula padded with gauze I excised the left arytænoid by the method described in the preceding portion of the present work (p. 31). With cutting forceps I also removed the greater portion of the fragment of cartilage left by the bistoury opposite the crico-arytænoid articulation. Two rectangular tampons of gauze were arranged side by side in the larynx, and three interrupted silk sutures inserted to bring together the muscular layers and to fix the tampons. The skin was also sutured and covered with a layer of collodion. On rising the mare was placed in a box without litter. No food was given. The evening temperature was 38·8° C.

Next morning two of the sutures were cut and removed. The dressing and the cannula were changed. After cleansing the wound with tampons of wadding held in forceps the skin and muscular layers of each lip were sutured together. The patient received and ate its ordinary allowance of food. Swallowing was somewhat difficult, especially in the case of fibrous food. Portions of the latter and of the drinking-water escaped from the laryngeal wound. Temperature, morning, 38·6° C.; evening, 38·9° C.

During the next three days difficulty in swallowing persisted; a little of the drinking-water escaped by the wound. Temperature, morning, 38·5° C.; evening, 39·3° C. Particular care was taken in cleansing the external wound.

After the 23rd the difficulty in swallowing diminished. The wound granulated over the entire surface.

From the 24th to the 30th nothing particular occurred. The wound suppurated slightly, and gradually contracted. Neither food nor liquid passed through it. Temperature, morning, 37·9° C.; evening, 38·3° C. From the 28th 2 to 2½ drachms of iodide of potassium were given daily in the drinking-water.

During the first week of October the animal showed signs of sore throat, including discharge from both nostrils and cough. This, however, diminished, and during the following week disappeared. On the 16th October the external wound had closed.

On the 20th and 22nd the mare was exercised at a trot in the riding

school. There was still a slight abnormal sound during inspiration, but the dyspnœa and difficulty in breathing, which had been so marked before operation, had disappeared.

The animal was returned to M. M— on the 28th October, and went to work during the early part of November. It worked in a brougham without interruption and without showing any difficulty with breathing. Eighteen months later the owner made the following statement:

"Since leaving the school the mare has worked every day. For the first three weeks breathing was still a little noisy, but during the course of December this trouble disappeared, and since then I have never heard any roaring, even in heavy work."

54. An eight-year-old Anglo-Norman horse belonging to M. M—, 232, Faubourg St. Honoré, Paris, left in hospital 13th June, 1896.

Had commenced to roar about a year before. The difficulty in breathing gradually increased. At the time of entry the horse was incapable of trotting work.

Tested in the riding school it roared very loudly in a few minutes.

On the 15th June it was operated on under chloroform, and the left arytænoid cartilage removed. A small fragment of the articular angle was left. Dressing was carried out as in the first subject. Two hours after operation the temperature was 39·3° C., and in the evening 39·6° C. No food was given for the first twenty-four hours.

Next morning the dressing and cannula were removed. The skin and muscular tissues of each lip were sutured together. On returning to its box the horse drank a bucket of water placed on the ground and began to eat. It consumed all its food, though swallowing was a little painful; the meal was interrupted by attacks of coughing, and water, oats, and fragments of hay were discharged through the wound. In the intervals the horse appeared a little dull and depressed. Temperature, morning 39·1° C., evening 39·4° C. After-treatment simply consisted in cleansing the external wound night and morning.

On the 17th the depression seen on the previous evening had disappeared. Temperature 38·4° C. Inspiration was difficult and noisy. The margins of the wound were drawn apart. When eating a little water and food escaped from the orifice. During the following days the difficulty in swallowing diminished, respiration became quiet, and the temperature fell to normal.

On the 22nd the muscular sutures were removed. Neither food nor drinking-water passed by the wound. The lips were granulating over their entire surface. Iodide of potassium was then commenced. The wound gradually contracted.

By the 11th July the larynx had closed. On the 17th the wound was entirely healed.

On the 18th and 19th the horse was trotted in the riding school. At the end of five or six minutes the inspiratory sound became marked, but was very different both in character and intensity from that noted before operation. During the first week of August the animal returned to work in a brougham, work for which its roaring had previously unfitted it.

In September, 1897, M. M— sent me the following report:

"Since operation the horse has worked very well. In warm weather the roaring sound still occurs, but to a very trifling extent, and does not prevent the horse being perfectly 'workable.'"

55. A ten-year-old Dutch mare, belonging to M. S—, 6, Rue Dieu, Paris, affected with chronic roaring, which appeared to have developed after bronchitis. Left in hospital 20th October, 1895.

The roaring was noticed when the animal first returned to work after illness, and gradually became more marked despite internal treatment. The animal could still be worked, but respiration was difficult, and dyspnœa continually appeared imminent.

Trotted in the riding school the mare roared loudly. By continuing for a few minutes longer dyspnœa was produced; the flank movements were very rapid, the nostrils widely dilated; inspiration was painful, and the appearance of the face anxious. Nothing abnormal was found on examining the nasal cavities, larynx, and trachea.

Operation on the 22nd October. The parts having been prepared the lower surface of the larynx and the first tracheal ring were incised. On dilating the wound paralysis of the left arytænoid was detected. The cartilage was removed, the parts dressed with gauze, double muscular and cutaneous sutures inserted, and the animal was placed in a box without litter. The evening temperature was 38·7° C.

Next day the dressing and cannula were removed; the muscular layers were united to the skin on each side by three interrupted sutures. Litter was again provided. Food and drink were given as usual after operation. Temperature, morning 38·3° C., evening 38·5° C.

During the following days a portion of the drinking-water and fragments of food mixed with saliva returned through the nostrils and operation wound. Feeding was interrupted by attacks of coughing. Temperature, morning 38·2° C., evening 38·9° C.

On the 1st November the difficulty in swallowing had disappeared. The laryngeal wound was covered with granulations and reduced in length to one half. Neither food nor liquid escaped by it. Administration of iodide of potassium was commenced. On the 15th the wound had closed. The animal left hospital on the 24th November.

Result.—At the commencement of December the mare returned to work. A little whistling was then noticed at a trot. By June, 1896, this had disappeared even at the fastest paces. Nothing more than rather loud respiration could be detected. There was no roaring sound, nor was the respiration in any wise impeded.

56. A nine-year-old Hungarian horse, belonging to M. S—, 6, Rue Dieu, Paris, suffering from chronic roaring. Left in hospital 24th September, 1896.

Had been in M. S—'s possession for five months. The roaring varied in intensity from time to time. Occasionally there was coughing and slight whitish, frothy discharge from both nostrils. M. S—

declared that the animal could not work at a trot, and on leaving it with us insisted on my at once performing the same operation on it as was practised on his other horse.

External examination of the larynx and trachea revealed nothing abnormal. After a few minutes' trotting the horse produced a roaring sound, which rapidly became aggravated. This test was repeated each morning for the following three days. On each occasion whistling occurred after a couple of minutes, and soon became very loud, while dyspnœa threatened.

Operation on the 28th under chloroform anæsthesia. The larynx was opened and paralysis of the left arytænoid detected. I removed the cartilage, leaving a small fragment of the articular angle in the depths. The intra-laryngeal wound was not sutured. A gauze dressing was inserted and fixed in position by two sutures passed through the skin and muscle. The sutures also served to steady the cannula.

The animal did not rise until ten minutes after the hobbles had been removed. It was then returned to its box and kept without food for twenty-four hours. Morning temperature 38° C.; evening temperature 38·4° C.

Next day the sutures were cut, the dressing and cannula removed, and the superficial wound cleansed. The skin and muscular layers of each lip were united by three interrupted sutures. To facilitate breathing the lips of the wound were kept widely open for some days. The patient was placed on ordinary diet, which it ate with good appetite. A little saliva, water, and food escaped by the wound. Temperature, morning 38·8° C., evening 39·5° C.

During the following days treatment was confined to cleansing the external wound night and morning with fragments of wadding held in dressing forceps.

From the 7th October food and liquid ceased to escape by the larynx. From the 10th to the 30th 2 to 2½ drachms of iodide of potassium were given daily in the drinking-water. On the 23rd the superficial wound had completely healed.

On the 28th the horse was trotted and galloped in the riding school. At the end of ten minutes at a trot, and of five minutes at a gallop, slight abnormal breathing sounds were still audible.

M. S— kept this horse for work. He reported on the 21st January, 1899:

"During the months following its return to work the horse was able to make long and rapid journeys without showing more than slightly noisy breathing. On starting out it coughed and discharged a little whitish mucus from the nose for the first mile. Even at the present time there is a slight discharge on commencing work, but once the animal warms to its work respiration becomes normal, even at a rapid trot. In harness this horse has made continuous journeys of fifteen miles without being distressed, and has often made the double journey, amounting in all to thirty miles, with a rest of one hour halfway. In the saddle it roars a little at rapid paces, but the sound ceases when the horse has galloped rapidly for some distance or after it has jumped. It is perfectly useful for all kinds of work."

57. A six-year-old Anglo-Norman horse, left in hospital 24th January, 1895.

In March, 1894, this horse had suffered from pneumonia. On returning to work towards the end of the following month it had shown difficulty in breathing, which was noisy. During the hot weather the roaring increased and the animal underwent various treatment, but without improvement. It was finally sent to Alfort to be operated on.

Nothing abnormal was detected on exploring the nostrils and nasal cavities, or on externally examining the larynx and trachea. At a slow trot the horse roared after five minutes. When pushed it almost immediately began to whistle loudly, producing a noise audible from a considerable distance; respiration became painful, the nostrils dilated, and the animal, though in very good condition, was obliged to slacken its pace.

Having been prepared for several days and submitted to two further tests, which gave results similar to the first, the horse was subjected to operation on the 28th January under chloroform.

The larynx having been opened, the left arytænoid was seen to be paralysed. The cartilage was removed, only a very small fragment of the articular angle being left, and at the same time the vocal cord was excised. The mucous membrane was not sutured. The parts were dressed with gauze, and sutures passed through the muscles fixing the gauze and cannula in position. The skin was separately sutured.

The animal was kept without food throughout the day. After-treatment was similar to that in the preceding case. From the second to the fifth day the temperature oscillated between 39° C. and 39·7° C. Up to the 10th February saliva, drinking-water, and fragments of food passed into the larynx. After the latter date the external wound healed rapidly. On the 8th administration of iodide of potassium had been commenced. On the 17th February the wound was closed.

When exercised in the riding school on the 1st, 3rd, and 5th of March, the horse roared much more loudly than before operation.

It left hospital on the 7th March. Some days afterwards tracheotomy became necessary.

58. Four-year-old Norman horse suffering from severe roaring, which prevented its being used. Left in hospital on the 31st August, 1898.

When ridden in the riding school a roaring sound was produced in a few minutes, and rapidly grew more marked.

On the 5th September operation was performed; the left arytænoid cartilage and internal wall of the corresponding ventricle of the larynx were removed. Dressing and after-treatment were similar to those in the preceding cases.

Next day the morning temperature was 39·1° C.; evening temperature 59·8° C. On the 7th the temperature again became normal.

Until the 11th a little liquid and fragments of food passed through the laryngeal wound. After the 12th, 1½ to 3 drachms of potassium iodide were given daily in the water. Trifling discharge occurred from both nostrils.

On the 22nd the external wound had closed. Discharge still continued, but gradually diminished during the succeeding few days, and disappeared a week later.

On the 5th October exercise was commenced, a quarter of an hour's walk being given every morning. During the first few days the horse was seized with violent fits of coughing on leaving the stable.

On the 7th it was exercised in the riding school. Roaring occurred after a few minutes' exercise. Two days later it was again tried at a trot; in three minutes the test had to be given up, so severe was the roaring.

During the night of the 3rd November the respiration suddenly became extremely difficult and asphyxia threatened. Tracheotomy was therefore performed.

Some days later the larynx was reopened. The seat of operation was occupied by a contracting cicatrix, extending the entire depth of the larynx.

Remark.—I could relate a number of cases showing the value of arytænoidectomy, and the failure of other methods of operation. I have chosen the most characteristic. Two horses belonging to one owner, M. M—, treated by ablation of the arytænoid, were both cured. Two horses also belonging to one owner, M. S—, and treated in the same way, were also quite cured.

The true value of those other operations which have been so greatly vaunted is shown by the results of Cases 50 and 51. With them one may rely on ensuring the greatest possible chance of failure.

III.—THORAX.

FISTULOUS WITHERS.

59. A ten-year-old Irish mare, sent for examination on the 30th January, 1899.

For several years this mare had been exclusively used for saddle work. Towards the end of December, 1898, a hæmatoma developed on the withers, was punctured on either side at its lowest point, the cavity injected with antiseptic liquids, and the surface repeatedly blistered.

The wound on the right side closed in three weeks, but that on the left suppurated and became sinuous. The pus, which had difficulty in escaping, macerated the supra-spinous ligament, which became necrotic.

State on Examination. The right side of the withers was marked by a cicatrix; the left, especially towards its posterior part, exhibited a diffuse, very tender swelling, pierced about an inch from the highest point of the dorsal spinous processes by a sinuous wound into which a probe penetrated for a distance of nearly four inches. Blood-stained pus ran from the opening.

The sinuous tract ran obliquely forwards and slightly upwards, appearing to end over the portion of the supra-spinous ligament covering the fifth dorsal vertebra.

Treatment.—On the 30th January the sinus was laid open parallel to the line of the superior spinous process for a distance of four inches, exposing the necrotic portion of the ligament, which was excised with the bistoury and curette. The wound was cleansed, the margins were touched with tincture of iodine, the parts powdered with iodoform, the edges brought together by three sutures, and covered with layers of iodoform gauze fixed in position with collodion.

The dressing was renewed every second day until the 10th February, at which time the back portion of the wound was granulating, though a fresh necrotic point had developed in front.

On the 11th February the animal was cast and the anterior angle of the wound laid open, when the cartilaginous disc covering the superior spinous process and a part of the supra-spinous ligament were seen to be necrotic. With the help of the bistoury and curette the dead structures were removed. The wound was washed with one per thousand sublimate solution and dressed with tannoform.

During the following days suppuration was trifling, and hopes of cure were entertained. After a period of real improvement a fresh complication occurred: at the commencement of March the liga-

mentous tissue covering the sides of the superior spinous process of the third dorsal vertebra became necrotic.

The mare was left in hospital on the 5th March. At that date the dead tissue was removed. The dressings used were 3 per cent. creolin, tincture of iodine, iodoform, and iodoform gauze.

On the 12th March the skin was seen to have become separated over the median line in front of the superior spinous process of the third dorsal vertebra, where a smooth spot appeared. Treatment was continued until the 28th March without much improvement. At that

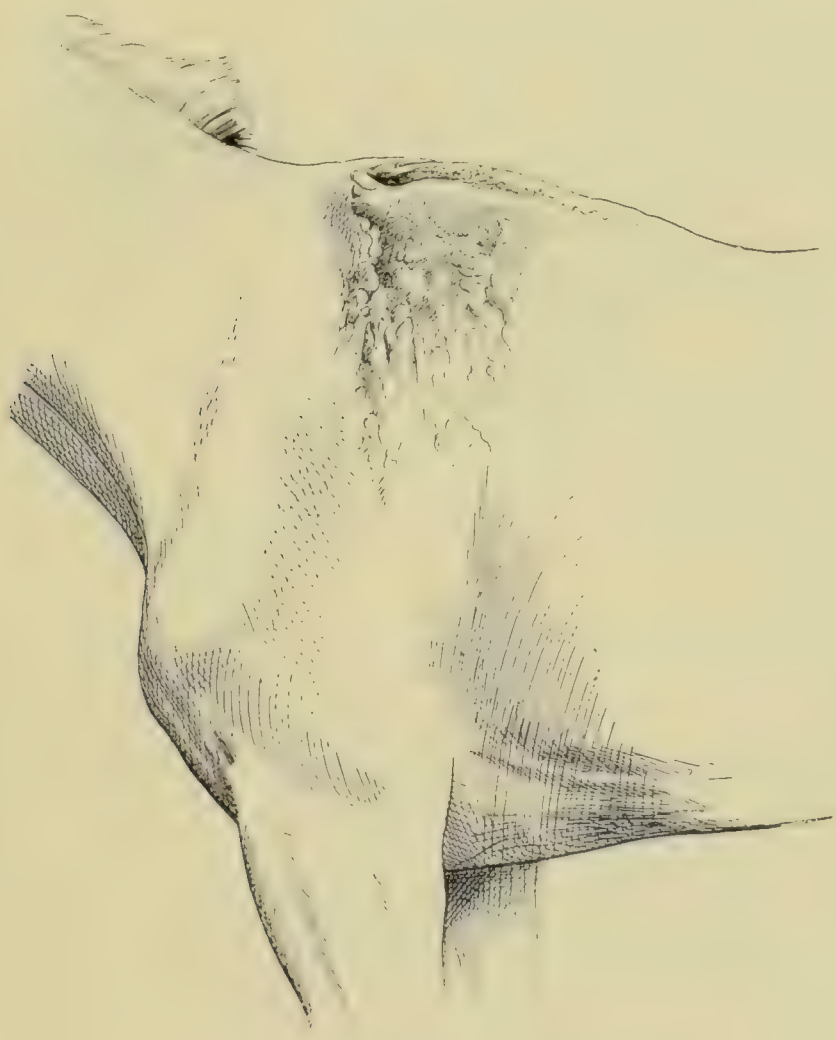

Fig. 34.

date marked swelling appeared in front of the wound, pointing to recurrence of necrosis in the supra-spinous ligament. We determined not to operate further, but to continue the antiseptic treatment.

From the 1st to the 15th April the wound did not show the slightest improvement. Towards the back for a distance of about six inches it was healing, but the separation of the skin and the swelling around the anterior angle caused us to fear that necrosis was extending in the supra-spinous ligament.

From the 15th to the 30th treatment consisted in applying to the necrotic parts a mixture of sulphate of iron and sulphate of copper, and in spraying the parts daily with creolin, followed by application of a dressing saturated with traumatol.

Under the influence of the spray and of the traumatol, especially of the former, suppuration diminished, and swelling became confined to the right side. It surrounded an opening, at the base of which a necrotic fragment of the ligament could still be seen. The parts were again opened, allowing the spray to play directly on the necrotic point, which was cauterised with a mixture of the sulphates of iron

Fig. 35.

and copper. Under the action of the 2 per cent. creolin and 1 per cent. lysol spray the eschar separated in a few days.

The wound finally granulated throughout, and healing became assured.

During the following days suppuration was trifling. Both wounds (Figs. 34 and 35) made regular progress towards cicatrisation.

Remark.—Antiseptic treatment, when thoroughly carried out, often gives good results in the treatment of fistulous withers, and in fistula of the neck and poll; but even when supplemented by removal of necrotic fragments of the supra-spinous ligament and the cartilaginous layer covering the superior spinous processes, recovery is frequently slow and uncertain. Sometimes necrosis has extended beyond the limits of the tissue removed, especially in front; sometimes the suppuration which accompanies large operative wounds itself causes recurrence. In the case just mentioned, despite excision and the observance of ordinary antiseptic methods, necrosis twice recurred in

front of the wound within the substance of the supra-spinous ligament. It was finally arrested and the wound rendered healthy by warm antiseptic spraying, which has the advantage over lotions and irrigations of penetrating the dead tissue and destroying the infectious agents in the depths.

ABSCESS IN THE LEFT COSTAL REGION—NECROSIS OF THE LAST RIB.

60. Eleven-year-old gelding, left in hospital 6th June, 1896.

A year before this horse had shown on the left surface of the chest over the last ribs a large swelling, which finally suppurated. The wound resulting from opening the abscess became sinuous. The animal having been cast on the 5th May for castration, the veterinary surgeon who operated took advantage of the occasion to explore the tract. The parts were afterwards irrigated with carbolic solution, but refused to heal.

State on Examination.—On the left side of the chest, over the centre of the last rib, was a sharply-defined swelling, the centre of which was pierced by a sinuous tract running obliquely inwards and forwards. A probe penetrated for a distance of four inches.

The horse having been cast, the sinus was laid open in the axis of the last rib, a portion of which was then seen to be necrotic. It was resected. On passing the finger into the wound the two ends could be felt about one inch apart. After antiseptic irrigation of the wound a rubber drainage-tube was introduced and fixed to the skin by sutures.

During the following days the wound was cleansed and injected with a solution of iodine varying in strength between 20 and 30 per cent. Suppuration was trifling.

On the 15th the rubber tube was removed; the iodine injections, however, were continued. The wound was daily plugged with gauze. The surrounding tissues showed little swelling.

On the 25th the deep portions of the operative wound had to a large extent filled up. The plugging was discontinued. From this date treatment simply consisted in washing out the wound.

A week later the animal was returned to work. By the end of July the wound had healed, and the trifling swelling which remained was quite painless.

FRACTURE OF THE FIRST RIB IN THE HORSE.

61. Eight-year-old well-bred chestnut mare.

History.—Had been worked for three hours in a victoria; returned home with great difficulty and exceedingly lame in the off fore-leg.

State on Examination.—The near fore-heel showed signs of a recent overreach. The animal was in great pain, and supported the weight of the body mainly on the hind legs; the off fore-leg was flexed, the knee and fetlock bent, and the outside of the toe just touched the ground. The elbow was lower than normal, but was not unusually "dropped."

By forcing the knee backwards, and thus straightening the leg, the animal was enabled to take one step with the sound limb; but immediately the knee of the injured limb became in the least degree bent the leg collapsed, and the animal nearly fell. Progress was facilitated by pulling forward the lame leg as far as possible, and then pressing on the knee until a step had been taken with the sound leg. The most marked symptoms were absolute inability to advance the leg, and great difficulty in keeping it perpendicular. No fracture of any of the leg bones could be distinguished. Crepitus was entirely absent.

Fig. 36.

Diagnosis.—Fractured first rib.

Prognosis.—Unfavourable so far as useful recovery was concerned.

Treatment.—Slinging and rest.

During the three weeks and three days the animal was kept the limb was always flexed and turned slightly inwards, so that the outside toe of the foot became worn.

Post-mortem examination showed fractured first rib (see Fig. 36); the surrounding muscles were not lacerated or ruptured. Only a small provisional callus had formed. The broken and overlapped pieces of bone were freely moveable, and not (as might appear from inspection of the figure) rigidly fixed together.

Mr. H. G. Rogers' case, *Veterinarian*, 1894, p. 78.

MYOMA OF THE ŒSOPHAGUS.

62. A fifteen-year-old gelding, brought for examination on the 4th January, 1895.

A fortnight before a considerable swelling had been noticed in the lower portion of the jugular furrow, which the owner thought due to collar pressure.

During the following days the animal began to roar as soon as put to work. The respiration became very rapid and gasping, so that asphyxia appeared imminent. When swallowing the food passed slowly through the swollen region and showed a tendency to stop. At certain times a part of the liquid taken was rejected through the nostrils.

On trotting the animal almost immediately began to roar, and the swelling in the jugular region increased, dilating and contracting synchronously with the respiratory movements.

Diagnosis.—Tumour developed around and compressing the œsophagus and trachea, or the nerves in this region.

The lesion being principally thoracic no useful intervention seemed possible, and the animal was slaughtered.

Autopsy.—In the lower third of the neck the œsophagus was dilated. Its thoracic portion was very large, firm, and hard, forming a kind of elongated, fusiform tumour, eighteen inches in length and ten in

diameter, weighing over twenty-six pounds. This tumour had developed at the expense of the muscular coat. Sections appeared greyish in colour, and exuded a milky pus.

The lumen of the œsophagus, which was partly obstructed by masses of food, was greatest opposite the centre of the swelling, and gradually diminished towards the extremities; near the cardia it was reduced to very small dimensions. In the centre of the swelling the wall of the tube was four inches in thickness.

The anterior portion of this growth had compressed and flattened the bronchi and the last rings of the trachea, greatly diminishing their calibre. Microscopic examination of the swelling showed it to be a myoma of unstriped muscle—leiomyoma.

CHRONIC ENDOCARDITIS.

63. A six-year-old entire horse, bought at Beauce on the 14th February, 1897, and brought to the School for examination on the 20th.

The day after its arrival in Paris the animal had appeared dull and tired. It was left in the stable. It only ate a small part of its food. A veterinary surgeon who was called in at first regarded the case as one of pneumonia, and prescribed external application of mustard, and internally a mixture, the principal constituents of which were tartar emetic and iodide of potassium.

During the next four days the animal was not markedly worse, but the symptoms persisted.

At the first glance this animal appeared as though suffering from some pulmonary disease. It was rather stiff and sleepy, carried the head low with the eyes half closed; the conjunctiva was moderately injected and slightly infiltrated. The flank movements were more rapid than usual, the respirations 22 per minute, and expiration was double; the pulse was 60, small and irregular.

We auscultated the chest, commencing on the right side. The vesicular murmur was very feeble, and in certain parts of the lower half of the lung was almost imperceptible; some borborygmus was noted; the heart-beats were especially noticeable, being unequal and irregular in rhythm. This at once led us to examine the heart. We noted a strong systolic murmur without particular timbre, which covered the systolic sound and continued during the short pause. Furthermore, the contractions were of irregular strength, and every three, four, or five pulsations were followed by a pause, equal in length to an entire cardiac cycle. Auscultation of the left lobe of the lung revealed diminished vesicular murmur in the lower half.

Diagnosis offered no difficulty. Evidently this horse was suffering from old-standing mitral insufficiency, complicated at that moment with pulmonary congestion.

The animal was rested for a week. When brought back on the 28th February the secondary troubles noted on the former examination had disappeared. Externally the animal appeared in good health. The respirations were only 14 per minute.

On questioning the seller it was learned that this horse had suffered from strangles in October, 1895. A month after recovery it was used

for farm work, and had never shown any disturbance which could have aroused suspicion of heart disease (?). It had never had any internal disease other than strangles.

64. Sixteen-year-old gelding, brought for examination on the 27th March, 1897.

Was in heavy work. Between the previous December and the commencement of March it had been very hard worked. A month before its appetite was noticed to decline, and its condition to suffer, while the limbs became greatly enlarged. The horse was rested for about a fortnight. On returning to work it suffered from some respiratory disturbance, and was therefore brought for examination.

The hind limbs were œdematous, and almost half as large again as normal. In addition to symptoms of acute bronchitis we noted very strong pulsation in the carotid and subzygomatic arteries.

On auscultating the heart the first sound was heard to be feeble and double; the second was obscured by a murmur which continued throughout the long pause,—that is, by a murmur due to aortic insufficiency. All the accessible arteries exhibited strong pulsation. The carotid and the subzygomatic visibly rose at each beat of the heart.

Treatment.—Administration of iodide of potassium in daily doses of $2\frac{1}{2}$ drachms for the first two weeks in each month.

The horse still remained capable of work until the commencement of August. Shortly afterwards, however, it had to be slaughtered.

Autopsy.—Lesions of fibrous myocarditis. The aortic sigmoid valves were thickened, wrinkled, and their faces irregular. The right side of the anterior small valve near the corpus Arantii presented a narrow perforation; the lower surface of the left side, close to the free border, was occupied by a vegetation as large as a hempseed. There was marked insufficiency, a large space existing between the valves when approximated.

The anterior lobe of the right lung contained a patch of chronic pneumonia.

65. A fifteen-year-old gelding, brought to the School on the 5th June, 1898, to be used as a subject in the practical surgery class.

The animal was thin, emphysematous, and a crib-biter. On auscultating the heart a strong musical murmur, covering the second sound and the long pause, was heard over a large surface. The first heart-sound was diminished. There was no arterial "dancing." The pulse was of practically normal volume.

At the autopsy the heart was found to exhibit sclerosing myocarditis of both ventricles and changes in the aortic sigmoid valves, which were slightly thickened and showed several small indurated vegetations. Although the right and left valves were perforated parallel to their free border insufficiency was trifling.

This case shows once more that a strong murmur due to insufficiency does not necessarily imply large valvular lesions. The character of the pulse was explained by the very trifling hiatus, and by the lesions of the myocardium.

MYOCARDITIS—CARDIAC INTERMITTENCY.

66. Twelve-year-old gelding, left in hospital 29th April, 1896.

This horse had worked daily in a brougham for several years, and had done good service. During the months preceding entry, however, it had been dull in the stable, and for a considerable time had refused part of its food. At work it was "soft," and carried its head low, and sweated readily.

State on Examination.—Auscultation of the heart revealed intermittency; the first heart-sound was of a "rolling" character, and was regarded as systolic. The pulse was full, strong, and numbered 40 per minute. After a few minutes' trotting the heart-beats became violent; the first sound was prolonged, and the second double.

Certain peculiar symptoms had been noted, which appeared due to brain mischief. The animal was almost always depressed and somnolent. Sometimes it walked in circles round its box, sometimes it suddenly stopped while eating. If the front legs were crossed it remained as placed for some moments. It was timid and very irritable, being frightened by the slightest movement; when ridden it would often stop in front of any object, such as a piece of paper, and refused to proceed. The urine contained only traces of albumen. There were no ocular lesions.

Diagnosis.—Chronic myocarditis, probably complicated by chronic disease of the brain, dropsy of the lateral ventricle, or tumour in the choroid plexus.

On the 30th April, on auscultating the heart, intermittencies were noted lasting for a complete cardiac cycle, and repeated after every three or four beats. One and a half drachms of iodide of potassium were given in the drinking-water, and the dose progressively increased to 2½ drachms. The animal's condition became aggravated. The intermittency grew longer and more frequent. On being informed that his horse was suffering from an incurable disease the owner had it slaughtered.

Autopsy.—The heart was larger than normal, the left ventricle being especially hypertrophied. The walls of the auricles had undergone hardening. The right ventricle also showed patches of sclerosis. There were no valvular lesions.

The right kidney was smaller than the left. Its surface showed slight projections and depressions, and its capsule was more adherent than normal. Sections exhibited all the appearances of chronic atrophic nephritis.

There was no hydrocephalus. The plexus choroides was greatly thickened, œdematous, and contained small cholesteatomata.

67. A ten-year-old entire horse, left in hospital 23rd December, 1896.

Three years before it had suffered from purpura hæmorrhagica. After recovering it had always worked well and had shown no other internal disease. During the last few months the animal had appeared weak, soon lost breath, and on returning to the stable at once lay

down. A veterinary surgeon, who was called in, was struck by the slowness and irregularity of the pulse. He prescribed nux vomica and digitalis. This treatment producing no improvement the animal was sent here.

Condition on Entry.—The conjunctiva was pale; the pulse was feeble, irregular, and intermittent; there was no venous pulse. On auscultating the heart pauses were noted after every third or fourth pulsation. They lasted for a period equal to one or two complete heart cycles. Furthermore, the first beat of the heart was double.

Treatment.—Iodide of potassium in daily doses of 2½ drachms. Appetite was preserved, and the animal ate freely.

On the 16th December examination of the heart and pulse revealed no change. After a few moments' trotting the heart-beats became accelerated and violent, and the pauses, which at rest had occurred after every third or fourth pulsation, were deferred for much longer intervals. Their duration still equalled that of a complete heart cycle. The first pulsation which followed an intermittence was stronger than the others. The pulse was small and feeble, contrasting with the violence of the heart-beats.

After some minutes' rest the intermittency resumed its previous frequence. During the next few days the condition remained stationary.

The animal left hospital on the 9th January. Treatment had produced no improvement, but the owner was advised to continue it for fourteen days each month.

68. A three-year-old mare, brought for examination on the 14th December, 1895.

The animal had been bought a week before at a cab sale. In work it rapidly lost breath, slackened its pace, and stopped, showing signs of violent dyspnœa. The neck was extended; the face appeared anxious; respiration was very rapid, and the flank movements were short and irregular.

At the first examination, made after a period of rest, breathing was regular. There was no double flank movement and no check during expiration. The cough was not like that of broken wind. The pulse was irregular, a series of three or four normal pulsations being followed by a feeble beat. On auscultating the heart no murmur and no change in the sounds could be detected, but the rhythm was not quite regular, three or four normal beats being followed by a slower and feebler contraction.

After a few minutes' trotting the heart beat violently and irregularly; the second sound was diminished and almost lost, but the irregularity of the pulse was less marked. At the end of about two minutes pauses could be detected approximately equal in duration to two cardiac cycles; these were followed by two slow, and afterwards by four or five rapid contractions; beats then succeeded in increasingly rapid succession until the next pause. The pulse showed some want of rhythm. At the end of ten minutes intermittency had disappeared, and all that could be detected was irregularity in the strength of the cardiac contractions and pulse.

On again exercising the horse the same peculiarities were noted. The intermittency recurred two or three minutes after exercise was stopped, and again disappeared some minutes later.

69. A ten-year-old gelding, brought for examination on the 16th January, 1896.

Had been in the hands of the same owner during four years, doing regular work delivering parcels, sometimes at a walk, sometimes at a trot. Had been healthy for that period. Both at work and in the stable this horse coughed rather frequently. A month before examination it began rapidly to lose breath, and to cough more than usual.

The patient was emphysematous. It showed a distinctly double flank movement, and had a short, dry, paroxysmal cough. Auscultation of the lungs revealed sibilant *râles* and a dry crepitant sound. On auscultating the heart, every fourth or fifth contraction was followed by a pause equal in length to two cardiac cycles. The pulse showed similar characters.

This intermittency disappeared during exercise, but returned after a few minutes' rest.

Iodide of potassium and arsenical preparations were prescribed, to be continued for a week and interrupted for a similar period.

70. A seven-year-old entire horse, left in hospital 31st July, 1897.

Three weeks before had been attacked with pneumonia, which had not been detected until in an advanced stage, and had left troubles regarded as due to heart disease.

On entry the animal's general condition was satisfactory. There were no visible signs of disease. Respiration was normal. The pulse was rapid, small, and intermittent. On auscultating the heart the first sound was double, the second diminished, and pauses occurred after every sixth or eighth normal contraction, each pause lasting as long as a complete heart cycle.

Treatment.—Iodide of potassium in 2½-drachm doses daily, gradually increased by the end of a week to 4 drachms.

During the following days intermittency persisted with the same characters. After the 10th August the pauses occurred at longer and less regular intervals. On the 20th August, when the animal left hospital, they only occurred after every fifteenth to twentieth pulsation.

71. A six-year-old gelding, left in hospital 7th December, 1897.

Had been worked very hard. Three days before, when sweating freely, had been exposed to rain for more than an hour. That evening the animal refused food. A veterinary surgeon who examined it prescribed treatment. The animal was brought here on the morning of the succeeding day. The temperature was then 40·5° C., the conjunctiva yellow, the eyes half closed; the nostrils discharged a little rusty-coloured mucus; the lower third of the chest was dull, the right side revealed moist crepitation; the pulse was large and strong, 56 per minute; respirations were 22 per minute.

Diagnosis.—Pneumonia.

Treatment.—Bleeding, sinapisms, 5 ounces of alcohol, mashes and milk.

Next day the temperature was 39·9° C., respirations 30, pulse 63. The animal was depressed and sleepy. Nevertheless it took milk and hay tea, to which alcohol had been added.

On the 9th a tubal murmur could be heard on the right side. The heart-beats were violent and audible on either side. Temperature 40·7° C., pulse 64, respirations 32. Sulphate and bicarbonate of soda were further prescribed.

On the 10th and 11th the animal was more depressed; it could scarcely stand, and appeared as though suffering from laminitis in the fore-feet.

On the 12th these signs of weakness and of congestion about the feet had disappeared. The pneumonia was undergoing resolution. A moist crepitant *râle* could be heard. Temperature 38·5° C.

On the 13th the heart became intermittent, pauses occurring after series of four to twelve contractions. All treatment was stopped.

On the 14th intermittency was more frequent. Of five pauses, four usually occurred after a regular series of four pulsations, the fifth after an irregular series of two to eight.

On the 16th the pauses were less numerous. They became less and less frequent until the animal left hospital.

[An interesting contribution to the study of heart disease in the horse, by Professor Stockman, appears in the *Journal of Comparative Pathology and Therapeutics* for 1894, p. 138.]

HYDATID CYST OF THE HEART.

72. An eight-year-old Percheron gelding, which had died suddenly during work on the 9th August, 1893. The autopsy was incomplete, but the heart was sent to us as it exhibited peculiar changes.

It was of large size, and towards the centre of the left ventricular wall showed a swelling as large as a turkey's egg, yellowish white in colour, the surface marked—especially towards the periphery—with fine vascular branchings. The swelling was uniform, fluctuating, and thin-walled.

Incision gave exit to a serous liquid containing in suspension a few whitish flocculi. Though for the most part smooth, the wall of the cyst was irregular in places, marked with slight depressions and prominences. Microscopic examination of a scraping from the internal surface showed scolices and numerous hooks. The wall was formed of two distinct membranes somewhat loosely united: the external, forming the hydatid membrane or cuticle, exhibited a number of caseating and calcified patches; the internal, or germinal membrane, was greyish in colour, thin, and very delicate.

The cyst measured three inches and a half in greatest length, and two inches and three quarters to three inches in diameter. It projected above the surface of the ventricle to the extent of more than an inch. Two thirds of the thickness of the wall of the ventricle were destroyed, so that the muscular tissue, which should have been nearly

two inches in thickness opposite the centre of the swelling, was reduced to about half an inch.

INTRA-MURAL CARDIAC ABSCESS IN A COW.

73. *History.*—About a year previous to death the animal had suffered from "foul in the foot" with fever; the foot had not perfectly healed until after three months. A week before death, which occurred very suddenly, the cow had shown trifling symptoms. It had not been treated.

Post-mortem examination showed all the internal organs except the heart to be healthy. Projecting from the ventricular septum into the right ventricle was an eminence the shape of an English cottage loaf, measuring three inches in diameter by two in depth from its summit to the level of the ventricular surface of the septum. The endocardium had become softened and entirely removed from its salient parts by the current of blood, and was replaced by several layers of coagulated lymph. On incising this fluctuating swelling, thick, creamy, odourless pus escaped, leaving a very large cavity in the substance of the septum, which, however, was intact on the side of the left ventricle. There was slight hypertrophy, but the walls of the heart and the valves were otherwise healthy.

Note.—Professor Walley regarded the abscess as pyæmic in origin, and consequent on the above-mentioned attack of "foul in the foot." Death was probably due to syncope.

Prof. Walley's case, *Journ. Comp. Path. and Therap.*, 1894, p. 65.

FOREIGN BODY IN THE PERICARDIUM—INTRA-PERICARDIAL HÆMORRHAGE.

74. On the 6th June, 1892, a cowkeeper in the neighbourhood brought us the body of a cow which had died during the night, without having previously shown any signs of grave disease.

Post-mortem examination proved that the animal had died from intra-pericardial hæmorrhage produced by a fragment of iron wire. This fragment, starting from the reticulum, had pierced its anterior wall, passed through the diaphragm, penetrated the pericardium, and attained the heart opposite the posterior vascular furrow, an inch or two from the point, the sharp extremity as usual being in front.

The foreign body having, as commonly happens, produced chronic inflammatory lesions in the tissues traversed, there is some room for doubting the extreme suddenness of death and the absence of more or less grave premonitory disturbance, either of continued or intermittent character, during the days preceding the end.

Questioned on this point, the owner gave the following very precise information:—"I purchased this cow on the 22nd January last. Apart from a trifling ailment lasting for a few hours, which she showed soon after arrival, her soundness never appeared doubtful. One thing, however, struck me. Although she showed excellent appetite this beast never grew fat, but this I attributed to the fact that she was a very good milker. On the evening before the day of death I passed through

the stable as usual about ten o'clock, and she then seemed to me to be ruminating like the others. At any rate I noticed nothing remarkable, and at six o'clock next morning she gave the same quantity of milk as on the preceding days. Next morning she was found dead. As to the swallowing of some sharp body, or the cause of death itself, the explanation is as follows:—At the beginning of February I received from Brittany some hay in bales fastened with iron wire. A fragment of this wire must have fallen into the food given to this animal and have been swallowed."

As none of this hay had been used after the first week of March, the fragment of wire had remained for about three months in the stomach and in the tissues it had traversed before producing fatal results.

RUPTURE OF THE RIGHT VENTRICLE IN THE HORSE.

75. A five-year-old well-nourished brown cart gelding, 16.2 hands high.

History.—Had recently been purchased and only worked for a fortnight. On the 1st July, 1896, had made a long journey involving much hill climbing; arrived at its destination, the animal had to draw and back through new-made ground. It suddenly plunged, fell, gave a few convulsive struggles, and died.

Autopsy.—The right side of the thoracic wall was wounded over the ninth rib by the broken shaft, but the chest cavity was not penetrated. Abdominal organs healthy. Right lung hypostatically congested, but lungs otherwise normal. The pericardium was distended with blood. On cautiously incising it and examining the heart three ruptures were found in the wall of the right ventricle; the first, about two and a half inches in length, situated almost centrally in the wall of the ventricle, was irregularly funnel-shaped, being large externally, and tapering down to an aperture about three quarters of an inch across, communicating with the interior of the ventricle. The muscular fibres were not shredded, but showed a comparatively "short" fracture. The second wound resembled the first, was two inches from the apex of the heart, about three quarters of an inch in length, and communicated with the ventricle by a mere point. The third was about one eighth inch across and a quarter of an inch in depth; it lay half an inch from the apex of the heart, but did not communicate with the ventricle. Measured at their thinnest points the thickness of the walls of the various heart cavities was as follows:—Right auricle five sixteenths of an inch; left auricle (close to junction with ventricle) two inches; right ventricle five eighths of an inch; left ventricle (near auricle) two and three eighths inches; near apex of heart one and a quarter inches; septum one and seven eighths inches.

Mr. Jno. A. W. Dollar's case, *Veterinarian*, 1896, p. 670.

RUPTURE OF THE PULMONARY ARTERY.

76. A two-year-old Irish setter, bought when five weeks old.

At the age of ten months had suffered from severe distemper, but had completely recovered, and afterwards enjoyed good health.

About three in the afternoon of the 2nd March, 1895, it was playing with another dog in front of its master's house, when suddenly it began running as though mad, leaped upwards several times, and fell dead. Poisoning being suspected, the cadaver was sent to the College.

Autopsy.—Extreme pallor of the visible mucous membranes. The spleen was large, and of the lilac tint common in lymphadenoma. The liver had undergone a certain degree of hypertrophy.

Lungs normal. The pericardium was considerably distended with blood. The organs about the base of the heart, the large vessels originating there, and the trachea, were covered with a layer of coagulated blood, infiltrated between the layers of the mediastinum.

On opening the pericardium a little red blood escaped. The cavity contained a thick clot moulded on the heart. Over the origin of the great arterial vessels the visceral layer presented a rupture about three eighths of an inch in length.

The heart was carefully examined, but neither ventricles, auricles, nor valves showed anything abnormal.

The external surface of the pulmonary artery was covered with a thick clot. On removing this we detected on the right surface of the vessel, about three eighths of an inch from the base of the heart, two transverse ruptures, one measuring a quarter of an inch, the other one eighth of an inch in length. Opposite these tears the artery was extremely thin, and showed several little atheromatous points. Escaping by these ruptures the blood had spread around the large vessels, thrust apart the layers of the mediastinum, lifted the visceral layer of the pericardium, which became ruptured under the pressure, and then by accumulating in the pericardial sac produced cardiac syncope and death.

IV.—ABDOMEN AND TAIL.

NECROSIS OF APONEUROTIC TISSUES IN THE FLANK.

77. A twelve-year-old gelding, left in hospital the 5th February, 1894.

Two months before this horse had suffered from colic and intestinal indigestion, for which the cæcum was punctured. During the following days a warm, painful, œdematous swelling developed around the wound, but nevertheless the horse continued to work for some time. As the wound became sinuous, suppurated freely, and resisted treatment by antiseptic injections, the animal was sent to Alfort.

The centre of the right flank displayed a granulating wound, nearly an inch in diameter, surrounded by induration which extended as far as the last rib. The pus was abundant, liquid, and offensive.

Diagnosis.—Necrosis of aponeurotic tissues in the flank.

The horse was cast on the table. The sinus was found to be about six inches in length, penetrated deeply, and ended in a large blind pouch. It was exposed, a counter-opening made at the lowest point, and a rubber drainage-tube inserted. The sinus was frequently washed out with creolin and sublimate solution.

By the 20th February swelling and suppuration had markedly diminished, and the animal seemed in a fair way to recovery. A week later, however, swelling extended below the lower wound, from which pus escaped freely. Fresh operation was decided on. On probing the lower wound a sinus, four inches in length, was found running obliquely downwards and slightly backwards, along the last rib. A counter-opening was made, and this second sinus drained like the former. The injections were continued, though the liquids used and the degree of concentration were varied. Among others, carbolic acid, sublimate, chloride of zinc, Villate's solution, and tincture of iodine were tried. A 20 to 30 per cent. solution of tincture of iodine and iodide of potassium was found most useful.

Recovery was not complete until towards the 15th June, though had the animal not been used in a carriage it might long before have been returned to work.

Remark.—Although the disease was remarkably obstinate we did not think it advisable to perform a radical operation, as this would have necessitated too great destruction of tissue and would not have been without danger, on account of the depth to which the sinus extended into the abdominal wall. We therefore preferred to confine ourselves to counter-openings, drainage, and antiseptic injections.

HERNIÆ.

78. A cart stallion brought to the external clinique on the 14th June, 1898.

A few hours before, when working in a dray, one of the arms of the windlass * had penetrated the left flank.

A large œdematous swelling was visible in the left flank opposite the stifle. On manipulation, the abdominal tunic was discovered to be ruptured, and slightly above this rupture the muscles were torn through. In order to confirm the diagnosis (of ventral hernia) the parts were explored per rectum. Four to five inches in front of the inguinal ring was a tear about six inches long in the abdominal wall, running obliquely forwards and outwards.

During the afternoon the animal was cast on the right side and chloroformed; the left hind leg was abducted, as in operation for strangulated inguinal hernia. After disinfecting the parts, M. Almy made an incision about six inches in length through the skin, in an oblique direction backwards and inwards, exposing a loop of slightly congested small intestine. This having been reduced, the muscles and aponeuroses forming the abdominal wall were seen to be irregularly torn, the several layers being ruptured in different directions. The muscular tissues were brought together with a line of silk sutures, which, however, were very difficult to insert on account of the condition of the tissues. A second row of silk sutures, crossing the former in an oblique direction, was inserted in the aponeurotic portion; lastly, the skin was brought together. A cotton-wool dressing was applied.

After removal of the hobbles the patient remained recumbent, not rising until the end of a couple of hours. Food was confined to gruel and milk. The evening temperature was 38·8° C., respirations 16, pulse 50.

During the three following days the temperature oscillated between 38·8° C. and 39·7° C. A considerable œdematous swelling developed around the wound.

Between the 17th and 20th the temperature rose to 39° C., sometimes even to 39·5° C., and the respirations became more frequent—45 to 50 per minute.

On the 20th the wound, after cleansing, was bright red, and almost entirely covered with granulations. A few small fragments of the aponeurosis, which had become loose, were excised. Some of the deep sutures were removed, the parts were dusted with iodoform, and a gauze dressing applied. Fever continued distinctly high, respiration was rapid and shallow.

From the 22nd to the 25th general disturbance diminished. The patient consumed all its food. On the 30th June it left hospital in a fair way to recovery.

When again seen on the 9th July the wound had healed, and the swelling disappeared; the hernia was cured.

* In France carts used for carrying casks are provided with a windlass for tightening the ropes by which the load is secured.—Jno. A. W. D.

79. A five-year-old entire horse, brought to the school on the 5th March, 1895. Since the previous night it had suffered from colic.

Examination of the upper inguinal rings left no doubt as to the origin of the abdominal pain, which was due to acute left-sided inguinal hernia.

The animal having been cast and suitably secured was anæsthetised with ether, the scrotum was disinfected, and operation performed. On enucleating the cord, the deep tissues (cremasteric fascia and tunica vaginalis) were found torn through externally for a distance of three to three and a half inches. Having incised the vaginal sheath along the lower margin of the testicle, strangulation was seen to have taken place at the hernial ring, which was situated opposite the external inguinal ring at a much lower point than usual. The hernial swelling was composed of two parts. The first, above the hernial ring, was rather larger than a man's fist, formed by a portion of intestine which had thrust aside the vaginal tunic and drawn the peritoneum through the internal inguinal ring, the anterior margin of which was torn. In the other part, situated below the hernial ring, the intestine had already undergone grave change, was blackish in colour, and in imminent danger of becoming gangrenous. It was rinsed with boiled salt solution. After enlarging the hernial ring by incision in an outward direction reduction was easy. A little hesitation was felt as to the best method of fixing the clamps, but it was finally decided, after torsion of the vaginal sheath, to apply them to the cord and skin. This method was preferred, firstly, as insuring against further protrusion of intestine, rendered possible by tearing of the vaginal sheath, and favoured by patency of the inguinal ring; and secondly, as favouring adhesion of the skin to the cord below the ring, and thus ensuring formation of a solid fibrous cicatrix.

The operative wound progressed favourably, but the herniated portion of the intestine became gangrenous, and death occurred on the sixth day.

It is easy to explain the symptoms shown by this case. The hernia presented two conditions of different age and character. The internal inguinal ring had been abnormally large before strangulation; the peritoneum surrounding it had yielded under the continual tension, and a loop of intestine had become extruded, forming a hernial swelling in the depth of the groin. This swelling afterwards became complicated with acute inguinal hernia. Tearing of the vaginal sheath probably resulted from the repeated manipulation to which the scrotum had been subjected before operation.

80. A five-year-old setter bitch, left in hospital 15th March, 1893.

This animal had long suffered from inguinal hernia, which, however, had gradually increased in size during the preceding months. On entry it was incommoded by the swelling, and sometimes appeared in pain.

The swelling occupied the left inguinal region, and was the size of a man's fist. Though tense when the animal was standing, it immediately diminished and became flaccid when the animal was placed in the dorsal position and taxis performed. It was perfectly reducible.

For three days the patient was placed on milk diet and received one third grain of calomel daily.

Operation.—On the 9th March the bitch was secured in the dorsal position. Anæsthetics were not given.

The skin covering the swelling and surrounding parts was washed with soap, shaved, and rinsed with alcohol and sublimate solution. The flanks and abdomen were covered with aseptic compresses. An incision about three and a half inches in length was then made through the skin in the long axis of the swelling, running in a slightly oblique direction backwards and inwards. The sac was enucleated with the fingers, care being taken not to tear it. By methodical compression over the exposed part of the sac the contained organs were gradually returned to the abdomen. The hernial opening, formed by the enlarged inguinal ring, was oval in form; it measured about three quarters of an inch in its longer diameter and three eighths of an inch across. The sac was twisted under slight tension, ligatured with silk as close as possible to the inguinal ring, and the free part removed about one sixth of an inch below the ligature. After slightly curetting the margins of the inguinal opening the lips were touched with strong carbolic solution and brought together with two silk ligatures. The wound was cleansed with tampons of cotton wool, powdered with iodoform, and the skin brought together with interrupted sutures. When dried the sutures were covered with a layer of iodoform collodion. The inguinal region was surrounded with a gauze compress and enveloped in a thick layer of cotton wool put in place by a bandage.

No bad results followed. During the succeeding night and next two days the animal was fed on milk and meat. The temperature never exceeded 39·4° C.

On the 11th March the dressing was removed. The margins of the wound were slightly swollen; there was no suppuration.

On the 16th the wound had healed to a very large extent; its centre, and about one and a quarter inches of its lips, discharged a little sero-sanguinolent fluid. It was cleansed with carbolic solution and the cutaneous sutures removed. The parts were swabbed with a cotton-wool tampon saturated in alcohol, a new dressing of cotton wool was applied and left in position until the 20th. At that date the centre portion of the wound had healed. The animal left on the 25th.

Remarks.—Operation for acute inguinal hernia in the bitch is sometimes difficult owing either to adhesion between the herniated organs and the sac, or to the presence of a fœtus in one of the (herniated) uterine horns. When one of the herniated organs is adherent to the sac the latter is incised, the adhesion broken down, the hernia reduced, and operation concluded as usual. When, however, epiploon alone is contained in the sac the latter is either ligatured with catgut and excised, or traction is exercised on the sac, which is ligatured as high as possible and resected, together with its contents.

At the present moment we have in hospital a St. Germain setter bitch operated on for left inguinal hernia, in which the sac contained both uterine horns and a large mass of epiploon. The removal of these parts necessitated triple ligation; nevertheless, recovery was uncomplicated.

When the sac contains a horn of the gravid uterus it is freely opened and ligatures applied to the pedicle of the ovary, the base of the horn, and the corresponding half of the broad ligament, and drawn thoroughly tight, the parts being excised four inches below the ligatures. Before returning the stump of the horn the mucous membrane is scraped and disinfected with strong carbolic solution.

Wherever asepsis appears doubtful, a drainage-tube or strip of gauze should be inserted and sutured to the skin to allow of discharges escaping.

81. A two-year-old Danish dog, left in hospital 14th October, 1894.

Three months before a hot, œdematous, painful swelling was noted on the lower surface of the abdomen, immediately in front of the right stifle, accompanied by lameness in the right hind leg. Swelling and pain disappeared in the course of a week. The dog was suffering from ventral hernia.

Condition on Entry.—In the lower portion of the right flank, slightly in front of the stifle, was an ovoid swelling, the size of an egg, painless, uniformly fluctuating, and readily reducible.

The animal having been placed on its back one could, after reduction, pass the end of the index finger into the hernial opening, which was of considerable size and elliptical in form. The animal was prepared as in the preceding cases, and operation was performed on the 18th October under chloroform.

The skin having been disinfected, an incision about three to three and a half inches in length was made over the long axis of the tumour, in a slightly oblique direction, downwards and inwards, and the sac enucleated. Whilst an assistant exercised slight traction on the sac, a double catgut ligature was passed around it, level with the opening, drawn tight, the two ligatures separately tied, and the sac resected. The margins of the abdominal opening were curetted and united by three silk sutures. The cutaneous lips of the wound were brought into intimate contact by interrupted sutures. The wound was covered with collodion, over which was applied a cotton-wool dressing and bandage.

The patient was fed on milk and a little meat. In the evening the temperature was 38·8° C.

The sequelæ were very trifling, the temperature never exceeding 39·2° C.

On the 22nd October the dressing was removed. The upper two thirds of the wound had healed throughout; in the lower third the lips were swollen, retracted, and discharging. They were cleansed with carbolic solution and a new cotton-wool dressing applied.

On the 26th the cutaneous sutures were cut and removed. On the 30th dressing was discontinued. The wound had healed, and the hernia was cured.

82. A five-year-old setter bitch, left in hospital 8th February, 1895.

Had been ill for five days, showing symptoms of intestinal obstruction, loss of appetite, dulness, groaning, vomiting, constipation, and

sensitiveness over the abdomen; but none of these symptoms in a very severe form. Examination of the abdomen and rectum gave no information.

Treatment.—Administration of castor oil, hypodermic injection of two milligrammes of eserine, and warm water enemata. Dead next day.

Autopsy.—A little reddish serosity in the peritoneum; intense congestion of a portion of the intestines. On isolating the convolutions it was seen that a part of the intestine had passed into the thorax. The upper margin of the diaphragm opposite the right pillar showed a narrow tear, through which the hernia had occurred. On opening the chest about fourteen inches of the last portion of the jejunum were found. The gut was blackish in colour, its coats greatly thickened and œdematous. The opening through which the intestine had passed was oval in form, its greatest length being vertical. The fibrous condition of the margins showed it to be of old standing.

On auscultating the chest we might undoubtedly have noted borborygmus, but the diagnosis would, nevertheless, have remained doubtful, in view of the rarity of diaphragmatic hernia in the dog.

83. Six-year-old bay mare, seen at midnight on the 2nd March, 1894.

History.—Shortly before the first symptoms appeared the animal had had "a severe twist round with the van." The attack commenced at 3.30 p.m., and the mare reached home at 6 p.m.

State on Examination.—Acute persistent pain, great excitement, free perspiration. Pulse hard, small and frequent. Temperature 105° F. Chloral and enemas were given freely. The animal continued violent, rapidly became weaker, and died at 2.15 p.m. on March 3rd.

Autopsy revealed a rupture one and a half inches long on the inner border of the muscular portion of the right side of diaphragm, through which several loops of the small intestine (ten or twelve feet from the ileo-cæcal valve) had passed. The pleura covering the anterior surface of the diaphragm was separated, thickened, and enclosed the intestine like a bag. The intestine could not be pulled back into the abdomen, for it was strangulated. The loop was very full of dark-coloured blood. The bag-like swelling in the chest was as large as two cocoa-nuts, was tense, and attached by exudate to the right side of the chest. The whole of the small intestine from the hernia to the stomach was greatly dilated, and filled with sanious watery fluid.

Mr. G. C. Lowe's case, *Journ. Comp. Path. and Therap.*, 1894, p. 75.

84. A ten-year-old mare showed on *post-mortem* examination a rent one inch in diameter about the middle of the muscular portion of the diaphragm, through which a considerable portion of the gastro-colic omentum had passed and become attached to the fifth rib of the right side. The accident was of considerable standing, as the displaced fragments were firmly ossified. During the four years previous to death the animal had never shown a day's illness. The case proves that rupture of the diaphragm is by no means necessarily fatal.

Mr. H. D. Young's case, *Veterinarian*, 1894, p. 259.

85. In the *Veterinarian* for 1845 is described a case of strangulated phrenic hernia in a mare, whose history for eighteen months prior to death did not disclose any accident, and yet autopsy revealed a fractured rib, to which the displaced intestine was firmly attached. The opening in the diaphragm was only "large enough to admit the thumb."

Mr. Gabriel's case.

CANCER OF THE STOMACH.

86. An eleven-year-old mare, brought for examination on the 5th June, 1894.

The only information tendered was as follows: Had been in the owner's possession for several years, and always worked satisfactorily until the 3rd June. No digestive trouble, nor sign of any disease whatever had been noted previous to that date. Suddenly the animal appeared depressed, uneasy, and without appetite. It had coughed a little.

State on Examination.—The patient was prostrate; the mucous membrane injected; the respiration rapid (18 to 20 per minute), the pulse small (70), the rectal temperature 39·6° C.

Percussion of the chest was painful, and revealed slight dulness of the lower half of either side. On auscultation of this region the vesicular murmur was diminished. The heart-sounds were feeble and irregular. The abdomen was slightly painful on palpation. The mare was regarded as suffering from pneumo-enteritis.

Treatment.—Bleeding, mustard plasters, alcohol, digitalis.

During the night the symptoms became aggravated. The pulse rose to 75° C., the respirations to 40. The patient refused all food.

On the morning of the 6th June the condition was still graver. The mare was extremely depressed, and occasionally scraped the ground with her foot. The conjunctiva was deep red; the respiration short, tumultuous, and discordant. Nothing fresh could be discovered on auscultation or percussion of the chest; the walls of the chest were still very sensitive; the heart-sounds feeble; the pulse was scarcely perceptible. There was slight muscular trembling, especially opposite the point of the elbow. Temperature 39·2° C. Half an hour later the condition suddenly became alarming. The patient looked extremely anxious, lay down and rose again several times with great care, then suddenly groaned, leaned against the wall, rolled from side to side, and fell heavily. The necks and limbs became stiff, the face drawn, the respirations more and more rapid, and death occurred after a short struggle.

Autopsy.—Several quarts of reddish liquid in the abdominal cavity. Lesions of peritonitis; different portions of the serous membrane, and especially of the epiploon, were congested and hæmorrhagic. The pleural cavity contained a certain quantity of liquid resembling that in the peritoneal, and showed similar changes to the latter. The viscera were congested and dotted over with ecchymoses. These changes were secondary, and had been produced by a septic process originating in the stomach.

The stomach itself, which was large and very heavy, was adherent to the diaphragm over an area of 9 inches by 7 inches. The adhesions were particularly marked near the small curvature, towards the termination of the œsophagus, where the serous coverings of the stomach and diaphragm become continuous. These adhesions were supplemented by an enormous number of short, fibrous bands, some old, others of recent formation. While the posterior portions of the wall of the stomach were normal, or nearly so, the anterior were thickened, hard, and bosselated around the adherent area. On being removed and incised along its greater curvature, the stomach showed an enormous ulcerated swelling developed on the anterior wall of the left *cul-de-sac*.

This new growth was of irregular, triangular shape, the base being upwards; it measured 10½ inches in length by 9½ inches in width. Limited above by a horizontal line which followed the small curvature, and of which the cardia occupied the central part, it extended along the mucous membrane of the œsophagus, forming a small reddish patch, clearly visible against the whitish ground of the adjacent normal mucous membrane. This patch was but slightly elevated above the surrounding parts, and did not sensibly diminish the lumen of the canal.

The lesion stopped exactly at the line of separation between the cuticular and villous portions of the gastric mucous membrane, leaving the latter intact. On the left side the principal ulcer was very irregular in shape; its margins were indurated and excavated; at points the mucous membrane was thickened, loosened, scalloped, or exhibited apertures due to circular losses of substance—some of which were as large as a sixpence; all produced by extension of the process under the mucous membrane, and by ulceration of the latter.

Around the margins of the injury the walls of the stomach were everywhere thickened and indurated for a width of 2½ inches to 4 inches. At several points the submucous connective tissue was also œdematous.

The tumour was not of the same appearance and character throughout. A portion of the upper part—about six by four inches immediately below the cardia—was very prominent, soft in consistence, and reddish or violet in colour, according to the point examined. This first part was limited below by a deep semicircular groove. Over the rest of its surface the ulcer was covered with reddish, rounded, irregular vegetations, varying in size between a pea and a hazel nut, separated by sinuous depressions filled with an ichorous stinking material.

On cutting through the walls of the stomach from the cardia to the lower portion of the ulcer, *i.e.* through the entire thickness of the tumour, the serous and muscular layers were seen to be greatly thickened and indurated by infiltration with the new growth; the muscular tissue, however, was only ulcerated opposite a few of the above-mentioned grooves. The projecting mass formed by the upper part of the tumour contained irregular communicating spaces with friable walls—spaces filled with sloughing débris and ichorous liquid.

This tumour had certainly existed for several months, but its insidious development (it had produced no apparent disturbance until

two days before death), and especially the absence of digestive disturbance, were explained by the seat of the lesion: the cardia remained patent, and the left portion of the stomach sufficiently wide to permit food to pass, while the mucous membrane of the right *cul-de-sac* was normal.

The clitoris showed a reddish, mammilated tumour, the size of a nut, of the same nature as that in the stomach.

The growth was a pavement epithelioma. Microscopically examined it appeared formed of a fibrous stroma and masses of epithelial cells arranged in anastomosing bands and large lobules, the centres of which were occupied by spherical groups of cells undergoing cornification (epidermal nests).

ABSCESS OF THE LIVER IN THE HORSE.

87. An eleven-year-old grey Persian mare, first admitted to hospital 15th May, 1898. The animal was very dull, but showed no other symptoms; was treated for simple fever, and discharged to duty 21st May.

Readmitted 7th September. Since the previous treatment had been dull and disinclined for food.

State on Examination.—Appetite entirely in abeyance; signs of liver disorder, membranes yellow, fever, intense dulness; pulse 50, respirations 20.

Treatment.—Tonics and nourishing food.

By the 31st May the animal had improved, but the membranes were paler and more anæmic. Considerable bodily wasting had occurred, the urine was brownish and very offensive, but free from bile or albumen; fæces normal. The most careful examination of all accessible organs revealed nothing.

On the 3rd October the fæces were dark in colour, very offensive, and contained much mucus. Urine free of albumen or bile.

On the 9th the animal fell and remained down in its box for two hours, rising again of its own accord; this was the only occasion on which it ventured to lie down.

On the 15th muscular wasting was intense, the pulse quicker, respirations increased; the case was evidently sinking.

On the 17th and 18th the animal walked aimlessly round its box; pulse imperceptible; early on the morning of the 19th it died.

Autopsy.—On opening the abdomen about two quarts of inspissated pus mixed with serum escaped; peritoneum inflamed and covered with lymph; the transverse colon and extremity of cæcum were highly inflamed, preparatory to adhesion, for the right portion of the double colon was already firmly attached to the abdominal wall. The liver was mottled, and its entire anterior surface adherent to the diaphragm; it weighed 20 lbs. The hepatic lobules were swollen and engorged with blood. On section the organ appeared gritty; the right lobe contained a large abscess, the contents of which had burst into the peritoneal cavity; the walls of this abscess varied in thickness, measuring at places three or four inches, and at others being as thin as paper;

rupture had occurred at the thin part; the right lobe alone contained seven abscesses in various stages, and the whole liver at least twenty yellow cheesy deposits—the nuclei of future abscesses (?). The walls of the stomach were two to three inches thick; the cuticular portion was thickened, of a dirty yellow colour, and resembled a honeycomb: these changes were the result of inflammatory action, and due to an attempt to glue the main abscess to the stomach, so as to afford an outlet for it. (This case occurred in India.)

Prof. F. Smith, *Journ. Comp. Path. and Therap.*, 1891, p. 355.

INTESTINAL OBSTRUCTION.

88. A fifteen-month-old spaniel, left in hospital 5th February, 1895.

This animal rarely left the shop where it lived. On the 2nd February it refused food. Meat and other food, of which it was generally fond, were offered, but in vain. It would only take cold water. These symptoms continued on the 3rd and 4th of February. The animal was brought to the school next day.

State on Examination.—The animal was feverish and appeared in great pain; it lay down on its chest with the head extended on the fore paws, and paid no attention to what passed around it. The mouth was hot, the eye retracted into the orbit, the conjunctiva injected. Respiration and circulation were very rapid, the heart beat tumultuously, and at times expiration was accompanied by groaning. The animal would not touch food, but greedily drank cold water. Urine normal.

The abdomen was not painful. Nevertheless, as fæces had not been passed for thirty-six hours, intestinal obstruction was suspected.

Treatment.—Administration of $1\frac{1}{4}$ ounces of oil and warm water enemata.

The animal's strength was supported by spoon feeding with milk containing $1\frac{1}{4}$ drachms of bicarbonate of soda.

On the morning of the 6th February the general condition appeared better than on the previous evening. The dog seemed to have recovered its appetite, and took a few mouthfuls of solid food. Liquid excrement was found in the kennel. Manipulation of the abdomen produced slight pain, but no foreign body was discovered. The same treatment was continued.

On the 5th February depression and feebleness were more marked than on the previous evening. The animal could scarcely stand. Died during the night.

Autopsy.—The anterior portion of the intestine was dilated, very greatly congested, and about twelve inches from the stomach contained a large rounded object. On incision an india-rubber ball was found obstructing the lumen of the tube.

Remark.—A number of cases of intestinal obstruction in the dog accompanied by symptoms resembling rabies have been described. In that just mentioned, and in a number of others, nothing suggestive of rabies was noted. In reality these rabidiform symptoms are seldom seen except in dogs of naturally bad temper, or in cases where the foreign body has torn the intestinal mucous membrane.

PERFORATION OF THE INTESTINE.

89. An eighteen-month-old sheep-dog, left in hospital 10th May, 1898.

Though usually very bright and playful, this dog had two days before suddenly become dull and refused food. It moved unwillingly, and only when forced. There were no symptoms resembling rabies. The condition was referred to the animal having swallowed some fish-bones (pike).

On entering its kennel the animal lay down on the right side and moaned. As it refused all food, milk was given by a spoon. Died next day.

Autopsy.—Lesions of diffuse acute peritonitis. The entire intestinal mass was greatly congested.

Towards the centre of the small intestine was a perforation due to a fragment of bone (from the upper half of a sheep's tibia). In front of this bone the intestine was distended by grass, which the animal had doubtless swallowed when it felt the first pains due to obstruction.

90. A three-year-old setter dog, left in hospital 5th June, 1898.

The animal had appeared unwell three days before, and remained continually recumbent. If forced to move it walked slowly, showed pain, and howled. Appetite was entirely lost. At times there was nausea and vomiting of yellowish bilious material.

When brought here the animal was in a grave state; it no longer recognised its master, and took no notice when called. It walked with short steps, the back bowed, and the limbs thrust apart. The abdomen was tense and painful on pressure; the pulse rapid and feeble; the respiration frequent, expiration being at times moaning; temperature 40° C.

Placed in a kennel the animal lay on its side with the head and legs extended. It refused to drink milk, and was therefore fed by hand. The condition rapidly became aggravated, and death occurred during the night.

Autopsy.—Lesions of purulent peritonitis.

Towards its centre the duodenum was greatly swollen; the surface of the right half was inflamed and granulating. In the thickened wall of this portion, lying almost parallel to the general direction of the intestine, was a needle two and a half inches in length, the eye of which contained a worsted thread, twenty inches long, enveloped in the thickness of the intestinal tunics.

In front of the point where the needle had become inserted the duodenum was dilated; behind it was contracted and empty.

Remark.—The symptoms which follow small perforations of the wall of the stomach or intestine by needles differ widely, according to whether the needle does, or does not, carry a thread. The thread when present becomes the carrier of septic materials, which almost always produce fatal peritonitis. On the other hand, needles alone often pass through the intestine without causing any appreciable symptoms. When they become implanted in the liver they are usually

encysted, and may remain permanently in position without producing any notable effect.

SUBCAPSULAR HÆMORRHAGE IN THE LIVER OF THE HORSE; PARTIAL RECOVERY; RELAPSE AND DEATH.

91. A fifteen-year-old dun gelding, seen about 8 p.m., 18th June, 1896.

History.—Said to have been suffering from colic. At 5 p.m. a small quantity of fæces had been passed, and the animal had afterwards staled.

State on Examination.—The animal was standing quietly, its head thrust a little forward, its face drawn, pupils dilated, legs straddled apart, muscles quivering, and its whole body bathed in cold perspiration. The mouth was cold, the conjunctiva pale, the tongue and lips were blanched and flaccid. The pulse was 94, very small and weak; temperature $100\frac{2}{5}°$; the respirations were about 31, shallow but not noisy, and the nostrils were dilated. Within a few minutes the animal began to walk round its box, cringing from time to time towards the right side, turning its head in the direction of the right flank, but seldom lying down. This wandering round was occasionally interrupted, the animal standing in one place, pawing violently, stretching out its head, and curling its upper lip. Vision appeared defective, for the head was several times struck against the side of the box, while the pupil scarcely reacted on the approach of a light. Raising the head caused staggering.

As the animal had been resting for ten days and had not been out of its box, and as the attack was of sudden onset, the history threw little light on it. The suddenness of the attack, the extreme depression, dilatation of the pupil, paleness of the membranes, and general bloodlessness seemed to point to internal hæmorrhage, while the animal's age, considered in conjunction with the known frequency of rupture of the liver in the horse, seemed to warrant the diagnosis of ruptured liver. As very little more could be done than relieve pain, a hypodermic injection of seven grains hydrochlorate of morphine was given, it being considered too dangerous to attempt giving a draught.

This afforded some relief, and for about forty minutes the animal kept wandering round its box or occasionally standing still and pawing. Just as death seemed imminent, it went down rather heavily, struggled a good deal, stretched out its legs stiffly, groaned deeply several times, and apparently died. In about a minute, however, it gathered itself together, rose and stood swaying about stupidly, but apparently in less pain than before. At this time the pulse was about 130 to 140, small and thready; the respirations about 30, but shallow and quiet. The temperature was not taken.

Directions were given that the animal should be kept perfectly quiet, placed on low diet, and general precautions be adopted against its catching cold or injuring itself. In point of fact death was expected to occur within a few hours.

Next day, however, the patient was still alive and distinctly better.

Pulse 82, respirations 75, temperature 100°, pupil still rather dilated, surface temperature better distributed; the bowels and kidneys had acted, the former slightly, and the animal had eaten a little mash. Trifling jaundice, which had been overlooked the evening before, was noted.

Slow but steady progress was maintained until 11.30 a.m. on June 29th (*i. e.* eleven days), on which date the pulse, temperature, and respirations were nearly normal. At 3 p.m. the horse died.

Post-mortem examination revealed profuse intra-abdominal hæmorrhage, and pronounced yellow staining of all the internal organs. The foam in the bronchi was tinged yellow, the bowels were similarly tinted; the kidneys, though otherwise normal, were of a like shade, and everywhere the abdominal fat was deeply coloured. The principal interest of the case centred in the liver, which was of enormous size, weighing over 58 lbs. Owing to the large subcapsular clots being in great part lost during removal of the liver from the abdominal cavity, this is probably a low estimate. One of these clots removed from the left lobe weighed 13 lbs. of itself, and several others existed. The liver showed excessive fatty degeneration, was yellowish to dull brown in colour, pultaceous, broke down under the slightest pressure, and permitted of the capsule being readily stripped at all points. Normal liver tissue seemed absolutely wanting. The capsule of the left lobe was separated (by hæmorrhage) over an area about nine inches square. The contained clot was firmer than the others, and appeared to be undergoing absorption. The right lobe showed somewhat less extensive change than the left, but subcapsular breathing had occurred and the capsule had ruptured, allowing of free hæmorrhage into the abdominal cavity. The space between capsule and liver substance contained a clot weighing about 6½ lbs. Sections through the liver showed internal hæmorrhages of all ages throughout the organ; at some spots a few dark brown patches were all that remained, at others the blood was still nearly fluid. It was scarcely possible to find a cubic inch without a hæmorrhage.

Viewed in light of the facts shown by *post-mortem* examination, it seems probable that the first attack, on the 18th June, was due to subcapsular hæmorrhage in the left lobe, where the clot seemed to be oldest; that under the combined influences of lowered blood-pressure in the arteries, and increased local pressure at the seat of bleeding, the loss gradually ceased with the effects noted, but that on the second occasion hæmorrhage was followed by rupture of the capsule, free bleeding into the abdominal cavity, and rapid death from syncope.

Mr. Jno. A. W. Dollar's case, *Veterinarian*, 1896, p. 668.

CHYLOUS ASCITES IN THE CAT—MENINGITIS AS AN ACCOMPANIMENT.

92. A large black male cat about eight years old, first seen on the 12th April, 1895.

History.—Five weeks previously the animal had been caught in a shower of rain, and a week later its abdomen appeared swollen; it was

rather dull, and lay curled up in its basket, but took food fairly well. Swelling continued to increase, but the abdomen was not tender or painful on palpation. About the end of March swelling had become considerable, and in descending a long flight of stone steps the animal overbalanced, and rolled from top to bottom. To the previous difficulty in movement (probably due to enlarged abdomen) a new symptom was now added: the animal seemed "weak in its hind quarters," and when turning staggered considerably, but soon recovered itself; it could walk quite steadily so long as it continued in a straight direction.

State on Examination.—Pulse about 200, small, rather wiry and difficult to detect. Respirations 26. Temperature $103\frac{2}{5}^{\circ}$ F. Nose and mouth hot, dry, and offensive, tongue coated and whitish brown in colour. Appetite bad, no great desire for either food or milk. General condition poor, abdomen enormously distended and pendulous; the animal was "pot-bellied," and walked with the hind legs semi-flexed, the abdomen almost in contact with the ground (apparently in conse-



FIG. 37.—Chylous ascites. Showing the enormous distension of the abdomen, and the falling away about the hind limbs, spinal column, and neck.

quence of the feeling of insecurity due to inability to control movements of the hind limbs). Supporting the abdomen seemed grateful to the animal. The coat was dull and in process of shedding, leaving bare patches, though the skin seemed normal. The vertebræ were unusually prominent, the flank fallen in, the hind quarters and thighs wasted. The animal weighed $10\frac{1}{4}$ lbs.

The posterior portion of the neck, the back from the dorsal to the lumbar region, and the tail seemed insensitive. When pricked the animal failed to respond except locally—there was slight local twitching, —but if the needle were more vigorously employed it half turned its head, and seemed for a moment to reflect. A second or third stimulus might cause it to turn the head completely round, but it never seemed sensible of the exact site of injury, or of any real pain. Sometimes it licked a point adjoining that touched, sometimes one three or four inches away.

There was incomplete paraplegia of both hind limbs, difficult to exactly marginate. The gait was very unsteady, the animal, especially

when turning a corner, suddenly swerving to the right or left, and nearly or completely falling over. There was marked disinclination to remain on any elevated spot. If placed on a table the animal approached the edge, and after deliberating for a moment (all its movements were very deliberate) slowly glided off towards the ground. It was, however, unable to resist the shock, and fell over almost helpless. When placed in a basket it appeared comfortable, seldom changing its position, and did not move even when the basket was slowly inclined until it lay with the head undermost. It could, however, still walk fairly well in a straight line, could ascend and descend stairs without falling, and could spring over low obstacles. The bowels and kidneys acted regularly, the bladder was under control, though the innervation of the rectum seemed somewhat defective, causing defecation to be difficult.

The pupils responded readily to light, and vision seemed perfect,

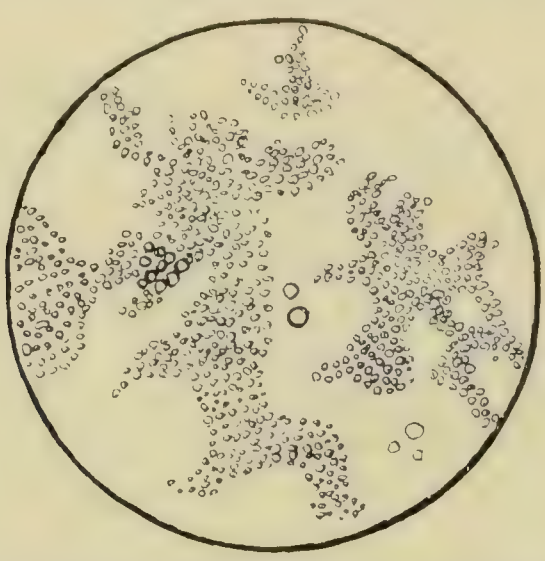

Fig. 38.—Chylous fluid, freshly withdrawn.

though the animal only winked languidly when threatened. There was no change in the cornea.

The knee-jerks, as tested by Professor Victor Horsley, were not exaggerated.

Diagnosis.—Ascites, consequent on chronic peritonitis, probably complicated with cerebellar tumour. The cat was killed with chloroform.

Post-mortem Examination.—The skull was exceptionally well developed, the occipital and parietal crests being especially prominent and the diploë dense.

On opening the cranial cavity about half to three quarters of an ounce of a glairy reddish serous liquid escaped. It was accumulated in greatest amount about the falx cerebri, the posterior aspect and base of the brain.

The meninges were infiltrated with it, and the liquid continued to ooze away for some minutes. The meningeal vessels were congested, and there was well-marked meningitis. The brain seemed to have suffered little change.

The abdomen contained about 30 ounces of a thin white fluid exactly resembling milk, and the internal organs showed the following appearances.

The serous coat of the bowel was covered with small elongated whitish spots resembling minute worms, many of which were not larger than grains of sand. On being pricked, the larger exuded a minute drop of the same milky fluid as was found in the abdomen. Along the free border of the bowel, furthest from the mesentery, and most marked in the duodenum and jejunum, were minute red commencing granulations. The gastro-splenic omentum was bright pink in colour, and showed numerous areas of what appeared like chyle extravasation—whitish spots the size of a threepenny piece, from which fluid escaped on pricking. In and on the serous membrane, and especially around the mesenteric vessels, were deposits of lymph.

The liver showed subperitoneal lymph effusion, and on incision the lobules were marginated by a pearly-grey infiltration.

The spleen was covered with greyish points of lymph effusion. The

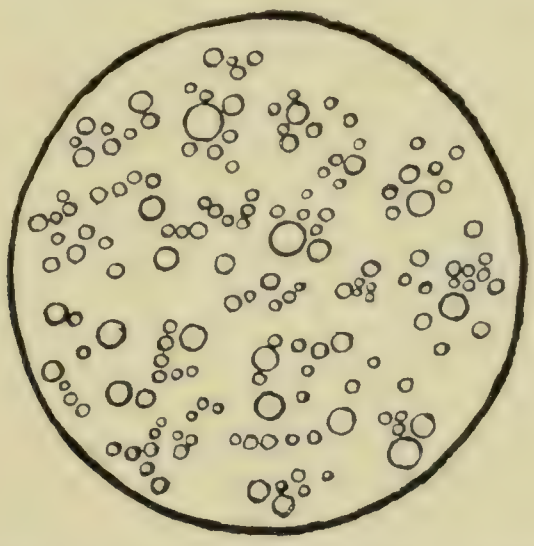

FIG. 39.—Microscopic appearance of fresh milk. All these figures are drawn to the same scale.

kidneys showed well-marked fatty change, which on microscopic examination seemed to be fatty degeneration. The bladder was full of urine.

The peritoneum had everywhere undergone extensive change. Its shining appearance was lost, lymph deposits had occurred over it, though without glueing together the intestines, and in some places, as shown by microscopic examination, the lymph was undergoing organisation.

The thoracic duct could not be isolated.

The heart appeared enlarged, and had suffered fatty change. The muscular tissue was lax and friable, and instead of a deep maroon was brownish in tint. It left a greasy stain on the knife after cutting.

The lungs were dark in colour and congested. The inferior border and base of the lungs were collapsed, probably in consequence of the continued pressure of the abdominal contents.

The ascitic fluid, when freshly withdrawn, showed the appearances denoted by the figure. The minute granules were of a fatty character; they dissolved in ether, which afterwards left a greasy stain if poured over paper and allowed to evaporate. A few leucocytes were also present. Within half an hour of withdrawal this milky fluid coagulated spontaneously, forming a kind of soft curd, though if a few drops of chloroform were previously added it remained fluid and without perceptible smell for fourteen days. During that time it separated into two distinct layers, an upper thick creamy, and an under serous and clearer layer. For the purpose of comparison a drawing of a specimen of milk is appended.

Mr. Jno. A. W. Dollar's case, *Veterinarian*, 1895, p. 403.

CHYLOUS ASCITES IN THE CAT.

93. A male cat first seen on the 28th September, 1893.

In June its abdomen was abnormally large, and afterwards increased in size. The animal showed occasional dulness, lay down on its side and groaned; at other times it seemed quite well. Before enlargement appeared the cat used sometimes to vomit after a meal, but this symptom afterwards disappeared and the appetite became ravenous. As the owner refused to have it killed, five grains of potassium iodide were given night and morning, and in a fortnight the abdomen almost regained its former dimensions, but began to refill again immediately treatment was stopped. Killed on 6th November.

Autopsy.—The abdomen contained three pints three ounces of fluid indistinguishable from cow's milk. The lacteals in the lower part of the mesentery were distended with chyle, but no rupture or abnormality could be detected in them. The thoracic duct between the heart and receptaculum chyli contained a little pale-pink lymph; both it and the receptaculum chyli appeared intact. The blood-vessels of the omentum and mesentery were much congested, those of the peritoneum less so. The liver was fatty; the other organs were normal.

Microscopically the fluid resembled ordinary chyle. It contained no epithelium and yielded neither sediment nor cream when passed through the centrifugal machine.

Mr. H. Gray's case, *Journ. Comp. Path. and Therap.*, 1893, p. 375.

CONSTIPATION.

94. A four-year-old setter, suffering from constipation, which had resisted purgatives.

According to the statement of the person in charge of the dog the condition had existed for nearly three weeks. The animal was left in the School for treatment on the 21st January, 1898.

It appeared to be suffering from severe abdominal pain, and from time to time made expulsive efforts. On manipulating the abdomen an enormous, very hard mass was felt, formed by the rectum distended with fæces.

Attempts were made to evacuate the rectum by curettage, but the

amount and consistence of the fæces rendered this useless. The animal was placed on milk diet, enemata of hot water were slowly injected, and repeated six times daily; 1 centigramme (·15 grain) of pilocarpine was subcutaneously injected, and the abdomen was massaged.

This treatment was continued during the succeeding four days. Every other day 5 centigrammes of calomel ($\frac{3}{4}$ grain) were given. The animal only passed very small quantities of fæces, which had been softened by the enemas.

On the 27th each enema was followed by the passage of softened excrement. The calomel was stopped.

On the following day the animal passed a large quantity of semi-liquid material and fragments of bone. On manipulation of the abdomen the hard mass formed by the distended rectum could no longer be detected.

On the 28th several evacuations.

On the 29th passage of almost liquid and slightly blood-stained fæces. Every minute the animal made expulsive efforts. It was fed on milk, containing a feeble proportion of laudanum, and with rice and milk.

On the 30th similar treatment. The excrement no longer contained blood, and the diarrhœa had diminished.

On the following days the stools resumed their normal appearance.

95. Six-year-old water spaniel, left in hospital 14th May, 1898.

Had for some months shown incontinence of urine, and was then suffering from obstinate constipation. The anus was swollen, and formed a projection as large as a man's fist. The dog continually made efforts to defæcate. The rectum was obstructed by hardened excrement.

Treatment.—Milk diet; warm water enemas every two hours.

On the 15th, after administration of several enemas, a portion of the fæcal mass could be broken down and removed. Two centigrammes ($\frac{1}{3}$ grain) of calomel were administered as an intestinal antiseptic.

During the three following days the enemas and calomel were continued. The material was still hard, and only passed in small quantity. Straining was still frequent.

On the 20th a large quantity of softened excrement was passed.

From the 21st to 25th the previous symptoms gradually diminished. The animal was placed on ordinary diet, which it consumed.

On the 27th the stools were normal.

Remark.—Among methods of treating constipation in the dog, that usually recommended comprises administration of purgatives, and mechanical removal of fæces. I prefer frequently repeated warm enemata, milk diet, and small doses of calomel.

FOREIGN BODY IN THE RECTUM.

96. A one-year-old King Charles' spaniel, left in hospital 15th April, 1898.

Though usually very affectionate this dog had, during the preceding five or six days, become bad tempered and snappish. It even attempted

to bite its master when touched. Appetite was lost, and delicacies of which it was usually very fond were refused. The fæces were hard, streaked with blood, and only passed after prolonged, very painful efforts; the peritoneum was œdematous; from the anus escaped a fœtid muco-purulent liquid; the anal mucous membrane was swollen. The introduction of the index finger into the rectum caused intense pain. Three fourths of an inch in front of the sphincter, in the upper wall of the rectum, a hard, extremely sensitive swelling could be detected, towards the centre of which was implanted a sharp object—a needle or pin—projecting an eighth of an inch beyond the mucous membrane and pointing obliquely downwards and forwards.

The foreign body was seized and removed by introducing the right index finger and thumb into the rectum. It proved to be a sharp needle two inches in length, the eye of which contained a fragment of thread.

Subsequent treatment consisted in washing out the rectum with a 5 per cent. solution of creolin. Recovery was complete at the end of a few days.

RUPTURE OF THE POSTERIOR AORTA.

97. A twelve-year-old bay mare, brought to the College on the afternoon of the 2nd February, 1894.

The off fore fetlock had just been severely injured by a tramway car. The external surface of the joint showed a contused wound, from which a little bright red blood flowed, owing to injury of the digital artery.

The animal was placed in the trevis. Despite considerable struggling the wound was dressed, the lips brought together, and an antiseptic compress dressing applied. We were just about to liberate the animal when it suddenly collapsed, and showed signs of dying: excessive pallor of the mucous membranes, convulsive movements, and rotation of the eyes. Death occurred in a few moments.

Autopsy.—On opening the peritoneal cavity a stream of blood escaped. A layer of semi-coagulated blood covered the intestinal contents. After removing the viscera we discovered in the sublumbar region an enormous sanguineous swelling formed by a subperitoneal hæmorrhage, which had dissected and thrust back the parietal layer of the peritoneum. This swelling extended from the origin of the cœliac axis as far as the recto-vaginal *cul-de-sac*. Slightly behind its centre, in the median line, we discovered a narrow perforation in the peritoneum, through which the blood, which had first accumulated beneath the serous membrane, had passed into the abdominal cavity.

Examination of the tissues in the lumbar region revealed the lesion responsible for the hæmorrhage. Though examined throughout its entire length the vena cava showed no solution of continuity. The walls of the posterior aorta were abnormally thin, but the perforation was not at first seen. After carefully removing the vessel, we at length discovered a narrow tear situated on the superior surface opposite an exostosis on the third lumbar vertebra. Opened along its lower sur-

face the vessel showed two ulcerations, the smaller about one sixth of an inch in length, resembling a scratch with the finger-nail. Its margins were sinuous and of irregular outline; this injury extended almost through the entire thickness of the arterial wall. The other ulceration, which, like the preceding, occupied the dorsal surface of the vessel, offered the same characters, but was larger (five sixths of an inch in length and one sixth in breadth), and was ruptured through its base. Through this orifice the hæmorrhage had occurred.

No atheromatous change could be detected in the posterior, nor in the common aorta.

THROMBOSIS OF THE ILIAC ARTERIES IN THE HORSE.

98. Six-year-old well-bred saddle and harness horse, first seen on July 24th, 1894.

History.—Had been purchased about two years previously, had always seemed healthy, and had carried a rider through Yeomanry exercises. For three weeks afterwards seemed in good health. Reported as having "something seriously wrong with its back" on July 24th, after being driven in harness. Had then been quickly brought home.

State on Examination.—Was "blowing," sweating profusely over the entire body, and showed a swelling—as if from local cramp—under the saddle; movement stiff; pulse increased, but no fever. The disease —diagnosed as a mild attack of azoturia—was treated by hot fomentations and administration of a purgative.

Complete recovery in a few days. The horse was, however, only exercised, carefully dieted, and for a time kept under observation. A few days after again returning to light work it showed some difficulty in moving the right hind leg, began to blow and go stiff, and was brought home. The above treatment again resulted in recovery. The above circumstances recurred twice, but on the next occasion Mr. Rutherford was called in, and found the animal in precisely the same condition as on July 24th, but with the addition to its symptoms of very marked irregularity of the heart's action, from which he concluded there was obstruction to the aortic circulation. The animal was rested, the cardiac difficulty disappeared, and the horse was sent to a prospective buyer on trial, but was returned, having failed to complete its first journey. The alarming symptoms then developed disappeared in a day, but the horse was noticed to pass very little urine, the cardiac irregularity had returned, and the hind limbs remained cold below the hocks in spite of bandaging. The appearance and appetite were good; temperature normal.

On September 11th Mr. Rutherford had the horse ridden, at first at a walk; it showed no symptoms. When trotted, however, it faltered on the right hind limb, over which it lost control before it had gone 500 yards. The pace was at once slowed to a walk, but after a few yards more the left leg became involved, the animal began to blow and show distress, and had great difficulty in covering the remaining sixty yards to its stable, walking in a crouching manner "as if the fore

and hind feet were all at fault," and was evidently in great pain. Immediately on entering its box it lay down, the back became swollen as before, and the belly tucked up; the animal groaned continuously, and sweated profusely over the body, fore extremities, and neck. For two hours from this time (3 p.m.) the animal remained in terrible and continuous pain, rolling occasionally half over on its back, poking its nose into its flanks, biting at its hind fetlocks, and frequently attempting to rise. At first it succeeded, but could not stand level, and only remained up long enough to turn round, when it again lay down; soon, however, attempting to rise again, and on each occasion having greater difficulty in doing so. Very soon it could only rise high enough to roll over on its bent hind legs. Hot fomentations were applied and morphine given hypodermically, under the influence of which the animal became somewhat quieter, and groaned and sweated less, though quite unable to rise. The fore limbs were thrown about a great deal, but the hind, which were "deathly" cold from the hocks downwards, and cold and insensitive above, could scarcely be moved. Sweating was confined entirely to the body—in front of the croup—behind which the skin was cold and dry, and the muscles showed tremulous movements. Rectal exploration during a quiet period revealed the existence of aortic and iliac thrombi. The vessels were resistent to gentle pressure; the aortic pulse was quick and thumping, and the impulse in the internal iliacs was indistinct, that on the right side being much weaker and more indistinct than that on the left. The horse had always fallen lame on the right leg. As the night advanced the animal became much quieter: pain recurred at long intervals, though it was then severe. The case seemed hopeless, but morphine was again administered, and the patient seemed fairly comfortable. At 3 a.m., after attempting to rise, it again became very violent, lashing about with its fore feet, and raising the fore part of the body, only to fall back again. When seen at 5 a.m. it was dying; hind quarters and legs cold, submaxillary pulse imperceptible. Died at 6 a.m., fifteen hours after attack. The temperature never rose more than 1° F. during the entire time.

Autopsy disclosed thrombosis of the termination of the posterior aorta, of the right external and internal iliacs, and of the left internal iliac; a patch of inflammation of the sublumbar fascia above the aorta, with exudate; and inflammation of the inner coats of the vessels involved. The most interesting point in connection with the thrombi was that they were apparently of different ages, the most recent being that of the external iliac, which from its appearance—a dense, fresh blood-clot mainly—was evidently the product of the last attack.

Mr. R. Rutherford's case, *Veterinarian*, 1895, p. 35.

ACUTE NEPHRITIS.

99. Three-year-old sheep-dog, left in hospital 20th December, 1893.

For some days the animal had been dull, had refused to eat, and at times howled. Walking was difficult, movement of the hind limbs being particularly embarrassed.

Next morning the patient appeared very feeble, and moved with difficulty. The conjunctiva was dull and infiltrated; the pulse 85; the respiration slightly accelerated, short, and sighing. Nothing abnormal was discovered on auscultating the lungs and heart. Manipulation of the abdomen was painful, especially towards the spine. Rectal exploration discovered nothing abnormal in the pelvic organs. Urine passed during the night was slightly reddish, and contained about forty-five grains of albumen per quart. On microscopical examination cylindrical casts, leucocytes, a few red blood-corpuscles, and some epithelial cells were discovered in it.

Diagnosis.—Acute nephritis.

Treatment.—Milk diet and bicarbonate of soda, emollient enemata.

The animal's condition became rapidly aggravated. On the 24th December the patient was seen to be lame on the right hind leg. Nothing could be detected on examining the limb.

On the 27th the scrotum became swollen, hot, and painful. When punctured reddish pus escaped. Pulse 120, respirations 28, temperature 39° C.

On the 29th weakness was extreme. Pulse 130, respirations 28, temperature 40° C. The animal several times took milk, but almost immediately afterwards vomited. The urine was very red in colour. A little discharge escaped from the nostrils. In the evening the pulse was 160, respirations 25, temperature 37° C. Died during the night.

Post-mortem Examination.—The kidneys were large and black in colour. Sections were deep red, marbled with a few whitish points, indicating little abscesses distributed through the cortical and medullary substances. The pelvis of the kidney contained a little purulent urine. The liver, spleen, and lungs were large and congested.

On microscopic examination the tissue of the kidneys appeared greatly changed throughout. The glomeruli and walls of the tubuli were inflamed. The glomeruli were filled with a granular material, exuded between the capillaries and Bowman's capsule. The tubes were obstructed by cylinders, and their epithelium was granular. The pericapsular and intertubular connective tissue was infiltrated with migratory cells. Sections coloured by Gram's and Weigert's methods showed streptococci in short chains in the capillary vessels, in the exudate, in the glomeruli, and in the tubes. Others, surrounded by masses of leucocytes, were present at certain points in the interstitial tissue.

CANCER OF THE KIDNEY.

100. An eight-year-old spaniel, left in hospital 19th March, 1892.

For the preceding month it had appeared very thin, although its appetite had remained good until a few days previous to entry, when it refused food, and remained continually lying down in a moist corner of the courtyard, in which it was left.

State on Examination.—The animal was very feeble. The muscular tissues, and especially the temporal muscles, were excessively wasted. The breath was offensive. A large, moderately firm, subcutaneous

swelling was noted on the left side of the lumbar region; and another hard, rounded, very large swelling on the left side of the inferior abdominal region. The abdomen was enormous, and the back was depressed. Temperature 39·4° C., pulse 170. The respiration, though only slightly accelerated (25 per minute), was irregular and discordant. The animal had shivering fits and muscular tremors. On percussion the entire depth of both pulmonary lobes showed partial dulness.

Diagnosis.—Malignant tumour in course of generalisation.

During the following days no notable change occurred. The urine was a little darker than normal, and albuminous. It contained glucose or bile pigment. Nothing could be detected on rectal exploration. On counting the blood-corpuscles a cubic millimetre was calculated to contain—

Red blood-corpuscles	8,215,875
White blood-corpuscles . . .	19,058

That is a proportion of 430 to 1.

The owner was informed that recovery could not be expected. Being handed over to us, the dog was kept until the 19th May. The tumours on the back and in the abdominal region increased in size, and the animal gradually became thinner until the day of death.

Autopsy.—Extreme wasting. On removing the skin covering the dorsal region an ovoid, lobulated tumour, as large as a man's fist, was found in the longissimus dorsi muscle, which at this point had almost entirely disappeared.

The left kidney was transformed into an irregular, ovoid, bosselated, obscurely fluctuating tumour, the size of a man's head. It was suspended by a peduncle, and floated in the abdominal cavity, adhering to the epiploon. On incision a brownish-red liquid escaped. After escape of liquid the growth weighed thirty-five ounces. The pelvis of the kidney was very large, irregular in shape, and lined with inflamed mucous membrane. An inch from the depression, which represented the hilum, the ureter was obliterated and atrophied.

The lower portion of the left lobe of the liver was deformed by a soft, fluctuating tumour, the size of a man's fist. Incision gave exit to a brownish liquid. The right lobe contained a tumour as large as a hazel nut, similar in appearance to the preceding, but which had not undergone softening.

On opening the thoracic cavity a new growth, as large as a pigeon's egg, was seen under the vertebral column, immediately in front of the diaphragm. The lungs were covered with mammilated tumours of varying dimensions and appearance, the largest the size of a hazel nut. Nearly 200 were counted on the different lobes, and sections revealed hundreds more in the depths. All these new growths showed the same macroscopic character; their tissue was greyish, friable, and full of liquid. The bronchial lymphatic glands were somewhat swollen.

On microscopic examination these tumours appeared formed by delicate connective-tissue bands surrounding alveoli filled with epithelial cells, usually of small dimensions.

Inoculation Test on Two Dogs.—The tumour developed in the longissimus dorsi muscle was kept in the incubator at 37° C. until the moment of inoculation. In the first dog the lumbar region was shaved and rendered aseptic. An incision, about an inch in length, was then made through the skin, the longissimus dorsi divided after displacing the skin, a fragment of the cancerous tissue inserted at the base of the muscular incision, and the skin allowed to return to its first position. The wound was sutured with silk and covered with collodion. In the second animal the fragment of cancerous tissue was placed in the subcutaneous connective tissue.

Next day the surroundings of the wound were slightly swollen. No suppuration occurred.

These inoculations remained sterile. The swelling they produced gradually diminished, and disappeared entirely during the course of the third week.

[A case of carcinoma of the kidney is described in section VII hereafter.]

DISEASED PROSTATE IN THE DOG.

101. Eight-year-old bull-dog, weighing 45 lbs.

History.—The development of disease was gradual and very ill-defined. Structural changes had occurred long before symptoms drew attention to them. During 1894 had several attacks of constipation, accompanied by slight prominence of the anus; but no marked symptoms occurred until three months before death. An attack accompanied by much straining, apparently due to impaction of fæces, then occurred, but after administration of enemata with a long tube suspicion arose of other complications, and careful examination revealed the condition of the urinary organs.

State on Examination.—With the abdomen relaxed and a finger in the rectum the pelvic swelling could be well defined, and was obviously either a prostatic tumour or a stone impacted near the neck of the bladder. A limited area of the tumour was calcified, and through the abdominal wall it felt exactly like a stone about the size of a small walnut, connected with the bladder and fixed to it, but not to the spine or pelvis, except to the extent to which the bladder and prostate were fixed. An impacted stone producing much inflammatory thickening and a partially calcified prostatic tumour would obviously have presented similar or identical symptoms; the latter hypothesis was thought the more probable, but the former was not altogether excluded. The bladder was greatly distended, as was to be expected; but there were peculiar features. In shape it was very much elongated in proportion to its breadth, passing high up into the abdomen, and its contour was broken by a slight constriction a little above the middle, giving it somewhat of an hour-glass shape; it was not clear at first whether this constriction was due to some fibrous band engaging the bladder itself, or to a partial interval between a distended bladder and a dilated kidney; but the question was settled by emptying the bladder with a catheter, when it was found only the lower part of the tumour was reduced, and that a soft fluctuating tumour remained in the left lumbar

region, due to a permanent hydronephrosis caused by obliteration or closure of the left ureter. Catheters up to No. 5 could be passed readily when there was no engorgement of the corpus spongiosum; but when this was present (and the irritation of the urinary organs was apt to produce it) even the smallest size would not pass the groove in the penile bone until the hyperæmia was relieved by a few whiffs of chloro-

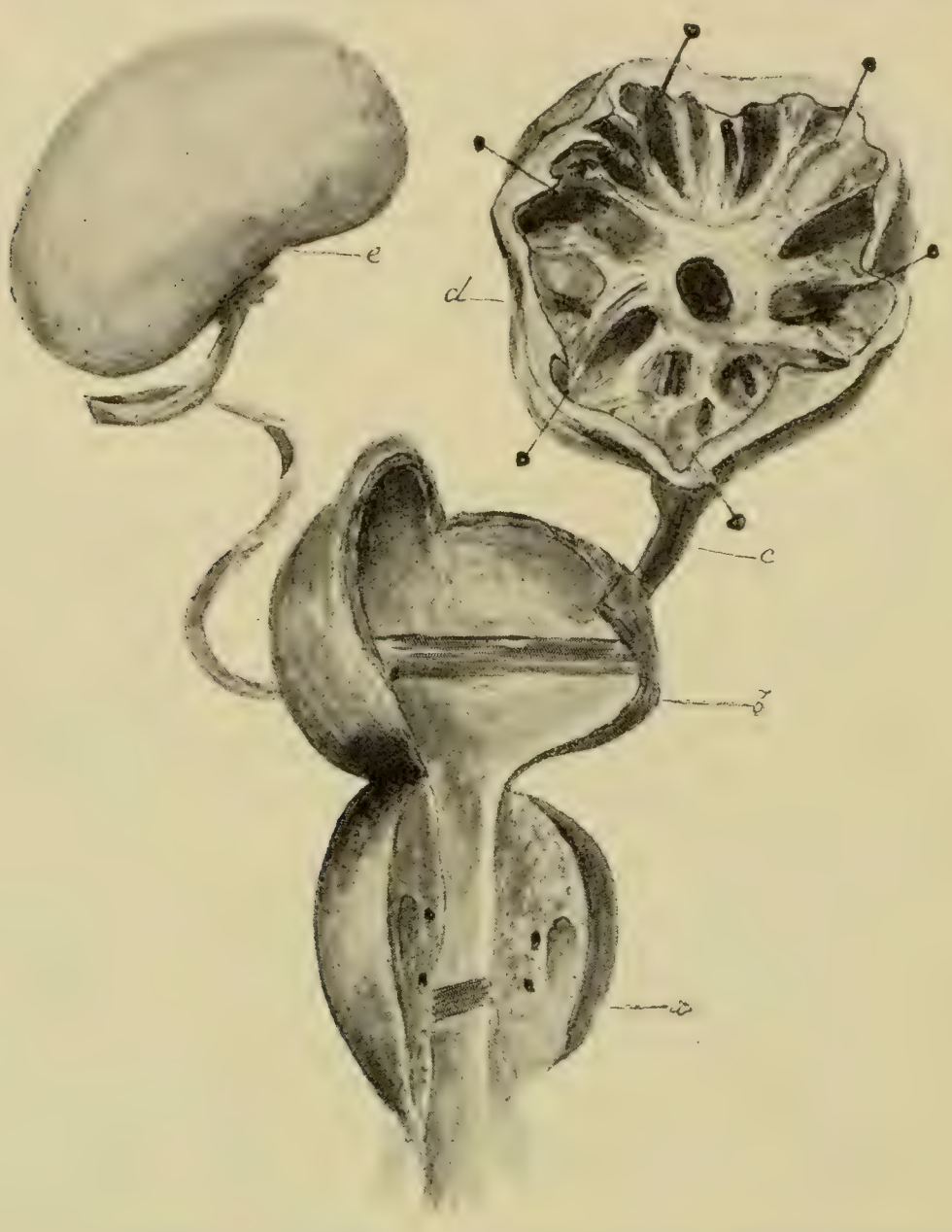

FIG. 40.—*a*. Prostate. *b*. Bladder. *c*. Thickened ureter. *d*. Diseased kidney. *e*. Hypertrophied (otherwise normal) kidney.

form. Human catheters were hardly long enough for this bull-dog, and for a large dog would have been too short.

It was resolved to keep the dog alive so long as he enjoyed his life and did not suffer much pain.

Treatment.—The bowels were regulated with gentle laxatives, principally sweet oil, which was taken readily in milk and kept the motions soft, and unloaded the bowels without purging or straining. Occasionally the rectum was emptied with a warm soap-and-water

enema administered through an elastic catheter, and irritation and spasm were controlled by sedatives administered by the rectum. The drugs were mixed with about a drachm of warm starch, and injected with an ordinary glycerine enema syringe. The most useful were belladonna, morphia, ergot, cocaine, and iodoform. Ergot is the only one not generally recommended for this condition, but the author regards it as a valuable vascular sedative, especially for the genito-urinary system. Two or more of the foregoing were usually given in combination—a dose at night, and sometimes one or even two in the day. By such means the dog was able to keep its bladder empty, or nearly so, without much difficulty; it had little or no cystitis, and the urine was never ammoniacal. Occasionally when the bladder, which was carefully watched, became distended it was emptied with a catheter.

It was decided if the symptoms could no longer be kept in check by the above means, that as there was a possibility of an impacted

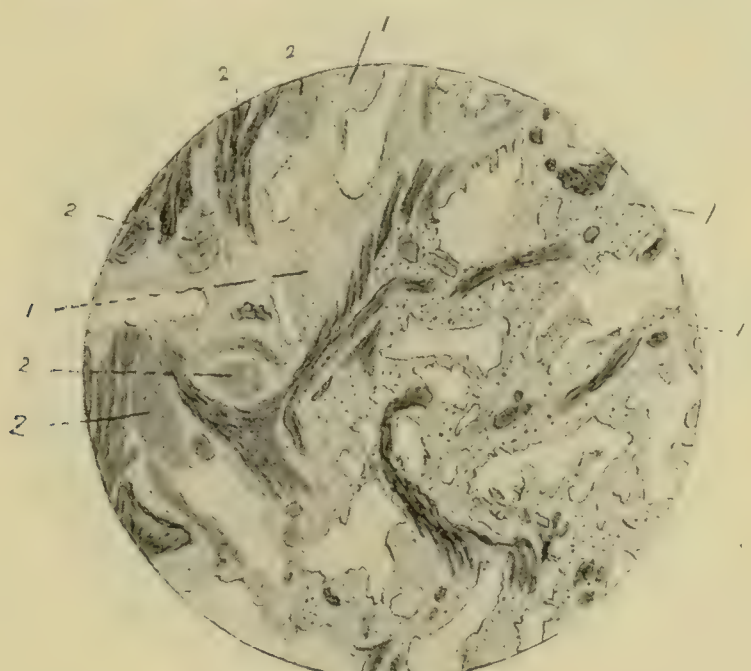

FIG. 41.—Prostate of dog. General structure. × about 16. 1. Fibroid tissue infiltrated with cells and enclosing irregular cavities. 2. Longitudinal and transverse sections of muscular bundles.

stone, the abdomen should be opened above the pubes with the strictest antiseptic precautions, and if the case proved hopeless an overdose of chloroform should be given; but if an impacted stone were found it should be removed by a supra-pubic lithotomy, and the animal given a chance of recovery.

It occurred to Mr. Clarke that, considering the small calibre and great length of the dog's urethra, and the probability of hyperæmia of the corpus spongiosum after an operation, which would render free access to the bladder and regular catheterisation difficult, it would be a great advantage to establish artificially a shorter route. A perinæal fistula is usually a curse to its owner, but this arises from the fact that it is usually associated with advanced vesical mischief, loss of control over the sphincter, and the constant dribbling away of ammoniacal

urine. As none of these conditions were present in this case, there appeared no reason why a perinæal fistula should be attended with any of these evils, nor why it should do more than give a dog a short and direct urethra like a bitch. To test this question the following operation was performed experimentally on a dog. Under ether the perinæum was shaved, a catheter passed into the bladder, and an incision made in the long axis of the urethra down to the catheter at the point in the perinæum where it could be most distinctly felt. A longitudinal incision half an inch long was made towards the scrotum, then bifurcating in the shape of a Y with the stem towards the anus. The fork of the Y was continued with a slight curve to both sides, extending altogether about two thirds of the way round the urethra, and forming two rounded flaps. These flaps were then stitched to the skin with a fine curved needle and horsehair. Both the result and the method

Fig. 42.—Prostate of dog. Section of portion of tumour where calcification is in active progress. × about 65. 1. Scirrhous structure, fibroid tissue infiltrated with epithelioid cells. 2. Calcified part. The calcareous salts are deposited in fine granules in the fibres, the spaces containing cells remaining in the same condition.

were satisfactory, though it might be better to divide the urethra and dissect half an inch of it up. After the operation a short straight catheter could easily be passed into the bladder; the flaps united to the skin, and the dog retained its water without difficulty and passed it through the artificial opening. The disease in Mr. Clarke's dog seemed to make very little progress for rather more than two months; then the animal began to show signs of increased irritation, it passed water more frequently, and could not retain it all night, and finally there was an attack of inflammation, which gave rise to a good deal of pain which was not controlled by sedatives; so having prepared sterilised dressings, instruments, and ligatures, and having the kind assistance

of Mr. Turner, Mr. Clarke shaved the perinæum and abdomen, washed them thoroughly with soap and hot water and then with ether, covered the abdomen with a towel wrung out in a weak solution of bichloride of mercury, with a slit cut in the towel corresponding to the proposed incision in the skin; sterilised cotton wool for sponges, instruments, and ligatures were placed in warm saturated boric solution, and an irrigator with a rose and tap was filled with boiled water and suspended above the table. Having given ether, the above-described perinæal section was first performed; the abdomen was then opened, but as soon as the parts were exposed it was evident that operative interference was out of the question, and the dog was therefore killed with chloroform.

Post-mortem.—A drawing of the parts is given. The prostate was much enlarged, being about the size of a billiard ball. In the anterior part was a calcified nodule as large as a small walnut, and of stony

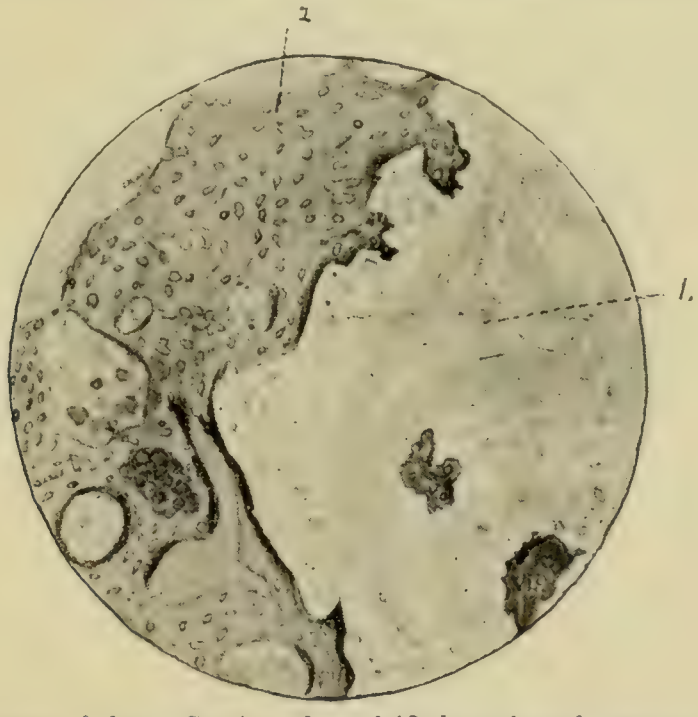

FIG. 43.—Prostate of dog. Section of a calcified portion of tumour. × about 65. 1. Fibroid tissue. 2. Imperfectly developed bone.

hardness, and from this point a new growth had invaded the pelvic tissues, forming firm and extensive adhesions. On section the substance of the prostate contained several cysts with semi-purulent contents; the termination of the left ureter was involved and completely obliterated in a mass of new growth of cartilaginous consistence; the ureter was dilated to the size of a man's middle finger, filled with fluid, and very thin. The left kidney was destitute of secreting structure, which had been absorbed; it was considerably dilated, and formed a sac filled with fluid, and with walls scarcely thicker than those of the bladder. The right kidney was hypertrophied, weighing more than four ounces. The bladder was thickened, but the mucous membrane was normal; the dog was fat, and all the other organs were perfectly healthy. Microscopically the tumour presented a great variety of structural changes.

According to Sir H. Thompson, the enlargements of the prostate usually found in elderly men are (1) true hypertrophy, (2) fibrous or fibro-muscular hyperplasia, (3) glandular hyperplasia, and (4) simple tumours and outgrowths. In addition to these are the cystic and malignant degenerations. Primary cancer of the prostate is, however, not common in men. The prostate of this dog appeared to have first undergone a fibro-muscular hypertrophy; the tumour was principally of a firm but spongy texture, consisting on section of fibrous trabeculæ, with numerous bands of muscular fibres passing in all directions and enclosing irregular spaces, so that to the naked eye a section resembled a section of lung; upon this a malignant process had supervened, the fibrous tissue became infiltrated with epithelioid cells forming groups and masses in the interstices of the fibrous bands, extending into the pelvic tissues, and at the anterior part of the tumour undergoing an

FIG. 44.—Right kidney of dog. Section showing tubules irregularly distended with swollen cells, diminishing or obliterating the lumen of the tubes. × about 65. 1. A glomerulus with thickened capsule.

imperfect ossification; there were also several cysts in different parts of the tumour. The right kidney, which was hypertrophied, showed signs of recent tubular nephritis, not unlike the condition found in scarlatina; the tubules were swollen and irregularly distended with cells. The glomeruli showed thickening of Bowman's capsule, but there was scarcely any areolar hyperplasia or cirrhosis.

Note by Mr. Clarke.—The question arises whether, if the disease had been detected earlier, it might have been arrested by castration. The difficulty appears to be to make a sufficiently early diagnosis.

Very careful attention to urinary symptoms in cases which appear to be only constipation would probably secure earlier recognition, though perhaps not early enough. Whether malignant changes are commoner in dogs than men is at present undetermined, but unless

they are usual it would seem worth while trying the effects of castration as soon as any enlargement of the prostate was discovered. The recorded cases of this operation in elderly men suffering from enlarged prostate have been very favourable. The adoption of this mode of treatment seems to have been partly due to John Hunter's comparison of the prostate of a bull with that of a steer, and to Griffiths, who observed the degenerated condition of the prostate in various animals after castration. Such observations must be very familiar to veterinary surgeons, and probably many of them are acquainted with the effects of castration on the prostates of different animals at different ages, the rate at which the prostate usually atrophies after operation, and whether enlargement or disease of the prostate is ever known in gelded animals. I do not know whether any such information is recorded, but I have not seen it.* Dr. White, who was the first to advise the operation for senile hypertrophy, argued that castration ought to be beneficial by analogy, from the effect oöphorectomy in women had upon uterine fibro-myomata. At any rate, the operation has now been performed for the relief of enlarged prostates of old men a good many times, and most encouraging results have been recorded, amongst others by the following operators:

F. Ramm of Christiania: two cases, with good results. *Centralblatt für Chirurgie*, No. 17, p. 387, 1894.

Dr. Francis Haynes, Los Angeles, California: three cases, all satisfactory. *Buffalo Med. and Surg. Journal*, March, 1894.

Fremont Smith: one case completely cured in six weeks. *Annals of Surgery*, p. 52, July, 1894.

Dr. Arthur Powell, Bengal: one case much relieved. *Brit. Med. Journal*, November 18th, 1893.

Mayer and Haenel: a bad case cured in two months. *Centralblatt für Harn- und Sex.-Org.*, Band v, Heft 7, 1894.

The references are taken from a *resume* by Mr. Hurry Fenwick in the 'Medical Annual' for 1895.

Mr. R. H. Clarke's case, *Veterinarian*, 1895, p. 431.

CRYPTORCHID OPERATIONS.

102. A three-year-old Percheron horse, entered 12th August, 1892.

Had been bought two months before in the belief that he was a gelding.

On examining the scrotal region no cicatrix could be discovered. Neither testicle had descended. The animal was prepared from the 12th to the 18th August by light diet, and internal administration of three and a half ounces of sulphate of soda daily.

Operation was performed on the right side according to the Belgian method. The horse was cast on the left side, the right hind limb carried forward and kept abducted by means of two strips of webbing. The scrotum and surrounding parts were most carefully disinfected.

At the entrance to the inguinal canal we found a rudimentary vaginal sheath containing a portion of the vas deferens. The inguinal

* *Annals of Surgery*, 1893.

space was opened throughout its entire depth outside the vaginal sheath, and the peritoneum perforated with the fingers at the spot chosen.

On exploring the preiliac region the epididymis was discovered and drawn into the canal. The testicle, which was next withdrawn, was excised with the écraseur. All blood-clot was removed from the wound, which was irrigated with sublimate solution. No dressing or suture was applied.

Slight hæmorrhage occurred when the animal rose, blood escaping in drops for several hours. During the following days the wound was irrigated with sublimate solution. No disquieting symptoms occurred.

The testicle weighed two and a quarter ounces, was flattened and flaccid. On section its tissue was seen to be fibrous, whitish, and marbled with blackish spots and lines. It was perforated with sinuous tracts, in which four armed strongyles were found.

On the 5th September operation was practised on the left side. Here the condition was similar. Treatment followed the same lines.

The left testicle weighed two and one eighth ounces, and resembled the right in appearance. Its tissue was fibrous, and traversed by irregular canals, in which we found three strongyles.

103. Three-year-old horse, left in hospital on the 10th May, 1893.

On examining the scrotum neither testicles nor cicatrices could be found. The animal was prepared in the usual way for six days. On the 17th the Belgian operation was performed.

The peritoneum was perforated at the base of the inguinal canal, the tail of the epididymis seized, and the testicle having been drawn into the canal was removed with the écraseur; hæmorrhage was trifling. The end of the cord was cauterised, the wound irrigated with sublimate solution, and the lips brought together with three cutaneous sutures. The testicle weighed four ounces.

The other testicle, found in the inguinal canal, was also removed with the écraseur.

An hour later the animal showed symptoms of trifling colic, which, however, passed off. The evening temperature was 38°.

Next day the sheath was a little swollen. The sutures were cut and the wound irrigated with 2 per cent. creolin solution. During the following days the general condition was good. The swelling above the sheath increased; suppuration was trifling. By the 31st, *i.e.* fourteen days after operation, the wound had almost closed.

104. A four-year-old half-bred horse, left in hospital on the 10th October, 1893.

Had been castrated in Normandy. The right testicle alone being accessible the operator had confined operation to removing it. On examining the scrotal region the cicatrix resulting from removal of the right testicle was found; none could be felt on the left side. After several days' preparation operation was performed on the 16th October by the Belgian method under chloroform.

The first stage having been completed, the external opening of the

lower inguinal ring had to be slightly enlarged to allow the hand to penetrate. No trace of the testicle was discovered. After examining the inguinal canal the peritoneum was broken through at the point chosen. The testicle was discovered after some moments' exploration. It was excised with the écraseur, and found to be very soft, flattened, and to weigh only one ounce.

A tampon of gauze was placed in the opening of the inguinal canal, and the cutaneous wound brought together with three interrupted sutures.

That evening the animal's condition was good. Temperature 38·8° C., respiration 17, pulse 45.

Next day the sutures were cut, the gauze removed, and the wound cleansed with warm sublimate solution. On the 18th swelling was marked. During the following day it extended under the belly, remained for some time stationary, and then became absorbed. Suppuration was trifling. The animal left hospital on the 4th November.

105. A four-year-old Percheron horse, entered hospital 24th May, 1895.

On manipulating the scrotal region the left testicle could be felt. The right side of the scrotum was empty.

The animal was prepared for six days, and operation performed on the 30th May according to the modified Danish method. The horse was cast on the left side, the right hind leg drawn into a position of abduction; the scrotal region washed with soap and water, and afterwards with an antiseptic, while the foot of the raised limb was covered with a moist cloth.

The inguinal canal contained a rudimentary vaginal sheath, which, however, on incision was found to contain only a portion of the vas deferens.

With the broad end of a grooved director the small oblique muscle, the transverse muscle, and the peritoneum were perforated a little outside of and behind the external commissure of the lower inguinal ring; the opening was afterwards enlarged with the same instrument. The right index and middle fingers having been introduced into the abdominal cavity soon discovered and withdrew the testicle, which was excised with the écraseur. Bleeding was checked with tampons of cotton wool, and the wound washed with a solution of sublimate.

The button-hole wound in the small oblique muscle was closed with a suture, the wound covered with gauze, and the skin brought together with sutures. The testicle weighed three ounces.

On the left side castration was performed by the covered operation.

After-treatment and progress were as in the preceding case.

106. Four-year-old Percheron horse, entered hospital 7th June, 1895.

The left testicle was of moderate dimensions. By examining the inguinal region the right could be felt. On rectal exploration the inguinal ring was found to be very narrow and to be traversed by a thin cord; the gland itself could not be discovered. The animal was

prepared for a week, and the modified Danish operation performed on the 14th.

The inguinal canal contained a rudimentary vaginal sheath enclosing a portion of the epididymis and vas deferens. The small oblique muscle was duly divided and the peritoneum opened. The opening being slightly enlarged in the direction of the muscular fibres, two fingers were introduced into the abdominal cavity and passed towards the upper inguinal ring. In a few seconds the testicle was discovered, seized, and drawn outwards. The traction on the gland caused the parts contained in the vaginal sheath to be drawn upwards; the epididymis was evidently astride the posterior border of the small oblique muscle.

The testicle was removed with the écraseur. There was no hæmorrhage. After closing the muscular breach with a silk suture the wound was cleansed, the entrance of the inguinal canal filled with gauze, and the scrotal opening brought together with three sutures. Weight of the testicle one and a half ounces.

On the left side castration was performed by the covered method.

During the afternoon the animal ate its food. In the evening it was a little depressed. Temperature 38·4° C.

Next day the sutures and dressing were removed and the parts washed with sublimate solution; temperature 38·8° C.

During the following days the margins of the wound became swollen, but the pus was creamy and trifling in amount. The antiseptic dressing was continued. The temperature varied between 37·8° and 38·4° C.

On the 28th the clams were removed. The temperature was normal. From the 23rd swelling diminished, and the wounds granulated actively. The animal left hospital on the 30th June.

107. A two and a half year old Breton horse, left in hospital 16th October, 1895.

On the right side a cicatrix and the stump of the cord could be felt; on the left no cicatrix and no signs of a testicle. Rectal exploration was also unsuccessful.

The animal was prepared for one week, and on the 23rd operation was performed by the modified Danish method.

The small oblique muscle was freely exposed by tearing through the aponeurotic layer covering the external commissure of the lower inguinal ring, and the muscle punctured at the usual point. Two fingers were passed through the aperture. The testicle was at once found, seized, and drawn outwards; forceps were applied to the vascular portion of the cord, and the testicle was removed with the écraseur; on the forceps being relaxed no hæmorrhage occurred. Weight of the testicle three and a half ounces.

The cord was returned to the abdomen, and the opening in the small oblique muscle closed by a suture. A gauze tampon was placed in the wound, and the skin brought together with three interrupted sutures.

During the afternoon the horse showed no signs of abdominal pain, and ate all its food. Temperature at midday 37·9° C., evening 38·4° C.

Next day the suture and gauze tampon were removed and the parts irrigated with a ·1 per cent. sublimate solution. Temperature, morning 37·9° C., evening 38·4° C.

On the 25th the animal's condition was excellent; temperature, morning 38° C., evening 38·4° C.

The sublimate lotion was continued. During the following days the temperature never rose beyond 38·2° C. The region of operation became slightly swollen, and a little suppuration occurred, but the animal was able to leave on the 6th November.

108. A five-year-old horse, left in hospital 15th May, 1896.

On exploring the inguinal region no testicle could be discovered; rectal exploration was also unsuccessful.

On the 20th May the modified Danish operation was performed.

The horse having been cast on the left side, and the right testicle not being discovered in the inguinal canal, the small oblique muscle was exposed and perforated at the usual point. The right index and middle fingers were passed into the wound, and after a few moments search the epididymis was discovered and the testicle withdrawn. Hæmostatic forceps were applied to the cord, which was divided with the écraseur. On removing the forceps there was no bleeding. The cord was returned to the abdomen. The wound in the small oblique muscle was closed with a single silk ligature, and the parts covered with a gauze dressing.

The animal was then turned over; the left testicle was also in the abdomen. A second operation was carried out similar to the first. The right testicle weighed three and three quarters, and the left one and a half ounces.

On rising, the horse was taken back to its box, and began to eat almost immediately. No serious symptoms during the day; evening temperature 38·5° C.

Next day the sutures and dressing were removed, and the wounds irrigated with warm 2 per cent. creolin solution.

On the 22nd, the animal ate all its food, but appeared depressed. Temperature, morning 39° C., evening 39·2° C.

During the following days the temperature varied between 38·5° C. and 39·5° C. There were, however, no serious after-symptoms. Left hospital on the 30th May.

109. A six-year-old Belgian horse, entered hospital 23rd June, 1896.

On rectal exploration the left testicle was found an inch or two in front of the anterior border of the ilium. The right testicle was similarly situated, slightly in front of the anterior margin of the pubes.

On the 28th, after a preparation of five days, the horse was castrated by the modified Danish method. It was cast on the right side, the left hind limb abducted, and the region disinfected. An incision about five inches in length was made over the left inguinal ring, the small oblique muscle freely exposed, and torn through at the usual point by means of a grooved directer. The left index and middle fingers were introduced into the abdomen, but neither the testicle nor cord could be

felt. An assistant therefore passed his hand into the rectum and thrust the organ from the prepubic region towards the operator's fingers. In a few minutes the epididymis was seized, the testicle withdrawn, forceps were applied to the vascular portion, which was divided with the écraseur, and returned. The lips of the wound in the small oblique muscle were brought together with silk. A gauze tampon was placed in the wound and fixed by sutures passed through the margins of the scrotal incision.

The animal was turned over and the same operation performed on the right side. On introducing the fingers into the abdominal cavity the testicle was almost immediately found, withdrawn, and excised, and the stump of the cord returned. The operation was performed as on the opposite side. Weight of the left testicle two and seven eighths ounces; of the right, one and three quarter ounces.

During the afternoon the patient took part of its food, but in the evening appeared depressed. Temperature 39·1° C.

On the 29th the general condition was good. Temperature 38·3° C. The sutures and dressing were removed, the wounds irrigated with warm creolin solution, and one and a half ounces of bicarbonate of soda given in the drinking water. During the day the horse ate all its food. Evening temperature 39° C.

Next day the morning temperature was 38·4° C., evening temperature 38·7° C. A little subcutaneous emphysema was noted in the flank. Treatment as on the previous day.

On the 1st July there was considerable swelling around the wound. Morning temperature 38·3° C., evening temperature 38·6° C.

From the 7th onwards the wounds became covered with granulations, and the œdema gravitated towards the umbilicus. The animal left hospital on the 13th July.

110. A three-year-old half-bred horse, entered hospital 18th October, 1896.

This horse had been castrated on one side when about two years old. On manual examination of the inguinal region the cicatrix resulting from castration could be felt on the right side; on the left the testicle could not be discovered.

The animal was prepared from the 18th to the 23rd October, and operated on by the modified Danish method.

Having been cast on the right side it was fixed as usual. Immediately after perforating the small oblique muscle and peritoneum, at the moment when the two fingers were passed into the abdomen, about three pints of yellowish serosity escaped. The testicle was easily found and withdrawn. It was removed with the écraseur, and the cord returned to the abdomen; the small oblique muscle was closed with a silk suture, a gauze tampon was applied to the wound, and three sutures were passed through the skin. The testicle weighed five ounces.

The animal was allowed to rise and returned to its box. During the evening it ate its food. Temperature 39° C.

On the 24th October the cutaneous sutures and the gauze tampon were removed. Temperature 38·3° C.

During the following days the temperature never rose beyond 38·7° C. The animal left hospital on the 4th November, at which time the wound was about three quarters healed.

111. A five-year-old Percheron horse, entered hospital 26th May, 1898.

The right testicle had descended, but the left was retained in the abdomen. The animal was prepared from the 26th May to the 2nd June, and operated on by the modified Danish method.

The testicle was found and withdrawn in a few minutes, and the cord divided with the écraseur. On the right side castration was performed by the covered method. The right testicle weighed two and three eighths ounces.

On returning to its box the horse ate part of its food. The evening temperature was 39·2° C. On the 3rd June the animal showed signs of depression, and a certain amount of emphysema in the right flank. The dressing was removed, and the wounds irrigated with a 1 per 1000 solution of sublimate. Appetite was fair. Temperature 39·5° C., pulse 40, respirations 27. Four drachms of quinine sulphate, and ·5 per cent. creolin enemata were given.

On the 4th the temperature was 39·5° C., respirations 36, pulse 52. The pulse was feeble, the respiration shallow, and expiration sighing. The animal ate part of its food. The evening temperature was 41° C.

On the 5th the emphysema in the flank remained stationary; the wound suppurated a little. Temperature 40·2° C., respirations 34, pulse 54. Appetite was fair. Same treatment. Evening temperature 40·3° C.

On the 6th the temperature was 40·6° C., respirations 46, pulse 54. The creolin enemata were continued. Four drachms of quinine sulphate, and 8 ounces of sodium sulphate were given internally.

On the 7th the patient refused part of its corn. Temperature 40·3° C., respirations 46, pulse 54.

A mustard plaster was applied. In the morning 1 drachm of calomel, and in the evening 4 drachms of quinine sulphate were given. The wounds were cleansed with sublimate solution. During the afternoon prostration became very marked, and expiration moaning. Evening temperature 40·8° C.

During the following five days the condition remained stationary.

On the 13th the temperature was 39·5° C., respirations 35, pulse 50. One quart of 1 per cent. salt solution was hypodermically injected, and three ounces of sodium bicarbonate, five drachms of quinine sulphate, and six quarts of milk given by the mouth. The animal ate little and showed signs of colic and diarrhœa; manipulation of the abdomen was painful.

On the 14th the general condition was bad. Morning temperature 38·5° C., respirations 20, pulse 44. One pint of salt solution was injected. The abdomen was tapped at the lower part of the left flank, and some quarts of a slightly turbid liquid, which gave an abundant deposit, were withdrawn. One pint of salt solution, and four ounces of

30 per cent. tincture of iodine were afterwards injected by the cannula. The evening temperature was 39° C. Hypodermic injection of one pint of salt solution; oral administration of 4 drachms quinine sulphate, $1\frac{1}{4}$ drachms of laudanum, and six quarts of milk.

On the 15th improvement was perceptible. The animal had eaten its food, and its expression was brighter. Temperature 38·6° C., respirations 24, pulse 48. The same treatment as on the previous day was continued.

On the 16th improvement was again marked. The diarrhœa had diminished, and the animal took note of its surroundings. Temperature 38·4° C., respirations 28, pulse 40. Same treatment.

On the 17th and 18th the appetite was good; the fæces became more consistent. Temperature 38·2° C., respirations 14, pulse 40. The injections of salt solution were continued, and the oats increased. During the following days the last symptoms disappeared.

On the 23rd the temperature was normal, and the wounds had almost healed. The animal left hospital on the 26th, was put to work some days later, and rapidly recovered its condition and strength.

Remark.—Even in solipeds the peritoneum is fairly tolerant. It is well protected against infection, otherwise the mortality after intra-abdominal operations, as usually practised, would be considerable, for despite all precautions morbid germs are introduced into the peritoneum. But not only are complications rare, but traumatic fever is often very moderate.

In castrating cryptorchids it is of the greatest importance to avoid soiling the hands, the écraseur, the forceps, or the ligatures applied to the cord. If at first the testicle cannot be found, the operator must under no circumstances perform rectal exploration, and if an assistant carries out this part of the operation he must not afterwards touch the instruments, especially the chain of the écraseur, even though his hands have been washed and disinfected. Against this possible source of inoculation of the operative wound special care must be taken. The peritoneum may be infected even though the soiling of the operator's fingers occurred one or two days previously if an abscess has been opened or a *post-mortem* examination made. Under such circumstances the fingers remain infected for two or three days, even though washed with germicide solutions, and unless the most minute precautions are observed, asepsis of the veterinary surgeon's hands is for this reason almost always a fallacy.

For the past four years I have used the modified Danish method in castrating cryptorchids in my portion of the hospital. It can very readily be performed even by the average practitioner. It is not more dangerous than other methods, and has the great advantage over them of allowing all the details of the different operative acts to be followed visually.

CRYPTORCHIDISM IN THE CAT.

112. A two-year-old cat, left in hospital 4th May, 1898.

Two months before a veterinary surgeon had excised the right testicle. Somewhat later an unsuccessful attempt had been made to

remove the left, which was retained in the abdomen. A ventral hernia had developed beneath the second operative wound.

On the 5th May the animal was fixed on the table and chloroformed. After disinfecting the parts M. Almy made an incision of about three quarters of an inch in the long axis of the hernia, dividing the subcutaneous tissue and afterwards opening the hernial sac. The left testicle was found at the entrance to the pelvis, was withdrawn, and removed by torsion. The muscular wound was closed by interrupted silk sutures, and the cutaneous incision by sutures of silkworm gut. The wound was painted with collodion containing salol, and the abdomen covered with a dressing.

On the 10th the dressing was removed. The wound only contained a little blood-stained serosity.

On the 13th the sutures were cut and removed; two thirds of the wound had healed. During the following days the parts were simply washed with an antiseptic solution. The animal left hospital on the 19th May.

CANCER OF THE SCROTUM.

113. A seven-year-old setter dog, left in hospital 15th October, 1898.

Had suffered for four months from a tumour on the scrotum, which had become ulcerated, and had been unsuccessfully treated by cauterisation with nitrate of silver.

State on Entry.—The tumour appeared as a rounded, reddish patch the size of a two-shilling piece, covered with fine granulations, slightly painful on touch, sharply defined, and with hardened margins. From a distance, and at the first glance, it resembled a patch of moist eczema, but on closer examination its nature was clearly apparent. It was in fact an ulcerated cancer. The inguinal glands were not infected, and the animal's general health was good.

Treatment.—On the 17th October the tumour was removed. The region having been prepared and disinfected, complete excision, without injury to the deeper structures of the scrotum, proved easy, as the new growth only extended to the superficial layer of the dartos muscle. The lips of the wound were united with silk sutures, and a cotton-wool dressing, kept in position by a bandage, was applied. Despite the precautions taken, the centre part of the wound suppurated, and was not completely healed until the 4th November.

The animal left hospital on the 8th. Recovery was perfect. There was no return.

The tumour was a lobulated epithelioma. Sections stained with picro-carmine appeared formed of a more or less abundant fibrous stroma, enclosing masses of newly formed epithelial cells and epidermal "nests."

CANCER OF THE TESTICLE—UNSUCCESSFUL ATTEMPT TO INOCULATE.

114. A ten-year-old entire horse, entered hospital on the 4th February, 1898. During the previous four months the right testicle had progressively increased in size.

At the time of examination it was as large as a child's head, ovoid in form, uniformly hard, and bosselated; the skin was moveable over its surface. The lower portion of the cord was swollen, but there were no signs of acute inflammation. On rectal exploration an irregular tumour, formed of several lobes each the size of a man's fist, was discovered under the centre, and extending somewhat to the right of the sublumbar region.

Treatment.—The animal having been cast on Daviau's table, the testicle was removed with the écraseur. The cord, which was found

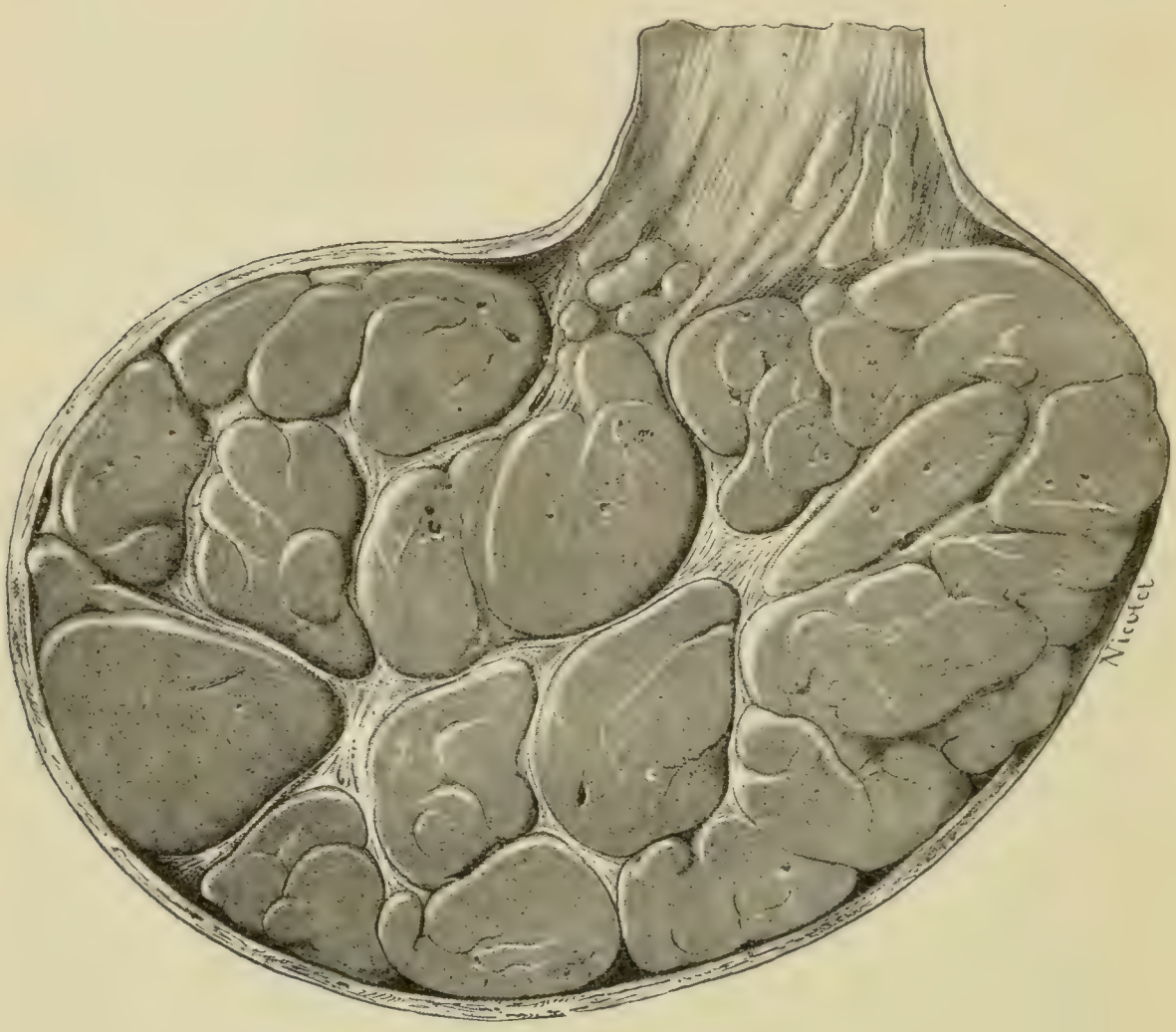

FIG. 45.—Epithelioma of the testicle. Section.

to be little changed, was cut through about three inches above the epididymis. The operative wound healed without trouble and as rapidly as after normal castration. The tumour weighed five and a half pounds. On section it appeared reddish-grey in colour, succulent, and formed of lobules of varying size; the interstitial connective tissue was scanty in front and towards the margins, but more abundant in the centre (Fig. 45).

On microscopical examination this tumour was seen to be formed of a fairly abundant fibrous stroma, arranged in tracts surrounding large alveoli filled with polyhedral epithelial cells. At certain points,

where these tracts were of some thickness, they contained lines of epithelial cells.

With the owner's consent an attempt was made immediately after operation to inoculate with the new growth on the left side of the neck. The skin, having been shaved and disinfected, was incised for a distance of one inch, and a small pocket formed by blunt dissection, into which a fragment of the tumour, about three eighths of an inch square, was introduced. The skin was united with two sutures and covered with collodion, protected by a fragment of taffeta. Healing occurred by first intention. The trifling swelling which formed disappeared in a few days, leaving an indurated patch, which finally became entirely absorbed.

The patient left hospital on the 16th February, and returned to work a few days later. At first it was brought back weekly, and later once a month. In spite of hard daily work, and the fact that the growth under the lumbar vertebræ increased in size, the animal's condition markedly improved for several months, and work was continued without interruption until the 3rd November.

On that day the animal was brought for examination on account of loss of strength and appetite. It had worked as usual on the previous day. The symptoms were those common to all wasting diseases: the conjunctiva was very pale, the pulse small, the circulation and respiration markedly accelerated, the temperature 38·9° C. Auscultation of the heart revealed a systolic murmur. On manipulating the abdomen peritoneal exudate was recognised. The sublumbar tumour had become enormous. The condition being regarded as due to generalisation of the cancer no treatment could be advised.

The animal returned home, and died during the night. Next day the cadaver was sent to us for examination. The abdominal cavity contained a large amount of blood-stained exudate, though the large vessels were normal. The intestines appeared healthy. The upper part of the right spermatic cord was very large and moniliform (with expansions and contractions, like a string of beads); it exhibited a chain of new growths, varying in size between that of a hazel-nut and a walnut, and extending as far as the sublumbar tumour. The latter was sixteen inches in length by ten in breadth, and showed numerous rounded projections, some as large as an apple. It weighed sixteen and a half pounds. Pyramidal in form, its base partly obstructed the anterior opening of the pelvis; its summit, which was slightly inclined towards the right, was in contact with the corresponding kidney; its upper surface adhered to the sublumbar region; its inferior was ulcerated, and showed an irregular tear with ecchymosed margins, from which the bleeding had occurred. In front of the tumour the right ureter was dilated; the walls of that portion contained within the tumour were hardened and thickened, while their lumen was considerably diminished; the right kidney was slightly dilated. The left ureter was obliterated, and the corresponding kidney showed lesions of hydronephrosis. No secondary tumours were found in any of the viscera.

[A case of round-celled sarcoma of the testicle is described in section VII hereafter.]

SPERMATIC ANEURISMAL VARIX IN THE OX.

115. Two-year-old Dutch bullock in prime condition.

State on Examination.—The swelling presented the appearance of a very large testicle, over which the unmistakable purring fremitus and humming bruit were well marked.

The scrotum was carefully removed close up to the abdominal wall, and the artery, and from that the vein, injected with wax. The disparity in size between the artery and vein was marked. Each scrotal sac showed a very visible castration cicatrix.

Note by Professor Walley.—The origin of aneurismal varix in the spermatic vessels of the castrated animal is perhaps more easy of explanation than in the case of uncastrated animals. It would appear to arise in much the same manner as the stump aneurisms so familiar to the surgeon, *i. e.* a communication would seem to be established between the severed ends of the spermatic vessels shortly after castration. At first sight it might be thought that the arterial influx would be conveyed away by the spermatic vein without much difficulty, but when it is remembered that the arterial blood has, under normal circumstances, to pass through the capillaries of the testicle, and that the impetus of the arterial influx is thereby materially checked, whereas in such cases as that under consideration it passes directly into the vein, which cannot possibly convey it away as quickly as it is poured in through the artery, it will be seen that both vessels must in the end become greatly dilated. In due course another factor in the production of distension is superadded in the gradual narrowing of the inguinal canal and the abdominal rings. In no case have I seen the dilatation extend beyond the external ring, showing, I think, conclusively that the aneurism has its origin in obstruction to the venous flow.

Prof. Walley's case, *Journ. Comp. Path. and Therap.*, 1894, p. 68.

SCIRRHOUS CORD WITH URETHRAL OBSTRUCTION IN THE HORSE—OPERATION—RECOVERY.

116. An aged chestnut Clydesdale gelding, seen on the 17th March, 1893.

History.—Had difficulty in micturition.

State on Examination.—The animal made repeated attempts (even when moving) to micturate, but could only pass small quantities of urine, which continued to flow for several minutes after each attempt. The animal showed scirrhous cord on the left side, and a considerable amount of dense tissue embracing the lower and lateral aspects of the penis, about six inches from its free extremity, beyond which point a catheter could not be passed. On rectal exploration the bladder was found greatly distended.

On the following day the horse was cast, and the scirrhus exposed by dissection, doubly ligatured high up, and removed. The dissection being continued in a forward direction, the enlargement around the penis was found to be caused by hypertrophy of the suspensory

ligament of the sheath. It was removed by the knife. The catheter was afterwards passed without difficulty.

The incision in the sheath was sutured and dressed antiseptically. Considerable œdema occurred, but soon subsided. The ligature sloughed away from the spermatic cord, the wound healed, and the aneursis gradually ceased. Recovery was very satisfactory.

Prof. Walley's case, *Journ. Comp. Path. and Therap.*, 1893, p. 361.

NECROSIS OF THE PENIS.

117. Two-year-old setter dog, left in hospital 21st October, 1898.

During the early part of October had been injured at the base of the sheath when hunting. In forty-eight hours the prepuce became greatly swollen, rendering micturition difficult. Despite treatment the symptoms grew worse, and the patient was sent to us.

Condition on Entry.—The sheath was enlarged, œdematous, and its right surface exhibited two suppurating wounds from which urine escaped during micturition.

The dog having been secured on the table, an incision, two inches in length, was made along the median line of the sheath, the lips everted, and the penis, which seemed to be necrotic, exposed. In endeavouring to draw forward the penis, the free extremity ruptured opposite the anterior part of the bone of the penis. This portion was removed, some fragments of dead tissue still adherent to the bone were snipped away with scissors, and the bone itself slightly curetted. The parts were dressed with gauze, care being taken to leave an exit for urine.

During the night blood-stained urine was several times passed. During the following days the urine was expelled without difficulty, and the patient, though previously thin and weak, recovered its strength and condition.

Treatment.—On the 4th November an inverted V-shaped incision was made over the inferior surface of the sheath, behind the first operative wound and over the bone of the penis, the tissues covering the bone were removed, and the urethral gutter enlarged by means of cutting forceps. Although the lips of the wound were touched with the actual cautery, operation was followed by considerable hæmorrhage, which returned during the night, and for several days afterwards whenever urine was voided. The patient left hospital on the 15th November, and at once took its usual place in the pack of hounds. We recommended its being kept under observation and returned if it showed symptoms of contraction of the urethra.

The artificial urinary meatus contracted somewhat rapidly, and the dog again came into hospital on the 19th December.

To permit of urine being evacuated the urethral canal and the tissues covering it were laid open for a distance of half an inch. Hæmorrhage was considerable, and for several days recurred during micturition.

From the 26th to the 30th December a subcutaneous injection of one and a half ounces of artificial serum was made daily.

On the 6th January the urethral orifice was again enlarged, this

time opposite the posterior part of the bone of the penis, the urethra laid open, and the tissues covering it removed in the shape of an inverted V. To prevent further loss of blood the lips of the wound were cauterised without touching the margins of the urethra. The result of this second operation was good; the urethral orifice remained permanently free.

CANCER OF THE PENIS.

118. A twelve-year-old gelding, left in hospital 15th January, 1897. Had been in its then owner's hands since 1889. No previous disease. A month before the horse was noted to have difficulty in "drawing the penis" when staling. A veterinary surgeon, who was called in, discovered a tumour on the penis and recommended its removal. The horse worked up to the day of entering hospital.

At the time of examination the horse was in good condition, and did not appear to suffer from the disease. The sheath was swollen, and discharged a little blood-stained fœtid pus. On introducing the hand a hard, indolent tumour was found on the penis. When the organ was withdrawn it appeared of large size, and its lower third was covered with blackish, friable cauliflower vegetations. The upper part of the new growth was sharply defined. Microscopic examination of a fragment showed it to be of a cancroid nature.

Treatment.—Amputation of the penis above the tumour. On the 18th the horse was cast on the left side and secured, as for castration. The inguinal region having been disinfected, an elastic ligature was applied to the base of the penis to check hæmorrhage. Amputation was performed by the method described on p. 61. On the horse returning to its stall some hæmorrhage occurred, but only in drops.

During the evening the animal showed signs of trifling colic. The mucous membranes were slightly injected; the pulse accelerated, respiration normal, temperature 38·5° C. Hæmorrhage returned during the night, the blood escaping sometimes by drops, sometimes in a thin stream. The sheath was washed out with warm 2 per cent. creolin solution.

The part of the penis removed was five times the normal size, and covered with blackish, very friable, irregularly arranged vegetations, some the size of a hazel nut, others larger than a walnut. The urethral orifice was thrust towards the left side and masked by a large growth. All the lower half of the penis was dotted over with little greyish tumours resembling papillomata.

On the 19th the general condition was good. There was no fever. Micturition was performed easily. The sheath was washed out with lukewarm antiseptic injections.

Next day the sheath showed swelling, which increased for several days. On the 26th it was less swollen and sensitive. On the 27th the portion of the stump destroyed by the ligature separated. Urine was easily passed; the animal left hospital on the 29th January. There was no after contraction.

After disinfecting and scarifying the integument of the glans penis in a horse retained for experiments, we attempted to inoculate the new

growth. The scarified surfaces were several times rubbed with fragments of the tumour, which had been kept in the incubator at 38° C. The result was negative.

119. An eighteen-year-old gelding, left in hospital 10th May, 1898.

For a long time previously this horse had shown difficulty in urinating: it stretched out and made efforts, but the penis did not protrude beyond the sheath, and the urine escaped in a straggling stream accompanied by very offensive pus.

State on Examination.—The scrotum and prepuce were extremely sensitive to the touch. After casting the horse the penis was withdrawn, and a tumour the size of a man's fist, occupying the upper and right lateral surfaces, but not affecting the urethra, was found on its free extremity. This tumour was greyish in colour, ulcerated, divided into two lobes by a deep longitudinal groove, and covered with a thick layer of offensive material, formed by pus, blood, and smegma. Urine was passed into the sheath, which was greatly inflamed. The general condition was satisfactory, and the functions of the body normal.

Treatment.—On the 19th May a portion of the penis was amputated by the usual method. Hæmorrhage was trifling, and was checked by applying a rubber bandage, an inch below which the penis was cut through. Evening temperature was 38·5° C. The horse ate its food.

On the 20th and 21st the animal was depressed, left the greater part of its food, and showed signs of colic. The sheath was enormously swollen and the stump of the penis retracted. Temperature 38·9° C. During the next two days the condition remained stationary.

On the 25th the animal was cast on the table. The sheath had greatly contracted, so that the stump could not be protruded. It was laid open. The extremity of the penis was slightly swollen, the india-rubber ligature had cut through, and the urethral wound was covered with sebum and blood-clot. The sheath was freely incised along the middle line. The somewhat free bleeding which ensued was checked by the actual cautery and application of forceps.

During the following days the stump was readily protruded previous to staling.

When the horse left hospital on the 10th June the preputial and urethral wounds were healing well.

On microscopic examination the tumours in this, and in the preceding case, appeared formed by a connective tissue stroma, and by pavement epithelial cells arranged in lobules of various size. In the small lobules the cells appeared actively growing, and stained readily with carmine; in the centre of the larger the cells had undergone cornification, and were arranged in epidermal "nests."

PARALYSIS OF THE PENIS.

120. A fifteen-year-old entire horse, left in hospital 23rd December, 1897.

A few days after an attack of colic the penis had remained pendent and swollen, and could not be retracted into the sheath. It was scarified and cold douches applied, despite which, however, it

increased in size. During the course of the third week of treatment the animal was sent to the College.

State on Examination.—The penis, which was doubled in size and insensitive, hung inertly from the sheath. Its surface showed signs of the scarification which had been performed. The scrotum was slightly swollen. There was no fever.

Until the 4th January the treatment consisted in: scarification, repeated cold spraying, passage of the electric current, and internal administration of potassium iodide. No improvement followed. Amputation was finally resolved on.

The operation was performed by the usual method. The urethra was exposed, incised, and the flaps sutured to the surrounding integument. An elastic ligature was applied to the penis, the free portion of which was divided just below. Hæmorrhage was somewhat abundant, and returned several times after urination. The sheath and scrotum showed extensive swelling, which persisted until the end of the second week, when it began to subside. The wound was cleansed night and morning with warm creolin solution, and healed regularly. The animal left on the 5th February. The scrotum and sheath were still slightly swollen, but urine was freely passed. There was no after-contraction.

121. An eight-year-old gelding, left in hospital 16th May, 1898.

Three months before this horse had suffered from pneumonia. During the period of resolution the penis became paralysed. One morning it was found swollen, pendent, inert, and exhibiting a sharply defined circular ridge, a few inches below the margin of the sheath. The condition was at first treated by douches and scarification, but unsuccessfully.

Condition on Entry.—On the day of entry the protruding section of the penis measured fourteen inches in length, was swollen, œdematous, insensitive, and about three times normal size. It showed scarification marks, some of which still suppurated, though others had healed. The sheath was slightly engorged. The animal's general health was excellent.

On the 18th May the penis was amputated by the usual method. A reversed V-shaped incision was made on the lower surface, each limb being about three and a half inches in length. The other stages of the operation were as usual. The excised portion of the penis weighed six and a half pounds. On the animal rising the stump bled, and continued dripping for half an hour. During the night only a part of the ordinary food was consumed.

During the following days nothing noteworthy occurred. There was no hæmorrhage, and the temperature did not exceed 38·5° C. The sheath swelled, the wound suppurated slightly, and the gangrenous portion of the penis became blackish and hard. Urine was passed without difficulty.

At the end of a week suppuration had almost ceased. The eschar only held by a narrow pedicle, and on the ninth day became separated. The wound had healed and the urethra was widely open. The animal left on the 28th May. There was no after-contraction.

This horse died on the 3rd May, 1899, from rupture of the stomach. Fig. 46 shows the appearance of the urethral opening at that time, *i. e.* one year after operation.

122. A ten-year-old entire horse, entered hospital 26th November, 1898, affected with paralysis of the penis consecutive to pneumonia.

On a certain day during the convalescent period the penis was seen to remain pendent. For the following few days it increased in size. As scarification and cold douches produced no benefit the horse was sent to Alfort to undergo amputation.

The animal's general condition was good. The penis was insensitive and pendulous, four times its normal size, and marked with transverse ridges and depressions. The paralysis having only existed for a month, that is from the 26th November to the 4th December, was at first treated by local scarification, douches, and administration of

Fig. 46.—Amputation of the penis showing stump and urethral orifice.

potassium iodide. The parts were several times scarified at a dozen points, hæmorrhage on each occasion being abundant and prolonged. Nevertheless, the extremity of the penis only diminished slightly in size, and remained paralysed and insensitive.

On the 5th December the organ was amputated by the usual method, though the sutures were slightly modified. The urethral canal having been dissected free, cut transversely, and the exposed portion laid open, the flaps of mucous membrane were only attached to the skin by two sutures passed about three eighths of an inch from the margins of the wound. The integument of the penis was divided in a circle opposite the base of the wound, the elastic ligature drawn tight in the depression thus formed, and the penis cut through about three quarters of an inch below.

Despite the application of the elastic ligature considerable hæmorrhage occurred, and had to be checked by cauterisation and the application of forceps. A quart of one per cent. salt solution was injected

into the subcutaneous connective tissue of the neck. The animal was fed on hay tea and milk.

A great deal of blood having been lost by scarification, salt water injections were repeated on the three following days. The extremity of the penis was irrigated night and morning with a warm antiseptic solution.

Until the 8th the animal remained feeble and depressed, and refused part of its food. Temperature 38·1° C. to 38·5° C. On the 9th it began to rally, and each succeeding day improvement was more marked.

On the 13th the slough and ligature separated, the margins of the excision wound were covered with large granulations, but the urine was passed without difficulty. Subsequent progress was steady. The animal left hospital on the 4th January.

ATROPHY OF THE PENIS.

123. A twelve-year-old gelding, left in hospital 28th May, 1898.

Soon after purchase this horse was noticed to pass urine into the sheath, which was inflamed, enlarged, and filled with very offensive sebaceous material. Micturition was slow, difficult, and painful.

The horse was cast, fixed as for castration, and the sheath cleansed and disinfected. M. Almy then proceeded to operate. There was difficulty in passing the hand into the sheath even for a short distance, and the penis could not be discovered. The sheath was laid open for a distance of four to five inches; free bleeding occurred, which was checked by the application of artery forceps. In spite of this incision it was still impossible to seize the penis. The incision was therefore extended backwards for a further distance of four inches. Finally, the penis was discovered in an atrophied condition.

The internal and external integuments of the sheath were united with interrupted silk sutures throughout the posterior two thirds of each lip; the anterior third, being inflamed and greatly thickened, was excised. The artery forceps were removed, and bleeding vessels twisted or ligatured.

Next day urine was easily passed, the jet falling vertically from the preputial opening. The parts were irrigated with warm one per thousand sublimate solution.

During the following days similar treatment was continued. Swelling was considerable, but gradually diffused over the abdomen and became absorbed. Healing was rapid.

The horse was seen three months later. Operation had been successful; the head of the penis remained sufficiently exposed, and urine escaped in the form of a jet.

CALCULUS IN THE URETHRA.

124. The subject was a cat, which had previously enjoyed good health. One evening, without apparent reason, it refused to eat, appeared greatly depressed, and hid away in dark corners. A few hours later it was brought for examination, the history given being

that on the evening when attacked it had been played with by some children and made to walk on its hind legs.

The animal was very fat, and none of the internal organs could be examined. It died on the day of entering hospital.

On *post-mortem* examination the peritoneum of the posterior abdominal region and pelvis was found to be inflamed; the bladder was an enormous size, full of turbid urine, and its walls were extremely distended and inflamed. It contained no foreign body, but in the urethra, not far from its origin, we found a rounded calculus the size of a hemp seed, which had hermetically sealed the passage.

URETHROTOMY FOR REMOVAL OF CALCULUS IN A HORSE.

125. Six-year-old cart-horse, seen at midday, December 15th, 1894.

History.—The horse was said to have had difficulty in staling for a month or two previously; at first the urine had escaped in a thin stream, afterwards it dribbled away almost continuously, but on the day in question the horse had not been seen to stale. It perspired greatly at work, seemed easily distressed, and had once or twice shown signs of colic when returning from work.

State on Examination.—The horse was perspiring freely and blowing a good deal. On coming to a stop it immediately stretched out as though to urinate, strained rather violently and groaned, but passed no urine. The sheath was explored, the penis withdrawn, and the urethra examined by passing the fingers along the lower surface of the penis; nothing abnormal was discovered. On rectal examination the bladder was found enormously distended, so that at first it was proposed to tap the bladder with a trocar. It was, however, decided to first pass a catheter. The instrument was arrested at the point where the urethra passes round the ischial arch. On examining the intra-pelvic portion of the urethra it appeared distended, forming a kind of band extending from the bladder to just beneath the anus, where a hard enlargement, painful on pressure, was discovered. An impacted calculus being diagnosed, urethrotomy was performed.

An intra-venous injection of morphine and atropine having been given, the hind legs were hobbled, the catheter again passed, and the perinæal region carefully washed with 1 in 2000 sublimate solution, which was also used to disinfect the operator's hands. With an ordinary scalpel the urethra was incised over the catheter; the lips of the wound were retracted, and by exploration with the tip of the forefinger a rough-surfaced calculus was discovered about an inch and a half in front of the incision. A little melted vaseline was injected, and after slight manipulation the calculus was removed. A gush of urine followed; the writer estimates that in all about two gallons and a half were voided. Rectal exploration failed to detect any more calculi.

After cleansing with an antiseptic solution the wound was closed with three harelip sutures and the catheter withdrawn; the parts were dusted with iodoform and covered with a pad of antiseptic wool, re-

tained in position by two strips of plaster bandage, and the whole covered with a piece of silk, also fixed by strips of plaster. The tail was secured to the collar and the animal tied up short. Slop food and small doses of potassium nitrate were given. The anus, etc., was cleaned three or four times daily.

Next day urine was observed to be dribbling from the sheath—a fact attributed to temporary paralysis of the sphincter vesicæ, due to the previous great pressure and distension. This dribbling ceased about four days after operation. On removing the dressing on the third day the wound appeared perfectly healthy, with little swelling; the lips seemed to be adherent. The pins were removed, the parts dusted with iodoform and, quickly covered with a medicated pad, secured as before.

Progress was excellent and appetite good. On the sixth day the horse urinated with apparent ease. The pad was removed from the wound, which was almost healed, and the horse was allowed to lie down, precautions being taken against its rubbing the parts.

On December 23rd the horse was sent home. The catheter could be readily passed, and there was no evidence of stricture. In six weeks hardly any scar could be seen. There was afterwards no sign of difficulty in urination.

The calculus was very rough on the surface, measured seven eighths of an inch in length, three quarters of an inch in breadth, and five eighths of an inch in thickness.

Mr. E. C. Russell's case, *Veterinarian*, 1895, p. 458.

NYMPHOMANIA—OVARIOTOMY.

In the mare the mortality from ovariotomy has been considerably reduced by asepsis, and by such simplification of the operative technique as I described in 1888. Of fifty-six mares which I castrated between 1888 and 1889 only one died. This animal struggled very violently when the vagina was punctured, and the external iliac artery was opened near its origin by the blade of the knife. Of the others, some showed signs of abdominal pain for a few days, but the majority exhibited very trifling post-operative symptoms. These results confirm what I stated as to the tolerance of the peritoneum when speaking of castration of cryptorchid horses. Under the ordinary conditions of veterinary practice absolute asepsis is a myth. Whatever the precautions observed in performing ovariotomy the peritoneum is always infected; but, like all other tissues, it is able to destroy the germs, provided they be not too numerous or too virulent.

Of the seven mares which I castrated during the years 1897 and 1898 one showed signs of colic, lasting for forty-eight hours. Three of these mares, which belonged to the General Omnibus Company of Paris, were sent to the Alfort depôt and operated on in the School. M. Mouilleron gave me their after-history. One still remained excitable, came on frequently in season, and had to be drafted. The others were returned to work at the end of a fortnight, and have not since shown any sign of nymphomania.

126. Eighteen-month-old female cat, left in hospital 11th June, 1898.

Œstrum occurred very frequently, and for long periods. The owner, Dr. B—, asked us to perform castration.

On the 17th June the ovaries were removed by M. Almy. Chloroform was administered by placing the cat under a bell-jar. When anæsthetised the animal was fixed in the dorsal position on the table.

The middle line of the abdomen having been shaved and disinfected, a longitudinal incision, one and a quarter inches in length, was made along the white line. The peritoneum was perforated with a blunt instrument. On drawing apart the lips of the wound with retractors a little firm, reddish cord—the right uterine horn—carrying at its extremity an ovary the size of a small pea, was at once seen. The latter was removed by torsion with artery forceps. The left uterine horn was in turn discovered, and the corresponding ovary removed in like fashion. The muscular and skin wounds were sutured, the cutaneous sutures covered with a layer of collodion, and a cotton-wool dressing was applied. During the night the animal took only a little milk; temperature 39·3° C. Fever continued during the ensuing three days. Temperature 39·4° C.

On the 20th the dressing and cutaneous sutures were removed. The lips of the wound were slightly swollen, had united below, and externally showed fine granulations. The parts were disinfected with tampons of cotton wool saturated with alcohol. A fresh cotton dressing was applied.

Next day the general condition and appetite were good. Temperature, morning 38·7° C., evening 39·0° C.

On the 22nd the last signs of fever disappeared. The animal left hospital on the 25th. The wound was healed.

HYSTERIA IN A MARE.

127. A nine-year-old dark brown, well-bred mare, about 15 hands high, seen April 11th, 1886.

History.—To improve the animal's condition it had been recently placed on a very liberal diet. On the 10th April it had been driven thirty-five miles.

State on Examination.—The animal was tied up short in the middle of a large stable, and appeared excessively uneasy and excitable. By stamping with the hind feet it had formed a beaten semicircular track in the straw; the feet were brought violently to the ground, the animal occasionally grabbed at the rack, and squealed like a mare when shown the stallion. It frequently stopped in the semirotary movement and stretched out as though to stale, passing an ounce or two of thick whitish urine; each micturition was followed by a very pronounced convulsive spasmodic movement of the clitoris. Small pieces of dung were also ejected. The animal kicked at its body and at neighbouring objects or persons, watching every movement, showing the white of the eye, laying the ears back and kicking most viciously. With great difficulty a twitch was applied and a side line fixed. On examining

the animal the conjunctiva was found highly injected, the pulse quick, small, and irritable; the skin tight; the muscles of the quarters hard and tense; the anus retracted into the pelvis (as it is after violent purgation); the vulva relaxed and open; the walls of the vagina tense and highly inflamed, the vessels standing out prominently like tortuous cords.

The vagina itself was a large cavity in which the hand could be easily moved to and fro, the walls appearing to be stretched to their utmost limit; when pressed on by the fingers and the pressure suddenly relaxed, a kind of elastic recoil occurred. Air constantly passed in and out of the vagina—there was, in fact, a kind of vaginal respiration.

Treatment.—A purge was given by the mouth, a dose of morphine hypodermically, and a sedative injected into the vagina.

On the 12th the purge was acting, the appetite was in abeyance, and the animal only showed occasional attacks of excitement.

On the 13th the excitement returned almost as severely as at first, but yielded after a sedative had been given.

During the ensuing five days the appetite gradually returned, the attacks diminished, and the animal recovered.

In another similar case recovery was protracted for three weeks, and the animal afterwards retained the habit of kicking, so that it was sold.

In a third case, in which the animal had been served by a stallion and three days afterwards had performed a journey of twenty miles, dulness and depression replaced the excitement seen in those above mentioned. The animal made no resistance to examination, and when moved remained standing inertly until its position was again altered. The pulse was full, regular, and forty per minute; the conjunctiva was injected, the eye glassy, amaurotic, and scarcely sensitive to light; the temperature 101° F. The condition of the anus, vulva, and vagina was identical with that above described; air passed in and out of the vagina, and urine was frequently passed in small quantities. The patient remained extremely depressed and sluggish for four days; it did not perfectly recover for a week or two. The visit to the stallion was not repeated, but the animal proved to be in foal.

Note.—Though the normal period of œstrum in the mare does not exceed three days, it lasted in Case 1 about six days, in Case 2 nearly a month. In Case 3 the sexual appetite had been gratified, and instead of excitement the animal showed an almost cataleptic condition. The writer ascribes the onset in Cases 1 and 3 to the highly stimulating diet.

Mr. G. E. King's case, *Journ. Comp. Path. and Therap.*, 1893, p. 69.

PROLAPSUS VAGINÆ IN A YOUNG MARE.

128. A two and a half year old Clydesdale mare, sixteen hands high, seen on August 20th, 1897.

History.—In the autumn of 1896 had been cast in the stable, as a result of which the owner thought the animal had injured itself. During the summer of 1897, while the mare was at grass, the vagina

had several times appeared prominent, but had not become everted until the above date in August, 1897.

State on Examination.—The vagina was completely prolapsed, much congested, and covered with blood. The animal was in thin condition, and the coat was staring. Temperature 102° F. Appetite good.

Treatment.—The animal was placed in a stall and the hind extremities elevated by a bank of turf. The vagina was cleansed with warm 1 in 300 creolin solution.

On rectal examination a distinct bony ridge could be felt running along the pelvic symphysis, its height being about half an inch.

An attempt was made to return the parts. Very little resistance was offered until after the vagina was adjusted, when straining became so violent that it was impossible to retain the organ in position by aid of the hand and arm. A hypodermic injection of morphia was given with no better effect.

The parts were therefore left *in statu quo* and bathed three times a day with warm creolin solution, for an hour at a time. The tail was tied to one side, to prevent it injuring or soiling the vagina. A ball containing six drachms of Alöes Barb. was given, and powders containing each—

Rad. Gent. Pulv.	ʒij,
Sodæ Hyposulph.	℥iss,

were also left to be given twice daily in a bran mash or soft food. The mare received laxative diet, like cut grass, etc.

On the third day the organ returned to its normal position spontaneously, and to all appearances the mare had perfectly recovered. A tonic powder containing—

Rad. Gent. Pulv.	ʒij,
Nux vomica	ʒj,

was given daily, and strict injunctions were given that should the animal be seen in season, or the prolapse show the slightest reappearance, the patient was to be brought in and placed in the stall.

On September 8th it was found in the same condition as on the first visit. The mare had come in season, and the horses in the same field had no doubt caused straining by their excessive teasing.

The same treatment as on the first occasion was repeated, but failed. On the sixth day the warm water bathing was changed to cold. The organ was bathed three times a day for an hour each time with cold water, an ounce of alum being added to three gallons of water. The water was allowed to fall from a sponge upon the vagina. After each bathing the parts were dressed with a lotion composed of—

Boracic acid	℥ss,
Tinct. Opii	℥ij,
Aqua	ad ℥xij.

The cold water treatment was continued for two days, when the mare began to show symptoms of distress. The anus became relaxed, and on the mare straining, which occurred frequently, the rectum came down to its full extent, but returned when the straining ceased.

In consultation it was agreed that as the organ was still much congested, and not returnable on that account, and great resistance was still offered by the mare, a vertical incision should be made on the lowest point of the inverted organ through the mucous membrane and muscular coats, leaving the serous coat intact to prevent protrusion of the intestines. This incision caused the parts to diminish in size on account of the hæmorrhage that ensued. The region was bathed

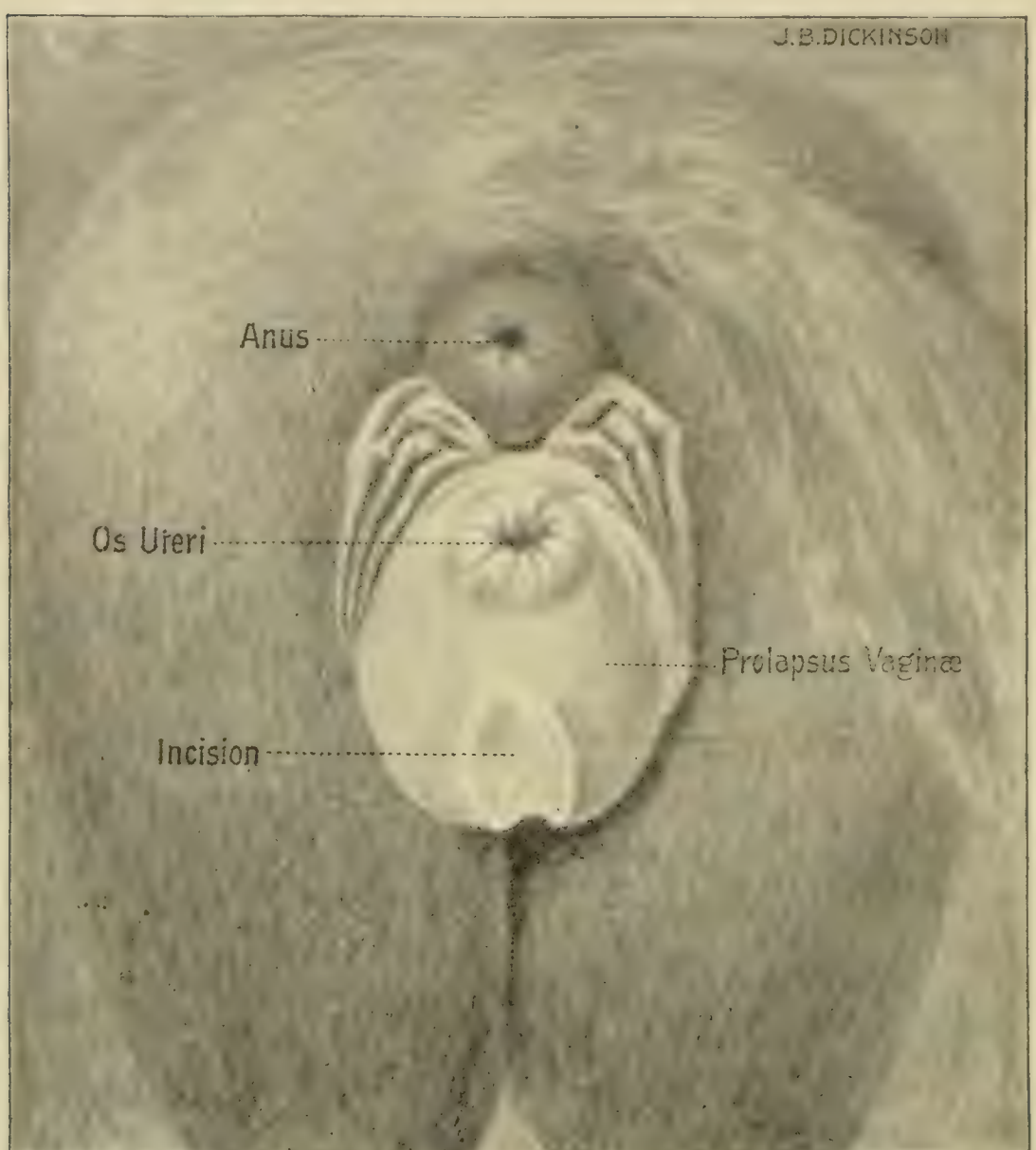

Fig. 47.

for a few minutes with warm water containing a little alum, and then painted with Tinct. Benzoin. Co.; the treatment was repeated twice daily.

As considerable œdema had developed between the fore-legs in consequence of standing high on the hind extremities, the mare was

removed to a loose box at night, and turned out alone in a pasture field during the day. It received a powder containing—

Chloral hydrate	℥ss,
Nux vom.	ʒj,

given in soft food twice a day.

This treatment was continued from the 16th of September to the 8th of October, by which time the operation wound had healed. The prolapse had considerably diminished, and the mare had greatly improved in condition. Occasionally, however, the rectum came down.

The vagina was now adjusted without much difficulty, and without much resistance being offered. One of West's prolapsus clamps was placed on the lips of the vulva. The clamp answered its purpose very well. The rectum never again appeared. The mare now received—

Chloral hydrate	℥ss,
Nux vomica	ʒj,

twice every alternate day for a week, and was placed on dry food. A week after the clamp was placed in position the animal was occasionally sent out to plough for half a day, the clamp still remaining on. This course was followed for a month, when the clamp was taken off. During the ensuing five months there was no indication of any reappearance of the vagina. The mare appeared to have entirely recovered.

Mr. W. T. Hewetson's case, *Veterinarian*, 1898, p. 83.

CYSTIC DEGENERATION OF THE OVARY AND FALLOPIAN TUBE.

129. A ten-year-old Danish bitch, brought for examination on the 30th July, 1897.

Had been punctured for ascites on four occasions. On the second the liquid removed had been blood-stained.

The appetite was good, though the animal appeared emaciated. There was no cough, vomiting, or diarrhœa. On manipulating the abdomen a large swelling could be detected, apparently hanging from the lumbar vertebræ. The animal was again brought on the 17th September, when it was left to be killed.

Autopsy.—The abdominal cavity contained several quarts of reddish serosity. With the exception of the left ovary, the thoracic and abdominal viscera were healthy. This ovary was as large as a man's two fists, and showed rounded elevations and depressions of varying forms, dimensions, and consistence; the majority were soft, cystic, deeply tinted or blackish, and only covered by peritoneum. Weight twenty-four ounces.

On section the central portion of the tumour appeared formed of a greyish-white, soft, friable tissue, containing large numbers of small cysts, which readily burst under the pressure of the finger. The walls of the left Fallopian tube were much thickened and full of little closely packed cysts, projecting above the mucous membrane.

Nothing abnormal in the uterus or vagina.

On microscopic examination the tissue of the ovarian tumour seemed

formed of a connective-tissue stroma, fibrous or sarcomatous according to the point chosen, and of numerous epithelial new growths, in most cases assuming the form of little cysts, the internal surface of which was lined with polymorphic cells.

PROLAPSE OF THE UTERUS.

130. A nine-month-old sheep bitch, left in hospital on the 23rd February, 1897.

Being always at liberty in a courtyard this bitch had first come in heat a fortnight before, and been lined. The period of œstrum having passed, a tumour, the size of a fowl's egg, was seen projecting from the vulva. For a few days no notice was taken of it.

At the end of a week the animal was brought for examination. The swelling consisted of the prolapsed uterus. It was reduced, and a bandage supplied, which, however, was soon torn off, causing a recurrence of the prolapse the same night. The patient was therefore sent back on the 23rd April, 1897, and left in hospital.

Treatment.—Antiseptic bathing of the swelling, which was soiled with fæces and dust; reduction; injection of warm boric solution into the vagina and warm enemata. Ten minutes after the administration of the enema the bitch passed a large quantity of hard fæces. On account of the straining prolapsus recurred. It was reduced, the parts irrigated with warm antiseptic solution, and the vagina packed with gauze and wadding, care being taken to leave uncovered the meatus urinarius, so that micturition was not interfered with.

Next day the tampon was found in the straw, and the swelling had returned, though it was smaller. Same treatment continued. For several days following the tampons were, after an interval, rejected, but the swelling on each occasion was of less size.

On the 5th March the uterus no longer appeared externally, the prolapsus being contained in the vagina. After reduction the neck of the uterus could be clearly felt.

On the 9th the vagina was empty and the neck of the uterus closed.

131. An eighteen-month-old Danish bitch, entered hospital 27th April, 1897.

When in heat the bitch had several times previously suffered from prolapsus of the uterus, which, however, had yielded to simple reduction. This time the prolapsus was more serious. The uterus was completely inverted, and formed a reddish mass, the size of a man's two fists, projecting from the vulva. Astringent lotions, used to diminish its size, had produced no result. The animal was left in hospital.

Treatment.—Antiseptic cleansing of the swelling; reduction; injections into the vagina; plugging of the vagina with cotton wool and gauze.

Next day the tampons were still in place, and were therefore not interfered with. The patient was bright and made no straining efforts, although micturition appeared a little difficult. The dressing was re-

moved on the 29th, on April 1st, and on the 3rd of May. On the 5th May recovery was perfect.

Remarks.—Plugging of the deeper portion of the vagina, as practised in these two cases, is the best treatment for prolapsus of the uterus in the bitch. When carefully performed it is well borne, and if the pessary is rejected there is no difficulty in renewing it. Since 1896 all cases of prolapsus of the uterus have been treated in this way in our practice. We have never had to practise amputation.

MYXOMA OF THE UTERUS.

132. A ten-year-old bitch, brought for examination on the 1st February, 1892.

Two days previously a large swelling had appeared below the vulva. The last œstrum had occurred six weeks before.

A month before this bitch had been seen to make frequent straining efforts; urine was passed frequently, but in small quantities; the abdominal muscles contracted violently, and remained contracted for a certain time after emission of urine. No treatment was adopted until the 29th January, when a swelling was seen behind the labiæ, which was at first regarded as "the everted uterus containing one or more young."

The swelling was partly covered by the long hair of the tail, and on exposure appeared ovoid, smooth, of fairly firm consistence and reddish colour; its upper part was rounded; it diminished in size towards the base, which was continued by a pedicle the size of a lead pencil, issuing from the orifice of the vulva. It measured five inches in length and six in circumference. In order to determine the point of insertion, slight traction was exercised on the growth; the pedicle was fixed to the right side of the neck of the uterus, the surface of implantation being scarcely one sixth of an inch in diameter. The patient was lively, and only seemed to have a little difficulty in walking.

The tumour was excised with the knife, the base of the pedicle being ligatured with silk, and the growth divided immediately behind the ligature.

The tissue of this tumour was soft, whitish towards the centre, marbled with red towards the periphery. Dotted through it were little cavities containing a reddish liquid.

On microscopic examination it appeared formed of rounded, fusiform, or branching cells, with one or more nuclei, contained within a highly refractile, almost amorphous stroma. Its peripheral layer contained considerable numbers of vessels. It was a myxomatous tumour of the variety known as cystic myxoma.

IMPERFORATE VAGINA.

133. Four-year-old bitch, entered hospital on the 23rd June, 1898.

For the previous week this animal had been constipated, and made violent attempts to defæcate. It showed marked wasting. From between the anus and vulva a fluctuating swelling the size of a large

apple projected, and was at first regarded as a perinæal hernia. On introducing the index finger into the rectum, however, the inferior surface of the latter was found to be compressed by a kind of cyst. The patient was secured to the table and operated on by M. Almy.

On dilating the vulva we discovered about half an inch from the orifice a tensely stretched mucous partition, which projected backwards and exhibited fluctuation. At first it was regarded as the distended bladder, or a submucous cyst. On passing a rubber catheter into the bladder, however, only a little normal urine was withdrawn. The finger could not be introduced into the vagina, the above-mentioned partition closing the entrance. The swelling was punctured with a trocar, when about a pint of viscous, yellowish pus-like liquid escaped. The pocket was laid open and part of the partition removed with curved scissors. The vagina and uterus were washed out with boiled water until the liquid returned clear.

During the following days the vagina was irrigated with boric acid solution. The symptoms noted before operation rapidly disappeared, and the bitch was sent home cured on the 5th July.

AMENORRHŒA DUE TO IMPERFORATE HYMEN.

134. A "six-quarter" Ayrshire quey in fat condition, first seen 11th September, 1894.

History.—Had been straining at intervals for five days, the pains daily becoming worse. A dose of physic had given no relief.

State on Examination.—Appetite lost; head depressed, face anxious; the animal strained almost constantly and groaned loudly at intervals. During the more severe pains about two inches of the rectum in a bleeding state were protruded. Skin clammy; ears and horns alternately hot and cold. Temperature 104·5° F.; pulse 115, rather weak. Rectal examination revealed the presence of a large ovoid painful swelling almost filling the pelvic cavity. On exploring the vagina the hymen was found to be imperforate and impossible to rupture by manual exertion.

Treatment.—After administration of a full dose of chloral the hymen was punctured with an embryotomy knife, and broken down throughout by the fingers. Four pints of putrid steel-grey fluid containing whitish and reddish flocculi were ejected. After washing out the vagina with a weak tepid solution of Jeyes' fluid, the os was found to be apparently normal. Stimulating liniment was applied to the croup, and chlorodyne given internally to check further straining. Pains entirely ceased twelve hours after operation, and on September 13th the quey was doing well.

Mr. H. Begg's case, *Veterinarian*, 1894, p. 757.

EPITHELIOMA OF THE VULVA.

135. An aged cow.

History.—The tumour had been noticed eight months previous to the photograph being taken; it was then the size of a mandarin orange. It grew rapidly and caused the animal much inconvenience, as shown

by the continual switching of the tail. The owner partially removed it, but it then grew even more rapidly than before. Operation was first proposed, but was afterwards abandoned owing to the extent to which the vagina was involved.

State on Examination.—The surface of the growth was raw and

FIG. 48.—Cow with malignant epithelioma, showing anus and vulva affected.

bleeding, and extended on each side of the vulva for three to four inches, completely surrounding the labia with the exception of the lower commissure, while the inferior segment of the anus was also

implicated. There were no remains of healthy skin on the tumour with the exception of the external borders, where it was being raised by the extension of the new growth underneath. The wall of the vagina for from six inches to eight inches from the posterior extremity was affected, the mucous membrane being ulcerated. The animal was slaughtered.

On *post-mortem* many of the lymphatic glands of the abdomen, especially the pelvic and the posterior mesenteric, were found to be affected with small nodules, consisting of greyish-looking material of soft consistency. The lungs were tubercular, and the liver contained a few tuberculous nodules.

Microscopical examination afterwards demonstrated conclusively that this tumour was epitheliomatous, and also that secondary infection of the lymphatic glands had taken place. The fact that the animal was also tubercular is of interest on account of the extreme rarity of the occurrence of the two conditions in the one animal.

Mr. J. A. Gilruth's case, *Veterinarian*, 1900, p. 294.

RUPTURE OF THE PERINÆUM—OPERATION.

136. A seven-year-old thoroughbred mare, entered hospital 19th October, 1897, suffering from rupture of the perinæum, consequent on difficult labour.

The wound extended from the superior commissure of the vulva as high as the anus, without, however, affecting the sphincter ani. It had been allowed to heal without surgical interference. When the mare came in season she was covered, but unsuccessfully, the failure being attributed to the rupture. The parts were sutured by a veterinary surgeon. Adhesive union was not obtained, and some months later the mare was sent to Alfort.

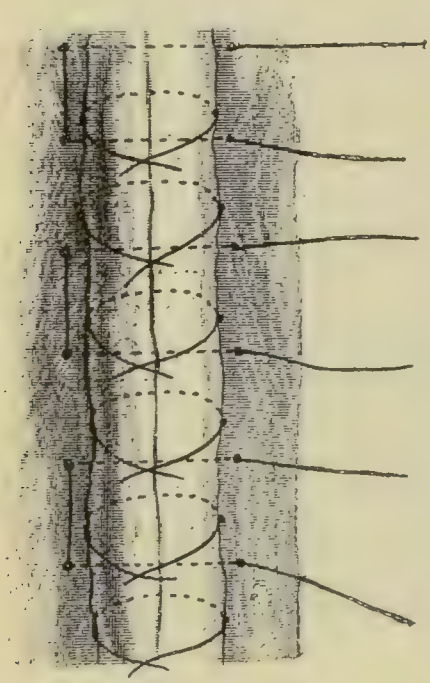

Fig. 49.

State on Examination.—General health good. The perinæal rupture, which ran obliquely upwards and towards the right, started from the superior commissure of the vulva, and terminated beneath the sphincter ani. The margins were fibrous, irregular and contracted, and showed a large opening, through which a portion of the fæces escaped, causing continual irritation of the vagina.

Treatment.—Until the 26th October the mare was prepared by injections of warm boric, or one per cent. creolin solution repeated twice daily, and internal administration of three ounces of sodium sulphate daily in the drinking-water. During the last two days the animal was placed on very low diet. On the 27th it was cast on the right side by means of the table. After evacuating the rectum the operative wound was washed with soap and water and carefully disinfected.

The cutaneous and mucous integuments were separated with a bistoury throughout the entire length of the tear for a width of half an inch. Hæmorrhage having ceased, the weeping surfaces were freed of the small clots which covered them and thoroughly dried. They were then united by a double suture, which, although passing through the skin alone, produced accurate coaptation of the internal surfaces (see figure). The first series of sutures consisted of thick silk inserted in the form of loops, the ends of which were separated and emerged about three eighths of an inch from the cutaneous margins of the wound. The second series consisted of ordinary interrupted sutures of fine silk. The object of this second series was to bring the margins of the integument into accurate contact. The vaginal wound was dusted with iodoform; the cutaneous wound touched with carbolic solution, powdered with iodoform, and covered with a strip of taffeta.

On the 28th the parts were again dressed with iodoform and a fresh strip of taffeta. During the following days this treatment was continued. There was no suppuration.

On the 3rd November the sutures were removed; union was complete except in the upper part of the wound, where several of the deep sutures had torn away. As a precaution dressing with iodoform and taffeta was continued for several days afterwards. On the 24th the animal was cast and the upper margins of the wound were again operated on. The preparation and dressing were similar to those in the first instance.

On the 25th the taffeta had become loose, and was replaced by iodoform collodion applied night and morning until the 30th. Union was obtained without suppuration. The sutures were removed on the 1st December. The animal left hospital on the 6th December.

CANCER OF THE TAIL—GENERALISATION AFTER ABLATION.

137. A nine-year-old bay-brown gelding, suffering from tumours of the tail, left in hospital on the 11th May, 1896, for removal of the new growths.

The lower surface of the tail, a hand's breadth from its base, showed two sessile growths as large as a walnut, with firm, reddish, excoriated surfaces; a little in advance, but also on the inferior surface, was another growth, the size of a hazel nut, and behind were three growths the size of a pea, around which the skin was thickened. The tail was swollen. These tumours interfered with the application of the crupper, and were often injured by it.

Ablation was performed in the standing position, the hind limbs alone being hobbled. The growths were removed level with the skin by a single stroke of the knife. The cut surface was curetted, and afterwards touched with the thermo-cautery. In excising one of the two larger tumours the animal struggled violently, and the entire thickness of the skin was divided for a distance of one and a half inches; hæmorrhage was checked with the hot iron.

The parts were covered with a cotton-wool dressing, renewed every five days for a period of a fortnight, the wounds being dressed with 30

per cent. solution of iodine tincture. On the eschars separating, the wounds appeared healthy and covered with fine granulations. The horse was returned to work.

The wounds did not completely heal, and the granulations soon projected more than three eighths of an inch above the level of the skin. Gradually the tail became swollen, its base doubling in size in six weeks; the swelling extended to the upper part of the croup, in which region numerous subcutaneous tumours developed. The animal showed symptoms indicating generalisation of the new growth, gradually fell away in condition, and had to be slaughtered.

Autopsy.—The tail was of enormous size, asymmetrical at its base, the left half being larger than the right. On the left side, a hand's breadth from the anus, was a large mammillated patch, from which the hair had fallen, formed by the confluence of several tumours; it extended to both the upper and lower surfaces of the tail. Several small tumours were included within its area. The base of the tail was everywhere invaded; the skin and connective tissue being very markedly thickened. The muscles were whitish, hard, and sclerosed.

In the subcutaneous connective tissue of the croup and upper part of the quarters, numerous rounded, slightly flattened, tumours were found, the largest the size of a two-shilling piece. Most of the muscles in these regions were hardened or destroyed by the new growths. The spleen was enlarged and bosselated on both surfaces, in consequence of the growth of yellowish-white tumours, varying in size between a hazel-nut and a man's fist; the centres of some of these tumours were slightly depressed. The liver was hypertrophied, and contained many small tumours, resembling those above described. The surface of the lungs showed numerous whitish nodules, and sections displayed a dozen tumours as large as a man's fist.

On microscopic examination the tumours in the tail, muscles, and viscera showed the characters of encephaloid cancer. Their tissue consisted of a stroma arranged in tracts, surrounding spaces filled with epithelial cells. Blood-vessels were numerous. Sections of the tumours from the tail showed in places hæmorrhagic centres.

Remark.—The inflammation caused by excision and cauterisation had provoked rapid diffusion of the new growths.

V.—THE LIMBS.

OSSIFYING PERIOSTEAL SARCOMA OF THE SHOULDER—GENERALISATION.

138. A six-year-old Danish bitch entered hospital 11th June, 1898, suffering from a tumour of the shoulder, which had developed without apparent cause in less than two months.

The patient was extremely depressed, and remained lying on the right side, apparently in acute pain; at certain times the respiration was moaning. As the animal could not be moved it was brought to the school in a carriage.

State on Examination.—The entire left shoulder was greatly swollen.

Opposite the cervical angle of the scapula traces of firing were visible. The tumour formed a compact, lobulated, hard mass, not painful on manipulation, extending from the central portion of the neck to the middle of the thorax; above it projected beyond the shoulder; below beyond the line of the sternum. Having developed beneath the scapula, which it had thrust outwards, it appeared to be adherent to the neck and trunk. The skin covering it was moveable. The physical characters were those of a sarcoma.

In order to confirm the diagnosis two exploratory punctures were made into the tumour with a trocar, after disinfection of the skin. From the first puncture, which was made in the upper lobe, no liquid escaped; the point of the trocar passed through friable, osseous tissue, producing crepitation. A second puncture, made into the inferior lobe, below the elbow, gave exit to a little blood-stained liquid.

Successful treatment was impossible. The patient was killed by intra-venous injection of chloral.

Autopsy.—The upper portion of the tumour was situated beneath the shoulder. The lower half of the scapula was intact, but the upper was infiltrated by new growth. Detached from adjacent tissues, the tumour appeared covered over the greater portion of its surface by a thin fibrous capsule. It measured eighteen and a half inches from before backwards, seventeen inches from above downwards, was four and three quarter inches in thickness, and weighed nearly fourteen pounds. Sections showed numerous interstitial hæmorrhages, particularly in the central part and bony trabeculæ. In the spaces surrounded by these trabeculæ the tissue was soft, friable, greyish at certain points, rose-red or reddish at others, but everywhere very vascular. The trabeculæ were numerous near the bone, but became

rarer towards the surface; they sprang from the inner aspect of the upper third of the scapula, the point of origin of the tumour. The neighbouring muscles, the ribs, vertebræ, and cervical ligament were not invaded. The connective tissue between the subscapular and large serratus muscles contained some secondary tumours.

The superficial layers of both pulmonary lobes were dotted with nodules, varying in size between a pin's head and a walnut, some blackish and hæmorrhagic, others greyish-white, the majority hard and like the primary tumour, containing bone elements. Sections showed many new growths scattered through the two lobes. The mitral and tricuspid valves were irregularly thickened by little whitish, very hard nodules.

Nothing abnormal was discovered in the abdominal organs.

On microscopic examination the primary and secondary tumours were seen to be formed of polymorphic cells, though round, uni-, or multi-nuclear cells preponderated. At certain points an intermediary fibrillated substance and tracts of osteoid tissue could be detected.

TOTAL NECROSIS OF THE SCAPULA.

139. A five-year-old cart gelding, sixteen hands high, in good condition.

History.—Had gone lame a fortnight before examination.

State on Examination.—Was slightly lame in the near shoulder. The shoulder was bathed with hot water for half an hour three times daily, and a lotion containing belladonna, arnica, and rectified spirit afterwards applied.

The patient remained in much the same condition for about three weeks, when it suddenly became very lame, dragging its leg behind it in a helpless fashion when made to walk, and evincing the greatest difficulty in passing over the threshold of the stable door, apparently being quite unable to advance the toe of the foot. The same treatment was continued for three or four weeks, at the end of which the swelling pointed and burst, the opening resembling a small punctured wound about half an inch in length. By probing, the scapula could be felt, and a number of sinuses detected burrowing in all directions and filled with pus, which gave off a most offensive odour. The wound was enlarged by an incision about four inches in length above and along the vertebral edge of the scapula. The wound was thoroughly syringed out three times a day with the following:

Zinci Chlor.	℥j.
Aqua pura	℥xij.

At the end of six weeks, as the case showed little signs of improvement, the wound was opened sufficiently to allow the hand to be inserted behind the bone; on manipulation the superior portion of the scapula could be distinctly made to move backwards and forwards, giving the impression of the superior third of the bone being broken off from the inferior two thirds. The antiseptic treatment was continued. Abscesses now began to form and discharge on the muscles of the

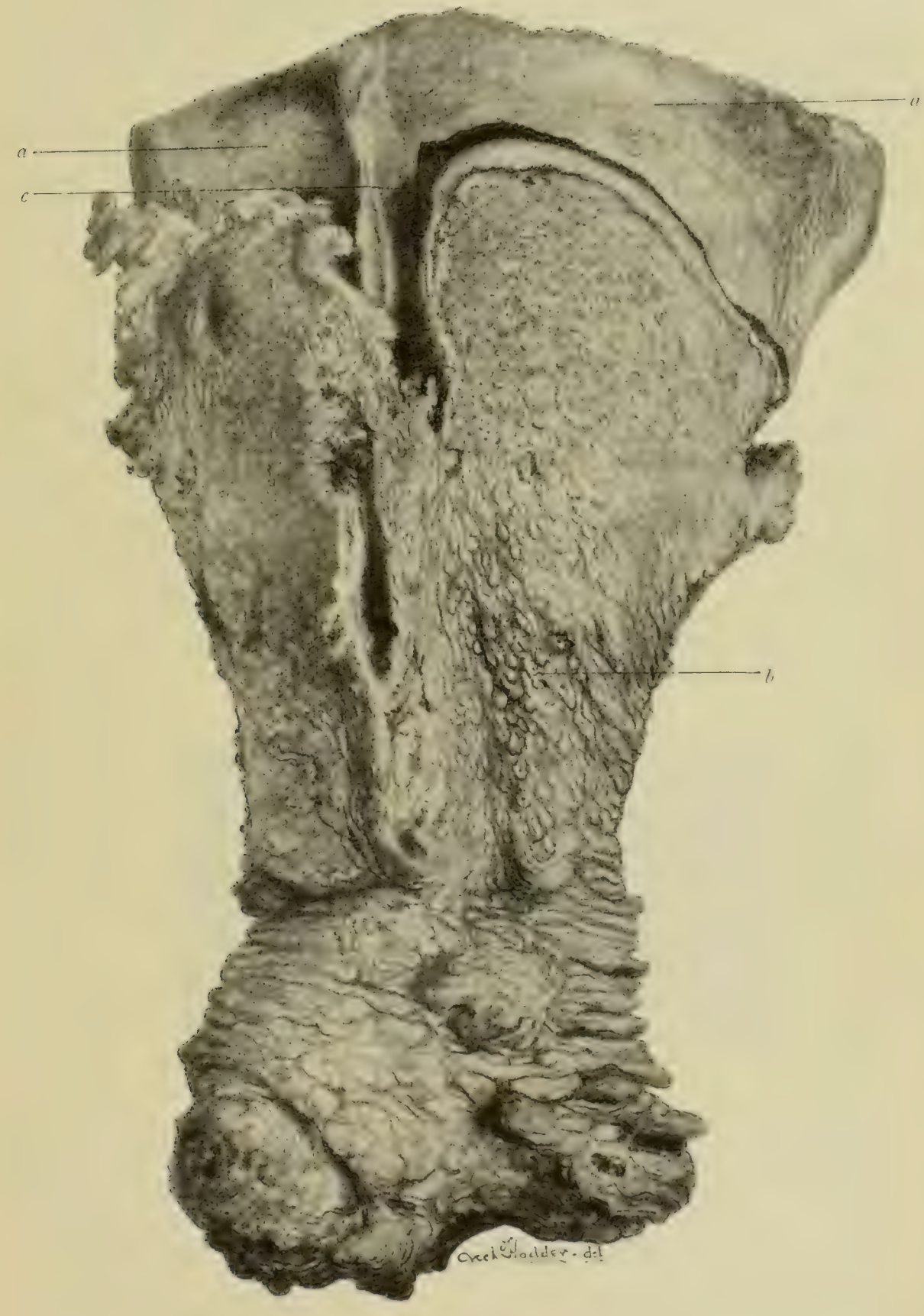

FIG. 50.—*a*. Sequestrum or dead mass. *b*. Case of bone formed by the periosteum. *c*. Space filled with pus in wet specimen.

chest. These were opened, and dressed with a 1 in 1000 solution of Hydrarg. Perchlor. The animal remained in much the same condition for the next few weeks, with the exception that its general health, which had previously been excellent, was not quite so good. As, however, signs of pyæmia began to manifest themselves, the case was considered hopeless, and the animal was destroyed. The injury was proved to be the result of a kick.

Post-mortem Appearances.—On dissecting out the scapula the bone was found to be surrounded by large quantities of very offensive pus. It appeared much larger than normal, and was encased in a sheath of bony matter, the superior third being comparable to a dagger, the inferior two thirds to the sheath. After boiling, the specimen was found to be totally necrosed, the bone forming a sequestrum, with a space filled with pus between it and the large mass of new bony tissue.

Mr. A. Hodder's case, *Veterinarian*, 1896, p. 589.

DISEASE OF THE SCAPULO-HUMERAL ARTICULATION—NECROSIS OF THE ARTICULAR CARTILAGES.

140. Clydesdale gelding, rising four years old.

History.—Was broken to harness in June, 1897, and a month later fell lame. The condition was diagnosed as "shoulder-slip" of the right shoulder, the parts were blistered, and the animal rested. No improvement occurred. Somewhat later abscesses formed in the scapular region; the first, at the dorsal angle of the scapula, burst and discharged a large amount of pus. (There were no symptoms of strangles.)



Fig. 51.

Another formed behind the shoulder-joint, burst and discharged, healed up, and again broke. Extremely severe typical shoulder-lameness persisted. The entire shoulder region was diffusely swollen and enlarged, and there was no perceptible atrophy of the shoulder muscles. The animal was blistered and turned out to grass, but without improvement. As recovery seemed very doubtful the animal was killed.

Post-mortem Examination.—The subcutaneous fascia was found to be much thickened, dense, and sclerosed. The muscles covering the dorsum of the scapula were almost entirely fibrous throughout their

extent. The tendon of origin of the biceps where it plays over the bicipital groove of the humerus showed signs of inflammation, and was discoloured upon the serous surface of the tendon, due doubtless to extravasation of blood of long standing. The muscles in the immediate neighbourhood of the articulation contained numerous small abscesses, the pus being thick and partially inspissated. The most interesting lesions, however, were found upon the articular surfaces of the scapula and humerus. The articular cartilage of the glenoid cavity of the former was eroded to an extraordinary degree, the lines of erosion being broad and deep, and coloured deep red. In one place the removal of cartilage and bone had progressed so far as to produce a canal leading from the joint cavity into the cancellated tissue of the scapula. Upon the head of the humerus necrosis was also to be seen, but not to the same extent as upon the scapula; but here also two perforations passed through both articular cartilage and bone into the cancellated tissue of the head. So far as could be ascertained from the pieces of scapula and humerus submitted, there were no abscesses in the bone. In connection with the scapula a new deposit of bone had occurred just above the glenoid rim, this being enveloped for two thirds of its circumference by newly formed bone of a spongy character, and somewhat of the nature of a callus. (This may have been the first indication of an ultimate synarthrosis.)

Prof. Mettam's case, *Veterinarian*, 1898, p. 305.

INJURY OF THE FLEXOR BRACHII MUSCLE.

141. A nine-year-old chestnut mare, 15.2 hands high.

History.—Had been fired over the flexor tendons of both fore-legs, and turned out to grass. One morning the animal was seen "hopping" about the field on three legs, showing excessive lameness of the near fore, on which no weight could be borne. This limb was pendulous, and the hind limbs were brought far under the body as shown in the figure. It was afterwards learned that the animal, when being brought from the field into a straw-yard with others, had to pass through a narrow gateway, against the post of which it might have been violently thrust.

State on Examination.—There was no local heat, pain, or swelling, but as the case appeared to have existed for some time, and such symptoms might have disappeared, a stimulating application was made to the muscles of the shoulder and to the shoulder-joint. Little benefit resulted. A smart cantharides blister was then applied. The limb continued to contract, the muscles of the shoulder to atrophy, and the spine of the scapula to appear more prominent. As the animal seemed to be steadily growing worse, it was shot eight weeks after being first seen.

Post-mortem Examination.—On removing the affected limb from the trunk the muscles of the shoulder were found to be much atrophied, and those on the inner aspect of the limb and corresponding outer aspect of the chest wall bore large emphysematous patches. No sign of fracture of any of the ribs could be detected. An extravasation five

inches in diameter was observable opposite the internal surface of the fourth rib of the right side. The lungs appeared healthy, with the exception of some signs of hæmorrhagic infarction about their root. The pericardium was distended, and upon making an incision was

FIG. 52.—Inflammation of the bursa of the biceps, flexor brachii, or coraco-radialis muscle, with pericarditis and hypertrophy of the heart. The near fore-limb is slightly flexed and swung behind the off fore-limb. The muscles of the shoulder are atrophied, and the horn of the toe is worn away.

found to contain a quantity of inflammatory fluid. On removing the heart and washing out the chambers it was placed on the scales, and weighed 10½ lbs.

Mr. A. Hodder's case, *Veterinarian*, 1897, p. 147.

FRACTURE OF THE HUMERUS IN A HORSE.

142. A nine-year-old harness mare, 14.2 hands high.

History.—Had run away while attached to a gig, come in violent contact with a wall, and fallen on the left shoulder. On regaining its feet the animal was very lame.

State on Examination.—The animal stood on three legs; the affected limb was flexed from the knee downwards, and hung pendulous. Crepitation could be detected over the region of the humerus. The leg could readily be drawn far outwards from the surface of the body, and when released swung inertly back. The animal did not appear in excessive pain, and remained perfectly quiet; respiration was not accelerated.

Diagnosis.—Fracture of the humerus.

The animal was killed.

Autopsy (made immediately after death).—The muscles surrounding the humerus were much bruised and infiltrated with blood; the bone



FIG. 53.

itself had sustained a comminuted fracture, and was broken into seven pieces.

Mr. A. Hodder's case, *Veterinarian*, 1898, p. 240.

PENETRATING WOUND OF THE ELBOW.

143. An eight-year-old gelding, entered hospital March 29th, 1898.

While drawing a cart on the previous evening, the horse had fallen from a height of twenty-two feet into a barge in the Seine. The left shaft of the vehicle broke off obliquely, the sharp end penetrating between the olecranon and thorax, passing through the subscapular region, and emerging in front, near the point of the shoulder. It was at once removed.

Condition on Entry.—Just inside the point of the left shoulder was a large irregular wound about twelve inches long, extending obliquely downwards and inwards, the lower part only affecting the skin and connective tissue, the upper part traversing the fibres of the mastoido-humeralis muscle; the caput muscles were hardly affected. At the lower angle of this first wound was a deep *cul-de-sac* filled with coagulated blood. The wound traversed the connective tissue in the axillary space, the superficial pectoral muscle (in the direction of its fibres) and ended over the upper part of the inner surface of the fore-arm. At this point was a straight wound, oblique like the first, about eight inches in length and distant about two inches from the fold of skin under the elbow, to which it was parallel; the lips of this wound were in contact when weight was placed on the limb, but gaped when the leg was rested. No important vessels were injured.

The upper parts of the limb, from the knee to the withers, showed a diffuse, insensitive, crepitating swelling, due to subcutaneous emphysema.

Movement was slightly impeded, but weight was readily placed on the limb.

The animal also had a large wound in the sheath, and a number of contusions, none of which, however, were of much gravity.

Treatment.—The parts were disinfected, and the lower angle of the shoulder wound was laid open, to prevent discharge accumulating in the above-mentioned *cul-de-sac*. Drains were inserted and warm antiseptic solutions freely employed. An injection of antitetanic serum was given.

On the following days the wound suppurated, but its walls gradually became covered with granulations.

Drainage was continued until the 20th April. At that date the wound near the elbow was half healed and reduced to five inches in length. The shoulder wound also filled up rapidly, though the external lip was strongly drawn inwards in the direction of the tract by cicatricial contraction. To remedy this the skin covering the outer surface of the wound was dissected free for a sufficient distance to allow of its being brought into contact with the inner lip, to which it was united by a few silk sutures.

On the 23rd April the central part of the tract had filled up. The animal left hospital on the 16th May. Healing was almost complete. There was no lameness, or interference with movement.

FOREIGN BODY IN THE KNEE.

144. A four-year-old Gordon setter, entered hospital February 7th, 1899.

Had suffered since the commencement of December from lameness, the cause of which could not be traced. One morning the animal was seen to be going lame on the left front leg and showed a small circular wound on the knee. It was thought to have been injured by a fragment of glass from one of the forcing-houses of a market-gardener, who lived in the neighbourhood. No importance was attached to the accident. In spite of the use of various topical applications and dressings, the lameness persisted and grew more marked, the knee gradually becoming swollen and painful. The dog was finally brought to Alfort two months after the accident.

State on Examination.—The animal walked on three legs. The left fore-limb was flexed, and no weight could be borne on it. The knee, the lower part of the forearm, and upper part of the metacarpus were swollen, the posterior aspect of the knee especially being greatly enlarged. The parts were so extremely sensitive that the animal howled when they were lightly touched, or when an attempt was made to extend the metacarpus on the forearm. There was trifling traumatic fever. Temperature 38·9° C.

After clipping the hair from the swollen region a circular wound, and two narrow sinuous openings, from which blood-stained pus escaped, were discovered, opposite the centre of the knee; one was situated on the external surface, near the flexure of the joint; the other at the anterior part of the external surface.

These symptoms and the long-standing character of the disease, led us to suspect necrosis of bone or tendon, or the presence of a

foreign body. In order to settle the point the patient was fastened to the table, and both sinuses vertically exposed. Exploration revealed no foreign body, or necrosis. The wounds were cleansed with dilute tincture of iodine, and an iodoform cotton-wool dressing applied. During the day the temperature rose to 39·4° C. The dog refused food, and was therefore fed on milk. The dressing was renewed every day until the 11th.

On the 8th and 9th the condition remained stationary. The animal refused part of its food. It always showed acute pain on manipulation of the knee.

On the 10th and 11th signs of improvement were noted. The animal seemed brighter, ate with better appetite, and the knee was slightly less sensitive.

On the 12th the dog was much brighter, left its kennel, and stood on the injured limb. On removing the dressing, the end of a fragment of rubber band was seen in the wound on the external aspect of the knee (Fig. 54). After extraction with forceps it was found to measure three and a half inches in length, one twelfth of an inch in width, and about one thirtieth of an inch in thickness.

The wounds were irrigated with carbolic solution, and a cotton-wool dressing applied. During the following days swelling and pain rapidly diminished, and the limb was much more freely used.

At the end of a week the wounds had healed and the dog returned home, though still slightly lame.

Remark.—This elastic band had divided the skin, which healed over it, and in consequence of its length and relaxed condition had remained for two months in the tissues of the knee without producing grave lesions. It had been divided when the sinuses were exposed. Although the limb was very little used, sufficient movement had occurred to displace the fragments, and cause one of the ends to appear in the wound.

Fig. 54.

SUPPURATING SYNOVITIS OF THE CARPAL SHEATH.

145. A ten-year-old gelding, entered hospital December 15th, 1896.

During August this horse had fallen lame on the near fore-leg. A veterinary surgeon who was consulted first applied a blister, and a month later fired the knee in points. Two months after the last operation the horse was returned to light work. It worked for about a fortnight, when the lameness returned and increased in intensity, the knee meanwhile becoming swollen.

Three weeks before entering hospital an abscess had been opened at the upper part of the knee, between the posterior and external surfaces; after-treatment had consisted in lotions and antiseptic injections. As the condition became aggravated the horse was sent to Alfort.

State on Examination.—No weight was placed on the near fore-limb. When walking the knee was not flexed, and the toe was dragged along the ground. The knee showed great swelling, extending about four inches in an upward direction, and downwards as far as the centre of the canon-bone. The upper part of the external surface exhibited a sinuous wound; on the internal surface of the limb the upper cul-de-sac of the carpal sheath was tense and fluctuating. Pressure at this point and over the lower portion of the sheath produced a considerable discharge of purulent synovia.

The horse lay down on the right side almost as soon as it entered its box, and groaned frequently. Temperature 39·0° C. It was placed in slings. The wound was disinfected, and the tendon sheath irrigated with one per thousand sublimate solution. This treatment was continued for three days.

On the 19th the horse was cast on the right side. Over the lower cul-de-sac of the carpal sheath a counter-opening was made on the external surface of the limb, and a fragment of gauze introduced to serve as a drainage-tube. The upper cul-de-sac on the inner surface of the limb was punctured at its most prominent part; some purulent synovia escaped. The sheath was irrigated with warm sublimate solution. Considerable hæmorrhage followed, and was arrested by plugging. The horse was replaced in slings, and the knee irrigated with a small current of water. The evening temperature was 39·2° C.

Next day the tampon was removed, and a second drain inserted. The general condition was good, and there was little fever.

From the 22nd December to the 10th January the temperature varied between 38·5° and 39·3° C. Every three or four days the gauze drain was renewed.

On the 11th irrigation was stopped. The animal still knuckled over a little at the fetlock, but weight was freely placed on the limb. The second drainage-tube was removed.

During the following days the sheath was irrigated with one per thousand sublimate solution. Swelling gradually diminished, pus became less abundant, and the temperature fell to 38·0° C., where it remained.

On the 30th the size of the first drain was diminished.

On the 10th February drainage was altogether suspended, but antiseptic injections were continued for some days longer.

The animal left hospital on the 16th February. It was not lame at a walk, but still showed tenderness at a trot. This, however, disappeared soon after return to work.

"LUXATION" OF THE PATELLA.

146. A six-year-old bay cob mare, seen in January, 1895.

History.—The animal had worked on the previous day, and returned

home perfectly sound. Next morning it was unable to walk, or even to move over in its stall.

State on Examination.—The animal had much difficulty in backing out of its stall, and when pushed into the yard stood in the position shown in Fig. 55.

The off hind leg was extended and placed stiffly under the body, with the toe pointing somewhat outwards. The stifle and hock joints were perfectly rigid, and resisted all attempts at flexion. When the mare was walked forwards the limb gradually became upright, rotating around the toe as a fixed point, but as it neared the perpendicular the fetlock was flexed more and more, until finally it assumed the position shown in Fig. 56, the front of the hoof then forming an angle of about 15° to 20° with the ground, the metatarsus and tibia being nearly vertical, the limb as a whole inclined outwards, and the body leaning towards the near side. This seemed the critical angle; any further forward movement was followed by the leg escaping, describing a semicircular sweep, and returning to the position of Fig. 55. There was no particular distress in moving forward, though it was difficult; but movement in a backward direction was almost impossible. As the animal could not place the off hind leg any further behind it than is shown in the second of the two figures, movement in this direction was accomplished by crouching down nearly on to the hocks, rotating the body on the near hind leg, thus dragging back the off hind, then rising, taking weight on the off hind, and retiring the near hind. The same process was repeated at each step.

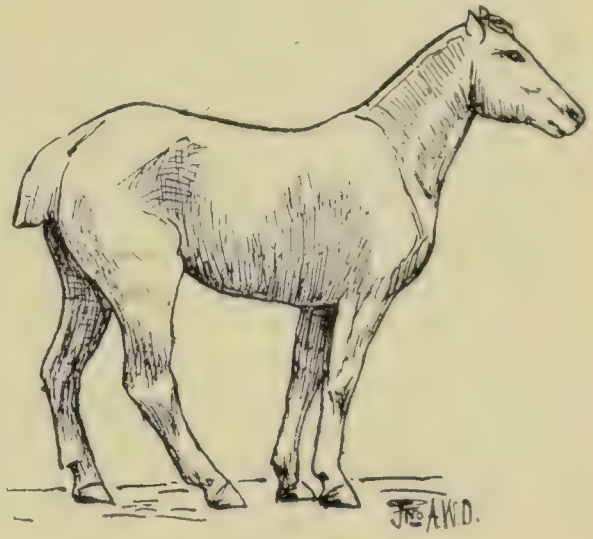

Fig. 55.

The peculiar rigidity of the limb at once suggested luxation of the patella, and by thrusting the bone inwards and downwards the writer succeeded in reducing the condition, replacement occurring with a sudden click and spasmodic flexion of the limb similar to that in stringhalt. The animal could then walk forwards in a straight line or move backwards without difficulty, but immediately it essayed to turn the patella again became displaced, and had to be assisted into position. In all the dislocation was reduced five times on the first day. It was difficult to distinguish any marked difference in the shape of the two stifles, though the displaced patella formed a somewhat more prominent mark on the outer aspect of the stifle, and was rather higher in position than usual.

The patient was placed in slings, the leg drawn forward and fixed to the girth, and the luxation finally reduced.

The animal soon slipped out of the slings, and when returned hung with its whole weight in them, so that it had to be released.

Next day there was considerable local swelling; the patella was once more out of position, and could not be replaced. Manipulation gave great pain, and at last caused the animal, which had crouched down on its hocks, to make a sudden movement and fall over. Just at this moment the patella suddenly slipped from under the pressure of the operator's thumbs, a loud sound was heard, and the horse scrambled up, once more able to freely use the limb. It was immediately taken back to its stall, placed on a deep bed of straw, and left to itself, the only precaution taken being to wedge it up on either side with trusses of straw so as to prevent its lying down or moving about much. Five days later a blister was applied round the stifle to limit the movement of the parts, and in a month the animal was returned to work. It afterwards worked hard in a hansom cab, and appeared to have suffered no ill effects from its accident.

Note by Mr. Dollar.—The peculiar features of this case appear to have been, firstly and principally, the position taken up when at rest; secondly, the rather advanced age at which the accident occurred; and lastly, the rapidity and completeness of recovery.

To sum up the results of our investigation in so far as they tend to answer the three questions propounded at the commencement of this article, I think we may safely conclude—(1) that the patella in by far the greater number of instances is not truly displaced, but only abnormally retained at a certain point of its ordinary travel. Where displacement does occur, however, it is always outwards, and must be accompanied by injury to the internal lateral ligament.

(2) Such retention may be due either to failure of the nervous centres to properly co-ordinate the muscular movements necessary to release the patella when at its extreme upper point of travel, or to spasm or paralysis of certain of the muscles involved, or merely to mechanical causes interfering with their movement; or, again, it may result from excessive tension of the inner straight ligament, which slips behind the groove on the inner side of the extremity of the femur, and cannot be released.

(3) That the symptoms are not always the same, and that they often differ widely from those of the "classical" cases, as is shown by that described by Mr. Cameron, and lastly by my own.

English observers seem to concur in believing that in luxation of the patella the leg is directed backwards, that great force is required to extend it, and that all the joints, save, perhaps, the fetlock, are fixed; and most writers on the subject favour the theory of relaxation or rupture of the internal lateral ligament.

By experiments on the dead subject M. Violet (Lyons Veterinary School) has shown that the patella at its highest point of travel "rides on the larger lip of the trochlea." The stifle-joint cannot then be flexed until it quits this position, a movement which is accomplished as follows:—"The vastus internus relaxes a little, whilst at the same moment the superficial gluteus extends the femur slightly and draws back the outer side of the patella, causing it to pivot from within outwards; the external straight ligament then becomes tense whilst the inner relaxes, for the central prominence of the patella has now

glided into the depression separating the two trochlear ridges; finally, the internal ligament no longer opposing any resistance, the corresponding side of the patella rises and easily leaves the flattened surface before described.

As soon as this happens the flexors of the limb act, the superficial gluteus relaxes, the patella falls into its groove, and straightway commences its descent."

Should, however, the animal attempt to move, and the patella refuse to leave its seat, the symptoms of luxation at once appear.

In replying to the question of why luxation occurs, M. Violet regards the primary cause as probably imperfect muscular action—either cramp or paralysis. In other words, luxation is due either to (1) spasmodic contraction or cramp of the inferior fibres of the vastus internus, which may be sufficient to counteract the efforts of the superficial gluteus; or (2) paralysis, feebleness, or injury to the superficial gluteus, which interfere with, render feeble, or disorder its contraction.

To reduce the displacement, M. Violet directs pressure to be exercised backwards and inwards, whilst the horse is thrust back by an assistant.



Fig. 56.

In Germany two forms of luxation of the patella have been distinguished—(1) momentary luxation, and (2) permanent luxation. The former is attributed to abnormal flatness of the upper surface of the trochlea before alluded to, or to excessive tension of the lateral ligaments of the patella; the latter to detention of the patella on the upper margin of the internal trochlear ridge. The symptoms are similar to those already alluded to.

Möller describes a form of luxation whose symptoms are identical with those in my own case. He says, "I have lately seen a peculiar luxation of the patella upwards and outwards. The leg was extended and directed forwards, flexion was impossible, but weight could be placed on the limb. When moving the limb was carried stiffly, without movement of the hip, stifle, or hock-joint, and placed far forwards; the progress of the body then brought the limb perpendicularly below the hip-joint, but the leg could not be placed behind this point either actively or passively. Slight pressure on the outer border of the patella sufficed to return it to its position, upon which the horse could advance several steps in the ordinary way; suddenly, however, the patella again became displaced, and all the symptoms returned.

"A *post-mortem* examination showed the inner lateral and the inner and central straight ligaments to be diseased and elongated, allowing the lower edge of the patella to ride up over the inner lip of

the trochlea, and become fixed in that position. The upper border of the patella then inclined forwards, and the bone itself slipped outwards to the extent of nearly an inch over the outer condyle of the femur. When the patella was replaced, the above-named ligaments appeared relaxed. The continued pressure of the lower border of the patella on the femur had caused absorption of the articular cartilage, and the formation in it of a distinct depression which corresponded to the shape of the under surface of the patella.

"Efforts were made during life to fix the patella in position by means of a dressing, but had to be given up on account of its causing inflammation and necrosis. A broad strap was therefore passed round both stifles and fastened to the slings.

"A splint was so applied to the tibia as to exercise pressure on the outer surface of the patella, but proved unsatisfactory, though after eight days of this treatment the horse could stand and even walk some steps without assistance. Previously it had been unable to make a single step. The experiment was unfortunately cut short by the animal succumbing to another disease."

Mr. Jno. A. W. Dollar's case, *Veterinarian*, 1895, p. 248.

OSSIFICATION OF THE TENDON OF THE SEMI-TENDINOSUS MUSCLE.

147. A five-year-old pony, which for several months had been suffering from lameness of the off hind limb, entered hospital May 5th, 1893.

State on Examination.—At rest the appearance of the lame limb was in no way abnormal. On examination the middle line and inner surface of the lower portion of the buttock showed a little swelling. A bony slightly prominent patch, which previously had been overlooked, could be felt. When moving, not only did the animal show lameness but the limb was abnormally flexed, and at the moment when this spasmodic contraction occurred the tendon of the semi-tendinosus muscle appeared unusually prominent. When caused to move backwards the animal brought the foot violently to the ground, and abducted the limb.

Diagnosis.—Ossification of the fascia of the thigh, and, without doubt, of the tendon of the ischio-tibialis. The only hopeful treatment consisted in removing the bony tumour. This operation was suggested to, and accepted by, the owner.

The operation was performed with the usual antiseptic precautions. The bony patch penetrated more deeply than had been thought on clinical examination. A drain was introduced to the bottom of the wound, and fixed at the surface by a suture. The lips of the wound were brought together by interrupted silk sutures.

During the following days some sutures yielded, and the wound suppurated. It was not entirely healed until the end of a month, but after the third week the animal walked sound. On leaving hospital it was again able for work.

Seen on two subsequent occasions—the first time eight months,

and the second two years after operation—the animal failed to show the slightest irregularity in moving the limb.

The bony plate was triangular, the base being uppermost; it measured six inches in length and three in breadth; the point was embedded in the tendon of the semi-tendinosus muscle. The internal surface was concave, especially at its upper part, into which muscular fibres were inserted. The external surface was only separated from the skin by a layer of connective tissue.

Fig. 57.—Fracture of the tibia in a horse.

The cause of ossification of this character is unknown. The animal's history did not point to any injury or violent contusion of the buttock. Its age was certainly not a predisposing cause, and no abnormal ossification was detected in any other region.

Note.—M. Laquerrière describes a similar case as follows:—"In 1874 I saw at Milianah a horse which had been lame for a very long time, and which showed a subcutaneous swelling in the upper external part of the right quarter. The horse was cast and the skin incised, when I found, to my great astonishment, a plate of apparently bony tissue, measuring about five inches in height, and two to two and a half inches in breadth. Some years before the horse had been wounded with a bullet in the upper part of the quarter. In consequence of its weight this bullet had gradually descended, but in so doing had produced inflammation, afterwards followed by calcification of a portion of the fascia in the external crural region. Whatever may have been the cause, the lameness disappeared as though by enchantment as soon as the growth was removed."

FRACTURE OF THE TIBIA IN A HORSE.

148. An aged bay cart mare.

History.—Whilst being shod the near hind leg was lifted, causing the animal to fall over against a bench on its off side; it continued leaning against the bench for a few moments, but soon recovered itself; it was, however, unable to place the near hind foot to the ground. It was then led into the yard walking on three legs, and on the near leg being lifted it fell to the ground.

State on Examination.—The animal seemed in great pain; the near hind leg was slightly flexed; a punctured wound about a quarter of an inch in diameter, from which blood oozed, was noticed at the upper

inner part of the tibia. The owner declared this had been seen two days before, but that the animal had not been lame. On the day of the accident the patient had been drawing loads, one of which weighed 35 cwt. It had backed into a difficult place considering the weight behind it. Careful questioning elicited the following facts. On the day previous to death, while drawing on the level, the animal suddenly fell, but soon rose again, and seemed none the worse. The wound had been noticed a day previous to this. From the position the animal occupied in its stable it could not have been kicked by another horse. After it fell the upper part of the leg around the tibia became swollen.

Diagnosis.—Fractured tibia.

As there was very little crepitation, and the bone was not displaced, the animal was slung. A probe entered the wound for a distance of one and a half inches. The animal hung in the slings and could not stand. Below the wound the leg was insensitive to pin-pricks. After full consideration the animal was shot.

Post-mortem Examination.—On removing the skin from the leg the subcutaneous tissue for two inches above and four or five inches below the wound was seen to be much bruised; the wound extended into the medullary cavity of the tibia, which contained a quantity of dark coagulated blood; the bone was broken into ten or twelve fragments, and cracked to within about one inch of its lower articular surface.

Mr. B. P. Godfray's case, *Veterinarian*, 1894, p. 677.

SUPPURATING LYMPHANGITIS—ABSCESS FORMATION IN THE POPLITEAL LYMPHATIC GLANDS—TREATMENT BY OXYGENATED WATER (HYDROXYL).

149. A four-year-old mare left in hospital November 12th, 1896.

Had been bought ten months before. Was affected with verrucous dermatitis (grease) of both hind legs, which had been unsuccessfully treated with warm solutions of lysol.

On the 7th November, on returning from a rather long journey, the mare was seen to be distinctly lame on the near hind leg. Next day the leg was swollen as high as the hock. During the following days swelling increased, extending to the lower part of the thigh. Lameness was intense, and the disease steadily became worse in spite of treatment.

The animal was brought to the school on the evening of the 12th November. While it was being led into the ambulance an abscess in the region of the thigh broke, and discharged a considerable quantity of pus.

State on Entry.—The entire limb was swollen and very tender on examination. The foot was rested on the toe. About twelve inches above the summit of the os calcis on the posterior surface of the thigh was a wound discharging viscous, offensive pus. Around this wound was a necrotic patch of skin measuring six inches by five. Removal of the eschar exposed a large inflammatory centre and slough involving the fascia of the thigh, the flexor pedis perforans, and perforatus muscles, the flexor muscles of the phalanges, and the popliteus. A probe penetrated about twelve inches and touched the tibia.

Diagnosis.—Acute lymphangitis with abscess formation in the popliteal lymphatic glands, and local moist gangrene.

Treatment.—Cleansing of the parts, excision of the gangrenous tissues, and disinfection of the wound with strong carbolic solution. Hæmorrhage was trifling, but was followed by discharge of lymph. At the base of the wound the posterior tibial artery was seen. As the skin formed a pocket in the direction of the hock, it was incised for a distance of three inches. The skin of the fetlock, pastern, and coronet, affected with grease, was clipped, washed with soap and water, and disinfected with carbolic solution, and afterwards treated with 6 per cent. sulphate of copper solution.

During the first two days the wound was cleansed night and morning with strong carbolic solution, and dusted with tannin. Fragments of dead tissue separated, suppuration was very abundant, and the odour extremely repulsive.

Swelling of the limb persisted, but the general condition was good, and fever moderate. Temperature 38·7° to 39·3° C. The animal ate the greater part of its food.

On the 17th treatment with oxygenated water (hydroxyl) was commenced. Night and morning the wound was cleansed with lukewarm boiled water, and then sponged with oxygenated water. The tissues touched with this fluid assumed a whitish tint, which persisted for about an hour. The animal did not object to the dressing, and did not seem to suffer pain. Temperature 38·5° C.

Next day the wound was much less fœtid, and suppuration had markedly diminished. The stream of pus which previously ran down the limb had disappeared, but a little lymph still discharged.

During the following three days the use of oxygenated water was followed by similar effects. The wound granulated actively over its entire surface. Discharge of lymph continued, but swelling gradually diminished.

On the 25th the wound was half healed, and the sinus communicating with its deepest part was much smaller.

On the 1st December the sinus had closed and suppuration ceased. The limb was only slightly swollen, and the swelling disappeared with exercise.

Remark.—In several other cases of inflammation accompanied by gangrene, and of contused wounds with sloughing margins, oxygenated water has had the same remarkable action. It rapidly purified gangrenous or septic areas, and diminished suppuration and fever.

SPAVIN AND KNUCKLING OVER AT THE FETLOCK.

150. A thirteen-year-old gelding, left in hospital May 23rd, 1894.

Had been lame for about six months. The lameness, though at first intermittent, became continuous, and for a month previously had rendered the animal useless.

When standing the off hind limb was rested on the toe and the fetlock markedly flexed, in consequence of contraction of the flexor

tendons. A large spavin was visible, extending a considerable distance forwards. The muscles of the croup and haunch were greatly wasted, in consequence of the continual resting of the limb; and lameness was severe, even at a walk. There was no other apparent lesion.

Treatment.—Needle firing of the bony tumour, and section of the cunean tendon of the flexor metatarsi. Tenotomy of the perforans tendon. The knuckling over at the fetlock immediately disappeared. The foot was placed flat on the ground, but the phalanges seemed unsteady during movement. During the following days the reaction due to firing was intense. On the 29th the wound, consequent on plantar tenotomy, had healed. The tendons were swollen, warm, and painful, and the animal placed little weight on the limb. When moving, the oscillating movement previously seen in the phalanges had disappeared.

The animal left hospital on the 6th June, thirteen days after treatment. When returned a month later it went sound at a walk. Between that date and 1896 it was again seen several times. The results were good, and the animal had continued walking work without interruption.

DISTENSION OF TENDON SHEATHS IN FRONT OF THE HOCK.

151. A six-year-old Anglo-Norman mare, affected with distension of the tendon sheaths in front of the right hock, entered hospital February 29th, 1896.

A few months before the antero-external surface of the right hock was seen to be swollen. It gradually increased in size, and was fired in points without success.

State on Examination.—The antero-external surface of the right hock showed an elongated vertical swelling extending above and below the hock, forming a semi-cylindrical enlargement, slightly contracted at its centre, due to distension of the sheath of the extensor pedis tendon. On manipulation it appeared indolent and uniformly fluctuating. If the lower part were compressed the upper increased in size, and *vice versâ*. Fluctuation existed throughout. Manipulation showed that no communication existed with the synovial membrane of the joint.

Treatment.—Puncture and drainage of the cavity. On the 2nd March the animal was cast on the table, and the anterior portion of the hock prepared by shaving and disinfecting the skin over the ends of the tumour. The lower part of the swelling was compressed by an assistant, causing the liquid to accumulate in the upper *cul-de-sac*, which was then opened with a bistoury. A quantity of light yellow, slightly viscous liquid, resembling synovia, escaped. A grooved director passed through the entire length of the cavity, and was arrested by the wall of the lower *cul-de-sac*, a little below the inferior margin of the hock. The lower part of the *cul-de-sac* was opened over the prominence thus produced, and the wound enlarged by passing a bistoury along the groove of the director. A rubber drainage-tube, rendered aseptic by boiling in carbolic solution, was introduced into the tract.

The animal was returned to its box and tied up. During the night the parts were irrigated with warm sublimate solution. Temperature at 7 p.m. 39·0° C.

Next day the parts were slightly swollen and painful, but injection of antiseptics did not produce any marked struggling.

During the following days swelling and pain increased, and the foot was rested on the toe. Purulent serosity escaped from the lower end of the drainage-tube. The injections were continued; temperature 39·2° to 38·6° C.

On the 6th the region was less sensitive, the discharge less abundant, and more weight was placed on the limb. The lower part of the drainage-tube was removed with scissors, and the lower wound opened so as to allow any liquid which might accumulate there to escape.

On the 10th the inflammation, suppuration, and pain were much diminished. The animal was suitably secured, and the drainage-tube replaced by one of smaller calibre.

On the 12th suppuration had almost ceased, and the limb was moved without difficulty.

On the 18th drainage was discontinued. The animal was perfectly sound when walking, and at a trot only showed occasional lameness.

Next day it left hospital, returning to work shortly afterwards. The external half of the hock remained slightly indurated.

Remark.—Double puncture and drainage also gave excellent results in another draught-horse similarly affected. Distension of this bursa offers the greatest clinical analogy with distension of the precarpal bursa. Most of the classic authors ignore it.

MEDIAN AND ULNAR NEURECTOMY—AFTER-COMPLICATION.

152. A ten-year-old gelding, suffering from arthritis of the near fore fetlock-joint, consequent on pneumonia. Treated at the commencement of November, 1898, by firing in points. After operation the animal was returned home; the region fired became covered with mud, and was not treated in any way.

At the end of a week three of the punctures on the inner surface of the fetlock discharged purulent synovia. The parts became greatly swollen and very hot; the foot was only rested on the toe. The cauterised surface having been disinfected with a 1 per 1000 warm solution of sublimate, and the three small wounds touched with tincture of iodine, a cotton-wool dressing was applied to the fetlock, and kept moist by applications of sublimate solution. The dressing was renewed daily. Inflammation remained confined to a part of the synovial membrane. In a fortnight the wounds had healed, and the animal began to use the diseased limb. The fetlock, however, remained swollen, and became indurated. The animal was exercised night and morning for ten minutes to a quarter of an hour, and the lameness diminished to a considerable extent.

Firing the fetlock in lines lessened the swelling and lameness, but the animal always remained too lame to trot. Median neurectomy was decided on. The result was insufficient. A month later the ulnar

nerve was divided. After operation the horse no longer walked lame, and only showed little lameness at a trot.

On the 8th March, ten days after division of the ulnar nerve, the fetlock of the diseased limb collapsed. In consequence of the want of sensation in the lower regions of the limb weight was still placed on it, but the row of phalanges was horizontal, and the fetlock touched the ground. The heels of the foot were horizontal, and the toe projected upwards. The canon-bone formed an angle of nearly ninety degrees with the phalanges. The fetlock was wider than normal,

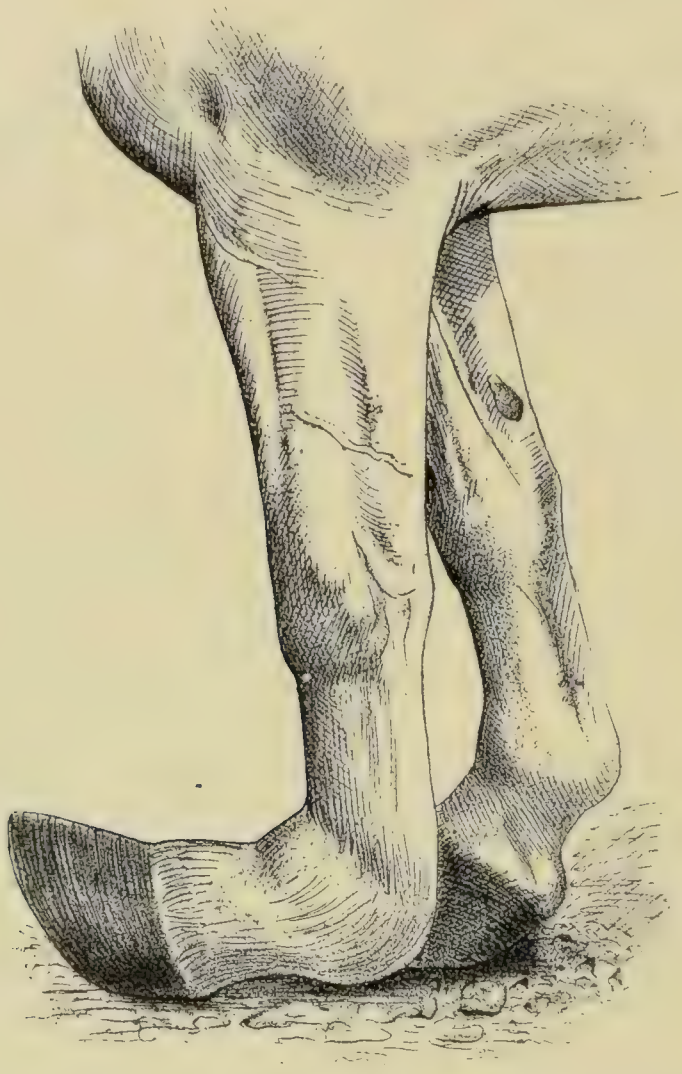

Fig 58.—Rupture of the flexor tendons, etc., after neurectomy.

though it was impossible to exactly discover the position of the lesions. Rupture of the flexor tendons and suspensory ligaments was diagnosed. As the skin covering the posterior surface of the joint and the synovial membrane of the joint itself had become lacerated in consequence of movement and repeated rubbing, the animal was slaughtered.

Examination of the Lesions.—Incision through the skin exposed a thick layer of infiltrated fibrous tissue enveloping the tendons, the upper parts of which, however, were intact. Opposite the fetlock the tendons were displaced towards the right and inflamed for a distance

of three to four inches. The perforatus tendon had become elongated. Its fibres were partially ruptured, necrotic, and disintegrated; the perforans tendon showed similar changes. Only the terminal branches of the suspensory ligament showed change; they were swollen, inflamed, infiltrated with serosity and blood, a condition which became more marked towards their extremities. The insertion itself was destroyed, the fibres being softened and degenerated. The surfaces of attachment on the sesamoid bones were rough to the touch. The intersesamoid ligaments were ruptured, and the sesamoid bones thrust to either side of the upper extremity of the first phalanx, causing the enlargement of the fetlock above mentioned. The inferior sesamoid ligaments had only undergone trifling change. The metacarpo-phalangeal synovial membrane was inflamed, and at points was stained with blood. The articular surfaces were free of injury. The great sesamoid sheath and the bones showed no change.

QUITTOR—PARTIAL NECROSIS OF THE ANTERIOR LATERAL LIGAMENT OF THE PEDAL JOINT.

153. A ten-year-old gelding with quittor, entered hospital October 13th, 1897.

The disease had been in existence for six weeks. During the previous three days the animal was unable to work.

State on Examination.—The inner surface of the off fore coronet showed a diffuse, slightly sensitive swelling, at the posterior part of which were two small cicatrices; and in front, opposite the anterior portion of the lateral cartilage, a sinus about an inch and a half in depth, discharging an abundance of watery pus. The wall of the hoof was separated along almost the whole of the internal quarter. At rest the limb was extended, and continually lifted and set down with a tapping movement. Even at a walk lameness was very marked.

Treatment.—The shoe was removed, the horn pared away, and the foot enveloped in moist compresses. Temperature 38·9° C.

On the 14th the animal was cast, the foot prepared, the horn of the quarter removed, and the classic operation for quittor performed. All the anterior portion of the lateral cartilage was necrotic; the fibrous layer below was almost entirely granulating. The anterior lateral ligament of the joint was partially necrosed; the superficial layer was yellowish in colour, and appeared softened and broken down.

The remainder of the cartilage was removed, together with the necrotic layer of the ligament, and the wound swabbed with tincture of iodine. The parts having been scrupulously cleansed, the deeper tissues were covered with a thick layer of iodoform, and the foot dressed with gauze and cotton wool.

On rising the horse appeared distinctly easier than before operation, and when returned to its box ate with some appetite. In the afternoon, however, it lay down. Respiration became rapid and moaning, and frequent lancinating pain was shown. In the evening the animal ate some oats and part of its hay. Temperature 40° C., respirations 26, pulse 58.

During the following days the general condition improved, though considerable pain still persisted. The temperature varied between 38·5° and 39·7° C.

On the 19th the horse began to place weight on the limb. Temperature 38·2° to 38·4° C.

From the 20th to the 23rd improvement increased. More weight was placed on the diseased limb.

On the 24th the dressing was renewed. There was little pus. The wound appeared healthy and granulating throughout, both opposite the ligament and at the back. It was thoroughly cleansed, a shoe applied, and the parts dressed with iodoform. In consequence of the concussion produced during shoeing, and the much greater compression caused by the new dressing, less weight was placed on the limb. Lameness was more marked, and lancinating pain returned to a slight degree. From the 25th to the 29th the condition gradually improved. On the 30th as much weight was placed on the diseased as on the healthy limb.

On the 5th November the dressing was renewed. There was little pus. The wound had almost completely healed, and the horse showed no lameness at a walk.

154. A ten-year-old mare with quittor of the near fore-foot, left in hospital August 5th, 1898.

Two months before the coronet of the near fore-foot had been injured. The wound was complicated by necrosis of the internal lateral cartilage. Treatment by caustic injections and cauterisation was unsuccessful, and partial operation also failed.

State on Entry.—At rest no weight was placed on the near fore-limb, which was advanced and rested on the toe. At a walk the animal was very lame. Over the internal lateral cartilage the coronet, which showed signs of having been fired in points, exhibited a considerable swelling, especially towards the heel. Above the centre of the lateral cartilage was a sinus about an inch in depth, running obliquely forwards and downwards, and discharging liquid, greenish, abundant pus.

Treatment.—The shoe was removed, the inner heel, bar, sole, and frog of the injured foot thinned, the hair clipped away from the coronet and pastern, and a large antiseptic moist dressing applied. Next day the mare was cast on the left side on the table, and the limb suitably fixed.

The foot, coronet, and pastern having been disinfected, operation was proceeded with. The sinus ended over the anterior lateral ligament. After having removed the remaining portion of the cartilage the surface of the ligament appeared in a necrotic condition, dull, softened, and yellowish grey in colour, its fibres swollen and separated. The dead portions were removed with a sharp knife. The remaining part of the ligament was several times touched with tincture of iodine. The operation wound having been irrigated with warm 1 per 1000 sublimate solution, an iodoform dressing was applied. The evening temperature was 38·5° C.

Next day the general condition was good. The animal showed a little lancinating pain in the diseased limb; temperature 39·0° C.

On the 8th the temperature was 38·3° C. Occasional lancinating pain was still noted.

On the 9th pain had ceased; the temperature and principal functions were normal. On the following days the animal began to place weight on the foot.

On the 14th the dressing was removed; the wound was granulating throughout, and visibly disposed to heal. A shoe and dressing were applied. Weight was readily placed on the limb, and lameness was trifling.

On the 25th the dressing was again renewed. Healing was almost complete, and lameness scarcely noticeable at a walk.

OPERATION FOR PICKED-UP NAIL.

155. A ten-year-old gelding suffering from picked-up nail in the middle zone of the near hind foot. Treatment by thinning the horn and poulticing had only resulted in the condition becoming aggravated. The horse was sent to hospital on the 14th April, 1896.

No weight was placed on the diseased limb, the animal walking on three legs. The injury in the sole traversed the anterior part of the external branch of the frog, which was very prominent at this point in consequence of swelling of the subjacent tissues. The sinuous wound discharged a large amount of yellowish viscous pus. The flexure of the pastern was swollen; temperature 39·0° C.

Treatment.—Thinning of the sole and frog; immersion of the foot in warm carbolic solution for twenty minutes; application of peat wool compresses soaked in the same solution.

Next day the animal lay continually. The affected limb was moved spasmodically in consequence of darting pain.

The horse having been cast, and the limb fixed in a convenient position, the partial operation for picked-up nail was performed. A portion of the plantar cushion was removed; the sinuous tract laid open in front and behind, and an elliptical piece removed from the margins of the plantar aponeurosis, so as to produce a button-shaped aperture three eighths of an inch in length.

The small sesamoid sheath, being full of purulent synovia, was irrigated with warm 2 per cent. lysol solution, powdered with calomel, and enveloped in a cotton-wool dressing.

Next day the animal showed evidence of acute pain. It only rose to eat, and even then left a portion of its food. Temperature 38·6° C. Less signs of lancinating pain.

During the following days the condition remained stationary; temperature 38·7° to 39·5° C.

On the 22nd the dressing was renewed. The operation wound had commenced to granulate; there was little pus; the parts were irrigated with lysol solution, and dressed with calomel.

From the 23rd to the 30th the animal remained lying for the greater portion of the time; temperature 38·5° to 39·3° C.

On the 1st May the dressing was changed. The flexure of the pastern was swollen in consequence of an abscess having developed.

This was punctured, and the cavity washed out; the foot was then immersed in lysol solution, and again dressed with cotton wool.

During the following days the condition improved; the temperature fell to 38·0° C. and more weight was placed on the foot.

On the 12th the dressing was removed; the operation wound was healing well, as was that produced by opening the abscess. On the 16th the abscess wound had closed.

The animal left hospital on the 19th. Lameness was still marked, but the horse walked well enough to return to its own stable.

156. A seven-year-old entire horse, left in hospital 25th September, 1897. Suffering from picked-up nail in the middle zone of the foot. Operation had been unsuccessfully performed.

State on Examination.—The off hind leg was the seat of frequent darting pain; in the intervals the foot was rested on the toe. Lameness was very severe, the toe being dragged along the ground. The parts, moreover, were very hot and sensitive. The operation wound was surrounded by fungous granulations, which masked a sinus discharging coagulated, fœtid pus. The navicular bone was not exposed at any point, previous operation having been confined to the plantar cushion and the superficial layer of the aponeurosis. Despite these grave local and functional symptoms the general state was fairly good, and the appetite preserved. Temperature 38·4° C.

Treatment.—The foot was pared, disinfected, and surrounded with a peat wool dressing, continually moistened with carbolic solution.

On the 26th, the animal having been cast on the table, the complete operation for picked-up nail was performed. The lower surface of the navicular bone appeared roughened, and was already granulating at points. Part of the right half of the perforans tendon showed necrosis, which extended a considerable distance upwards. In excising this, one of the synovial sheaths in the flexure of the pastern, without doubt the *cul-de-sac* of the great sesamoid sheath, was accidentally opened. A jet of synovia escaped from the wound.

A counter-opening was made in the flexure of the coronet, and a gauze drain passed; after carefully cleansing the wound, the fragment of necrotic tissue left on the tendon was touched with tincture of iodine. The parts were enveloped in an iodoform dressing.

On returning to the stable the horse began to eat. During the night the general disturbance was very trifling.

During the following days the chief functions were normal; the temperature did not rise beyond 39·3° C. For a week the foot was rested on the toe, and signs of severe stabbing pain were evident.

On the 2nd October the dressing was renewed. The base of the wound was granulating, and the wound in the synovial membrane had healed.

From the 5th pain diminished, more weight was placed on the limb, and the foot was at times rested flat on the ground.

On the 9th the dressing was removed. A considerable quantity of pus was found in the wound, which, however, was granulating throughout, except where the drain had been passed. It was washed out with

carbolic solution, and a fresh gauze drain inserted. Next day less weight was placed on the foot, but no general disturbance was noted.

From the 12th improvement was rapid. The dressing was renewed every week, the thickness of the gauze drain being diminished.

On the 28th drainage was suspended, a shoe was applied, and a dressing kept in position by splints inserted. The horse showed little lameness when walking.

Left hospital on the 7th November, and returned to light work a few days later.

157. A five-year-old entire horse, suffering from picked-up nail in the left hind foot, entered hospital March 5th, 1898. Three weeks before an operation had been performed by a veterinary surgeon; the wound had become sinuous.

Condition on Entry.—Lameness was very marked, the foot resting on the toe. There was frequent stabbing pain; the limb was swollen as high as the hock, and the coronet enlarged, especially at the back, and in the flexure of the pastern.

The dressing covering the lower surface of the foot was removed. The wound occupied the middle zone of the external lateral lacuna; its margins were greatly swollen and vegetating, and discharged purulent synovia.

Treatment.—Disinfection of the foot and wound; carbolic baths; application of a moist dressing. Next morning the horse was found sitting up like a dog, with the hind limbs extended under the body. It was assisted to rise.

After casting the animal on the table the complete operation for picked-up nail was performed. The external half of the plantar aponeurosis (*i. e.* the expanded terminal portion of the flexor pedis perforans tendon) was necrotic to a point level with the posterior margin of the navicular bone, which had been penetrated close to its anterior border. At that point was a splinter of bone, which was removed with forceps. The navicular joint had been opened, the interosseous ligament detached from the navicular bone, and the inferior synovial *cul-de-sac* perforated. After touching the articular wound with tincture of iodine the parts were irrigated with warm 2 per cent. carbolic solution, covered with iodoform, and plugged with gauze. The foot was surrounded with a cotton-wool dressing.

During the next two days pain was acute. Temperature 39·0° to 39·6° C.

On the 9th the dressing was removed, the wound cleansed with an antiseptic solution and covered with a fresh iodoform dressing.

From the 10th to the 17th the general condition remained good. The fall in temperature, diminution in frequency of stabbing pain, lessened swelling, return of appetite, and ability to stand, all showed that the wound was healing without complication.

On the 18th the dressing was renewed. The coronet was slightly swollen, the parts were granulating throughout. The articular wound had healed.

On the 1st April a shoe and splint dressing were applied. A week later exercise was commenced.

On leaving hospital on the 20th April the horse was able to resume work.

158. An eleven-year-old entire horse, left in hospital 7th November, 1898.

Five weeks before had picked up a nail in the near fore-foot. The wound was unsuccessfully treated by caustics and antiseptics. On the 4th November signs of complication appeared, the injured foot being carried clear of the ground. The veterinary surgeon in charge recommended sending the animal to Alfort.

State on Entry.—The animal had great difficulty in descending from the ambulance, and force was required to make it walk to its box. No weight whatever could be placed on the near fore-foot. The general condition was bad, and the face showed signs of suffering.

On removing the dressing a large fungating sinuous wound, covered with yellowish-white discharge, was seen towards the middle of the external lateral lacuna.

Treatment.—Thinning of the frog and sole, and moist applications to the foot.

Next day, although the temperature was only 38·6° C., operation was considered necessary. The horse was cast on the right side on the table. The near fore-foot was carefully fixed, the sole stripped, and the operation for picked-up nail performed. The plantar cushion was divided at right angles to the surface of the sole, about three eighths of an inch behind the point of the frog. The insertion of the perforans tendon was spared as much as possible. It was lifted with a retractor to allow the lower surface of the navicular bone to be scraped. Its surface of insertion on the pedal bone was preserved in its entirety. The interosseous ligament had been injured by the nail, opposite the anterior margin of the navicular bone, and at this point was several times touched with tincture of iodine. The wound was washed out with warm salt solution, and with 1 in 1000 sublimate solution; then, using a director, enveloped in wadding saturated with tincture of iodine, the superior *cul-de-sac* of the small sesamoid sheath was carefully disinfected.

A traumatol dressing was applied, the parts plugged with gauze and surrounded with a cotton-wool dressing. After operation the temperature was 39·5° C., in the evening 38·6° C. During the night the horse ate its food.

Next morning the general condition was good. Temperature 38·4° C., evening 38·6° C.

From the 10th to the 17th November the temperature varied between 38·0° and 38·8° C. There was little stabbing pain. The appetite was preserved, and everything showed that healing was occurring regularly.

On the 18th the dressing was removed. A quantity of blood-stained discharge was found under the gauze. Except on the navicular bone the wound was granulating throughout. It was cleansed, irrigated with warm sublimate solution powdered with traumatol, and covered with a new cotton-wool dressing. During the following days the

temperature only exceeded normal by a few tenths of a degree. From the 24th some weight was placed on the injured limb.

On the 1st December the wound was half healed. A shoe and dressing were applied. The horse walked easily; at a walk there was only trifling lameness. It left hospital on the 8th December.

COMPLICATED CASES OF CORN.

159. A twelve-year-old mare, left in hospital November 2nd, 1897. Had been lame on the off fore-limb for nearly three months. Corns had been found in the feet, and treated by thinning the horn. Lameness, at first trifling and intermittent, had become intense during the previous week.

When examined the mare was too lame for work. At rest the off fore-limb was advanced. Lameness was severe even when walking. The foot was very sensitive, and a suppurating corn could be seen in the internal quarter. The heel and posterior half of the quarter were swollen.

Treatment.—Thinning of the sole, bar, and frog; exposure of the fistula; clipping away of the hair of the coronet and pastern; careful washing of these parts, and of the foot with soap and water; carbolic baths; and moist antiseptic application to the foot.

On the 2nd and 3rd November the dressing was saturated with carbolic solution. No improvement.

On the 4th the mare was cast for operation. The heel of the hoof was entirely removed for a distance of about two inches; the wall thinned together with the corresponding portion of the sole, and part of the frog. A patch of necrotic laminæ was removed with the knife. A sinuous tract, running obliquely upwards and inwards, opened in the commissure, between the quarter and the reflection of the bar, penetrating a long distance into the plantar cushion. After laying open the fistula, parallel to the axis of the foot, and excising an elliptical portion of the plantar cushion, a mass of necrotic tissue, the size of a small nut, was discovered, formed by the base of the cartilage and the plantar cushion.

The necrotic tissues were freely removed with the knife and curette; the base of the wound was swabbed with tincture of iodine, irrigated with iodine lotion and covered with iodoform, iodoform gauze, and a cotton-wool dressing.

On rising the animal placed more weight on the diseased limb than before operation. Evening temperature 38·6° C.

On the 5th weight was placed on the limb, and there was no evidence of stabbing pain. During the following days improvement continued. The temperature was normal.

On the 13th the dressing was removed. The wound was healing well; the loss of tissue in the region of the laminæ had been repaired, and the wound was covered with horn. The cavity on the plantar surface was granulating throughout. There was little pus. A fresh cotton-wool dressing was applied.

On the 20th a shoe was applied and a dressing inserted, kept in

position by splints. When resting the foot was no longer advanced, and at a walk the animal appeared sound. Left hospital November 24th.

160. A seven-year-old mare, left in hospital November 28th, 1897, suffering from suppurating corn in the inner heel of the off fore-foot. Had been unsuccessfully treated by caustic injections. When standing the injured foot was rested on the toe. At a walk lameness was severe. The inner heel had been thinned, and was very sensitive. At the point of reflection of the bar a sinus had opened, and discharged considerable quantities of watery pus. The inner half of the coronet was swollen and painful.

Treatment.—Disinfection of the foot; thinning of the sole and bar; antiseptic baths; moist dressing.

Next day the patient was cast, and the right fore-limb fixed to the corresponding hind. The sinus, an inch in depth, was washed and laid open. A double elliptical-shaped incision revealed a large mass of necrotic tissue, formed by part of the plantar cushion and of the lateral cartilage, extending to the retrorsal process. This was removed with the knife, and the base of the wound, that is the base of the cartilage and of the retrosal process curetted. The wound was irrigated with sublimate solution, dusted with iodoform, plugged with gauze, and covered with a cotton-wool dressing. In the evening there was some darting pain; temperature 38·7° C.

Next day the foot was rested on the toe. There was still a little darting pain; temperature 38·5° C. During the next three days more weight was placed on the foot.

On the 4th December the wound was examined. It contained very little pus. After cleansing, a dry point was detected near the bottom and was touched with tincture of iodine. A calomel dressing was used.

On the 11th the dressing was removed. The wound showed a little discharge, but was granulating throughout. Pressure on the coronet still produced pain. A bar shoe and tow dressing were applied.

On the 17th the animal no longer walked lame. Left hospital on the 23rd.

161. A fourteen-year-old entire horse, left in hospital May 19th, 1898, suffering from suppurating corn in the inner heel of the off fore-foot. Had been operated on three weeks before. The operative wound had become sinuous. Lameness was intense, and the animal had to be carted to Alfort.

The off fore-foot was rested on the toe, and continually lifted in consequence of lancinating pain. The coronet was swollen and painful over the inner heel and posterior portion of the quarter. The sinus and the plantar surface discharged greyish blood-streaked pus.

Treatment.—The inner heel was thinned; the foot disinfected and enveloped in large compresses of peat wool saturated with 3 per cent. carbolic solution.

Operation was performed on the 21st. The animal was cast on the

right side, and the diseased limb fixed to the corresponding hind limb. The internal branch of the sole and the wall of the heel being loose were completely removed. The sinus was cleansed and laid open in front; from either side of the incision a slip of the velvety tissue and of the plantar cushion was removed. A necrotic fragment was then seen, formed by a portion of the plantar cushion and the lateral cartilage. This fragment was removed with the knife, and the base of the wound curetted. After cleansing with sublimate solution the margins of the wound were touched with tincture of iodine, covered with a layer of europhene, plugged with gauze, and enveloped in a cotton-wool dressing.

On the following days there was no stabbing pain. The temperature did not exceed 38·7° C. At first weight was sparingly placed on the foot, but the tread afterwards became more and more firm.

On the 28th the horse scarcely showed lameness at a walk. The dressing was renewed, the wound being found to contain little pus and to be healing well. The parts were dressed a second time with europhene. At the end of a few days weight was firmly placed on the foot, and the temperature was normal.

On the 4th June the wound was covered with granulations; swelling of the coronet had almost entirely disappeared. A bar shoe and tow dressing were applied.

The animal left hospital on the 11th June, at which time it no longer appeared lame at a walk.

Remark.—Before the introduction of antisepsis, operation for complicated corns was often followed by a return of necrosis in the lateral cartilage or in the plantar cushion, and sometimes by their extension to the plantar aponeurosis. In both cases it finally became necessary to excise tissues very freely. At the present time free removal of the necrotic tissue, careful curettage of the base of the wound, and antiseptic dressing almost always secure healing.

GRANULOMA ON FOOT OF STALLION.

162. A pure bred Clydesdale stallion.

History.—The origin of the growth was a severe quittor, which affected the whole of the subhorny tissue, sinuses running in all directions. These were successfully treated, but a gradual increase of granulating tissue then occurred around the coronary band. For about two years this increase was slow and interfered very little with the animal's work, but a sudden increase then occurred, so that in a few months the foot could scarcely be raised from the ground.

Although operation held out little hope of success, it was resolved on for lack of other remedy.

Operation.—The animal was cast and chloroformed, a tourniquet was placed above the hock, and the growth removed (with little hæmorrhage) as completely as possible. As the tumour practically encircled the foot, and extended, with œdema, as far as the hock-joint, it was impossible to remove the whole of the diseased tissue, so that only so much was excised as it was believed would enable the animal



FIG. 59.— Clydesdale stallion with large granuloma at coronet (off-side view).



FIG. 60.—Clydesdale stallion with large granuloma at coronet (near-side view).

FIG. 61.—Clydesdale stallion, showing foot three months after removal of growth.

to walk with freedom. The portion removed was carefully weighed afterwards, and totalled forty-nine pounds. Bleeding after removal of the tourniquet was almost totally prevented by the application of a 5 per cent. sterilised solution of gelatin, over which was placed alembroth antiseptic wool, the whole being bandaged.

Three days afterwards, when the bandages were removed, it was found that there had been practically no hæmorrhage, and the wound, which was about twelve inches square, was perfectly aseptic. Unfortunately the surface of the growth was in such a condition, and so implicated, that no skin could be dissected back wherewith to make a flap. However, under careful attention an almost complete recovery took place, scaly epidermis gradually covering the scar, and three months afterwards the animal presented the appearance seen in the third photograph, which was taken after he had served a dozen mares, and shows him in good condition. The growth, when examined microscopically, proved to be composed simply of granulation tissue of dense fibrous consistency.

Mr. J. A. Gilruth's case, *Veterinarian*, 1900, p. 298.

RUPTURE OF THE SESAMOID LIGAMENTS IN BOTH FORE-LIMBS IN THE HORSE.

163. The subject was a twenty-one-year-old Anglo-Norman horse, still in vigorous condition, which had been blistered both on its front and hind legs on account of some trifling synovial enlargements. A fortnight after the second application the horse was turned out to grass, and, on being set free, galloped round the field several times. It was then left without further supervision. At the end of half an hour it was found lying down, in great pain, and had to be assisted to rise.

It remained standing for a few seconds, the hind limbs being placed far under the body, the front excessively flexed on the fetlock, the ergot on which touched the ground, but soon fell. On examination signs of rupture of the flexor tendons were seen in both front limbs, and the animal was slaughtered.

Anatomical Changes.—The tissues surrounding the left fetlock-joint were swollen and hæmorrhagic. The perforatus tendon was not affected. Immediately below the point where it emerges from the ring formed by the perforatus, the perforans tendon, however, was partially torn through.

The external lateral sesamoidean ligament was ruptured. The subcarpal ligament and the external slip, which passes from it to the extensor pedis tendon, were only slightly injured, but the internal slip was ruptured at its point of origin. The capsular ligament was torn, thickened, and infiltrated with blood. The sesamoids were freely moveable, being no longer fixed to the great metacarpal, and only connected with the first phalanx by the internal ligaments. The intersesamoidean ligament was ruptured vertically.

The fibrous expansion surrounding the tendons at the back, where they pass over the gliding surface of the sesamoids, was ruptured at its internal point of attachment, a portion of the bone being torn away.

The three inferior sesamoidean ligaments were ruptured on the same line at their upper insertion. Here again the ligaments had torn away the portion of bone to which they were attached. The internal sesamoid was fractured transversely.

There were no other bony changes. The lower extremity of the metacarpus and the first phalanx were intact. The synovial capsule of the joint was torn and ecchymosed throughout the greater part of its surface. Finally, there was a great difference in size between the two terminal branches of the superior sesamoidean ligament (suspensory ligament); the internal was chronically inflamed, and double the size of the external.

Most of the lesions in the right fetlock were similar to those above described. Both sesamoids showed comminuted fracture.

VI.—INFECTIOUS DISEASES.

TUBERCULOSIS IN THE HORSE.

164. An eight-year-old Percheron gelding brought for examination, April 7th, 1889.

History.—Had been bought from a farmer in the neighbourhood of Chartres three years before, had always appeared in good health, and had worked without stoppage as a heavy draught-horse.

Towards February 15th, 1889, the animal suffered from bronchitis, from which it recovered in a fortnight. It had returned to work for a week, and appeared in its usual health, when one morning the driver noticed at different points a number of subcutaneous swellings of varying size, the largest having the diameter of a two-shilling piece and the thickness of a man's little finger. The animal also seemed rather dull, and became exhausted more readily than usual. This was the history given when the patient was brought here a few days later.

Condition on Entry.—At the outset of our examination we noted scattered over the surface of the trunk, and of many other regions, numerous swellings, recalling at first sight an outbreak of "heat spots," but distinguishable from these by their clinical characters. All were firm, hard, and of fibrous consistence. The majority had developed in the subcutaneous connective tissue. Some appeared continuous with the skin. In pursuing our examination we saw that certain lymphatic glands, corresponding with the affected zones, were enlarged, spherical or ovoid in shape, moveable under the skin, and of similar consistence to the hypodermic swellings. Several of these glandular enlargements were symmetrical, the corresponding glands of the right and left sides being practically of the same size. In some parts the larger patches beneath the skin were connected with the lymphatic glands by knotted cords.

Towards the point of the left shoulder, and over the masses of muscle formed by the extensors of the forearm, a lymphatic chain could be seen, extending from the girth to the pre-pectoral glands; it started from a disc-shaped tumour, one to one and a half inches in diameter, three eighths of an inch in thickness, of very firm and indolent character, and moveable under the skin. The shoulders, sides, flanks, and more particularly the croup, quarters, and thighs, showed similar new growths, varying in size between a pea and a five-shilling piece. The inguinal glands, especially those of the left side, were enlarged and indurated. The connective tissue surrounding them was slightly swollen. None of these lesions was at all painful.

Rectal exploration revealed nothing. The sublumbar lymphatic glands were normal, and no swelling was discovered in the posterior portion of the abdominal cavity or in the pelvis.

The great functions were not particularly disturbed. Had it not been for the cutaneous and subcutaneous lesions, the animal might have been thought in good health. The rectal temperature was 39·5° C. The urine was of normal colour, contained no sugar or bile pigments, but was slightly albuminous (about 7½ grains of albumen per pint). There was neither undue frequence of urination nor true polyuria. Examination of the blood showed no modification in the number or appearance of the blood-corpuscles.

One of the subcutaneous tumours was excised for histological examination. The structure was that of a sarcoma.

Treatment.—Iodide of potassium in daily doses of 4 drachms. Some days later the lymphatics on the left shoulder became inflamed in the same way as had those on the right, but the swelling gradually disappeared. The animal was left for a month in hospital. During the last fortnight the daily dose of potassium iodide was increased to 5 drachms. No appreciable improvement occurred.

On May 6th the owner withdrew the horse to try it at slow work, but again brought it here on June 5th in a very grave condition. The appetite had diminished and the animal grown extremely weak; the slightest effort caused its breathing to become so embarrassed as to bring it to a standstill.

We again examined it. It appeared extremely depressed and feeble. The head was rested on the manger; the mucous membranes were pale, the skin dry, and the coat staring. The respirations were 36; pulsations 57 per minute; rectal temperature 39·3° C. The accelerated respiration and absence of fever caused us to suspect invasion of the lung by the tumours. On auscultation a respiratory murmur was noted throughout the entire area of both lobes. There was a little partial dulness in the lower regions of the thorax.

The lymphatic enlargements in the flank had nearly disappeared, but the others remained almost as marked as before. The pre-pectoral and pre-scapular glands were large, hard, and slightly sensitive on pressure.

The left surface of the neck, over the region corresponding to the mastoido-humeralis (levator humeri) and of the levator anguli scapulæ was swollen and sensitive, and the neck slightly turned to the right, as in luxation of the neck.

Finally, one of the fore-limbs was frequently extended and placed under the vertical line of the body, giving the animal a certain appearance of "immobilité" (dropsy of the lateral ventricle).

Some days later the horse was exercised at a trot. It had scarcely gone a few hundred yards when increasing difficulty in respiration and a loud roaring noise were noticed. Being threatened with the whip, it continued trotting for about five minutes, and then stopped for want of breath. Sweating was abundant, respirations very rapid (70 to 80 per minute), expiration double, and auscultation revealed a respiratory murmur over the entire area of both pulmonary lobes.

After its return to hospital some of the tumours had disappeared, a few completely; but others had grown and continued to enlarge.

The animal appeared incurable, and was slaughtered a few days later.

Autopsy.—The lesions found on *post-mortem* examination were more generalised than had at first been supposed. On dissecting away the skin numerous small tumours, scattered through the subcutaneous tissue, were seen at some points discrete, at others more closely placed. A certain number were continuous with the corium. The smallest of these tumours was the size of a pea, the largest the size of the yolk of an egg. The majority were rounded, firm, and of fibrous consistence.

Here and there traces of the above-mentioned lymphangitis could be noted. The lymphatic glands at the entrance of the chest were enlarged, and formed two lobes, each the size of a walnut.

Graver lesions, which had not been suspected during life, existed in the muscles and viscera.

A large number of the muscles showed bands of sclerotic tissue and little rice-like whitish nodules. These growths were very abundant in the levator anguli scapulæ, the rhomboideus, the extensors of the neck, the small oblique muscles of the abdomen, but especially in the adductors of the two hind limbs, and in the superficial glutei, these two last muscular groups being crowded with them.

On opening the abdominal cavity certain viscera, particularly the liver and spleen, were seen to be invaded by these tumours. The liver and spleen were crowded with fine granulations; the spleen, in addition, contained three tumours the size of a walnut. The peritoneum covering the stomach showed a collection of granulations resembling recent tuberculous growths. Of the various abdominal lymphatic glands the sublumbar alone were affected. They formed an ovoid mass, the size of a man's fist, which had not been detected on rectal exploration.

The other abdominal viscera, together with the lung, heart, pleura, nervous centres, and bones, were free of these growths.

Histological examination extended to the muscles, skin, liver, and spleen. The diseased muscles showed the same characters as in tuberculous cirrhosis of muscle. In the skin, liver, and spleen the tubercles contained a large number of giant-cells. They tended, especially those in the spleen, towards fibrous change, and were exceedingly poor in tubercle bacilli.

164. A seven-year-old entire horse, brought to the school on the 8th May, 1896, for castration.

History.—The horse had been bought in 1894. At that time the scrotum was large, but the seller declared the condition to be congenital. The animal worked well until February, 1896, when the scrotum became swollen and appeared to interfere with movement; the patient fell away in condition. Castration was decided on.

Condition on Entry.—At first glance this horse appeared in good health. The right testicle was much larger than the left. Its en-

velopes were thickened and œdematous, but only slightly adherent to the gland itself. No change could be discovered in the cord. On the left side the envelopes were also swollen; the testicle, however, appeared normal. Rectal examination showed no enlargement of the sublumbar glands. The animal did not react to mallein.

On the 11th May the animal was cast on the table and fixed for castration. After careful disinfection of the parts the right testicle was removed by crushing the cord. There was very little hæmorrhage, and no dressing was employed.

The testicle was double the normal size. On incision its tissue appeared little changed. This was not the case, however, with the epididymis, the termination of which had been transformed into a tumour the size of an orange, formed of whitish, firm, fibrous tissue. The cord appeared healthy, except over its serous surface, where it was covered with small reddish granulations.

During the night and following days the wound was cleansed with warm sublimate solution. Swelling of the sheath increased until the 20th May, after which it diminished, and the wound appeared to be healing regularly.

On the 29th the swelling resulting from operation had greatly diminished, but the envelopes of the left testicle were thicker and more infiltrated than at the time of entry. The testicle was removed. Enucleation was rendered somewhat difficult by the induration of the subdartoid connective tissue. The cord was divided with the écraseur, hæmorrhage being trifling and of short duration.

The testicle was about one third larger than normal. The glandular tissue was infiltrated. The part of the cord removed was enlarged, and, like the right cord, covered with small vegetations. The vaginal sheath contained a little reddish liquid.

During the following days the animal's general condition and appetite remained good, though fever existed, the temperature varying between 39·4° and 39·8° C. There was considerable œdema about the wound, the swelling extending four inches beyond the front of the sheath.

The general condition remained stationary until the 11th June, and no disquieting symptoms occurred.

On the 12th the morning temperature was 39·2° C., evening 39·6° C. During the day the animal appeared depressed and spiritless, but ate all its food. Next morning it was found dead in its stall.

Autopsy.—The castration wounds were granulating throughout. The external envelopes were about two inches and a half to three inches and a quarter in thickness, and engorged with serosity. At the base of the operation wound in each division of the scrotum was a rounded swelling, the size of an apple, formed by the end of the cord, which was dense, firm, and of fibrous appearance on section. Both cords were covered with little whitish swellings, and vegetations similar to those found in the parts removed. The sheath was enlarged and œdematous, but without special feature.

Abdominal Cavity: The great omentum was riddled with tubercles, hard or soft in consistence and isolated or massed together in the

form of larger or smaller "grapes." The peritoneum covering the posterior surface of the diaphragm was covered with whitish tumours, the largest the size of a hazel-nut, some isolated, others collected in patches of varying extent and thickness; all were dense, firm, and without softened centres: though abundant at the limit between the aponeurotic and muscular portions, they were rare on the muscular part itself. Opposite the stomach was a patch measuring twelve inches in length, six inches in breadth, and two to two and a quarter inches in thickness.

The spleen was double its normal size, and of a lilac tint; its surface was irregular. Its substance contained seven large, firm, uniformly hard tumours, three the size of an orange, the others as large as an egg, all of yellowish-white colour, and showing on section a few calcified points. The base of the organ was infiltrated with granulations. The splenic lymphatic glands were hypertrophied. The gastro-splenic omentum was covered with tubercles containing caseous centres.

The liver was of enormous size, yellowish colour, and showed both on its surface and on sections numerous tubercles, varying in dimensions between a pin's head and a pea, all firm and without signs of degeneration.

The kidneys were unaffected.

The mucous membrane of the large colon was healthy throughout the greater part of its extent. Along the diaphragmatic curvature for a length of twenty to twenty-four inches, and at a few other points were numerous ulcerations, the majority as large as sixpence, surrounded by reddish aureolæ. In the small colon and small intestine were several similar ulcerations.

All the lymphatic glands in the abdominal cavity were enlarged; many showed softened caseous centres. The sublumbar lymphatic glands were relatively little swollen, but appeared caseous on section.

Thoracic Cavity: The lungs were enlarged, firm to the touch, and packed with recent greyish non-caseous granulations. The pulmonary tissue was unchanged except in the lower third of the lobes, which exhibited a zone of hepatisation. The bronchi and trachea showed no lesions. The bronchial glands were scarcely enlarged.

Like the epiploon, the mediastinum was thickened and covered with tubercles. The other portions of the pleura were little changed.

Both layers of the pericardium were thickened and dotted over with granulations. In the left heart the endocardium was whitish, thickened, furrowed, and contracted. The mitral and aortic valves were thickened and infiltrated. In the myocardium, below the anterior sigmoid valve, was a tuberculous abscess as large as a nut. The aorta and its branches showed several atheromatous patches. On bacteriological examination bacilli proved numerous in the caseous material from the lymphatic glands and in the fluid obtained by scraping the ulcerations, and fairly numerous in the pulmonary granulations, but rare in the endocardium. They were also discovered in the fæces.

With an emulsion prepared by crushing in sterilised water a fragment of the sublumbar lymphatic gland and a small tuberculous centre

from the epiploon, the following animals were intra-peritoneally injected:—a dog (5 cubic centimetres), a rabbit (2 cubic centimetres), two guinea-pigs (1 cubic centimetre), and two fowls (2 cubic centimetres).

The dog was killed on the 29th July, forty-seven days later.

Autopsy.—Numerous granulations on the peritoneum and epiploon. The latter was greatly indurated, being as thick as a man's hand in the neighbourhood of the spleen. Enlargement of the mesenteric, mediastinal, and tracheo-bronchial glands. Granulations in the liver and lung.

The rabbit died on the 25th September, 104 days after inoculation.

Autopsy.—Generalised tuberculosis. Enormous lesions in the peritoneum, epiploon, mesenteric glands, kidneys, testicle, and prostate.

One of the guinea-pigs died on the 25th June, after thirteen days. Bacteriological examination of the pulp of the liver and spleen revealed the presence of bacilli in these organs.

The other died on the 4th July, after twenty-two days. It was already much wasted, and showed lesions of tuberculosis in course of generalisation,—fine granulations in the peritoneum, hypertrophy of the epiploon, and granulations in the kidney and spleen, which last was five times its normal size. Two other guinea-pigs were injected with an emulsion prepared by crushing a little spleen pulp in sterilised water. The first died on the 1st October, after eighty-nine days; the other on the 13th October, after 101 days. Both showed on *post-mortem* generalised lesions with enormous enlargement of the spleen.

The fowls were killed on the 16th June, 1898, after two years and four months. No tuberculous lesion was found on *post-mortem*.

165. A ten-year-old grey cart mare, seen on the 8th January, 1898.

History.—During the last week of December, 1897, this animal appeared dull, unwell, and was not feeding. Several other horses in the stable were not thriving or eating well, but the above animal was the worst, and while medical treatment and better food improved the others this mare remained unaffected. There were no acute symptoms, but the disease appeared indefinite, chronic, and progressive.

State on Examination.—Appeared in fair condition, and at first sight showed no disquieting symptoms. Pulse 56 and of fair strength; respirations 25; temperature 103° F. Auscultation of the chest revealed a harsh respiratory murmur, indistinct towards the lower part; percussion everywhere indicated increased dulness, which towards the floor of the chest was almost absolute. Cough was almost completely absent.

Apart from the history of gradual onset and the comparatively slight fever and injection of the conjunctivæ this case might have been mistaken for influenza with supervening pneumonia. The symptoms failed to indicate the rapidity with which the disease was progressing until shortly before death on the 19th January.

Post-mortem Examination.—The lungs alone were diseased. The pleuræ were healthy, but the lungs on removal were very heavy and

felt very lumpy, owing to the presence of nodules varying in size between a bean and a bantam's egg. Some were cheesy throughout, others contained pus. All portions of the lung were diseased, the posterior and inferior borders, which were much thickened, being the parts most affected.

A portion of lung examined by Professor Dewar was yellowish white in colour, the pleura thickened and opaque, the parenchyma completely hepatised, or rather solidified, and requiring close and careful examination to identify it as lung. At first sight it seemed the product of an interstitial pneumonia. On section the parenchyma was of a light salmon colour, the interlobular tissue white and in some parts slightly translucent, but all completely solidified. Microscopic examination revealed numerous tubercle bacilli.

Note.—This case is interesting because (1) infection appears to have occurred by the respiratory tract, and not through the digestive organs; (2) the disease was confined to the lungs, not even the pleura (?) being attacked; (3) because of its acuteness; nothing was suspected until the end of December, within three weeks of which date the animal died.

Prof. Dewar's case, *Veterinarian*, 1898, p. 155.

TUBERCULOSIS IN A COW—INFLAMMATION OF THE OMASUM AND ULCERATION OF THE ABOMASUM.

166. A six-year-old shorthorn cow.

History.—Until within three days before examination the animal had appeared fairly healthy.

State on Examination.—Symptoms of advanced pulmonary and pleuritic tuberculosis, with pulmonary emphysema; the nose was protruded, the breathing laboured and accompanied by grunting; the chest was painful on palpation, and there was constant coughing. The anterior quarters of the udder were somewhat swollen and hard, the milk rather thin and slightly blue in tint. The appetite was moderately good. The bowels were relaxed. Temperature 106° F.; marked jugular pulse.

Microscopic examination of the milk failed to detect any tubercle bacilli. Tuberculin gave only a slight reaction.

The symptoms becoming aggravated, the animal was shot.

Autopsy.—The whole of the omentum was intensely hæmorrhagic and hyperæmic, the colour varying from bright red to a modena hue. Every stage of tubercular new growth, from bright red villous growths to yellow nodules, and even polypoid bodies were present. There was little peritoneal effusion, and comparatively few tubercular nodules on the peritoneum. The kidneys, liver, spleen, and pancreas were macroscopically free from tubercle, and the mesenteric glands only slightly affected.

The small and large bowels, except the cæcum, were healthy; the walls of the cæcum, however, were enormously thickened and inflamed, and the lumen of the gut materially diminished.

On opening the abomasum the pyloric portion showed consider-

able congestion and several circular ulcers with thickened bases, varying in size from a split pea to a sixpence. In addition, an intra-nasal growth of the size and shape of a pigeon's egg and homogeneous on section was detected.

The lungs were enormous, intimately adherent to the ribs, and riddled with tubercular broncho-pneumonia lesions; the right lung was œdematous.

The omental lesion was probably secondary to the pleural. The condition was evidently highly infective. The udder showed characteristic tubercular inflammation in the hardened and enlarged quarters. Professor Walley was unable to recall another instance of gastric lesions in the ox.

Prof. Walley's case, *Journ. Comp. Path. and Therap.*, 1893, p. 87.

TUBERCULOSIS OF THE CEREBRUM.

167. A five-year-old shorthorn cow, first seen August 29th, 1895.

History.—Had had three calves, the last on April 15th, 1895. About the end of June the animal had been out at grass, and appeared to be suffering from cold; it was treated and seemed to recover. On the evening of August 28th it fed well and yielded the ordinary amount of milk. On the 29th it was thought to be choking.

State on Examination.—Temperature 98° F., pulse 44, respirations hurried; bowels constipated; extremities very cold; the animal was coughing, and appeared very excited. The throat seemed swollen, and sore throat was suspected.

Treatment.—As water was readily swallowed, a purgative draught was administered. A cantharides blister was applied to the throat, the animal was well covered up, and linseed gruel was given to drink.

In the evening the temperature was 101° F., pulse 54. The nose was protruded and held high, the eyes appeared excited and the pupils were dilated. When gruel was offered the animal seemed anxious to drink, but could not put its nose in the bucket. It staggered when moved.

August 30th.—The eyes had become cloudy, there was marked strabismus and slight lachrymation. Some brain disease—probably a tumour—was diagnosed, but as some doubt was felt as to its exact nature, the poll was blistered, and cold applications made to the forehead.

August 31st.—The condition was much aggravated, and symptoms of paralysis gradually set in. Periods of excitation alternated with prostration. As the animal afterwards became comatose slaughter was advised.

The client continued the cold applications and gruel until next afternoon, when, losing hope, he had the animal killed.

Autopsy.—The head and neck alone were examined. On removing the skull-cap and incising the dura mater a quantity of sero-sanguineous fluid was found in the subdural space. Except for a certain amount of hyperæmia the meninges were normal.

The brain was much congested, showed hæmatoidin pigmentation,

and the right hemisphere appeared softened. In the anterior and upper portion of the left hemisphere a superficial depression was observed, the discoloration being more marked over that area. Incision through this depression revealed a very large tubercular nodule. The tumour was about the size of a walnut, caseated, and undergoing calcification. The cut surface was of a dirty yellow colour, and showed numerous calcareous particles, rather larger than coarse sand.

The submaxillary lymphatic glands were tuberculous.

Microscopic examination of the brain revealed the presence of tubercle bacilli.

Note.—The most striking points in the case are (1) the sudden development of symptoms, a characteristic also commonly noted in tuberculous children; (2) the subnormal temperature; (3) the absence of tubercular meningitis; and (4) the good bodily health and condition of the patient.

Mr. A. R. Routledge's case, *Veterinarian*, 1895, p. 504.

EXTERNAL LESIONS OF TUBERCULOSIS IN THE DOG.

168. A two-year-old Havanese bitch, brought for examination on the 1st May, 1894, suffering from a sinuous wound in the neck.

Three months before, a swelling had appeared in the upper part of this region, and had increased in size until it became as large as an egg. After poulticing it softened and ulcerated, discharging pus, at first freely, and afterwards in less quantity. The wound became sinuous, was treated by antiseptic injections, and had several times been laid open.

State on Examination.—The patient was fairly well nourished. On examining the abdominal and thoracic cavities no symptom suggesting tuberculosis was noted.

Over the median line of the larynx was a wound, as large as a sixpence, the margins of which were torn and irregular, separated from the deeper seated tissues, thickened, exuberantly granulating, at certain points thin, at others eroded, but in all parts covered with greyish viscous pus. Two little sinuses opened at the base of the wound and extended deeply along the sides of the trachea. Slightly below this first wound was another, similar in size, also sinuous in character, and separated from the first by a fragment of skin about two and a half inches wide. On the left surface of the neck, behind the lower portion of the parotid, was a cold abscess, as large as a hazel-nut. When punctured it discharged greyish watery pus, which, like that collected from the wounds, contained tubercle bacilli.

This animal was not left in hospital or brought back again for examination.

169. A four-year-old bitch, several times brought to the external clinique during the early part of 1894. Belonged to a tuberculous person.

Had been ill since the end of January. The owner had particularly noticed coughing and rapid emaciation, followed by diarrhœa and

dysentery. In March a nasal discharge, sometimes streaked with blood, appeared and continued until death.

At the commencement of April an abscess developed on the left side of the upper part of the neck. The wound left on puncture, refused to heal, and finally became sinuous. A fortnight later another abscess occurred on the opposite side, practically at the same level as the first. It opened spontaneously and became sinuous.

These sinuses, about one to one and a half inches in depth, suppurated somewhat abundantly for two months. The skin surrounding them was denuded of hair and separated from the subjacent tissues. The whole of the laryngeal region became swollen and indurated.

At the commencement of July appetite was entirely lost, and wasting made rapid progress. The patient died on the 17th July, 1894. The body was brought to the school.

Autopsy.—Diffuse pulmonary tuberculosis with formation of numerous cavernous spaces; inflammation of the tracheo-bronchial glands; tuberculosis of the liver.

The larynx and origin of the trachea were surrounded by a thick layer of tissue resembling sarcoma, excavated by several tracts. Sections through this tissue showed yellowish-grey tubercles and several little purulent centres. There was no apparent tuberculous lesion in the buccal, nasal, pharyngeal, or laryngeal mucous membranes.

Throughout the lower two thirds of the neck the lymphatic vessels were affected on either side of the trachea, several enlargements, the size of a haricot bean to that of a hazel-nut, being found.

Pus from the fistulæ contained numerous bacilli.

170. A seven-year-old spaniel bitch, brought for examination on the 6th April, 1895. Had been ill for three months previously. The principal symptoms were loss of appetite, wasting, and gradually advancing feebleness. About two months before the bitch had suffered for a fortnight from cough, and from a greyish discharge from both nostrils.

State on Examination.—The patient was exceedingly emaciated, feeble and dull, in fact, a characteristic example of advanced tuberculosis. Nothing abnormal could be detected on examining the abdominal cavity. The right wall of the chest, however, behind the shoulder showed an ovoid swelling, the longer axis of which was vertical, covering four ribs and the corresponding intercostal spaces. It was firm, and towards its periphery almost hard. Near the centre was a narrow sinus discharging greyish pus, in which microscopical examination detected tubercle bacilli.

The animal was left for observation, and was killed on the 15th April.

Autopsy.—Old-standing pulmonary tuberculosis with formation of cavernous spaces. Tuberculosis of the pleura; double parietal pleural adhesions. On the right side the costal pleura was much thickened and covered with vegetations. On incising it opposite the costal abscess a somewhat extensive cavity was opened, the internal wall

formed by the thickened pleura, the external by the eighth, ninth, and tenth ribs, which were denuded of pleura, inflamed, and at some points softened. Over the ninth and tenth intercostal spaces this cavity communicated with the external swelling seen during life. It contained a little greyish pus and fragments of necrotic tissue.

171. A fifteen-month-old spaniel, brought to Alfort on the 6th July, 1896, to be killed. Had been ill for about a year, and showed a suppurating wound on the neck, which had been unsuccessfully treated for a long time.

Autopsy.—Tuberculosis of the liver; old standing pulmonary tuberculosis with cavern formation. The wound in the neck, over the origin of the trachea, was rounded, ulcerated, and the size of a two-shilling piece. Its margins were denuded of hair, and the skin was thinned and separated from subjacent tissues. Its base showed a sinus, which extended as deep as the left retro-pharyngeal glands. These formed a swelling the size of a pigeon's egg, were hard, and firmly attached to the surrounding parts. The sinus had originated in several small purulent, caseating nodules at this point. The lower half of the left tonsil was destroyed by an ulcer, with a yellowish, finely granular base and indurated margins.

The tuberculous character of the wound in the neck, the inflammation of the retro-pharyngeal glands, and the ulcer in the tonsil was proved by the discovery of bacilli in each of these lesions.

TUBERCULOSIS IN THE CAT.

172. A one-year-old female cat, brought for examination on the 19th June, 1894.

The history was as follows:—About six weeks previously this cat had shown signs of chest disease, particularly cough and difficulty in respiration, followed by loss of appetite and wasting. For three days before the animal had not touched food.

This history, together with the results of clinical examination, and the chronic character of the disease, caused us to suspect tuberculosis. The owner would not allow the animal to be left, but brought it back, however, on the 7th July, when it was killed.

Autopsy.—Over the terminal portion of the small intestine were some tuberculous lymphatic glands, the size of hazel-nuts. In front of these were five smaller lymphatic glands arranged like a row of beads, parallel to the intestine. The epiploon showed a few tubercles as large as peas. The mucous membrane of the ileum exhibited two ulcerations: one, oval in form, with its longer diameter parallel to the intestine, measured half an inch in length and three eighths in breadth; the other was narrower, with indurated prominent margins. Liver large, crammed with greyish tubercles, the size of millet seeds, at certain points confluent; on the posterior surface of the organ hundreds could be counted. Spleen three times the normal size, both surfaces bosselated by tubercles, some as large as a pea. The lungs were firm, dense, fibrous, and greyish in colour; showed generalised

lesions in both lobes, and on section numerous tubercles and tracts of caseated pneumonia. All the lesions were very rich in bacilli.

173. An eight-year-old female cat, brought for examination the 2nd December, 1895; had been ill for several weeks. This cat belonged to a lady, one of whose children had died of tuberculosis a few months before. The animal was dull, weak, thin, and showed enlargement of the abdomen.

The enlargement was due to dropsy. The abdomen was punctured, and twelve and a half ounces of liquid, which gave a greyish deposit, were drawn off. No bacilli were discovered in this deposit on microscopic examination. Two guinea-pigs were intra-peritoneally injected with one cubic centimetre of the liquid.

On the 14th December the patient was brought back, the owner stating that it had improved, but that the ascites had returned. The abdomen was again punctured, about eight ounces of fluid, similar to the first, being removed.

The patient was not afterwards seen.

On the 15th January, 1896, the guinea-pigs were killed. On post-mortem tuberculous granulations were found in the liver and spleen, and on the peritoneum.

174. A seven-year-old cat, brought for examination March 17th, 1896. Had been ill for more than a year.

Belonged to a lady who died of tuberculosis. It had shown loss of appetite, cough, depression, a little nasal discharge, and progressive wasting. This cat seldom left its owner's rooms, passing the greater portion of its time in the bedroom. It was sometimes fed with meat, etc., left by its owner; sometimes with horse-flesh.

The animal was very greatly wasted; the respiration was rapid and difficult, and crepitant râles were noted on auscultating the lungs. It was left here and killed.

Autopsy.—Almost the whole of both pulmonary lobes was œdematous. Both on the surface and on sections numerous tubercles could be seen, some were firm, others softened and caseous. The lesions were rich in bacilli.

175. A three-year-old cat, brought for examination November 24th, 1896. It had been ill for several weeks; was dull, thin, and generally remained lying down. The appetite was capricious, sometimes the animal altogether refused food; it had been principally nourished on raw meat and milk. The excessive emaciation and the chronic character of the disease suggested tuberculosis. The owner, tired of nursing the animal, allowed it to be killed.

Autopsy.—The epiploon was dotted over with fine granulations. The terminal portion of the small intestine, the cæcum and first part of the colon were surrounded by an indurated mass, formed by enlarged lymphatic glands adhering to the walls of the intestine. Incision of the latter showed the mucous membrane to be thickened and ulcerated at several points. The tissue of the glandular swelling was

softened and at places caseous. The liver and spleen showed granulations; the pleura was dotted with vegetations, and both lungs contained recent tubercles. Bacilli were found in the pus from the swelling formed by the lymphatic glands.

TRANSMISSION OF PULMONARY TUBERCULOSIS FROM MAN TO THE CAT.

176. In June, 1887, Dr. Leon Petit described two cases of transmission of tuberculosis to dogs from their owners attacked with pulmonary phthisis. The first was that of a dog which ate the sputum, etc., of a phthisical person; the second referred to a dog which had lived for several months in a close room in which its mistress slowly died of phthisis. On autopsy both showed tuberculous pleurisy and invasion of the pulmonary tissue, and one in addition exhibited pneumothorax. Microscopic examination confirmed the diagnosis.

Somewhat later Dr. Petit had in his laboratory a female cat which greedily devoured the sputum of phthisical patients. All refuse of this kind was for experimental reasons given to it.

The animal soon grew thin, its coat stared, its eyes were bleared, it had a muco-purulent discharge from the nose, violent sneezing, and sometimes cough followed by vomiting. It crawled with difficulty, and appeared in the last stages of some chronic grave disease. Koch's bacillus was frequently detected in the discharges.

The animal was kept under close observation, and Dr. Petit was therefore greatly surprised when, two and a half months later, about the time of its becoming pregnant, the symptoms rapidly abated, and the animal seemed in a fair way to recovery. It still ate the sputum greedily. Somewhat later it bore seven well-developed kittens, one of which it suckled for five months. A slight dry, hacking cough persisted. Six months after delivery it was killed.

Autopsy.—The lower parts of both lungs were somewhat congested; a very frothy muco-sanguinolent liquid escaped from the bronchioles on section. In the lower part of the right lobe was a collection of small, hard cretaceous masses, which on manipulation produced a feeling like that of rubbing sand-paper. These little points were greyish and surrounded by a zone of paler colour than neighbouring parts. The apices of the lungs and the pleura were free of lesions, as were the visceral organs. Microscopic examination revealed the presence of Koch's bacilli.

Note.—Coincident with the onset of pregnancy the cat had begun to recover, and some time before being killed was practically cured.

Drs. Filbau and Petit's case, *Journ. Comp. Path. and Therap.*, 1888, p. 60; cf. *Journ. de Méd. de Paris*, January, 1888.

TRANSMISSION OF TUBERCULOSIS FROM MAN TO THE PAROQUET.

177. A green paroquet, belonging to M. A—, living at No. 9, Rue des Deux Ponts, Paris. Had been bought eight years before by M. A—, and kept in the suite of rooms occupied by him and his family. It had

seemed in good health until the end of December, 1894. At that time a small, greyish, firm, scaly swelling appeared on the right cheek, and gradually increased in size and prominence.

On the 1st January this tumour had been removed by a veterinary surgeon, who had not suspected its true nature. A fortnight later it had grown as large as before. The bird was brought here on the 19th January.

On the right side of the face, immediately behind the beak, was a horny, conical, greyish vegetation, slightly incurved towards its upper extremity, and of scaly appearance—a vegetation the appearance of which at once awakened suspicion of tuberculosis. It adhered only slightly to the skin, and was removed with forceps. The base appeared finely granular. Microscopical examination of a scraping from this surface revealed numerous bacilli.

Fig. 62.—Paroquet with cutaneous tuberculous growths.

On being questioned M. A— stated that during the course of 1894 he had contracted "bronchitis;" had coughed and expectorated a great deal from the month of August to that of December, 1894; that he had improved at that time, but that the disease had returned, and that in spite of various treatment he felt weak and oppressed. He was asked to expectorate into a glass, and with the purulent material contained in the expectorate two cover-glass preparations were made and stained by Ehrlich's method. Bacilli were found in large numbers. M. A— was exceedingly fond of this paroquet, which was very tame and affectionate. He liked to fondle it about the head and face with his lips, and in addition to feeding it daily by hand, sometimes fed it with masticated food.

We also learned that the paroquet was in the habit of rubbing its head against neighbouring objects, especially its master's hands and face.

Treatment.—Excision of the tumour, curettage and cauterisation of the diseased skin.

M. A— brought this paroquet back on the 12th February, 1895. The horny growth had again appeared. Between it and the eye another small swelling had developed. The same treatment was used as on the 19th January.

On the 2nd March the bird was again brought. Both swellings had again commenced to grow, and a third had appeared between the second and the upper part of the beak.

On the 16th April the paroquet was brought here a third time with three small horny growths (Fig. 62). A little later M. A— died. We did not afterwards see the bird.

To sum up: this paroquet had been bought by M. A— eight months

before, and had remained in excellent health until December, 1894. In April, 1894, M. A— coughed and expectorated. He suffered from "bronchitis;" in reality he was tuberculous. In December, 1894, the paroquet showed a tuberculous lesion on the face. Now it was the only bird kept in the rooms, and had never been in contact with any other bird whatever. Its food consisted only of seeds, coffee and milk, boiled milk, or food masticated by its owner. The inference is obvious.

BOTHRYOMYCOSIS.

178. A five-year-old gelding, left for examination on the 8th November, 1897. Was suffering from sinuses in the inguinal region following castration. Operation had been performed in April, seven

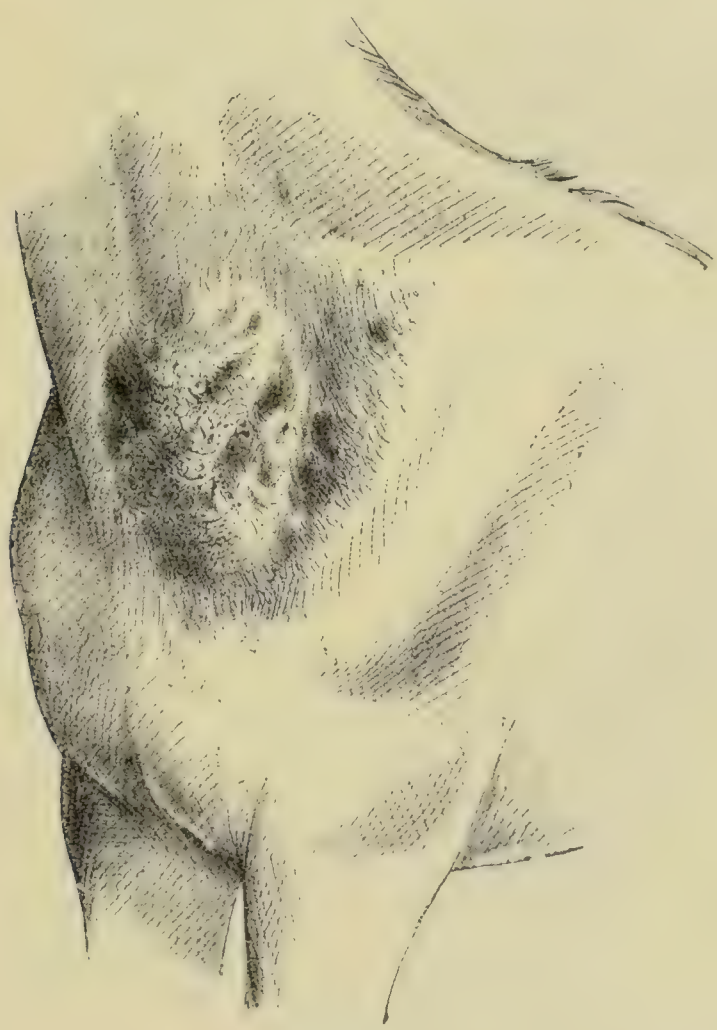

Fig. 63.—Bothryomycotic swelling of the shoulder.

months before. A fortnight afterwards the animal returned to work. The wound in the left inguinal region refused to heal, and suppurated freely until the commencement of July. It had been treated by injections of carbolic solution.

State on Examination.—The left inguinal region showed a circumscribed, sharply defined, hard, slightly painful swelling, traversed by

three sinuses, one of which opened at the base of the depression resulting from the operation wound. On direct manipulation the cord was found to be enlarged and indurated, forming a pear-shaped swelling, flattened below, where it was adherent to the envelopes, and contracted above, where it could be followed as high as the lower inguinal ring. On rectal exploration the intra-abdominal portion of the cord was found to be normal. Pus collected from the sinuous openings was greyish in colour, fairly consistent, and contained small yellowish-white granules, which, on microscopical examination, were seen to be formed by bothryomyces.

Treatment.—From the 8th to the 20th November, and from the 25th November to the 10th December, this horse received a daily dose of two and a half to four drachms of potassium iodide in its drinking-water. Each day the swelling was swabbed with iodine solution, and the sinuses injected with tincture of iodine. There was no improvement.

On the 10th December the tumour was removed, the cord being cut through with the écraseur. No dressing was applied.

During the following days the wound was cleansed night and morning with warm creolin solution. It healed rapidly and uninterruptedly. The animal returned to work at the end of three weeks.

179. An eight-year-old gelding, left in hospital the 27th September, 1898. Affected with swellings in different regions, the largest opposite the base of the neck. The disease had been in existence for nearly a year.

Swelling had first appeared in front of the left shoulder, and had been followed by further growths. As the swelling on the shoulder became so large as to prevent the animal being worked, it was sent to Alfort for operation.

State on Entry.—On the sides of the thorax and neck were small nodules varying in size between a nut and a small egg, almost all pierced with sinuous tracts discharging pus, in which bothryomyces were found on microscopical examination. The largest was situated over the jugular furrow. It measured ten inches in a vertical and six inches in a horizontal direction, and was formed of firm, resistent tissue. Its upper part was only slightly adherent to subjacent tissues; but its lower penetrated more deeply, and had become intimately adherent to the deep-seated tissues as well as to the skin. The swelling showed elevations and depressions, and was penetrated by several sinuous openings discharging pus, in which numerous little bothryomycotic granulations could be detected.

Treatment.—Before resorting to operation two and a half drachms of potassium iodide were given daily in the drinking-water, while the swelling was swabbed and the sinuses injected with tincture of iodine. This treatment was continued until the 13th October without the slightest success. The owner saw the horse on that date, and asked us to operate.

Next day the horse was cast on the straw bed. The parts having been prepared and disinfected the growth was excised.

The upper part, which was easy to separate from adjacent tissues, was first removed; the lower, which extended more deeply and surrounded the jugular and carotid, could not be entirely ablated. Operation was attended by considerable hæmorrhage, which was controlled by forceps. The portion of the tumour surrounding the vessels was left in position. After inserting a drainage-tube the lips of the wound were brought together by a few deep and several superficial sutures, and the parts were covered with a cotton-wool dressing.

In spite of precautions taken to prevent the animal rubbing, it soon displaced the dressing and tore out most of the sutures. Being very irritable, we were obliged to leave the wound open and treat it antiseptically. Nevertheless the animal was able to leave hospital on the 20th, the final result of operation having been highly satisfactory.

Remark.—The administration of potassium iodide in the treatment of bothryomycosis is of slight value. I have used it in twenty-four cases (horses), sixteen suffering from scirrhous cord, and eight from bothryomycotic growths in different regions:—one in front of the chest; two on the neck; one on the tail; one on the side of the chest; one on the hock; and two on the fetlock. The average duration of treatment was three weeks, and the average dose of potassium iodide from six to eight ounces. In certain of these patients the treatment was only continued for a fortnight; in others it was prolonged, with intervals, for six weeks, two months, and even longer. In 1897 I treated a horse with bothryomycosis of the hock (Fig. 64) for more than four months, giving during that time more than twenty ounces of potassium iodide without producing any appreciable result.

Fig. 64.—Bothryomycosis of the hock.

In three animals with recent scirrhous cord the swelling diminished with considerable rapidity, and finally disappeared; but all practitioners know that cases of recent inflammation of the cord often recover with ordinary local antiseptic treatment. In a horse with a bothryomycotic patch on the wall of the

chest swelling notably diminished at the end of a month, when the animal returned to work, but as treatment was afterwards neglected the swelling became as large as at first. In twenty other patients administration of potassium iodide appeared without action, or produced only trifling effects, quite unsatisfactory from a practical point of view. All the well-developed or old-standing cases of scirrhous cord had finally to undergo operation.

These results, and the cases published by Fröhner, confirm what I have already stated concerning bothryomycosis, viz. that radical operation should be preferred whenever possible.

PNEUMONIA.

180. A six-year-old mare entered hospital February 28th, 1898. At the beginning of February the off fore-coronet had been injured, and the animal had been treated for a week in a veterinary infirmary. During the two days previous to entry it had appeared stiff, had coughed, and only eaten a part of its food.

State on Entry.—The animal was depressed, carried the head low or rested it on the manger. The conjunctiva was dull yellow; the mouth hot and dry; the appetite in abeyance; temperature 40·6° C.; respiration 18; pulse 61. Respiration was interrupted, and at times accompanied by groaning. The pulse was small. On auscultation a strong vesicular murmur could be heard over the entire area of both pulmonary lobes.

Treatment.—Mustard applications to the chest; three and a half ounces of sodium bicarbonate in the drinking-water.

On the 1st March the general condition was little changed. Temperature 41·2° C.; respiration 21; pulse 58. Appetite moderate; cough deep and somewhat strong; mucous discharge from the nostrils. The lower part of the left lung showed some dulness on percussion. On auscultation the vesicular murmur was lessened in the lower, and increased in the upper regions. Nothing abnormal could be detected in the right lung. In the evening the lower part of the left side of the thorax was dull. On auscultation the vesicular murmur was inaudible.

On the morning of the 2nd, temperature 40° C.; respiration 30; pulse 80. The zone of dulness had increased, extending to the middle line of the chest; the lower chest region was silent on auscultation; towards the upper part a slight tubal murmur could be heard. The heart-beats were feeble, irregular, and intermittent, the first sound double. Five fluid ounces of serum from an animal which had recently recovered from pneumonia were subcutaneously injected.

On the 3rd June the condition was improved. The animal was brighter and ate all its food. Temperature 40·4° C.; respiration 24; pulse 72. The respiration was less painful, the dulness stationary, and the tubal murmur more clearly defined. The heart-beats were more regular. Urine was abuudantly passed, and the bowels were freely open. Five fluid ounces of serum were injected.

On the 4th the general condition was stationary. Temperature

38·9° C.; respiration 26; pulse 54. The zone of dulness extended over two thirds of the lower chest region. The pulse was strong and large. The urine contained no albumen. Five ounces of serum were again injected.

On the 5th there was marked improvement; the animal showed less depression, and appetite was good. Temperature 38·5° C.; respiration 24; pulse 58. At the uppper part of the hepatised zone dulness was less marked, and was replaced by a moist crepitant râle. Five fluid ounces of serum were injected.

On the 7th the temperature was 38° C. The crepitant râle peculiar to resolution was heard over all the lower part of the left lung. The cough was soft, and a serous discharge ran from the nose. The injections of serum were stopped.

During the next two days the last unfavourable symptoms disappeared. On the 10th the vesicular murmur extended over the entire area of the lung.

Remark.—In the horse and in a certain number of other patients suffering from pneumonia I have during the past three years employed serum obtained from animals recently recovered from pneumonia, and usually with good effect. In doses of 3 to 6 fluid ounces per day it forms a useful addition to the classic treatment.

181. A six-year-old entire horse from a stable in which several horses had died from contagious pneumonia, entered hospital December 19th, 1898.

On the 17th December this horse had only eaten part of its morning feed. During the next two days appetite was in abeyance, and breathing became more rapid. Was left in hospital on the evening of the 19th.

State on Examination.—The patient had scarcely entered its stall before it began to feed. It was relatively little depressed. The mucous membranes were greatly swollen and infiltrated; the respiration was rapid (25 per minute); expiration was double. The pulse was 60, feeble and thready. The cough produced by pressing on the larynx was strong, deep, and repeated. Nothing could be discovered on percussion of the thorax. On auscultating the middle portion of both pulmonary lobes mucous râles were heard. The vesicular murmur was diminished in the lower portion of the left lobe, but exaggerated throughout the rest of this lobe and the whole of the right.

Treatment.—Mustard applications to the lower part of the thorax; 6 fluid ounces of alcohol and 4 ounces of sodium sulphate in the drinking-water.

On the 20th the general condition remained unchanged; appetite was fair. On auscultation and percussion the physical signs were as before. Respirations 25, pulse 65, temperature 40·9° C. In addition to the foregoing medicine 5 drachms of hydrobromate of quinine were given in two doses.

On the 21st the general condition was stationary. Respirations 28, pulse 72, temperature 40·5° C. In order to estimate the antithermic action of quinine, the animal's temperature was taken each hour during

the day. Administration of the first dose of quinine was followed by a depression of temperature, which reached its maximum (1·4° C.) at the end of an hour. Two hours later the temperature had risen to its

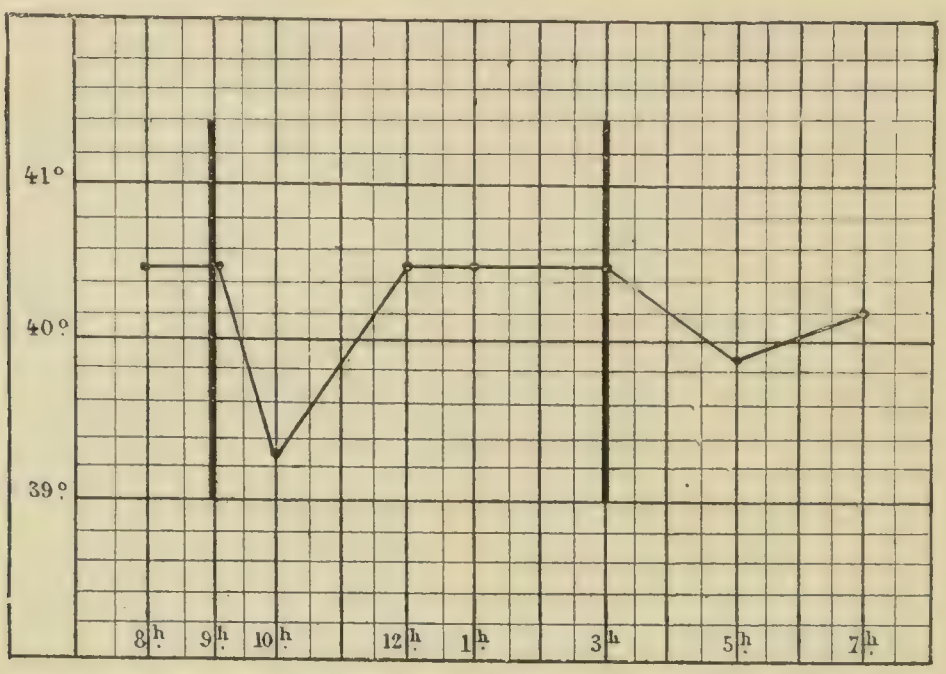

CHART I.—The dark vertical lines indicate the time at which quinine was given.

former point. After administration of the second dose the temperature fell six tenths of a degree C. in two hours; but two hours later it had returned to 40·2° C., only two tenths below the first reading (Chart 1).

On the 22nd the animal's state was little changed. Respirations 28, pulse 68, temperature 40·5° C. A little rusty discharge from both nostrils and some crepitant râles on auscultation. The first dose of quinine again lowered the temperature eight tenths of a degree in two

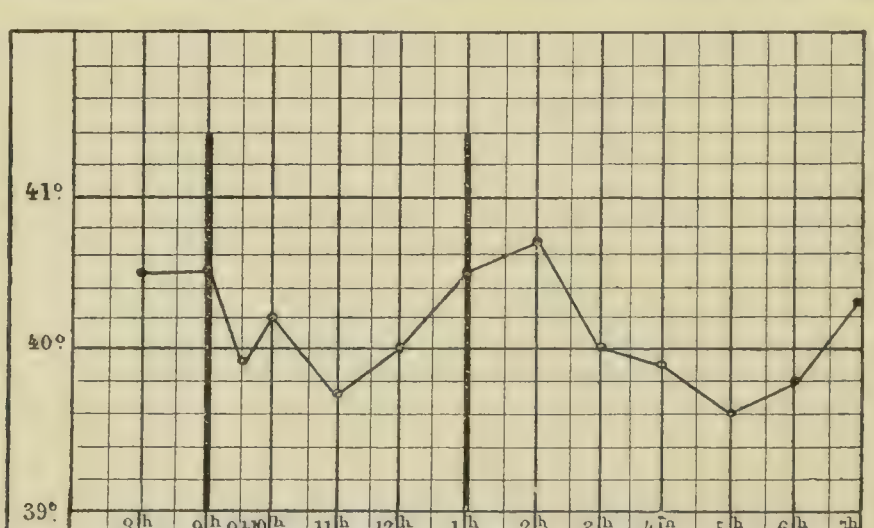

CHART II.

hours; but the curve afterwards rose, returning in two hours to its former height (40·5° C.). The second dose was followed an hour after administration by a rise of two tenths of a degree; three hours later

the temperature fell to 39·6° C. (depression of nine tenths of a degree). Six hours afterwards it had returned to 40·3° C. (Chart 2).

On the 23rd the patient was again dull, hung back from the manger, and left part of its food. Respirations 28, pulse 69, temperature 40·7° C. Dulness and tubal murmur in the lower part of the left lung. During the day the animal took five quarts of milk. The first dose of quinine produced a depression of five tenths of a degree in two hours,

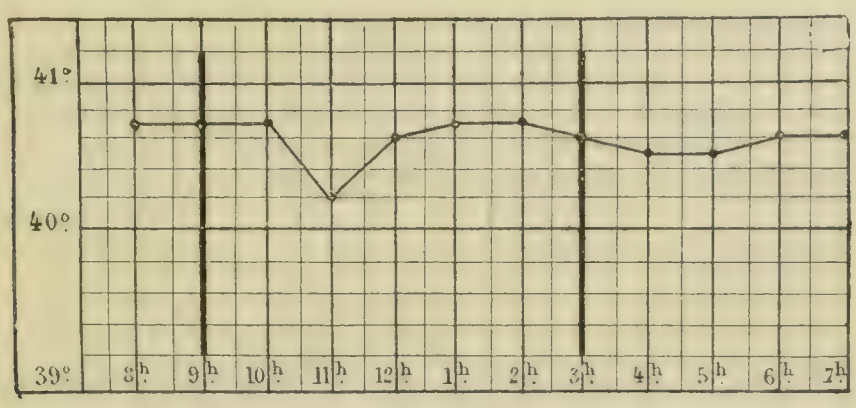

CHART III.

but less than two hours afterwards the temperature had returned to its former point. The effect of the second dose was less marked. The temperature fell one tenth at the end of an hour, but one hour later it again rose (Chart 3).

On the 24th the general condition was more satisfactory. The animal ate well, and drank milk greedily. Respirations 28, pulse 70, temperature 40·5° C. The clinical signs obtained by percussion and auscultation were similar to those noted on the previous evening. In

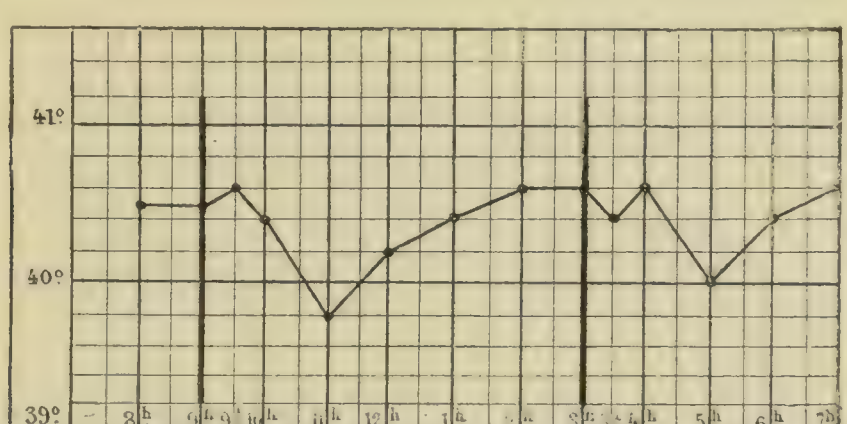

CHART IV.

the morning the quinine produced a depression of seven tenths of a degree two hours after administration, followed by a rise; in the evening a depression of five tenths in two hours, succeeded by a return to the previous height at the third hour (Chart 4).

On the 25th the general condition was good. Respirations 29, pulse 68, temperature 40·2° C. Marked tubal murmur. The heart-

beats were unequal and the pulse feeble. Quinine was discontinued, and $1\frac{1}{4}$ drachms of digitalis given in electuary.

On the 26th the general state was similar to that of the previous evening. The temperature began to fall. Respirations 26, pulse 72, temperature 39·7° C. The heart's action was more regular, the pulse larger and stronger.

On the 27th the general condition was still better than on the preceding days. Respirations 24, pulse 60, temperature 38·5° C. The murmur remained ; dulness was stationary.

On the 28th the general condition was excellent. Respirations 20, pulse 52, temperature 38·2° C. The cough had become easier and more frequent. There was some dulness on percussion, and the crepitant râle peculiar to resolution had returned.

During the following days the last troubles disappeared. The animal left hospital entirely cured on the 7th January.

182. A twelve-year-old entire horse, entered hospital January 26th, 1899. Had come from a stable in which contagious pneumonia was rife, four animals having been affected and two having died. On the evening of the 25th, after a hard day's work, this animal had refused its food, breathing had become rapid, and the animal had shown slight shivering fits. Brought to the College next day.

State on Examination.—The animal was depressed, and took no notice of what passed around it. The gait was careless, the limbs

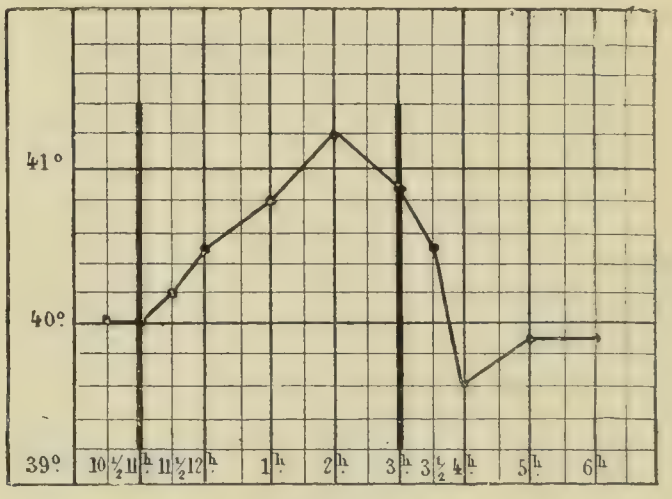

CHART V.

dragged along the ground. The skin was warm, the conjunctiva injected, the pulse 70, feeble and soft, the respirations 20, and the temperature 40° C. Pressure on the larynx produced a deep cough ; a little brownish discharge ran from the nostrils. On percussion the thorax was normally resonant. Auscultation detected exaggerated vesicular murmur throughout the depth of both pulmonary lobes.

Treatment.—Mustard applications to the lower portion of the chest ; internal administration of $3\frac{1}{2}$ ounces of sodium bicarbonate, 5 drachms sulphate of quinine in two doses, and $3\frac{1}{2}$ fluid ounces of alcohol.

At 11 a.m. on the 26th January the temperature was 40° C. Two

and a half drachms of quinine sulphate were given in electuary. At 11.30 the temperature was 40·3° C., at midday 40·5° C., at 1 o clock 40·8° C., at 2 o'clock 40·3° C. In three hours the temperature had risen 1·2° C. Concurrently with this rise in temperature excitement had been shown during the first two hours. There was anxiety, trembling, marked acceleration of breathing, and excessive dilatation of the nostrils. After the first two hours the temperature gradually decreased. At 3 o'clock it became 40·9° C. The second dose of electuary was given. During the following hour the temperature continued to fall. At 3.30 it was 40·5° C., at 4 p.m. 39·6° C. From 4 p.m. until 6 p.m. it rose three tenths of a degree (Chart 5).

Next day the general condition was stationary, the disease taking its usual course. Temperature 39·9° C.; respiration 18; pulse 60. The pulse was small; the conjunctiva remained injected. On auscultation the respiratory murmur was markedly diminished in the lower part of the right lung, which was also dull on percussion. Over the upper part of this lobe, and the whole of the left lung, the vesi-

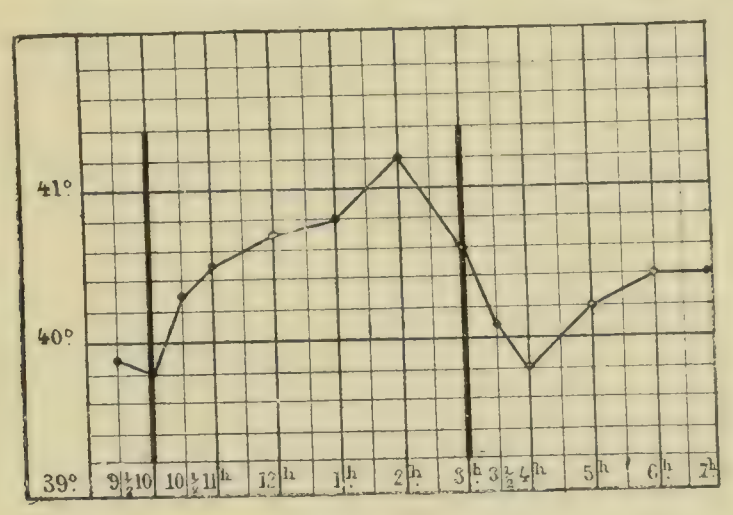

CHART VI.

cular murmur was exaggerated. The cough was rough, deep, and sometimes paroxysmal. An abundant rust-coloured discharge ran from both nostrils.

As on the previous days the animal received three and a half ounces of sodium bicarbonate and five drachms of quinine sulphate in two doses. The temperature curve on that day closely resembled the first. The first dose of quinine was followed by a rise in temperature of 1·3° C. in four hours. At three o'clock the temperature was 40·6° C. A second dose of quinine sulphate was given. An hour later the temperature fell to 39·8° C., but the depression was not maintained, for at seven p.m. the temperature marked 40·4° C. (Chart 6). The excitement, rigors, and trembling fits noted on the previous day were repeated.

On the 28th the morning temperature was 40·6° C., the pulse 80, and the respirations 25. The pulse was feeble, respiration painful, and expiration double. The cough still remained frequent and paroxysmal, and the rust-coloured discharge was somewhat free. Percussion

revealed a zone of dulness in the lower half of the right lung. At this level a moist crepitant râle was heard. The heart's action was somewhat weak, and both sounds were diminished.

The patient took milk and gruel, but hardly touched oats or hay. Treatment was modified by giving three subcutaneous injections of 80 minims of ether, and 1 drachm of digitalis, and applying mustard plasters to both legs. The dose of quinine sulphate was reduced to 1½ drachms. The temperature at 9 a.m. was 40·4° C.; at 10, 40·5° C.; and at 11, 40·6° C. One and a quarter drachms of quinine were then given. At 11.30 the temperature was 40·0° C., at midday 39·8° C., at 1 p.m. 39·5° C.; at 2, 39·3° C. There was no excitement. At 3 p.m. the temperature was 39·8° C. One and a quarter drachms of quinine were then given. At 3.30 p.m. the temperature was 39·1° C.; at 4, 39·2° C. During the next hour the temperature rose sharply. At 5 p.m. it was 40·3° C.; at 6, 40·7° C.; and at 7 p.m. 40·2° C. (Chart 7).

On the 29th the patient was greatly depressed. The fore-limbs were abducted, the head held low and rested on the manger. The animal took ten quarts of milk, but refused other food. Temperature

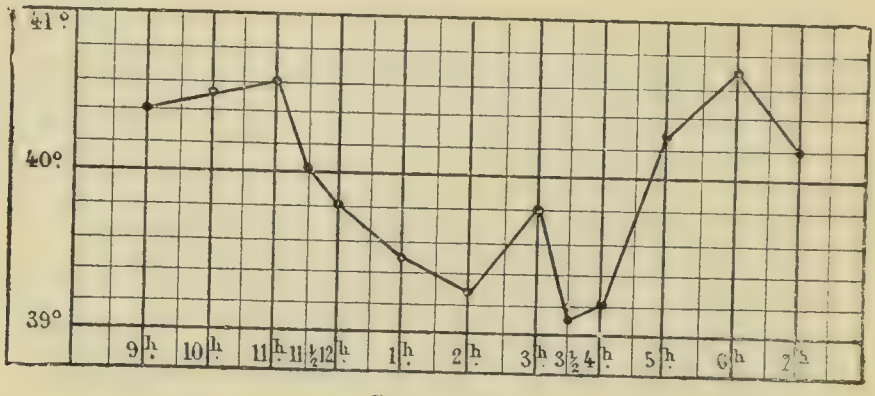

CHART VII.

40·2° C.; respiration 30; pulse very rapid, and perceptible with difficulty. Dyspnœa was intense, and expiration jerky. On the right side dulness was complete over more than half the chest. On auscultation a strong tubal murmur could be heard.

Treatment.—Bicarbonate of soda, sulphate of quinine, digitalis, injections of ether. After the second dose of quinine the temperature fell 1 degree.

On the 30th the general condition was better than on the previous evening. The temperature varied between 39·3° and 40° C.; the respiration continued rapid and irregular; the pulmonary dulness and murmur showed no change. Treatment was continued as before. After the first dose of quinine a slight rise in temperature occurred. After the second the temperature fell 1·3° C. in an hour, after which it gradually rose again.

On the 31st the improvement noted on the previous evening became more marked. Morning temperature 39·5° C.; respiration 21; pulse 63. The zone of dulness had diminished. On auscultation

the tubal murmur was still heard. The pulse became stronger; the patient was brighter than on the previous days, and ate a little hay.

On the 1st February the condition remained stationary. Morning temperature 39·7° C.; respiration 20°. The dulness and bronchial murmur remained. There were signs of cardiac weakness.

On the 2nd the patient appeared greatly depressed. It was feeble and tottered on its legs, so that it had to lean for support against the side of the stall. Temperature 39·2° C.; respiration 33; pulse very rapid and small. Dulness was limited to the lower third of the chest; the tubal murmur was weaker. The animal refused all food, including even milk. During the night it lay down on its side.

Next day it was found standing up eating some hay. It showed a little opposition when we attempted to auscultate the chest. The zone of dulness was limited to the lower half of the right lung; above this the crepitant râle peculiar to resolution could be detected. Temperature 38·7° C.; respiration 15: pulse 80.

On the 4th the temperature was 38·2° C., respiration 12, and pulse 64; the pulse still remained feeble. The animal received three injections of eighty minims of ether and one drachm of digitalis in electuary.

On the 5th and 6th the temperature and respiration became normal; the pulse was still 60, but fairly good.

The last symptoms disappeared during the following days. On the 11th February the animal had recovered.

183. A six-year-old entire horse entered hospital March 10th, 1899, after an illness of two days. Had come from a stable in which contagious pneumonia existed.

State on Examination.—The animal was depressed, showed rigors, and hung back from the manger. The mouth was hot, the skin cold, and the mucous membranes markedly injected. Respiration 24; pulse 75; temperature 40·5° C. The cough was strong and dry. There was little discharge. Pressure over the intercostal spaces caused pain. Respiration was irregular, expiration being slow and double. The lower quarter of the right lung was partially dull on percussion, but on auscultation the vesicular murmur was found to have disappeared; during expiration a few moist crepitant râles could be heard. In the upper part of the right, and over the entire area of the left lung the vesicular murmur was exaggerated. The pulse was feeble; the heart-sounds were strong and rhythmical, but at varying intervals a pause, equal in duration to a complete heart cycle, was noted.

Treatment.—Mustard applications to the chest; sulphate and bicarbonate of soda; alcohol. The mustard plaster produced a large swelling within four hours of application. The rectal temperature was 39·8° C. Appetite was preserved; the patient took several quantities of gruel and 8 quarts of milk. There was no noteworthy change during the evening. Temperature 40·3° C.

On the 11th the animal was more depressed than on the previous evening. The conjuctiva was deep yellow. Respiration 22; pulse 76; temperature 40·1° C. Inspiration was short, expiration prolonged and double. The lower part of the right lung was dull, and on ausculta-

tion silent. Above the dull zone the crepitant râle was more marked than on the previous evening. The pulse was scarcely perceptible though the heart-sounds were strong. Four drachms of quinine sulphate in two doses was added to the treatment. The first dose produced a depression of one degree in temperature at the third hour, but two hours later the temperature had returned to its former point. In the evening the quinine produced a similar result. The rectal temperature did not rise beyond 40° C.

On the 12th the general condition remained stationary. Respiration 26; pulse 72; temperature 39·9° C. A slight cough occasionally occurred. All the lower part of the right lung up to the level of the point of the elbow had become dull. Above this, crepitation was audible both during inspiration and expiration, but most markedly during inspiration. In the upper part of this lobe and throughout the left lung the vesicular murmur was exaggerated. The character and rhythm of the heart-sounds were modified; the first sound was strong, the second feeble; every three or four contractions were followed by a pause, lasting as long as a complete heart cycle. One drachm of digitalis was added to the former treatment. The quinine sulphate produced variations in temperature as on the previous day.

On the 13th the patient was prostrate and refused all food. The extremities were cold. Respiration 28; pulse 76; temperature 39·8° C. The zone of dulness was stationary. On auscultation borborygmus was heard far in advance of the diaphragm. Crepitation was increased and a slight tubal murmur could be heard. The cardiac pauses were more frequent, and occurred after every two or three beats. The pulse was feeble and intermittent, in sympathy with the heart The urine contained 18 grains of albumen per pint.

The weather being mild and bright, the animal was led from its stall and fastened in the open air from midday to 3 p.m. On returning to the stable it began to eat. The respiration was less rapid and difficult, the pulse good; the temperature remained at 39·7° C. Sulphate of quinine in similar doses as on the previous day produced no sensible diminution.

On the 14th the general condition had improved. The animal took several quantities of gruel, ate its hay, and drank 8 quarts of milk. Respiration 22; pulse 72; temperature 39·6° C. The condition of the chest remained as on the previous day, though a few crepitant râles were heard at points. The irregularity of the heart continued.

Treatment.—Sulphate and bicarbonate of soda were administered, but the alcohol, sulphate of quinine, and digitalis were discontinued.

On the 15th improvement was more marked. The animal took note of its surroundings. Respiration 20; pulse 68; temperature 39·4° C. Respiration was freer, the zone of dulness lower, and moist crepitant râles occurred over a large surface. The cough was loose and paroxysmal, and accompanied by discharge. The cardiac pauses were less frequent and longer than at first. They lasted considerably longer than a cardiac cycle; the second sound continued feeble, and was sometimes imperceptible. There was no dulness, though still some moist crepitant râles.

On the 16th improvement became more pronounced. Respiration 18; pulse 58; temperature 38·9° C.

During the following days the last symptoms disappeared, the cardiac intermittency becoming less and less frequent until it finally disappeared.

On the 25th the animal left hospital entirely cured.

184. A seven-year-old mare left in hospital April 11th, 1899. Had come from a stable in which contagious pneumonia was raging; affected three days before entry. The animal only ate part of its food, but suffered from a cough. There was no other history.

Condition on Entry.—The animal moved stiffly. The eye was retracted into the orbit and half covered by the upper lid; the conjunctiva was hyperæmic and infiltrated; the extremities were cold. Respiration 36; pulse 84; temperature 41·1° C. The pulse was fairly strong. The cough was infrequent, and when produced by pressing on the larynx was small, dry, paroxysmal, and inclined to return. There was a somewhat abundant rusty discharge. The lower part of the right lung was dull, and at this point borborygmus, heart-sounds, and some crepitant râles could be heard on auscultation. At the junction of the lower and middle thirds crepitant and mucous râles were audible; and in the upper part, and over the whole of the left lung, the vesicular murmur was strong. Except that it contracted with unusual suddenness and force, the heart revealed nothing noteworthy.

Treatment.—Bleeding, mustard application to the chest, quinine sulphate four drachms, sodium bicarbonate three and a half ounces. Evening temperature 40·6° C.

Next day the patient appeared less depressed. Respiration 36; pulse 80; temperature 40·5° C. Percussion showed increase in the zone of dulness, especially in front. On auscultation a slight tubal murmur was heard. Left lung normal. At 9.30 a.m. the thermometer marked 40·5° C. Two and a half drachms of quinine sulphate were given in electuary. At 10.30 a.m. and during the next two hours temperature 40·8° C.; at 1 p.m. 40·7° C.; at 2 p.m. 40·5° C.; at 3 p.m. 40·2° C.; at 4 p.m. 40·4° C. The second dose was then given. At 4.30 p.m. temperature 40·6° C.; at 5 p.m. 40·7° C.; at 7 p.m. 40·4° C.; at 8.30 p.m. 40·2° C. The urine, which was very deep in colour, contained eighteen grains of albumen per pint.

On the 13th April the general condition was bad. The animal lay on the right side, and was unable to rise without assistance. Respiration 36; pulse 76; temperature 40° C. The conjunctiva still remained deeply injected. The respiration was short and sighing. On percussion and auscultation of the chest the physical signs were as on the previous evening, except that the murmur was somewhat stronger. The heart-sounds were weaker. During the day three subcutaneous injections of two and a half drachms of ether were given; four drachms of quinine were administered in two doses. At 9.30 a.m., before the first dose, the temperature was 40° C.; at 10 a.m. 40° C.; at 11 a.m. 39·8° C.; at midday 39·6° C.; at 1 p.m. 39·5° C.; at 2 p.m. 39·4° C.

The animal lay down, but rose at the end of an hour. At this time the temperature was 40·3° C.; at 4 p.m. 40·6° C. The second dose of quinine was given. Temperature at 5 p.m. 40·4° C.; at 6 p.m. 40·5° C.; at 8.30 p.m. 40·2° C.

On the 14th the general condition remained stationary. Temperature 39·3° C. Respiration was still more rapid and sighing. The pulmonary dulness was unaltered, the tubal murmur strong. The left lobe remained normal.

The heart showed signs of weakness and irregular intermittency; the second sound was diminished, and almost lost at certain moments. The patient took the greater part of its food. One and a quarter drachms of digitalis were added to its medicine. At 9 a.m., the temperature being 39·3° C., two drachms of quinine sulphate were given. Temperature at 10 a.m. 38·9° C.; at 11 a.m. 38·8° C.; at midday 38·6° C.; at 1 p.m. 39·1° C.; at 3 p.m. 39·0° C. At 4 p.m. the second dose of two drachms of quinine was given. At 5.30 p.m. the temperature was 39·1° C.; at 6 p.m. 39° C.; at 8 p.m. 39° C. The animal was very weak, and during the day lay down several times. It received three subcutaneous injections of two and a half drachms of ether.

On the 15th it was still greatly depressed. Temperature 39·4° to 39·8° C.; respiration 48; pulse 76. The lower half of the right lung remained dull on percussion, though to a less degree at certain points. Over the tenth and eleventh ribs, near the (vertical) centre of the chest, was an area of tympanic resonance as large as the palm of a man's hand. On auscultation crepitant râles were heard in the posterior portion of the lung, and mucous râles about the centre. The left lung appeared normal on auscultation. The first heart-sound had a metallic ring, the second was dull. The cough was strong and loud. A little whitish discharge ran from the nostrils. One drachm of digitalis, three and a half ounces of sodium bicarbonate, three and a half fluid ounces of alcohol, and carbolic enemata were given.

On the 16th the temperature was 39·4° C. Respiration was less rapid, but continued short and sighing. Crepitant râles were heard in the upper thirds of the right lung, but in the lower third only heart-sounds could be detected. Cough was frequent. During the night the animal lay down on the right side, and showed so much excitement that a fatal issue was feared. It was lifted and placed in slings.

On the 17th respiration 30; temperature 39·8° C. Crepitation, alternating with localised liquid sounds, was heard over the entire area of the right lung. The heart-beats were scarcely perceptible. The pulse could not be counted.

Treatment as on the previous day. The allowance of hay was eaten; the gruel, etc., refused. The urine still remained albuminous.

On the 18th weakness was extreme. Temperature 39·6° C. Auscultation of the right lung revealed the same liquid sounds as on the previous day. The animal's hind legs seemed painful. At 9 a.m. it was taken out. It moved with difficulty. The right hind limb was paralysed, the joints yielded, and the limb rested on the fetlock whenever weight was placed on it. The symptoms resembled those of paralysis of the great sciatic. The patient refused to walk, and leaned

against the wall. Sensation was lost throughout the affected limb except in the region served by the femoral nerve; it was intact in the left limb and in all the other hind parts. At 3 p.m. the animal lay down on the left side, became greatly excited; respiration was moaning, and death occurred during the night.

Autopsy.—Muscles pale; mesentery and epiploon congested; liver large, friable, and of pale colour; spleen and kidneys normal.

In the pleural sac was a little yellowish serosity. The right lung had not collapsed, but adhered by its anterior lobe to the costal pleura, and by its postero-inferior part to the mediastinum. It showed lesions of lobular pneumonia. According to the point chosen it appeared black, bluish, deep red, bright red, or greyish in colour, the tints corresponding to centres of hepatisation, œdema, or emphysema. Palpation revealed dense hepatised areas, separated by yielding tracts of healthy pulmonary tissue. Sections of the upper and posterior parts appeared emphysematous, congested, or œdematous, according to the point chosen; the middle region showed hepatised areas, purulent centres, and œdema. One of the abscesses contained a fragment of necrotic tissue as large as an orange. Some of the bronchioles were obstructed by fibrinous clots. The left lung was unaffected. The

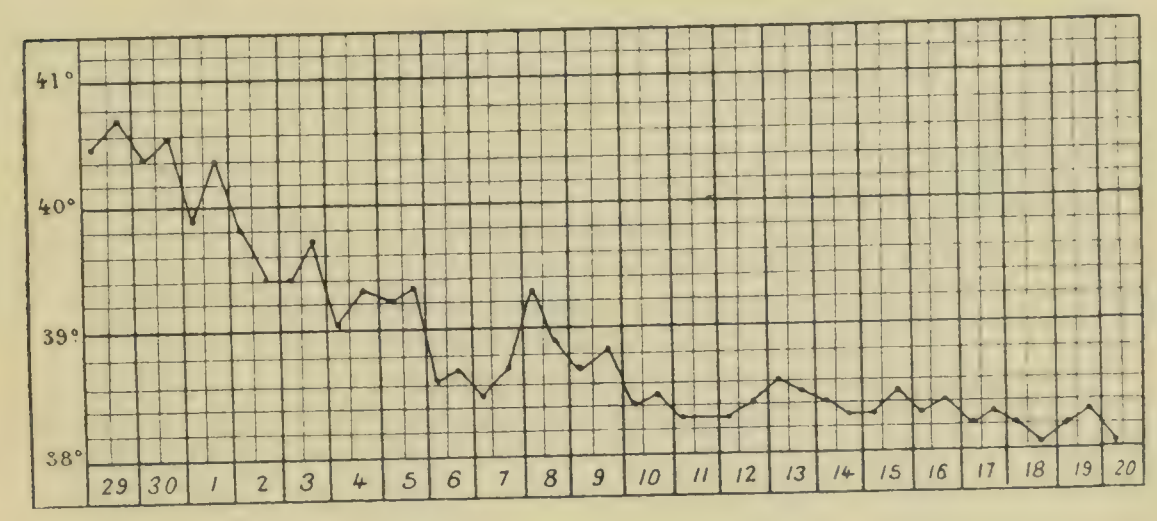

CHART VIII.

hepatised centres in the right lobe contained large numbers of different bacteria, streptococci and staphylococci predominating.

The heart was large, and showed ecchymoses along the vascular furrows, particularly at the base of the ventricles. It was discoloured, the greater part of the left ventricle being stained yellow, but the coloration was less marked over the right. Sections were deep red, pale red, or yellowish in colour. On laying open the left ventricle the decoloration of the myocardium was very striking; the muscle appeared greyish yellow, and was dotted with ecchymotic patches under the endocardium and pericardium. Its tissue was infiltrated: the surface of sections was covered with a viscous exudate. The mitral valves were intact; the aortic sigmoid valves were thickened and infiltrated, showed a few light red spots at their base, and several little hard,

fibrous patches, which, however, were of earlier date than the pulmonary disease. The endocardium and valves of the right side appeared unaffected. The great sciatic nerve of the right side was exposed throughout; its upper part displayed a few disseminated hæmorrhagic points. The spinal cord appeared normal. Microscopic examination of the cardiac and nervous tissues failed to reveal the presence of microbes, and inoculation of gelatin and agar with scrapings from these tissues produced no growths.

Remarks.—In equine pneumonia, quinine sulphate in doses of $1\frac{1}{4}$ to $2\frac{1}{2}$ drachms, according to the size of the patient, repeated twice a day, usually causes temporary lowering of temperature. Excessive doses produce excitement and hyperthermia, as in Case 182, where the animal was of medium size, and $2\frac{1}{2}$ drachms was an overdose.

185. A six-year-old entire horse, bought six weeks before, and left in hospital April 29th, 1899. Had been kept in a stable where outbreaks of pneumonia were frequent. In consequence of an attack of acute enteritis at the commencement of April it had been rested for nearly three weeks. On the 27th April it showed symptoms suggestive of pneumonia, and was sent here two days later.

State on Examination.—Seen in its stall, the animal seemed greatly depressed, and hung back from the manger, with its head low and eyes half closed. The conjunctiva was yellowish; the mouth moist and hot; the artery tense; the pulse feeble; the cough small and paroxysmal. Nothing was noted on auscultation or percussion. Respirations 26, pulse 68, temperature 40·5° C.

Treatment.—Mustard was applied to the chest, causing the temperature to fall eight tenths of a degree; internally, alcohol, bicarbonate of soda, and warm creolin enemata were prescribed, while 8 ounces of normal salt solution were injected subcutaneously.

On the 30th the condition was graver; torpor, loss of appetite, and injection of the visible mucous membranes were noted, and a dark line had developed along the gums. Respirations 35, pulse 75, temperature 40·4° C. On auscultation the vesicular murmur extended over the entire area of both pulmonary lobes. No abnormal sound could be heard. Apart from its rapid action the heart showed nothing particular. The evening temperature was 40·6° C.

On the 1st May the general condition remained as on the previous evening. Respirations 32, pulse 75, temperature 30·9° C. The conjunctivæ were saffron-yellow; the pulse feeble; there was abundant rust-coloured discharge from the nose; inspiration was oppressed, and expiration sighing. Cough was frequent. On the left side the zone of dulness extended as high as the point of the elbow. On auscultation, crepitation and a slight tubal murmur could be heard. On the right side the lower part of the chest revealed partial dulness, but no abnormal sounds. The heart-beats were strong and slightly irregular. The same treatment was continued, but a dose of digitalis was also given. Sixteen ounces of ·8 per cent. salt solution were injected. During the following hours the temperature fell a few tenths. In the evening respirations 35, pulse 84, temperature 40·4° C.

On the 2nd the general condition remained bad, and appetite was entirely lost. There was frequent cough and rust-coloured discharge. The pulse was feeble. Dulness had markedly extended on the left side, and rose to the middle third of the thorax; on the right a loud tubal murmur was heard during inspiration and expiration. Respiration 40; pulse 80; temperature 39·7° C. During the afternoon the horse was led out and left in the open air for several hours. Microscopical examination of the discharge resulted in several varieties of microbes being found, though two streptococci, one of which stained by Gram's method, predominated. During the evening the heart's action became very rapid, the pulse feeble, the respiration extremely difficult, and the face anxious. Twelve and a half fluid ounces of salt solution and five and a half fluid drachms of ether were injected. The thorax and limbs were rubbed with mustard. At 7 o'clock the temperature was 39·4° C. Another subcutaneous injection of ether was given.

At 3 o'clock the general condition was similar to that on the previous day. Respiration 44; pulse 82; temperature 39·4° C. The nasal discharge had ceased; the conjunctiva was deep red; the pulse perceptible with difficulty; dulness had increased on both sides; there was tympanic resonance on the left. During both stages of respiration and on both sides of the chest a loud tubal murmur could be heard. The cardiac sounds were feeble. The former treatment was continued. Two and a quarter fluid drachms of ether were injected. Night and morning the horse was led out of the stable and left in the open air for several hours, provided the weather was good. The urine did not contain albumen or bile pigments.

On the 4th respiration 44; pulse 84; temperature 39° C. General condition improved. The animal was less depressed, and for the first time after entering hospital fed voluntarily. The tubal murmur and tympanic resonance on the right side persisted. The hind limbs were a little swollen. The same treatment was continued. In the evening respiration 40; pulse 80; temperature 39·2° C.

On the 5th the rapidity of breathing contrasted with the improvement in the general symptoms. Respiration 50; pulse 88; temperature 39·2° C. The dulness and tympanic resonance continued: the tubal murmur was less marked. Crepitation and loud mucous râles were heard. Small subcutaneous abscesses developed in different regions. The same treatment was continued. In the evening respiration 60; pulse 78; temperature 39·3° C.

On the 6th the pulmonary symptoms were still marked, but the patient readily took food. The conjunctiva was rose-coloured, the pulse feeble; the respiration was more regular. Respiration 42; pulse 70; temperature 38·6° C. On both sides of the chest a tubal murmur and crepitation could be heard. Percussion revealed dulness with areas of tympanic resonance. In the evening respiration 42; pulse 70; temperature 38·7° C.

On the 7th dulness had almost disappeared from the left side. On auscultation crepitant and sibilant râles were still audible. On the right a tubal murmur and crepitation were noted. The heart-beats

were regular and fairly strong, and the pulse was good. Respiration 38; pulse 72; temperature 38·5° C.

On the 8th the general condition was excellent. On auscultation the tubal murmur had disappeared, and diffuse crepitation, together with bronchial râles, was heard on both sides. Respiration 34; pulse 74; temperature 39·3° C. Treatment was reduced to administration of sodium sulphate and bicarbonate.

On the 13th the respiration was still 26, pulse 74, and temperature a little over 38° C. On the 14th and 15th the breathing diminished in frequency. During the following days the last troubles disappeared. On the 18th the temperature was 38° C.

A week after leaving hospital the horse was brought back again suffering from a deep-seated metapneumonic abscess in the withers. The pus contained streptococci.

186. A five-year-old gelding, entered hospital March 15th, 1899.

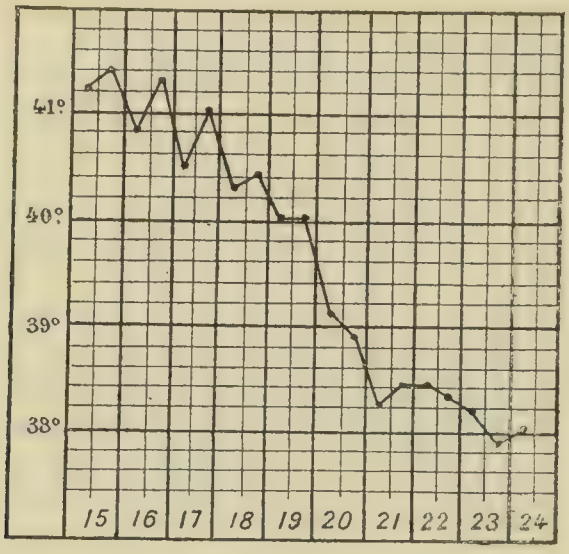

Chart IX.

For some days it had been dull, had eaten little, and coughed frequently. It had been treated for pulmonary attack during the spring of 1898.

State on Examination.—The animal was stiff, and moved with difficulty; the conjunctiva was deep yellow; the breathing and pulse were very rapid; the cough was strong and loose. Percussion of the thorax failed to reveal dulness. On auscultation some moist crepitant râles were heard in the lower part of the left lung; the heart-sounds were normal and the pulse was good. The animal ate slowly but consumed all its food. Respiration 25; pulse 70; temperature 41° C.

Treatment.—Injection into the jugular vein of five and a half fluid drachms of 1 per cent. iodine solution. At 7 p.m. respiration 27; pulse 60; temperature 41·4° C.

Next day respiration 27; pulse 60; temperature 40·8° C. Partial dulness and crepitant râle in the lower part of the left lung. Nothing on the right side. During the day three intra-venous injections of two

and a half fluid drachms of the iodine solution were made. The animal ate slowly, but consumed its oats and hay. In the evening respiration 32; pulse 65; temperature 41·3° C.

On the 17th respiration 30; pulse 67; temperature 40·5° C. In the lower third of the left lung was a zone of dulness limited by a line drawn obliquely downwards and backwards. Over this area a trifling tubal murmur, and towards the upper part some crepitation, were heard. The appetite still remained good. The same treatment was continued. In the evening respiration 34; pulse 70; temperature 41° C.

On the 18th respiration 82; pulse 65; temperature 40·3° C. The patient was less depressed than on the preceding days. The dull zone was larger, the tubal murmur strong, and there was more crepitation. The heart-beats were feeble but regular. The cough was frequent and strong; the mucous membranes were slightly injected. Two intravenous injections of 4 fluid drachms of iodine solution were made. In the evening respiration 37; pulse 70; temperature 40·4° C.

On the 19th respiration 35; pulse 68; temperature 40° C. Dulness over the lower half of the left lung; the tubal murmur remained marked. The heart beat regularly; the pulse was rather feeble. During the day the breathing became rapid. The animal took note of what occurred around it; it did not leave any of its food. Same treatment continued. In the evening respiration 50; pulse 66; temperature 40° C.

On the 20th respiration 45; pulse 62; temperature 39·1° C. The zone of dulness was stationary; the murmur persisted; the pulse was small, the conjunctiva slightly yellow; the appetite was preserved. Same treatment continued. In the evening respiration 35; pulse 60; temperature 38·9° C.

On the 21st respiration 35; pulse 52; temperature 38·2° C. The dull zone had diminished in size; the tubal murmur was weaker; the crepitant râle indicating resolution had returned; the pulse had again become large and strong. The animal was exercised for a quarter of an hour. Same treatment continued. In the evening respiration 37; pulse 50; temperature 38·4° C.

On the 22nd respiration 33; pulse 43; temperature 38·4° C. Dulness had almost disappeared. On auscultation only a slight tubal murmur and a few crepitant râles were noted. Exercised in the sun during the afternoon, the patient was bright and walked with freedom. On returning to its box it ate with good appetite. Same treatment continued. In the evening respiration 34; pulse 43; temperature 38·3° C.

On the 23rd respiration 30; pulse 40; temperature 38·2° C. There were still a few crepitant râles. No cardiac disturbance. The animal lay down during the day, but rose on the slightest disturbance. The iodine treatment was stopped, and one and a half ounces of sodium bicarbonate were given in the drinking-water. In the evening respiration 30; pulse 45; temperature 38° C.

On the 24th respiration 22; pulse 40; temperature 38° C. No abnormal sound was heard on auscultation. There were no after complications.

PURPURA HÆMORRHAGICA.

187. A six-year-old entire horse, brought for examination on the 5th March, 1897, suffering from a corn in the off fore-foot. The bar and branch of the sole were thinned, the foot reshod, and a tar dressing applied.

On the 10th March the horse was returned here. For two days before all four limbs had been swollen and œdematous.

State on Examination.—The swellings were of considerable size, and extended as high as the elbows and stifles, where they were sharply delimited. The mucous membrane of the nose was covered with petechiæ. There was no swelling about the face. Walking was difficult, the limbs being carried stiffly and not being flexed. The appetite was good. Temperature 38·4° C. During the previous three years four cases of purpura hæmorrhagica, three of which had ended fatally, had occurred in the stable from which this patient came.

Treatment.—Injection into the connective tissue of the neck of three and a half fluid ounces of normal horse serum. During the five following days four to four and a half fluid drachms of this serum were injected in the region of the neck, over the triceps muscles, and into the front of the chest.

On the 16th swelling of the fore-limbs had diminished; that of the hind remained as before. There was little fever, the temperature only rising a few tenths of a degree above normal; appetite was preserved. The treatment was continued.

On the 19th the swelling in all four limbs was diminishing. A trifling whitish discharge ran from both nostrils; it continued for a week. Serum was injected, and one and a half ounces of sodium bicarbonate were administered on alternate days.

The animal left hospital on the 31st March, the swelling of the limbs having completely disappeared.

188. A ten-year-old gelding entered hospital December 10th, 1897. Had been attacked with paraplegia a month before, and had afterwards suffered from the abdominal form of influenza. Still showed traces of bleeding from the jugular and blistering of the dorso-lumbar region. Had been rested since the 25th November. On the 9th December signs of purpura appeared. Was brought to the school on the evening of the next day.

State on Examination.—The limbs were swollen as high as the upper third of the forearm and thigh. The left side of the breast and the right of the abdomen showed œdematous patches; the lower half of the head was swollen; the nose, face, lips, and cheeks were greatly infiltrated. Blood-stained discharge ran from both nostrils; the mucous membrane of the nose exhibited blackish ecchymoses, almost everywhere confluent. The respiration was 60 per minute and noisy; temperature 39·7° C.

Treatment.—The swelling about the head was perforated in about thirty spots with the fine needle of the thermo-cautery, allowing a large quantity of reddish serosity to escape. Four and a half fluid

ounces of normal horse serum were injected; six and a half ounces of sodium sulphate and three and a quarter ounces of alcohol were given in the drinking-water. During the night the difficulty in breathing increased, and tracheotomy had to be performed.

On the 11th the general condition remained stationary. The breathing, however, was easier, and much less rapid than on the previous evening. Temperature 39·0° C. During that and the next day four and a half fluid ounces of normal horse serum were injected in three separate quantities.

On the 13th the head and fore-limbs were less swollen; the œdematous patch on the thorax was undergoing absorption; that on the abdomen remained as large as before, and had extended to the sheath. An œdematous zone of considerable size had developed around the tracheotomy wound. Temperature 39·0° to 39·5° C. The injections of serum were continued.

During the three following days the head continued to diminish in size; the swelling in the limbs remained stationary; the patch on the neck gravitated towards the breast, and increased; whilst that on the abdomen advanced beneath the thorax. Temperature 38·5° to 38·8 C.

On the 17th the swellings about the front of the body had greatly diminished, as had those on the hind limbs and abdomen. The tracheal tube was removed, and the wound swabbed with 20 per cent. iodine solution. Temperature 39·0° to 39·3° C. Treatment was supplemented by the daily administration of two ounces of sodium bicarbonate.

On the 22nd the œdema had almost disappeared at all points; temperature 38·0° C. The serum injections were discontinued; the patient was exercised night and morning.

A week later it had entirely recovered.

189. An eight-year-old entire horse, left in hospital December 18th, 1897, to be treated for bronchitis. Double pneumonia afterwards developed; its onset was insidious, but the real nature of the disease was clearly shown by the moist crepitation and tubal murmur on both sides, and by the dulness of a considerable area of both lungs.

The pneumonia commenced on the 8th January. On the 22nd the temperature still varied between 39·0° and 39·6° C. Cough persisted, and was accompanied by a double-sided muco-purulent discharge, in which streptococci and some staphylococci were found on bacteriological examination. The appetite was capricious. Percussion revealed dulness over the anterior part of the right lung. On auscultation moist râles were heard. A patch of chronic pneumonia was suspected. The principal drugs used were iodide of potassium and oil of turpentine.

On the 27th the hind limbs were swollen, and an œdematous patch, as large as a man's hand, appeared on the right side of the abdomen. The Schneiderian membrane showed a few petechiæ. Temperature 38·9° C.; respiration 17; pulse 40.

Treatment.—Subcutaneous injection of three and a quarter fluid ounces of normal horse serum.

On the 28th the general condition was bad and the appetite poor. The hind limbs showed greater swelling, sharply defined at the upper part. Temperature 40·0° to 39·8° C.; respiration 23; pulse 43. Treatment continued.

On the 29th the fore-limbs and the lower part of the head became swollen; breathing was accompanied by a wheezing sound. Temperature 39·7° to 40·0° C.; respiration 18; pulse 40.

For three days six and a half fluid ounces of serum were injected daily. The condition remained stationary until the 1st February.

On the 2nd the swelling about the face had diminished; the respiration was free, and the appetite good. Temperature 39·5° to 40·0° C.; respiration 20 to 24; pulse 45.

On the following days the swellings were smaller. The injections were continued.

On the 5th the swelling about the face had disappeared; that on the limbs and abdomen had diminished. One and a half ounces of sodium bicarbonate were given in the drinking-water.

On the 9th the swellings were almost entirely re-absorbed. Temperature 38·4° to 39·3° C.; respiration 15; pulse 42. Only three and a quarter fluid ounces of serum were injected, one and a half ounces of sodium bicarbonate being given daily in the drinking-water.

Some necrotic patches of skin sloughed away from the scrotum.

On the 17th the horse had fully recovered.

TETANUS.

190. A three-year-old entire horse, entered hospital November 4th, 1896.

State on Examination.—Various groups of muscles, especially those about the neck, showed tonic contraction; the head was extended on the neck; there was slight trismus; the eyes were partly withdrawn into the orbit, were immobile, and covered by the membrana nictitans; the tail was held horizontally, and the limbs were stiff. Respiration 30; pulse 50; temperature 38·5° C.

No wound could be discovered on the skin or mucous membranes. The front of the off hind fetlock exhibited a cicatrix resulting from an injury inflicted six months before. All four feet showed a little thrush.

Treatment.—The frogs were cleansed; the median lacunæ carefully wiped out, swabbed to the bottom with tincture of iodine, and covered with tar.

The patient was placed in a dark box and given three and a half ounces of sodium sulphate, one and a quarter ounces of sodium bicarbonate, and two and a half drachms of potassium iodide daily in the drinking-water. Enemata containing iodine and chloral were also given.

During the next four days the condition remained stationary, the temperature varying between 38° and 38·5° C.

On the 9th the hind limbs were slightly less stiff. The enemata produced rather violent expulsive efforts, and were stopped.

Up to the 15th there was no visible change. Each day the animal ate part of its food.

On the 16th the condition was graver. Temperature 39·8° C.; pulse 52; respiration 28. Mechanical pneumonia from passage of food into the trachea was feared. Auscultation and percussion of the chest revealed nothing abnormal. The laryngeal region was slightly painful on pressure. The animal refused most of its food.

From the 17th to the 20th, three and a half fluid ounces of alcohol were given daily in the drinking-water, and three antiseptic fumigations made. The symptoms persisted, and were accompanied by attacks of coughing.

On the 21st there was trifling double-sided muco-purulent discharge; the submaxillary glands were swollen and sensitive; the temperature 39·6° C.

On the 22nd discharge was more abundant; the pituitary membrane was deep red. The submaxillary swelling had become fluctuating. Temperature 39·5° C; respiration 22; pulse 56. The abscess was opened, and the cavity irrigated with carbolic solution.

Next day the general condition had improved. The neck and head were more freely moved. The animal ate all its food with the exception of a little hay. Temperature 39·2° C; respiration 28; pulse 78. During the next few days the last symptoms of sore throat disappeared, and the tonic contractions became less and less marked.

On the 28th there was still slight stiffness of the ears and tail.

On the 30th cure was complete.

191. A ten-year-old entire horse, entered hospital February 3rd, 1897. For the previous three weeks a wound caused by the collar had existed on the upper part of the neck. On the 3rd February the animal worked during the whole morning, but towards two o'clock the driver noticed signs of stiffness about the limbs and difficulty in breathing. He took it to a veterinary surgeon, who diagnosed tetanus. The animal was brought to Alfort during the evening.

State on Examination.—On its arrival symptoms of tetanus were clearly marked. Walking was difficult, the hind limbs especially being affected. The neck was stiff, the head extended, and the tail elevated. There was slight trismus. Temperature 38·3° C. No other wound except that on the neck could be discovered.

Treatment.—The patient was immediately placed in a dark box, and the wound disinfected with 5 per cent. carbolic solution and tincture of iodine. Three and a half ounces of sodium sulphate and one and a half ounces of sodium bicarbonate were given in the drinking-water. Milk *ad libitum* was allowed. The horse ate all its food, though mastication was difficult.

Next day the condition had become slightly worse. The breathing, which had previously been normal, was rapid and short. Temperature 38·4° C. The same treatment was continued, but in addition eight ounces of ·8 per cent. salt solution were subcutaneously injected. This was repeated during the following days. From the 5th fever ceased.

On the 9th slight improvement was noted. Movement was less

difficult; the neck less stiff; the nostrils less dilated; while respiration was slower and easier. The injections of artificial serum produced considerable struggling, but nevertheless were continued until the 14th.

From the 15th to the 25th treatment was reduced to daily administration of four and a half ounces of sulphate and one and a half ounces of bicarbonate ot soda. Improvement was slow.

From the 25th to the 30th injections of artificial serum were repeated, but they caused such violent struggling that finally they had to be suspended. Treatment was, therefore, again restricted to adding sulphate and bicarbonate of soda to the drinking-water.

During the early part of March improvement occurred more rapidly, and by the 10th recovery was complete.

192. An eleven-year-old mare, entered hospital October 15th, 1897. On the 25th September had fallen and injured the right forearm and knee. On the 14th October symptoms of tetanus appeared. The animal was brought to the school next morning. There was trifling generalised muscular contraction and slight trismus. Temperature was normal. The animal could still eat.

Treatment.—Disinfection of the wound and of the knee and forearm with 3 per cent. creolin solution, followed by tincture of iodine. Eight fluid ounces of warm 1 per cent. salt solution were injected into the jugular, five ounces of sulphate, and two ounces of bicarbonate of soda were given in the drinking-water. In addition enemata containing chloral were administered.

During the next two days the condition remained stationary. Respirations 20; temperature 38° to 38·4° C. The animal took gruel, hay, and oats. Treatment as before.

On the 18th the trismus was a little more pronounced. Temperature 38·2° to 38·5° C. Nine and a half fluid ounces of artificial serum were subcutaneously injected. These injections, together with the internal and local treatment, were continued until the 26th, on which day improvement appeared. As the animal became difficult to approach the enemata were discontinued.

Until the 12th November a daily dose of 1 to 1¾ ounces of sodium bicarbonate was given in the drinking-water, and from time to time 3 to 5 ounces of sodium sulphate. At the date mentioned recovery was complete. The animal left hospital on the 15th November.

193. A twelve-year-old gelding, entered hospital November 29th, 1896. Had been castrated four months previously; one of the wounds had become sinuous. A week before, the animal's left hind pastern had also been injured by a fragment of glass. On the 29th November the owner noticed that the horse moved with difficulty. The head was extended on the neck, the tail was elevated, and the limbs were stiff.

State on Entry.—The patient showed symptoms of acute tetanus. Tonic muscular contraction was intense and generalised; at rest the limbs were stretched out on either side, and during movement were advanced without being flexed. The tail was lifted; the head

markedly extended on the neck; the ears were directed forwards, and could not be moved; the membrana nictitans covered part of the globe of the eye. Trismus was very marked. The animal made unsuccessful attempts to swallow its saliva, which dribbled from the mouth in long filaments. Any excitement caused paroxysms. Temperature 39·3° C.; respirations 78; pulse 85. A wound about two inches in length, with contused margins, was found in the left hind pastern.

Treatment.—Disinfection of the wounds with dilute tincture of iodine, immersion of the foot in a ·1 per cent. sublimate solution, followed by iodoform dressing of the pastern. The patient was afterwards placed in a dark box and fed with nourishing enemata. At 9 p.m. 75 grains of Behring's dry antitoxin, dissolved in 11¼ fluid drachms of lukewarm sterilised water, were injected into the jugular. The animal was found dead next morning.

Autopsy.—Lesions of asphyxia; suppurating scirrhous cord; the base of the left spermatic cord was swollen, as large as a hen's egg, and contained numerous suppurating centres.

194. A four-year-old gelding, castrated on the 27th November, 1896, in the northern suburbs of Paris. The operation was performed by the covered method with clams, and partial antiseptic precautions were taken, During the days following operation the wounds were washed with ·1 per cent. sublimate solution three times daily.

On the 4th December the clams were removed. Next morning considerable swelling of the genital region appeared, but in a few days again diminished. The wounds suppurated slightly.

Until the 20th December nothing unusual was seen. Next morning, however, symptoms of tetanus appeared, and the horse was sent to Alfort.

State on Examination.—Generalised tonic contractions; tail elevated; head extended and held stiffly; ears directed forwards; membrana nictitans covering part of the globe of the eye; trismus; respiration rapid, varying between 32 and 36 per minute; temperature 38° C.

Treatment.—The horse was placed in a box. Every care was taken to guard it against the action of light, cold, and noise. The wounds were disinfected. Morphine and chloral were given. During the day and ensuing night the symptoms became aggravated.

On the morning of the 21st the skin was covered with sweat. Hyperæsthesia was very marked; opening the door, touching the animal, or making the smallest noise produced paroxysms. Respirations 36; pulse 46; temperature 38·2° C.

Seventy-five grains of Behring's dry antitoxin, dissolved in 11¼ drachms of lukewarm sterilised water, were injected into the jugular. During the day the patient took milk, and in the evening gruel. Respirations 36; pulse 48; temperature 38·5° C.

On the 22nd the condition was more severe. The respirations were 70 to 80 per minute during the attacks. Seventy-five grains of aqueous extract of belladonna and 5 ounces of sodium sulphate of soda were given in the drinking-water. Morphine was subcutaneously injected, and chloral given in enemata.

On the 23rd the contractions and trismus had become still more exaggerated. Swallowing was impossible. The same treatment was continued, but the animal died during the night.

Autopsy.—Lesions of asphyxia.

195. A nine-year-old gelding, entered hospital May 6th, 1899, having shown symptoms of tetanus for two days previously. Came from the eastern suburbs of Paris. A month before had fallen and injured its knees.

State on Examination.—The legs were stiff and placed farther apart than usual; the head was extended on the neck. The animal had relatively little difficulty in moving. The face appeared anxious; the eyes were fixed, the nostrils dilated, the ears drawn together and rigid; the tail was lifted. The least excitement caused the membrana nictitans to be projected over the eye. Mastication was slow, and appetite diminished; trismus was little marked. The front of the left knee showed a circular wound the size of a sixpence. Temperature 38·8° to 39·1° C.; respiration 28 to 30; pulse 60 to 66.

Treatment.—The animal was placed in a dark box. Milk, gruel, hay, and oats were offered. Bicarbonate of soda was added to the drinking-water. Five and a half fluid drachms of an emulsion prepared from the cerebral substance of a dog was subcutaneously injected, and two quantities of two and a half and five fluid drachms of 1 per cent. iodine solution were injected intra-venously. Though continued from the 6th to the 15th May, this treatment appeared to have no effect on the temperature, circulation, respiration, or on the muscular contractions. Nevertheless, during the hour following the iodine injections excitement seemed diminished.

Next day there was no particular change. The bowels were constipated. Passage of urine was frequent and painful. Six and a half ounces of sodium sulphate and four drachms of bicarbonate were added to the drinking-water.

On the 7th tension about the neck and trismus were less marked. Swallowing was easier. Temperature 38·1° to 38·7° C.; respiration 28 to 32; pulse 60 to 66.

On the 8th the improvement continued. Temperature 38° to 38·9° C.; respiration 22 to 30; pulse 60 to 62.

On the 9th condition stationary. The patient moved about its box. The eye was still partly covered by the membrana nictitans. Temperature 38° to 38·4° C.; respiration 25 to 32; pulse 60 to 64.

From the 10th to the 18th May the condition was more satisfactory. The symptoms gradually diminished. Temperature 37·9° to 38·6° C.; respiration 25 to 28; pulse 52 to 60. From the 15th only one daily injection of two and a half drachms of iodine solution was made.

On the 19th May the iodine treatment was stopped. The jaws were moved normally. There was only trifling stiffness when moving. Recovery was assured. The animal left hospital on the 24th.

Remarks.—None of the drugs, or combination of drugs, yet suggested for the treatment of tetanus are of much value. In the horse,

whatever treatment be adopted, the mortality is about 70 per cent. I have made experiments as to the benefit of excising the inoculation wound, and of injecting antitoxic serum. In our patient free removal of the margins of the inoculation wound necessitates anæsthesia, without which excessive excitement and violent struggling occur. It is of less value than careful disinfection of the wound, provided this can be done without causing pain.

It is well known that the first antitoxic serums produced in Germany and France were useless in the acute form of tetanus. They have only proved successful in chronic tetanus, a form which in the horse is often followed by recovery under the older forms of treatment.

In November, 1896, Professor Dieckerhoff published in the *Berliner thierärztliche Wochenschrift* some clinical cases which appeared to show that a new antitoxin (Behring's dry antitoxin), manufactured in the Sero-therapeutic Institute of Höchst-u.-Main, when subcutaneously or intra-venously injected in doses of seventy-five grains, dissolved in eleven and a quarter drachms of sterilised water, cured the acute form of tetanus. In spite of the high price of the remedy (6*s*. 3*d*. per fifteen grains), I procured a sufficient quantity to study the effects. Cases 156 and 157 were treated with an intra-venous injection of seventy-five grains of this antitoxin. The first died twenty-four hours after injection, and the second on the fourth day. In three other horses affected with acute tetanus, treated by subcutaneous injections of an emulsion of nerve substance, and by intra-venous injections of iodine solution, the course of the disease was less rapid than in the two preceding cases, but the final result was the same. The intra-cranial injection of antitoxic serum is still the subject of study. Its efficacy in acute tetanus not having as yet been clearly demonstrated, it cannot be recommended in practice.

VII.—VARIOUS DISEASES.

PARASITIC ANÆMIA (IXODES).

196. A nine-year-old setter dog, entered hospital November 24th, 1894. For several months this dog had been covered with ticks. More than 300 could be counted, fixed principally to the ears, the right side of the head, the left shoulder, the chest, and the dorso-lumbar region. The animal was thin and very feeble, showed slight ptyalism, and its mucous membranes were pale. Appetite was good. Temperature 37·8° C.

The ticks fixed to the ears and left shoulder were touched with oil of turpentine, and those in the other regions with benzine. At the end of an hour some of the larger which had been touched with benzine began to loosen their hold. An hour later the majority were only attached by the rostrum, and their bodies were blackish: they were then easily removed with forceps. The large ticks touched with oil of turpentine became detached more slowly. The smaller had all preserved their colour. At the end of four hours all the parasites, whether touched with benzine or with turpentine, remained fixed to the skin only by the end of the rostrum.

The patient showed uneasiness and partial paresis of the hind quarters, resulting from absorption of a certain quantity of the agents employed. It was washed, dried, and rubbed, and given a few spoonfuls of strong coffee and milk containing bicarbonate of soda.

Some ticks which survived the action of the benzine and turpentine were touched with pure carbolic acid. At the end of ten minutes they were easily removed. It is interesting to note that the larger ticks appeared less resistent than the small.

ECHINOCOCCOSIS OF THE BRAIN, LUNGS, AND LIVER IN A HORSE.

197. A fifteen-year-old blue roan pony, first seen at 5.30 a.m. on June 3rd, 1895.

History.—Was thought to have sustained some injury to its hind quarters, and was unable to rise.

On the previous evening it had been a little restless, and seemed rather uncertain on its hind legs, but becoming quieter after the administration of some simple colic medicine it was left for the night. Early next morning the coachman found the pony lying on its off side, sweating a good deal, and unable to rise. It had been lifted by sheer strength, but could not stand.

State on Examination.—The animal was still lying on its off side, and appeared fairly comfortable. The pulse was 50, soft, and of good volume; respirations 16, temperature 100$\frac{2}{5}$°. The conjunctiva was of a brick-red tint, and the pupil sensitive to light.

The animal was turned over and placed in a position to rise, but in spite of some assistance it made no effort to do so. Examination of the back and off hind limb revealed no injury. There was neither pain nor crepitation, and sensation seemed good in both hind limbs. The statement (elicited by close questioning) that the pony had not been exercised for some days, but had been liberally fed, aroused suspicion of hæmoglobinuria, although the lumbar muscles did not show the usual stiffness. The suggestion was afterwards negatived by the urine continuing perfectly normal.

As it was important to raise the patient, and allow it, if able, to stand, this was done, but the animal failed to place any weight on the off hind limb, which seemed paralysed: while the near, though sustaining weight, could not be moved. The united efforts of five men were required to keep the animal on its legs, and therefore after the bed had been renewed and increased it was again let down.

Fig. 65.—Region of insensibility (shaded).

Failing any positive evidence to the contrary, and no urine having been found in the bladder, the case was at this stage treated as azoturia. Stimulating applications were made to the loins, and an anodyne draught containing Tr. Opii fl. ℥ss, Chloral Hydrate ℥j, Spt. Tereb. fl. ℥ss, and Ol. Lini Oss administered, and ordered to be repeated in four hours.

By 8 p.m. on the same day (June 3rd) there was no particular improvement, but the urine having been examined the diagnosis of azoturia became untenable. In the meantime, however, the pupils became insensitive to light, and some difficulty was shown both in breathing and swallowing. Cerebral injury was therefore suspected, and a dose of aloes and calomel given to unload the bowels. Cold applications were made to the head, and at a later date a blister was applied.

At 6 p.m. on June 4th the pony was still unable to rise, and lay with the head and neck fully extended. The pulse was imperceptible either at the submaxillary or radial arteries, and the heart's impulse could not be detected through the chest wall. The respirations were 57. The pupil was fully dilated and completely insensitive to light; the retinal vessels appeared enlarged, and the bright reflection from the tapetum was dulled by what seemed to be a deposit of lymph. A

corneal ulcer, the size of a split bean, had developed in the right eye. The mouth was hot and dry, salivation completely in abeyance. There was moderate bilateral paralysis of both lips, grinding of the jaws, and from time to time a slight muscular spasm appeared to flit over the face. The near hind leg had become affected almost to the same degree as the off, but both still responded to stimuli, such as the prick of a pin, except over the upper part of each quarter in the region shown in the diagram (shaded). For the previous twenty-four hours the animal had shown regularly recurring periods of excitement, moving the legs rapidly, as if at full gallop, for a minute or two, and then subsiding into quiet. Latterly the fore-limbs alone had been moved, the hind limbs being partially flexed, and kept either quite still or only moving passively. Pricking the skin of the hind

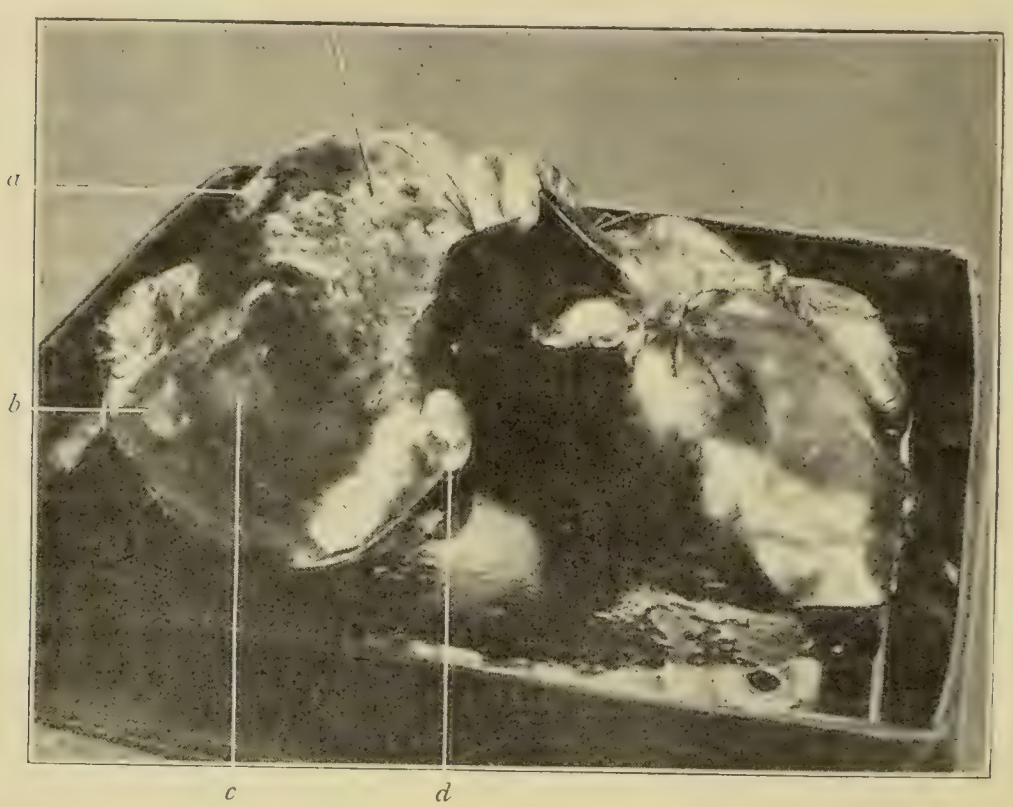

FIG. 66.—Liver with cysts.

limbs at any point outside the shaded area produced an exaggerated movement of the panniculus, or in some cases contraction of the limb. That sensation in the hind limb was not entirely destroyed, however, was shown by the fact that a sharp prick also excited contractions in the fore-limbs. There was local sweating under the arms and in the flank. The tail was partially paralysed.

The bowels were acting slightly. The kidneys had acted twice on the 3rd, and once on the morning of the 4th. Having regard to the sudden onset, the almost total absence of fever and of delirium, the failure to detect local injury, and the rapid course, the diagnosis was hæmorrhage at the base of the brain—an opinion that proved far from correct. The prognosis was necessarily very unfavourable, and, in point of fact, the animal died about 9 p.m. on the evening of the 4th June.

On *post-mortem* examination, made the same evening, the intestines, spleen, bladder, and kidneys were apparently normal, though, as would be expected in an old and well-fed animal, there was an unusual accumulation of fat around the kidneys and in the omentum and mesentery.



FIG. 67.—Liver, showing cysts, laid open.

The liver was enlarged, showed signs of fatty degeneration, and its left lobe contained numerous cysts, marked *a*, *b*, *c*, and *d* in the figure. These only represent a few (Fig. 66). A straw has been inserted in one of the upper cysts which had been opened. To facilitate description

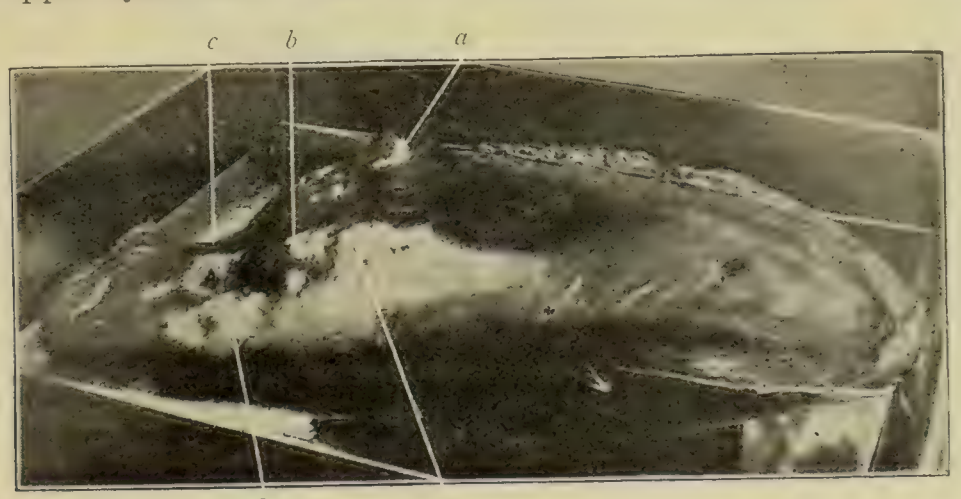

FIG. 68.—Right lung, showing cysts.

a further figure is given, showing the three larger cysts (*a*, *b*, *c*, and *d*) laid open (Fig. 67). That marked *a* was the largest. Its walls were of the consistency of cartilage, measured three eighths of an inch in thickness, and were lined internally with a light greyish, crapy-looking

membrane. It contained 9 ounces of a perfectly clear limpid fluid, which escaped under pressure on the sac being incised. Scrapings taken from this were microscopically examined. The appearances will be described later. The second cyst (really consisting of the cavities *b* and *c*) was perhaps as large in extent, but contained less fluid. Its walls were calcified, and varied in thickness from a quarter to half an inch. Its lining membrane was yellow, and covered with a slimy muco-purulent fluid, while the bulk of its contents was of a similar semi-purulent character, though thinner than the material adhering to the walls. The third cyst was somewhat smaller, and contained about 5 ounces of fluid. Its walls were some three eighths of an inch in thickness, but in all material respects it resembled *a*. The central lobe contained another cyst; the right seemed free.

The lungs were emphysematous. They showed in all about thirteen cysts of varying sizes, each having a wall of cartilaginous hardness, containing a clear fluid under pressure, and exhibiting a greyish-white

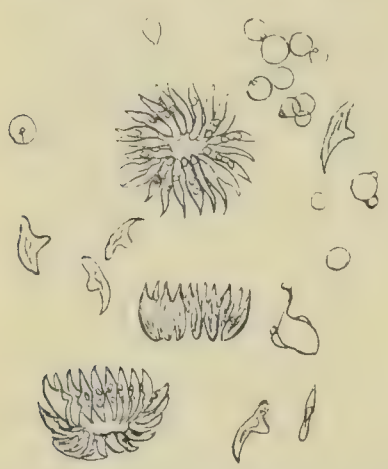

FIG. 69.—Débris in cyst fluid, showing echinococcus spines and buds or daughter cysts.

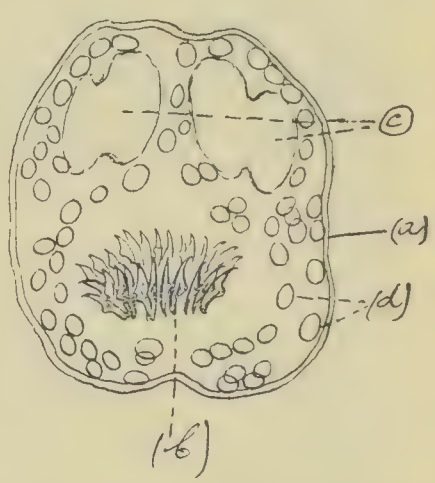

FIG. 70.—Echinococcus scolex, intact.

crapy lining. The right lung is that represented (see Fig. 68). The largest cyst, which projected prominently, is marked *a*; others are marked *b*, *c*, *d*, and *e*.

A minute particle scraped from the wall of any of these cysts showed the appearance of Fig. 69. Myriads of echinococcus spines, singly and arranged in the characteristic saucer forms, float in the fluid, together with secondary and tertiary cysts in various stages of development. A secondary cyst, more highly magnified, is shown in Fig. 70. By careful lighting this was seen to be bounded by a thin cell-wall containing apparently a glutinous fluid. At the base was the crown or saucer of echinococcus spines (*b*), which, on rupture of the investing membrane, break up and float singly in the fluid, producing the appearance shown in the preceding figure. Towards the top were two denser bodies (*c*), apparently undergoing division, while throughout the rest of the free space were numerous daughter cysts (*d*) arranged in order.

The heart was enlarged, but otherwise normal.

On removing the brain the meningeal vessels appeared congested, but it was not until the tissue had been hardened and carefully divided that the most interesting lesion was discovered. Two typical cysts were found: one about the size of a pigeon's egg in the upper part of the cerebellum, rather inclined towards the left side; the other, somewhat smaller, in the cerebrum. In both cases hæmorrhage had occurred around the cyst, and had infiltrated the substance of the brain.

The cerebellar cyst had a distinct wall about one twentieth of an inch in thickness, was lined by a greyish-white membrane, and contained a yellowish caseous material, examination of which showed the usual echinococcus spines. Around the cyst and extending obliquely downwards and forwards towards the fourth ventricle was a well-marked hæmorrhage (see Fig. 71). The cyst in the cerebrum appeared of later growth. Its wall was thinner and only perceptible with difficulty. It contained a similar material, and was equally surrounded by a hæmorrhagic area, which in this case, however, extended chiefly upwards towards the point where the crucial fissure abuts on the third anterior convolution.

Note.—The cysts in the brain and cerebellum were apparently of

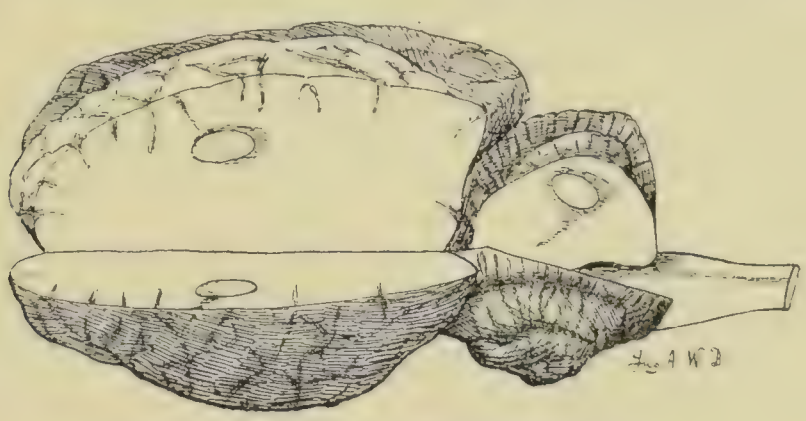

FIG. 71.—Brain, showing cysts.

considerable age, probably not less than two or three years, and possibly much older. That in the cerebellum might have existed for five or six years, and provided its growth were slow have caused no peculiar symptoms. Extensive tracts of the cerebellum can be destroyed by malignant growths without interfering with even the most complicated acts; and it is known that in dogs, large portions of whose cerebellum have been experimentally removed, function is sometimes completely restored after the lapse of a year or two. It need excite no surprise, therefore, that slowly increasing cysts in this region produced no symptoms calling for remark.

Cysts, however, like tumours, are always surrounded by a network of vessels, the walls of which are generally very thin, and which in an old horse would be liable to rupture. A simple shock, such as that of falling down when asleep, might produce this effect, especially if there were a tendency to brain congestion, as occurs in acute indigestion. (It must be remembered the horse had shown colic the evening before.)

Hæmorrhage might then have occurred on the left side in and around the motor tract for the hind limb, finally leading to more and more complete paralysis of the hind limb of the opposite (right) side. Extending still further, it would first produce irritation, and later paralysis of the motor fibres going to the fore-limb, and then of those supplying the face. It is somewhat difficult to understand the partial paralysis of the lips while the fore-limbs still retained their function, but the difficulty does not altogether invalidate the explanation.

Mr. Jno. A. W. Dollar's case, *Veterinarian*, 1895, p. 775.

PARESIS OF THE HIND LIMBS (CHOREA).

198. A two-year-old poodle, entered hospital August 22nd, 1897. On the 18th August the animal's walk appeared awkward; the hind parts rolled from side to side, the hind limbs being in fact partially paralysed. In addition spasms occurred about the face, ear, and shoulder, and discharge from the eye and prepuce had been noted. The owner did not think the dog had suffered from distemper, but the existing symptoms were certainly a consequence of that disease.

State on Examination.—The animal was thin. On clinical examination the most striking peculiarity was the weakness of the hind quarters; during movement the limbs partially collapsed. The muscles of the head—especially the temporal muscles—and those of the ear, shoulder, and forearm were the seat of very marked clonic contractions. Appetite was good, but the animal had a little difficulty in grasping its food. There was no cutaneous eruption, and the chief functions were normal.

Treatment.—Administration of 5 grains of potassium iodide; hypodermic injection of ·03 grain arseniate of strychnine; application of the faradic current by means of brass wires passed under the skin of the shoulder and of the base of the tail respectively. The current was continued for three to five minutes.

During the first four or five days the hypodermic injection of strychnine was followed by a period of excitement, and by slight generalised contractions. At the end of a week the effects became less marked and the contractions feebler. The daily dose was then increased by ·004 grain, until a total daily dose of ·045 grain was reached. In this dose the action of the strychnine was always well marked, all the anterior portion of the body showing clearly marked hyperæsthesia, and the slightest touch producing excessive excitability.

Continued for six weeks this treatment gave excellent results. The paralysis of the hind quarters and the clonic contractions gradually diminished. On the 20th September recovery was almost complete. Slight spasms still occurred about the shoulder, but afterwards entirely disappeared.

Remark.—In the treatment of paraplegia following distemper the medicines which have given the best results in my hands are potassium iodide, given by the mouth, and arseniate of strychnine injected subcutaneously. Very small doses are first given, and are gradually increased until the desired effect is obtained. I have also tried this treatment on

three pure-bred animals affected with chorea, a disease whose nature is still undetermined, but which certainly shows all the characters of chronic myelitis of toxi-infectious origin. It did not produce any appreciable result. At the present time we have in hospital a two-year-old thoroughbred dog affected with this disease, which we have unsuccessfully treated for the past three months with subcutaneous injections of cerebral substance and intra-venous injections of iodine.

RHEUMATISM.

199. A ten-year-old Danish dog, brought for examination September 30th, 1894.

For several years this dog had shown repeated symptoms of muscular rheumatism—difficulty in moving, stiffness of the neck, back, and limbs. At certain times it suffered such pain as to howl loudly, especially at night, or when it rose after having remained long in one position. It was in the habit of bathing in a running stream near its owner's house, and the attacks frequently followed these baths.

Except for these rheumatic attacks the dog had enjoyed fairly good health. Five or six days before, more serious troubles, however, had been noted. The animal refused food, remained continually lying down, and had frequent attacks of dry cough. If forced to walk, it rolled from side to side, and ended by falling. These troubles continued, though in less degree than at first.

When the animal was brought here it showed stiffness in movement, especially of the head and neck; the neck was tense and rigid, and seemed painful even on slight pressure. The heart revealed a double systolic and diastolic murmur.

We prescribed general hygienic treatment, together with internal administration of 1½ drachms of sodium bicarbonate and 15 grains of sodium salicylate. During the night and next day the condition remained stationary.

On the 2nd October the patient was found dead in its kennel. The owner sent the body to the school for *post-mortem* examination.

Autopsy.—No liquid in the abdominal cavity; intestines of normal aspect; gastro-intestinal mucous membrane slightly hyperæmic at points; liver enormous and blackish, with the appearances of "cardiac" liver; the spleen exhibited several blackish swellings, the largest the size of a nut; both kidneys were reddish, and their surface was marbled; sections showed lesions of chronic nephritis.

The right testicle was the size of a hen's egg, and contained a tumour; the spermatic cord and the sublumbar lymphatic glands were invaded.

The lungs contained numerous little whitish cancerous patches. The pericardium was normal. The heart was very large, marbled with greyish irregular patches, indicating areas of indurative myocarditis. The left heart showed lesions of chronic endocarditis; the mitral valves were thickened, contracted, fibrous at their base, reddish and vegetating towards their free margins; the aortic valves were thickened and contracted. The right heart was less changed, though the ventricle

was dilated; the lips of the tricuspid valves were thickened and reddish, and their free margins granulating.

The cerebro-spinal fluid was abundant. The meninges lining the cranium and covering the brain showed no change; in the cervical region, however, they showed patches of ossification; throughout the rest of their extent they appeared normal, as did the cord.

The muscles of the neck were hyperæmic, infiltrated, and marked with a few ecchymoses. The articulations were unaffected.

Toxicological examination discovered no poison in the organs.

The tumour in the testicle and those in the lungs were alveolar epitheliomata.

This case is interesting for more than one reason. It shows that a case which for years exhibits signs of rheumatism may end by contracting cancer; it shows lesions of rheumatism and of ossifying pachymeningitis associated, and leads us to ask whether these latter were not the effect of a localised rheumatic inflammation of the meninges.

RHEUMATISM OR PACHYMENINGITIS?

200. "Marquis," a six-year-old dog, left in the surgical laboratory on the 15th January, 1892.

The condition from which it was suffering had suddenly appeared two months before. Without apparent cause the animal was attacked with paroxysms of acute pain, during which it whined and sometimes howled loudly. Several attacks occurred during the first day. In spite of treatment being commenced on the second day these attacks returned more or less frequently and violently. The dog had previously been in excellent health, and had always seemed very intelligent, bright, and affectionate. It was fed on cooked meat, which it ate with good appetite. We were informed that it had always shown marked sexual instinct, continually running after females and even males of its own species, and attempting coitus.

A preliminary examination only showed somewhat marked double exophthalmia. Left at liberty in the laboratory it repeatedly manifested signs of excessive sexual excitement; the propensity to coitus appeared almost permanent during the intervals between attacks. Sometimes these occurred suddenly; sometimes they were preceded by warning symptoms, like dulness, stiffness of the limbs, arching of the back and fixity of attitude, the head being depressed and the nose almost brought in contact with the ground. The attacks, whether or not preceded by preliminary signs, were always very violent. The animal suddenly appeared to be in acute pain. Standing upright, with the head and neck extended, all four limbs stiff, or one of the front limbs flexed—most frequently the left (Fig. 73),—he gave vent for half a minute to a minute to piercing howls, which were followed by prolonged whimpering. Sometimes several attacks succeeded one another, but the first was always the strongest and most prolonged. At times these attacks could be produced by forcing the animal to move; sometimes by simply touching certain regions, which appeared hyperæsthetic. To bring them on it was only necessary to place the hand on the

animal's head, neck, or shoulder; to pass it over the back and loins; or to lift the animal by its front legs. The attacks also occurred if the sense-organs were suddenly stimulated as by opening or closing a door, or by letting fall any metallic object. Sometimes they came on without any appreciable cause. They were followed by a prolonged uneasy period. They also occurred during the night: on certain mornings the animal was found depressed, with the appearance of having gone through a series of attacks.

During its bad days the patient was not comfortable anywhere.

FIG. 72.—Attitude when quiescent.

Whether lying on its bed or sitting up it seemed to suffer extremely. The body showed slight trembling; the face was anxious; the eyes even more prominent than usual; the respiration moaning. When standing upright the back was strongly arched; the limbs were placed far in advance of their ordinary position; the body was rocked slightly from behind forwards; the neck was tense, and the head depressed. The least movement produced cries. If the animal lay down it did so with great precautions. First of all it sat down slowly, extended the front limbs, then rolled gently over on one or other side.

On the 29th February, 1892, the attacks were particularly severe.

The first was produced by a very trifling blow on the neck. The animal was still standing stiffly, with the back arched and the front limbs extended, when a second attack was determined by the noise of a metal box falling on the floor. A few minutes later, when it was about to lie down, still whimpering, a third attack followed without any appreciable external cause. During the night others occurred, but less frequently than at first.

In spite of these frequent crises the animal remained well nourished. During the intervals, and sometimes during several days together, it was bright and cheerful, ate well, and, as stated above, appeared desirous of coitus. Its intelligence was in no way impaired. The temperature was normal; the sensibility of the skin was not lessened

Fig. 73.—Attitude during an attack.

at any point; the reflexes were preserved; there was no ocular disturbance or apparent disease of the ears.

This condition continued without notable change until the 25th March, when recovery occurred. On the 28th March a small bitch in heat was brought into the laboratory. "Marquis," who had to be fastened up to prevent his troubling her, made a scene at the door of the room where she was. For hours he ran to and fro in the rooms through which she had passed, searching for her, jumping on tables, and looking through windows. In spite of this prolonged excitement no fit occurred.

After being castrated in March, 1894, this dog became eczematous and fat. He continued at liberty in the surgical hospital until May, 1897. Having been taken out one Sunday by the attendant in my hospital, whom he was in the habit of accompanying, he took advantage of a crowd to escape, and was never again found.

What was the nature of this disease, which continued for nearly five months producing these painful crises? Our diagnosis always hesitated between rheumatism and pachymeningitis. I have seen several other patients suffering from similar though less violent and less persistent attacks, due to rheumatism. I incline to think that in this dog a rheumatic localisation had occurred in the meninges and auditory apparatus. The hypothesis of ossifying pachymeningitis is scarcely compatible with the perfect and lasting recovery.

SARCOMATOUS DISEASE OF THE LUNG.

201. A fifteen-year-old entire horse, entered hospital June 1st, 1897. For two years previously this horse had enjoyed good health. The sides of the chest were marked by hairless patches due to long-previous blistering. On the 25th May the animal experienced a chill and showed some alarming symptoms, regarded as due to broncho-pneumonia.

State on Examination.—On the day of entering hospital the patient exhibited evident signs of grave disease; the mucous membranes were injected and slightly swollen; the respiration was very rapid (50 per minute); cough readily followed pressure on the larynx, and was loud, moist, and inclined to recur; there was abundant mucous discharge, which contained numerous organisms, among others an encapsuled diplococcus, which stained by Gram's method. Nothing abnormal was noted on percussing the chest. On auscultation the vesicular murmur could be detected over the entire area of both pulmonary lobes. The heart was normal, the pulse accelerated (70 per minute). The appetite was good, the animal ate all its food; the fæces were normal. Temperature 40·8° C. The cough, discharge, difficulty in respiration, and coloration of the mucous membranes appeared to indicate that the animal was suffering from pneumonia, still localised in the deep parts of one or both lungs.

Treatment.—Sulphate of quinine, and sulphate and bicarbonate of soda internally; fumigations with menthol (produced by adding a tablespoonful of the following mixture to half a bucket of hot water:

Menthol	10 drachms.
Oil of turpentine . .	10 drachms.
Alcohol	12½ ounces.)

From the 2nd to the 14th June little change occurred. The persistence of fever, cough, and dyspnœa, and the signs furnished by auscultation and percussion, led us to diagnose chronic pneumonia with abscess formation in the lung, or tuberculosis. The fumigations were stopped. Nothing abnormal was found on rectal examination. The discharge contained no tubercle bacilli. The urine was highly charged with deposit and was slightly alkaline, but showed no epithelial casts, or sugar, and very little albumen. The reaction for indican was doubtful.

On the 15th June the chest was punctured, with the hope of obtaining a little pleural liquid for examination; nothing escaped.

The temperature continuing at 40° C., the animal could not be tested with tuberculin.

Until the 25th June the condition slowly grew worse; wasting and weakness became more marked. Respiration was greatly accelerated and painful. Percussion indicated dulness at several points. On auscultation the vesicular murmur was diminished over the entire extent of both lobes, and various abnormal sounds were heard, particularly crepitant râles towards the end of expiration.

On the 28th June the animal was slaughtered.

Lesions.—The abdominal organs appeared normal, but on opening the chest the surfaces of the lung appeared mammilated and bosselated by greyish tumours. Sections exhibited a bright red ground formed by the healthy pulmonary tissue, marked with circular, sharply defined, whitish patches, varying in size between a sixpence and a man's hand, resulting from division of the tumours. The lungs weighed thirty-four pounds. The bronchial glands were only slightly hypertrophied.

The pleural cavity and heart were normal.

On microscopic examination the tumours showed the characters of round-celled sarcoma; but bacteriological examination was carried out in order to dispose of the question of tuberculosis. Numerous sections were made, but no bacilli found. Four guinea-pigs were intraperitoneally injected with an emulsion formed by crushing fragments of the pulmonary tumour in sterilised water. When killed five weeks later they showed neither tuberculous nor sarcomatous lesions.

These pulmonary tumours had the same naked-eye appearances as the lesions in the sarcomatous form of tuberculosis, from which they conld only be satisfactorily differentiated by bacteriological examination and inoculation.

ROUND-CELLED SARCOMA OF THE RIGHT TESTICLE WITH ENORMOUS INTRA-ABDOMINAL TUMOUR IN A HORSE.

202. Sixteen-year-old black cart-horse; a right monorchid.

History.—The animal had been in the possession of a carrier for twelve years, was noted for its great endurance, and had never shown signs of illness prior to the last week of December, 1893.

State on Examination.—Haggard expression of countenance; animal stood with fore and hind legs widely abducted, and showed great disinclination to move. Temperature 105° F.; pulse 65. Appetite fastidious; bowels costive. On careful search a large tumour was found in the right scrotal sac; it extended to the external abdominal ring, was very firm and non-sensitive. A dose of physic was given, and acted freely. On rectal examination on the following day an enormous abdominal tumour was discovered, occupying the right lumbar region, extending forwards to the right kidney, backwards into the pelvic cavity, and downwards to the floor of the abdomen. It was firmly attached to the inferior surface of the rectum.

Prognosis was unfavourable.

From this time onwards the animal became gradually weaker; the

right limb from the haunch downwards became greatly swollen, as did the sheath and subcutaneous connective tissue under the abdomen.

The horse was killed on the 17th January, the autopsy revealing the above-described tumour, which weighed fifty pounds. There was evidence of chronic peritonitis; the abdomen contained several gallons of sanguineous fluid; all the abdominal and thoracic organs were healthy.

Microscopical examination showed the growth to be a round-celled sarcoma.

The testicle was soft and pulpy; all the testicular substance appeared to have been destroyed; the structure of the cord up to the point of junction with the abdominal tumour was normal. The abdominal growth was for the most part firm, glistening on section, and here and there showed evidence of hæmorrhagic infiltration.

Prof. Walley's case, *Journ. Comp. Path. and Therap.*, 1894, p. 66.

CARCINOMA OF THE KIDNEY IN A HORSE.

203. An eight-year-old half-bred bay gelding.

History.—Four months before examination the animal seemed to be easily fatigued, and had fallen away in condition. When turned out to grass it wasted rapidly, and swellings appeared under the belly, in the sheath and hind limbs. On the right side the asternal ribs were outwardly displaced, apparently by some abdominal growth. Pulse 50, weak; temperature 101° F. During the subsequent stages the temperature varied between 101° and 104° F.

Diagnosis.—Enlarged liver.

Slaughter was advised, but a delay of some weeks occurred before the advice was put in practice.

Post-mortem examination showed the right kidney to be enormously enlarged. It was attached above to the psoæ muscles, on the right to the abdominal wall, and below to the double colon. Before incision it weighed seventy-nine pounds, and measured four feet six inches in circumference. The left kidney was nearly double its ordinary size, but otherwise normal.

Microscopical examination showed that the mass was almost entirely composed of a carcinomatous new growth, with a small amount of stroma and epithelial cells of the spheroidal or glandular type.

Mr. G. J. Harvey's case, *Journ. Comp. Path. and Therap.*, 1892, p. 378.

MAMMARY ADENOMA IN THE BITCH WITH PULMONARY METASTASIS.

204. A collie bitch suffering from a tumour about the size of a hen's egg in the mammary gland. Removal was not attempted. The patient had been unwell for about a week, but dyspnœa only appeared two or three days before death, and did not become distressing until twenty-four hours before the end.

On *autopsy* both lungs were found to be enlarged, and did not collapse on opening the chest. The surface of the visceral pleura was

raised by a multitude of small greyish nodules varying in size from a pea to a hazel-nut.

On section these nodules were found throughout the lung separated by a very small but variable amount of lung tissue. Their consistence was that of a hepatised area in the horse; the invaded parts were airless and contained no softened centres. The bronchial glands were enlarged and firmer than normal; some contained black pigmented centres (carbon).

205. A setter bitch with tumour about the size of a man's fist, which was excised. The patient remained dull after operation, but no definite symptoms appeared until the tenth day, when the temperature rose to 105° F., and the respirations became slightly hurried. The temperature gradually rose to 106° F., the symptoms of dyspnœa became more intense, and on the fourteenth day the patient died. The microscopic appearance of the lungs of this animal was practically the same as in Case 204. The nodules, however, were hardly so numerous, nor were they as firm; their consistence was that of a normal testicle.

The microscopical appearance was the same in both cases, and suggestive of what may follow from an infecting agent being arrested in the pulmonary capillaries. At various points the spongy tissue was obliterated by very dense collections of oval-shaped cells resembling certain forms of glandular epithelium, but only in a few cases was there an acinal arrangement. Each cellular area was surrounded by a limiting membrane, which was not of the same thickness in every case. In some cases this membrane was the alveolar wall, in others the interlobular septum; in the latter case the interfibrous spaces were invaded and the fibrous tissue cells were proliferating. The majority of the cells had a diameter of 5 μ; a few were somewhat larger. The segmentation of their nuclei indicated the activity with which they were dividing. In the more open parts the alveolar walls were thickened, and their cavities contained a few catarrhal cells. The new formations in the bronchial glands were identical in structure with those in the lungs.

Note.—Adenomata are the commonest malignant neoplasms in the bitch, and their primary seat is usually in the mammary gland. The two cases just described show in how astonishingly short a time the secondary (metastatic) growths may develop; they give an idea of when symptoms of secondary formation may be expected after operation, or in other words at what date after operation a favourable prognosis may be ventured on. In both cases symptoms of dyspnœa only occurred a few days before death, in Case 205 on the tenth day after that on which we might assume the infecting agent gained the venous stream. During this time the new cells were actively dividing and obliterating the lung tissue, which on the fourteenth day was so far destroyed as to render life impossible. As the primary lesion was in the mammary gland, and the secondary growths in the lungs and bronchial glands, it is probable that the infecting agent travels both by the venous and lymph streams.

Prof. Stockman's cases, *Journ. Comp. Path. and Therap.*, 1895, p. 254.

INFECTIVE GRANULOMA IN A MARE.

206. Ten-year-old bay cob mare.

History.—About the beginning of 1899 the animal showed incontinence of urine, which continued for a time without improvement.

A local adviser was called in, who prescribed, and the animal seemed to recover somewhat, but symptoms recurred soon afterwards. Naturally the almost continuous urination caused irritation and inflammation of the skin of the thighs, and ultimately developed raw sores. There was also a difficulty experienced in defecation. Gradual atrophy was observed to occur on the right side of the back behind the

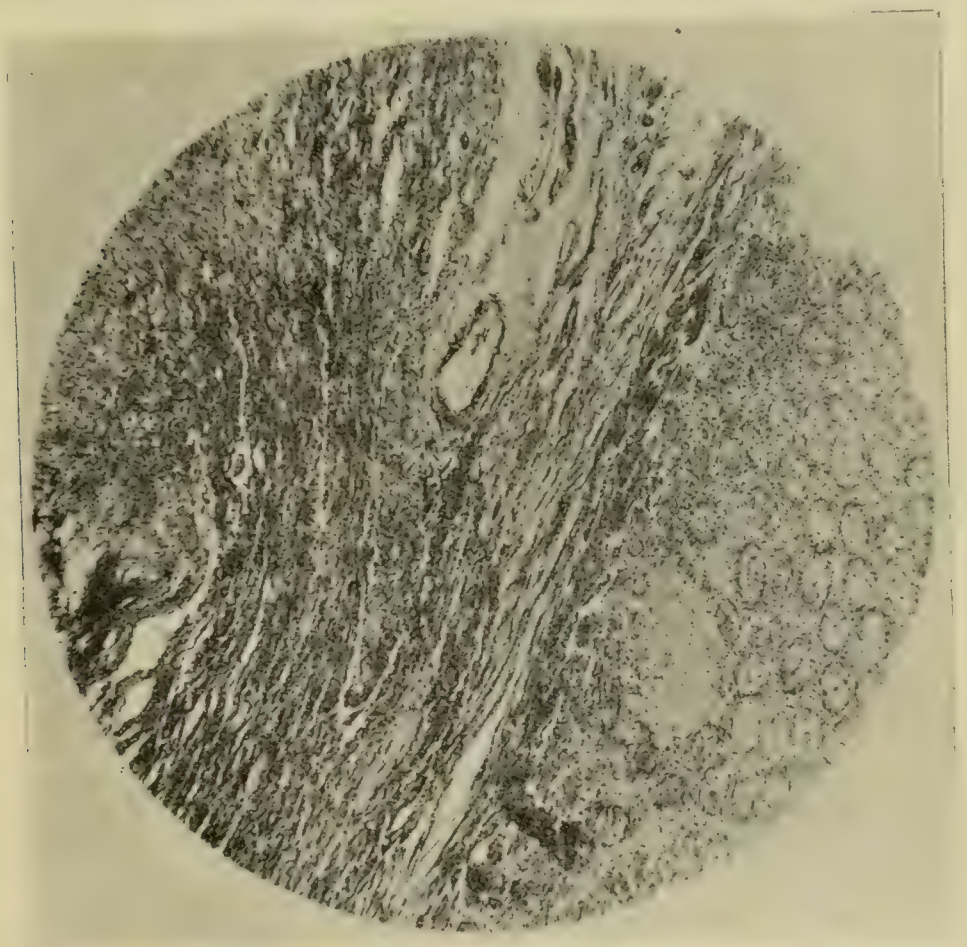

FIG. 74.—Malignant granuloma. Mare: section of stomach. ($\frac{2}{3}$ in. obj.; camera length 18 in.)

withers, just underneath the seat of the saddle, for a period of six to eight months before death. At last the owner had the animal slaughtered.

Post-mortem Examination.—"The animal was in poor condition. The pulmonary pleura was thickened and indurated, while large patches of the lung beneath were firm, very dense to the touch, and almost cartilaginous on section. The growth was in large areas, lying more or less underneath the pleura, and the inferior border of the lung, bronchi, and blood-vessels showed thickening to a great extent, while here and there in the diseased area small caseous nodules were discern-

ible. The thoracic lymphatic glands were apparently not affected. The liver contained large whitish fibrous areas scattered throughout its substance, and the diaphragm had attached to its posterior surface a number of yellowish nodules about the size of a pea. The wall of the stomach was very much indurated, being at places about an inch thick from the mucous to the peritoneal surface, and composed of hard, dense, fibrous growth, showing on section here and there small caseous foci, from the size of a pin's head to that of a wheat seed. The internal mucous surface was inflamed, and felt tough. The portion of the organ

FIG. 75.—Malignant granuloma. Mare: section of lung showing cirrhosis, periarteritis, peribronchitis, and distended lymph spaces.

affected was chiefly the greater curvature. The supra-renal bodies were enlarged. The ovaries were very much enlarged, and of the same dense fibrous consistency as the other organs affected. The walls of the uterus and of the bladder were also thickened and œdematous, the mucous surfaces being inflamed and raw-looking. The bladder contained a quantity of blood-coloured fœtid urine and a considerable quantity of calcareous deposit, the mucous membrane being inflamed and hæmorrhagic." Specimens of the different organs were preserved in a solution of "formalin." The pathological changes were evidently

due to the growth of new fibrous tissue, which was of a dense nature, feeling almost like hard india rubber, and of a peculiar dirty yellow colour.

Sections were made of various portions of the different organs, and the new growths ascertained to be composed of dense fibrous tissue. The appended photographs show the microscopical appearance of the lung and stomach. At first the case was regarded as due to actinomyces or botryomyces ; but, although sections were stained by every conceivable method, Mr. Gilruth failed to demonstrate to his own satisfaction any organism that might be looked upon as the cause of this peculiar condition. The caseous foci, where sections were stained with carbol-fuchsin and decolourised with picric acid, showed a few small points which retained the red stain, but it was doubtful whether these were even parasitic in nature.

In the photograph of the lung the intensity of the periarteritis and peribronchitis will be observed, as also the sharp line of demarcation between the fairly healthy and diseased tissue; and in that of the stomach the spread of the round-cells between the altered gastric glands, with the dense fibrous tissue underneath, will be noted with interest.

Mr. J. A. Gilruth's case, *Veterinarian*, 1900, p. 298.

PART IV.

EXPERIMENTAL AND COMPARATIVE PATHOLOGY.

I.—A CONTRIBUTION TO THE STUDY OF AVIAN TUBERCULOSIS.

(In collaboration with MM. Gilbert and Roger, Fellows of the Paris Faculty of Medicine, Doctors of Medicine.)

I.—HISTORICAL.

NUMEROUS memoirs published during the last thirty years have shown that tuberculosis is common in birds. Leisering, Larcher, Paulicki, Zürn, and certain others have published very interesting cases, but it may fairly be asked whether all were cases of true tuberculosis due to the microbe which Koch discovered in man. This doubt, however, seems to have been removed since Koch, Ribbert, Babes, Cornil, and Mégnin found in tuberculous material obtained from fowls a bacillus showing the same staining properties as that found in mammals.

MM. Nocard and Roux cultivated this bacillus, and their cultures, submitted to many observers, served for a large number of experiments. The identity of the two forms of tuberculosis was freely admitted,—indeed, could scarcely be doubted when innumerable experiments showed that the rabbit could be inoculated with avian tuberculosis, and when several observations appeared to establish the transmissibility of human tuberculosis to birds.

In 1873 Bollinger reported that eight pigeons had been contaminated by eating the expectorations of phthisical patients; in 1885 he also published several similar cases. Koch, Nocard, Mollereau, Chelchowsky, de Lemallerée, Durieux, and Cagny all published observations, or experiments, which seemed to place the conveyance of

human tuberculosis to fowls beyond question. Nevertheless some contradictory facts arose from time to time. It was recalled that Villemin had not been able to transmit tuberculosis to a cock and a wood-pigeon; M. H. Martin always failed in attempting to inoculate fowls by intra-peritoneal injection with tuberculous material derived directly from man, or with material which had been passed through the guinea-pig. But the idea of the unicity of avian and human tuberculosis had already struck deep, and M. Martin carefully guarded against the conclusion that fowls are proof against human tuberculosis; he only thought his failures due to his having made intra-peritoneal inoculations, or having introduced too small a number of bacilli.

Rebutting facts soon began to accumulate. MM. Straus and Wurtz fed six hens and a cock for six to twelve months with phthisical sputum. The animals resisted, and *post-mortem* examination showed their organs to be perfectly healthy.

Riffi and Gotti also declared that the tuberculosis of mammals did not affect the Gallinaceæ. Rivolta laid stress on the considerable differences between avian and human tuberculosis; he found that tuberculous products from the fowl did not produce general infection in the guinea-pig, the lesions being confined to an abscess at the point of inoculation. The same results occurred in the rabbit, though in this animal a few tubercles developed in the lungs.

The study of tuberculosis in the Gallinaceæ was again taken up by Maffucci. This author recognised that avian virus was transmissible to fowls; that in the rabbit it behaved as Rivolta had stated; and that in the guinea-pig its action varied according to the point of injection. The animal usually resisted inoculation into the subcutaneous connective tissue though it showed a local lesion; in other cases it died at the end of some months in an extremely emaciated condition, and on *post-mortem* examination the liver and spleen were found atrophied; no tubercles were seen, and microscopical examination and cultures revealed no bacilli. After intra-peritoneal inoculation the animals died within a period varying between fourteen days and three months; if development had been rapid the organs were infiltrated with embryonic cells and filled with bacilli; in more prolonged cases atrophy of the liver and spleen were alone found. Inoculation into the lung produced interstitial inflammation; the bacilli remained localised, and did not invade abdominal viscera; after intra-venous inoculation guinea-pigs died in fifteen, twenty, or twenty-five days, and on microscopic examination the liver appeared infiltrated with embryonic cells containing numerous bacilli. Finally Maffucci showed that mammalian

tuberculosis cannot be transmitted to the Gallinaceæ: twenty fowls inoculated under the skin, in the stomach, lung, peritoneum, and veins all resisted.

The interesting researches of Rivolta and Maffucci therefore again rendered it doubtful whether tuberculosis is identical in various species of animals. This doubt was shared by Koch, who announced at the Berlin Congress that he had resumed the study of the question, and that in his view the tuberculosis of birds was not in all respects similar to that of mammals. At this time we published a preliminary note on the same subject. Relying on a considerable number of experiments we showed that avian tuberculosis can be transmitted to the Gallinaceæ; that in the rabbit, intra-peritoneal inoculation with avian material produces generalised miliary tuberculosis; whilst in the guinea-pig it usually produces either no lesion whatever, or only a few little visceral tubercles. In some cases, however, avian, like human tuberculosis, is capable of producing visceral granulations in the guinea-pig. Nevertheless, speaking generally, the avian virus behaves differently in the rabbit and guinea-pig. The latter animal, though very sensitive to mammalian tuberculosis, appears very resistent to the tuberculosis of Gallinaceæ.

In spite of the differences which we observed between the two viruses we at that time avoided coming to any fixed conclusion as to their nature.

Regarding the importance of these differential characters, we said: "The bacilli of human and avian tuberculosis are regarded as two distinct species, or two varieties of one species. At present it is very difficult to settle the question; study of other microbes has shown that their form, development in various culture media, and powers of resistance and virulence are by no means fixed quantities, and vary under different circumstances. This question may possibly be cleared up when we know how the bacillus of human tuberculosis behaves when inoculated into birds." We therefore undertook researches in this direction, and were led to regard the two bacilli as representing two varieties of one species.

During this time M. Nocard had resumed his previous experiments. He again attempted to transmit mammalian tuberculosis to the Gallinaceæ. This time his results were negative, and he concluded that in his first experiments he must accidentally have utilised a number of fowls which had previously suffered from avian tuberculosis.

Finally MM. Straus and Gamaleia, in an important memoir, demonstrated in striking fashion the differences between the viruses of the two tuberculoses. Among the new facts contributed by these savants

is one of considerable importance, namely, that the dog reacts in an entirely different way to the two viruses. It readily contracts human, but resists avian tuberculosis. The authors were thus led to conclude that the two bacilli are entirely different, and represent two distinct species.

On our side we continued the comparative study of the tuberculosis of birds and mammals. Our research, though prosecuted for the past two years, is far from ended, but we have noted certain facts deserving of publication. On the basis of our own researches, and of others of earlier and later dates, we shall endeavour to set forth the history of avian tuberculosis.

II.—ÆTIOLOGY.

Tuberculosis affects the fowl as well as man with remarkable frequency. Of 600 fowls examined after death by Zürn, 62 were affected with tuberculosis. If this result truly reflects the facts tuberculosis would account for more than 10 per cent. of the mortality in these birds.

Pheasants, guinea-fowls, turkeys, peacocks, and pigeons are also, though less frequently, victims of tuberculosis. In order to discover the means by which the disease is introduced into aviaries and poultry farms, we undertook several inquiries and addressed a list of questions to nineteen owners or breeders who had sent us tuberculous birds. Some gave no reply; others useless information. We were only able to collect eight almost complete records of tuberculosis among fowls.

In three of these epizootics tuberculosis had clearly been introduced by newly purchased birds. The first outbreak attacked poultry without affecting pigeons; the second was confined to pheasants; the third to pheasants and poultry without affecting the peacocks.

In the five other epizootics the origin of the disease remained obscure. In three, fowls alone were affected; in one, fowls and turkeys; in the last, pheasants. Of the three epizooties in which fowls were affected one occurred in a new fowl run, which had only been inhabited for eight months; another in a fowl run occupied for two years; the last in a run where no new birds had been introduced during the previous five years. The epizootics which attacked pheasants had not been preceded by any importation of birds for a very long series of years.

In one of these cases we were able to discover that the person who looked after the fowls coughed and expectorated a greal deal, but examination of his sputum failed to reveal the presence of tubercle

bacilli, and we had every reason to believe that he was affected with chronic bronchitis. In another we learned that at the time of the outbreak the fowls were under the charge of a young woman who after showing cough and expectoration for more than a year, had become thin and was regarded as suffering from tuberculosis.

In only one of the attacks were we justified in supposing that the birds had been inoculated by the sputum of a phthisical patient, as in the cases related by Bollinger, Nocard, Mollereau, Chelchowski, de Lemallerée, Durieux, and Cagny. In no case were we led to suspect the ingestion of milk, or meat, from tuberculous animals, as in MM. Guerrin and Baivy's cases.

When tuberculosis is imported by new birds, these die first, and the disease afterwards attacks others. The mischief is rarely confined to a few, or to one fowl, as, however, happened in one of our cases; usually it extends successively to a large number; sometimes it continues for years (four years in one of our cases), and ends by completely clearing the run.

The owners of these badly infected fowl runs not infrequently sell the surviving birds, which being thus distributed among healthy subjects communicate the disease to them.

The contaminated fowl runs are afterwards cleansed, disinfected, and restocked, but even when they have remained empty for several months the new birds, though at first healthy, soon become ill and die of tuberculosis.

Observation of these epizootics leaves no room for questioning the contagious character of tuberculosis in fowls. Contagion occurs through the medium of the intestinal dejections, which in some cases contain very large numbers of bacilli. Being ingested with the food the bacilli pass through the intestine and gain the peritoneum, liver, spleen, and in rare cases other organs. In about half the cases the passage of bacilli through the intestinal wall leaves no trace. Under such circumstances the intestinal contents are probably free of bacilli, and the birds are incapable of transmitting tuberculosis. But in other instances inoculation is marked by the intestine itself becoming tuberculous and ulcerated. The dejections are then rich in bacilli, the distribution of which over the ground explains the propagation of disease.

III.—SYMPTOMS AND PATHOLOGICAL ANATOMY.

Symptoms.—The signs indicative of tuberculosis in fowls are, during life, usually very vague. The birds become progressively thinner, and

the amount of wasting may be estimated by palpation of the thorax over the breast-bone; the pectoral muscles fall away and the bone projects prominently. At the same time other phenomena peculiar to wasting may be noted: the comb loses its red colour, and the mucous membranes become pale. The birds die in this condition; towards the end paralytic symptoms have several times been observed.

Under these conditions diagnosis is difficult, but tuberculosis may be suspected because it is the most frequent cause of wasting. Under certain cicumstances, however, the observer may feel more certain of the nature of the disease, viz. when external manifestations occur, such as specific changes in the mucous membranes of the head, in the subcutaneous connective tissue, and in the bones or joints; in the latter case considerable swellings may occur, especially over the articulations of the wings and feet.

Pathological Anatomy.—On *post-mortem* examination the intestine is found affected in about half the number of cases. The peritoneum is sometimes, and the spleen and liver are almost constantly, the seat of new growths.

Tuberculosis of the liver is indicated by the existence on its surface and within its substance of tubercles varying in size between that of fine dust and of a hazel-nut, but usually of about a pea. The superficial nodules adhere to Glisson's capsule, beneath which they sometimes form slight projections. Whether superficial or deep-seated they are whitish in colour when small, and greyish or yellow when of larger size. Their shape is spherical, conical, or irregular; and they may be simple or confluent. They increase both the size and weight of the liver in proportion to their extent and number, which latter is usually considerable.

The hepatic tissue between the tuberculous nodules is not always unaffected; on the *post-mortem* examination of two fowls affected with "spontaneous" * tuberculosis we found in the right hepatic lobe large hæmorrhagic infiltrations; in one the blood had traversed Glisson's capsule and passed into the peritoneal cavity.

In two pheasants affected with "spontaneous" tuberculosis, and in four fowls which had been inoculated with avian tuberculosis, we found fibrinous ascites; in three cases this condition existed independently of any change in the peritoneum, and appeared therefore to have resulted from the hepatic lesions. On the other hand, six cases showed peritoneal tuberculosis without ascites.

After the liver the spleen is the organ most frequently invaded.

* By the term "spontaneous" tuberculosis is here meant tuberculosis not produced by experimental inoculation.—Jno. A. W. D.

Sometimes its parenchyma is filled with small granulations; sometimes it contains large tuberculous areas.

In all our observations of "spontaneous" tuberculosis the kidneys and lungs remained unaffected.

In about half the cases the intestinal mucous membrane showed either small tubercles, or ulcerations of greater or less depth. The latter lesions, which indicate the point of entry of infection, also serve to propagate the disease; examination of the intestinal contents several times resulted in the discovery of bacilli.

We should also mention the occurrence of tuberculous lesions in

Fig. 76.—Tuberculosis of the liver (fowl).

the subcutaneous connective tissue, in bones, articulations, and periarticular tissues, a condition which, according to Friedberger and Fröhner, is fairly frequent. We saw a remarkable case of tuberculous arthritis of the femoro-tibial articulation. The lesion occurred in a fowl dead of spontaneous tuberculosis, and was extremely rich in bacilli.

Tuberculosis of the pheasant and of the fowl are practically indistinguishable to the naked eye, but on applying iodine solution the tubercles in the pheasant assume the mahogany coloration characteristic of amyloid degeneration.

Histology.—Histologically the lesions in the fowl and in the pheasant vary to a marked extent. This was shown by microscopic exa-

minations carried out principally on the liver, an organ which readily lends itself to a study of this character.

In the pheasant the smallest tubercles are formed by a central mass of epithelioid cells surrounded by round cells.

In the largest tubercles the centre displays a cavity containing epithelioid cells, either crowded together in large numbers, or few and separate. This cavity, being more or less rounded and usually sharply delimited by a layer of dense connective tissue, might be mistaken for a vessel unless care were taken to examine a series of preparations. It is surrounded by layers of epithelioid cells. The latter are separated from one another by connective tissue attached to that surrounding the central cavity. Finally, the periphery of the tubercles is often surrounded by a layer of round cells.

The largest tubercles show two well-defined zones, a central and a peripheral. The internal is chiefly formed by a compact or vacuolated connective tissue, the cells of which, however, display no nuclei capable of being stained. Here, again, we find the pseudo-vascular cavity, which only contains shapeless cellular débris and granulations. The peripheral zone is composed of masses of epithelioid cells separated by connective tissue, and is surrounded by round cells.

Such is the structure of the simple tubercles. At many points these approach, touch, or become mutually fused together, so much so that in the internal zone of the largest tubercles, for example, one generally finds several cavities resembling blood-vessels.

The epithelioid cells which enter into the formation of the tubercles are generally provided with a single nucleus; a certain number, however, possess several, and some, of enormous size and principally situated in the centre of the tubercles, are half surrounded, or even completely surrounded, by nuclei, forming true giant-cells.

The connective tissue of the tubercles is coloured brownish red by a watery solution of iodine, and rose-red by methyl violet, thus resembling amyloid material.

The bacilli in the tubercles stain readily by Ehrlich's or Herman's methods. They are either isolated, or, as has been well figured by MM. Cornil and Mégnin, collected in more or less rounded clumps, surrounded by epithelioid cells. Though numerous in the epithelioid "nests," of which the smallest tubercles consist, they are even more common in tubercles of medium size, particularly in their pseudo-vascular spaces, where they often form compact masses. They partially or entirely disappear in the internal zone of the largest tubercles.

The hepatic tissue between the tubercles shows no alteration, and

in particular presents neither fatty nor amyloid degeneration, nodular hepatitis, nor cirrhosis.

The preceding histological details would appear to suggest that in the pheasant the development and subsequent course of hepatic tuberculosis is somewhat as follows. A colony of tuberculous bacilli first becomes arrested at some point in the liver, where the bacilli multiply and cause a local reaction, indicated by the production of a nest of epithelioid cells. Around this nest round cells group themselves, and a limiting connective-tissue membrane forms, which on section resembles the wall of a blood-vessel. This barrier is insufficient to prevent the spread of the tuberculous process. The bacilli pass it, extend beyond, multiply, and cause the development of fresh nests of epithelioid cells, which become surrounded by fresh fibrous limiting membranes. The bacilli thus gradually progress, exciting an epithelioid reaction and further formation of fibrous tissue, which, as we have seen, undergoes amyloid degeneration. When the tubercles attain a certain size the connective tissue in the central parts becomes thickened, the epithelioid cells undergo degeneration, and the bacilli cease to stain, but their periphery presents an active zone extremely rich in bacilli and epithelioid cells, the further growth of which only ceases with the death of the animal.

In the fowl the smallest tubercles are formed of a mass of epithelioid cells, surrounded by others of a spherical and fusiform outline. The larger show a central necrotic, hyaline portion coloured brown by picro-carmine. Around this hyaline centre is arranged a border of epithelioid cells, usually of considerable size, and always containing a large number of nuclei, which stain vividly with carmine. These cells are generally elongated, and more or less cylindrical in shape, and are arranged perpendicularly to the hyaline zone; they contain nuclei principally collected at that extremity of the cell farthest from the hyaline zone. It might thus seem at first sight as though the hyaline mass were contained within a bile-duct, in the same way that a superficial examination might suggest the existence of vascular cavities at the centre of the tubercles in the pheasant. Outside the border formed around the hyaline zone by the above-mentioned epithelioid cells are masses of ordinary epithelioid cells. The extreme periphery of the tubercle is indicated by round and fusiform cells.

Certain tubercles of similar size to the preceding are simply formed by masses of epithelioid cells, without the hyaline zone and border of epithelioid cells which distinguish the former. In other tubercles, on the contrary, the central epithelioid mass shows a hyaline zone and a

border of epithelioid cells, distinguished from the others by their direction, form, large size, number, and by the position and staining of their nuclei. In some of these tubercles the hyaline zones tend to become, or do in reality become, fused.

The largest tubercles, composed of large numbers of epithelioid masses, display a faint indication of a connective-tissue capsule. The hyaline degeneration is then extensive, and replaces the epithelioid cells. Certain of these tubercles resemble old syphilitic gummata, and appear simply formed of an encapsuled hyaline mass.

In tuberculosis of the fowl the bacilli stain readily by Ehrlich's method. They are contained in very large numbers in the epithelioid cells, and though usually isolated are sometimes collected in clumps, as in tuberculosis of the pheasant. They are also found in the smallest tubercles formed of a simple mass of epithelioid cells. In the larger tubercles they are more numerous, particularly in the vitreous zone, where they appear of great size and with a tendency to branch: the epithelioid border of the hyaline zone, on the contrary, contains extremely few; under any circumstances it contains much fewer than the epithelioid masses towards the periphery of these tubercles.

The first stage in the tuberculous process in the liver of the fowl, as in that of the pheasant, is therefore marked by the development, in consequence of microbic irritation, of an epithelioid mass, which is surrounded by spherical and fusiform cells. Around this primary mass of epithelioid cells others successively form. The centre of the primary clump of cells undergoes hyaline degeneration, as does that of the later formations; necrobiosis tends to replace the tuberculous neoplasis, whilst a fibrous barrier develops around the periphery of the tubercle. The tubercle may thus cease to grow, and become completely transformed into an encysted hyaline mass. But this is exceptional; whilst the older portions of the tubercles undergo degeneration bacilli escape through the imperfect fibrous barrier which surrounds them and spread into healthy tissue, in which they produce a crop of fresh tubercles.

To sum up, although the initial stages of tubercle formation in the liver of the fowl and of the pheasant are identical, later development is marked by notable differences.

In the pheasant the tubercle bacillus causes development of epithelioid cells; these soon undergo molecular degeneration and are succeeded by formation of abundant connective tissue, which surrounds pseudo-vascular cavities and undergoes amyloid degeneration.

In the fowl the epithelioid cells undergo hyaline necrobiosis, which,

though at first limited to the centre of the tubercle, and producing the appearance of a clear centre surrounded by special epithelioid cells, afterwards extends to the whole of the new growth and tends to encystment.

The histological appearances of tuberculosis of the liver in the fowl and in the pheasant so greatly differ that at first sight the micro-organisms producing the lesions might be regarded as of different species. This interpretation, however, would be erroneous.

We have inoculated from the pheasant to the fowl, and in the liver of the latter have found histological lesions identical with those of spontaneous fowl tuberculosis.

Although the production of tubercles, both in the fowl and in the pheasant, is due to the same bacillus, the development of these growths is none the less affected by peculiarities of the host. It is the story once more of the grain and the soil. Not only do the hepatic tubercles in the fowl and pheasant differ from hepatic tubercles in mammals, but they vary to a marked extent between themselves, although developed in such nearly related species. We cannot lay too much stress on this fact, which throws so prominently into relief the pathological peculiarities of animals, and which shows how dangerous it is to indulge in general conclusions drawn from experiments on a single species.

IV.—EXPERIMENTAL STUDY.

Only one method existed of determining the nature of avian tuberculosis, viz. the experimental. Only after having shown how the virus of avian tuberculosis behaves in mammals, and how that of mammals behaves in birds, could we even attack the continually recurring problem of the unicity of tuberculosis in various species of animals. We may therefore divide this chapter into two parts, and we shall commence by giving the particulars of experiments made with avian tuberculosis.

Part 1.—Inoculation Experiments with Tuberculosis of the Gallinaceæ.

To study the effects of the avian virus we directly inoculated from lesions developed in the Gallinaceæ and utilised in our experiments a considerable number of birds drawn from different localities, a fact which may be regarded as giving a certain general character to our results, and also explaining some apparently contradictory results which we have observed.

We obtained our virulent material from eleven subjects—eight fowls, two pheasants, and one guinea-fowl—sent us by different owners and breeders. In all these animals *post-mortem* examination showed

the existence of tuberculous lesions, and bacteriological examination revealed the presence of the characteristic bacilli. For our inoculations we utilised growths from the liver. Fragments of the viscus were crushed in sterilised water, and the emulsion thus obtained was injected into a certain number of animals. Unless otherwise indicated, all inoculations will be understood to have been made into the peritoneal cavity.

Inoculation of Fowls.—That the Gallinaceæ may be inoculated with avian tuberculosis has been placed beyond doubt by the study of epizootics in fowl runs, and by a certain number of experimental researches. We did not therefore undertake numerous experiments on this point.

Six fowls were inoculated with spontaneous avian tuberculosis. Two received the virus in the axillary vein; they fell away in condition, and died at the end of thirty-nine and fifty-three days respectively. The liver and spleen were crammed with tubercles; in one abundant fibrinous ascites and peritoneal granulations were discovered. The four others were inoculated in the abdominal cavity; they died at the end of from forty-one to ninety-three days. *Post-mortem* examination revealed the presence of numerous granulations in the liver, spleen, and on the peritoneum; in two cases the abdominal cavity contained a rather abundant fibrinous liquid. In all these animals histological examination of the liver showed the presence of bacilli and of lesions similar to those found in cases of spontaneous* tuberculosis.

On another occasion we attempted to transmit in series these tuberculous products; the result was negative: the second fowl, killed at the end of 165 days, showed no lesion. This result should, however, be regarded as absolutely accidental, and was probably due to a peculiar resistance on the part of the animal inoculated. The history of other infectious diseases reveals analogous occurrences. In another case we performed series of inoculations, and were able to transmit tuberculosis in succession to four fowls.

Inoculation of Rabbits.—Numerous experiments carried out in France with avian cultures showed that the rabbit is very sensitive to this form of tuberculosis. Intra-peritoneal inoculation produces visceral granulations, and intra-venous inoculation has the same effect, provided too large a quantity of virus be not injected, otherwise the animal dies with lesions of the Yersin type.

The results of avian inoculation in the rabbit being already fairly well known, we only made a few experiments. Five rabbits were inocu-

* As already mentioned, by spontaneous tuberculosis is here meant disease not produced by experimental inoculation.—JNO. A. W. D.

lated in the abdominal cavity with a few drops of an emulsion prepared from the liver of tuberculous fowls: three of them died between sixty-nine and eighty-seven days after inoculation; another was killed at the end of 108 days. In these four animals *post-mortem* examination showed generalised tuberculosis; the peritoneum, and especially the epiploon, were dotted over with little tuberculous granulations; the liver and spleen were crammed with them; the lungs and kidneys, however, contained a smaller number. Several times we microscopically examined the invaded organs, which we found contained large numbers of bacilli; the structure of the tubercles showed nothing special.

We must now mention an experiment in which the development of avian tuberculosis showed peculiar features.

On the 16th June, 1890, two rabbits were inoculated from the liver of a fowl. One died in sixty-nine days from generalised tuberculosis. The other remained in good health until the 3rd January, 1891, at which time swelling of the right hock was noted; some days later the radio-carpal joint of the same side was in turn attacked. On palpation numbers of fungous growths could be detected developed around the joints first invaded; these soon projected beneath the skin; at the antero-external part of the carpal region they perforated the skin, and appeared externally as reddish, soft granulations. In order to make certain as to the nature of the articular lesions, we had, before the external appearance of the granulations, punctured the parts aseptically with a Pravaz's syringe, and thus obtained a few drops of liquid containing the characteristic bacilli.

In spite of the existence of these fungating growths the animal's general health remained excellent, and its condition even improved. On the 5th January the subject weighed 5 lbs. 9½ oz. At that time we subcutaneously injected ·25 c.c. (that is at the rate of 0·1 c.c. per kilo. of body-weight) of tuberculin. We had previously satisfied ourselves that a similar or even larger dose produced no disturbance in a normal rabbit. The injection was made at 11 a.m., and the animal seemed to experience no effect throughout the day. At 7 a.m. next morning, however, it was dead.

On *post-mortem* examination the lungs were found engorged with blood; they contained a few disseminated tuberculous granules. The liver was congested, and contained five or six tubercles; two were also found in the spleen, which was of very large size. The kidneys were enormous and violet in colour: they only contained two or three little granules. Examination of the affected joints showed that the fungating growths had invaded the synovial membranes and periarticular tissues.

This case, which we reported to the Société de Biologie, appeared to us interesting for several reasons. It furnished a new example of varying resistance in two animals of the same species inoculated in the same way. It furnished a good type of experimental tuberculous joint-disease. Finally, it showed that animals affected with avian tuberculosis reacted to tuberculin like animals affected with human tuberculosis; in both cases large doses of tuberculin produce death with intense congestive symptoms precisely similar to those just described.

To sum up, avian tubercular material, when inoculated into the peritoneum of the rabbit, generally produces tuberculous granulations; in most cases all the viscera are affected, and death occurs on an average at the end of eighty days. In some cases, however, the animals remain to all appearance in good health, and when killed astonish the experimenter by displaying generalised tuberculosis.

It will be seen how greatly our results differ from those of Rivolta and Maffucci. These two Italian investigators regard avian tuberculosis as scarcely pathogenic for the rabbit, and as only producing a few very discrete pulmonary granulations. From our experiments it will be seen that the virus, when introduced into the peritoneum, produces generalised tuberculosis, and, in fact, acts on the rabbit as does mammalian tuberculosis.

Inoculation of Guinea-pigs.—The experiments of Rivolta and Maffucci have shown, as we said, the great difficulty of transmitting avian tuberculosis to guinea-pigs. MM. Cornil and Mégnin, who inoculated two guinea-pigs, failed to discover any visceral changes when the animals were killed two months later; the subjects only showed an abscess containing bacilli in the abdominal wall. They thought that generalisation would have occurred had they waited longer before terminating the experiment.

MM. Straus and Gamaleia, after intra-peritoneally inoculating guinea-pigs with avian tuberculosis, found that death occurred in two to four weeks. On *post-mortem* examination no lesion was found, or the spleen simply appeared rather large and red; in whatever way the material was introduced, tubercles failed to develop. These observers several times detected bacilli in the viscera, but the organisms had never produced any formation of nodules.

Our experiments extended to twenty-four guinea-pigs, which were intra-peritoneally injected with emulsions prepared with material from the livers of tuberculous birds. In several cases we simultaneously injected a few drops under the skin.

In the latter cases the results were as follows:—At the point of inoculation a small caseous abscess containing numerous bacilli formed, but healed in a few weeks. Whether or not this local lesion developed, the lymphatic glands in the neighbourhood of the inoculated spot (in this case the inguinal glands) generally became enlarged; instead of extending and becoming generalised, however, this glandular inflammation, which was especially marked from the eighth to the ninth or twentieth day, retroceded, and ended by disappearing. Most frequently the animals remained in good health, and did not fall away in condition. They showed nothing indicating disease; a local infection, characterised by the inoculation abscess and by inflammation of lymph-glands, certainly occurred at the time, but these lesions were temporary, and rapidly disappeared.

Of twenty-four guinea-pigs inoculated six died spontaneously, one rapidly in 16 days, as in Straus and Gamaleia's experiments; the others lived for a period varying between 30 and 164 days. The *post-mortem* examination of these animals was negative, in the sense that examination of the viscera showed no lesion resembling tuberculosis. We simply add that one guinea-pig showed at the point of inoculation in the peritoneum a small, entirely encysted caseous abscess.

The other animals remained in perfect health, and were killed between the 111th and 248th day after inoculation; in nine the results were negative; there was no appreciable lesion except in one guinea-pig, which showed a little encysted abscess in the peritoneum.

In short, of the fifteen guinea-pigs inoculated with avian tuberculosis which died spontaneously, or were killed, the organs remained absolutely unaffected; no appreciable lesion was found except in two animals, each of which exhibited a caseous abscess similar to those already discovered by Cornil and Mégnin.

Six other guinea-pigs were killed like the preceding whilst still in very good bodily condition, but the autopsy showed the presence of tuberculous granulations. The number and the localisation of these, however, differed entirely from what has been noted after inoculation with human tuberculosis; instead of becoming generalised the lesions were confined to one or two viscera, or to the peritoneum; in one case the serous membrane was alone affected, five or six miliary granulations being found in the perihepatic portion. In addition, infection had extended to the liver and spleen, but careful examination was required to detect it. Each of these viscera contained three or four small granulations, so that the appearance of the organs was hardly modified. In particular the spleen showed none of the hypertrophy generally seen in experimental tuberculosis in rodents.

In two cases the lesions were again very different from those usually observed; the abdominal organs were normal, the lungs alone containing two or three pearly tubercles, the size of millet-seeds, projecting beneath the pleura.

Microscopic examination of these lesions revealed bacilli remarkable for their size, which was somewhat greater than that of the human bacillus, and for their more granular appearance.

The pulmonary new growths were formed of a mass of epithelioid cells; giant-cells were absent, and the periphery of the lesions exhibited very few embryonic cells.

The hepatic tubercles had a special appearance. In one case the granules were formed of a caseous centre surrounded by a fibrous zone; in another, a tubercle had been entirely transformed into a fibrous mass; this was unquestionably a tubercle in course of healing.

Histological study, therefore, showed that the lesions produced in guinea-pigs by inoculation with avian tuberculosis tend to become localised and to heal. This tendency towards spontaneous recovery had already been suggested by the course taken by the local tubercle resulting from inoculation and by the glandular inflammation.

To sum up, avian tuberculosis behaves quite differently in the rabbit and in the guinea-pig. This fact, which escaped Rivolta and Maffucci, and which we were the first to note, has been confirmed by the researches of different authors, and by the results of further experiments which we have carried out. Thus we are led to conclude that avian, unlike human tuberculosis, is more active in the rabbit than in the guinea-pig. In the latter animal it either causes no lesions, or gives rise to a caseous abscess, or finally produces a few rare visceral tubercles, which scarcely interfere with the animal's general health, and tend to undergo fibrous transformation, that is, to heal.

But although the results just noted are generally constant, they are subject to certain exceptions.

A guinea-pig which had been inoculated with a fragment of liver from a fowl, which again had been inoculated from the liver of a pheasant, died at the end of 103 days. At the autopsy it was found suffering from generalised miliary tuberculosis; the peritoneum contained a certain quantity of serous liquid; the liver, which weighed $1\frac{5}{8}$ ounces, and the spleen, which weighed $2\frac{1}{4}$ drachms, were crammed with tubercles; the lungs also showed granulations. The lesions were, in fact, similar to those seen after inoculation with human tuberculosis.

From this guinea-pig a second was inoculated. The latter remained

in perfect health; when killed at the end of 141 days its condition appeared perfectly normal; *post-mortem* examination revealed the existence of five or six scattered tubercles in the liver and lungs; the spleen was healthy. The virus, instead of increasing in virulence, seemed therefore to have become attenuated by passage through two guinea-pigs.

To continue the series we inoculated another guinea-pig and a rabbit from the liver of this animal. The guinea-pig died on the 109th day, a dozen granulations being found in its liver. The rabbit remained in good health and was killed at the end of 139 days. The cadaver showed numerous granulations remarkable for their localisation; instead of having invaded the liver and spleen they occupied the lungs, mediastinal lymphatic glands, and kidneys. To test the results of inoculation with this virus, which had behaved in such a peculiar manner, we utilised it to inject a guinea-pig and two fowls. The guinea-pig remained in apparently good health, but on killing it at the end of 169 days we were not a little surprised to find it suffering from generalised tuberculosis; the lungs, peritoneum, spleen, and liver were filled with granulations; the liver was the seat of very marked cirrhosis, which rendered its surface bosselated and deeply channelled. The fowls were killed at the end of 169 and 176 days respectively, but the autopsy revealed no appreciable lesion.

Thus after passing three times through mammals the avian virus behaved very much like that of human tuberculosis; it produced tubercle in the guinea-pig but failed to affect the fowl. It might, therefore, be suggested that in this second series accidental inoculation with mammalian tuberculosis had occurred, but such a supposition appears to us inadmissible. Along with the first guinea-pig, which showed generalised tuberculosis, a second had been inoculated; the same syringe had been employed, and the two guinea-pigs had been placed in the same cage; now one of these behaved as usual, the other died from generalised tuberculosis. Accidental contamination, moreover, seems to us less probable, as at this time the laboratory contained animals inoculated only with avian tuberculosis.

The above experiments show that in some cases intra-peritoneal inoculation with avian tuberculosis may produce in the guinea-pig a generalised crop of tubercles; such a result is somewhat rare, but is indisputable, and has, moreover, been confirmed by MM. Courmont and Dor, who have also obtained generalised tuberculosis by inoculating with avian cultures. To enable the reader to more readily follow our experiments, we give the results below in tabular form.

The tables describe the animals which provided the material for experiment; those in which inoculations were practised, the after history, and the principal results of the autopsy. The asterisks indicate animals which were intra-venously injected. All others were inoculated intra-peritoneally.

FOWL I.

Tuberculosis of the liver and spleen.

November 7th, 1889.

FOWL.*
Died December 30th (53 days afterwards).
Tuberculosis of the liver and spleen.

GUINEA-PIG.
Killed June 8th (158 days afterwards).
Two or three granulations in the lungs.

FOWL.
Killed June 15th (165 days afterwards).
No lesion.

FOWL II.

Tuberculosis of the intestine, liver, and spleen.

December 30th, 1889.

GUINEA-PIG.
Killed June 15th (165 days afterwards).
No lesion.

RABBIT.
Died April 6th, 1890 (97 days afterwards).
Generalised tuberculosis of peritoneum, spleen, liver, kidneys, and lungs.

RABBIT.
Killed June 15th (70 days afterwards).
No lesion.

FOWL.
Died February 10th, 1890 (41 days afterwards).
Ascites, tuberculosis of the peritoneum, liver, and spleen.

GUINEA-PIG.
Died February 26th (16 days afterwards).
No lesion.

FOWL III.

Tuberculosis of the liver and spleen.

January 25th, 1890.

GUINEA-PIG.
Killed June 15th (140 days afterwards).
No lesion.

FOWL IV.

Tuberculosis of the intestine, liver, spleen, and peritoneum.

March 18th, 1890.

RABBIT.
Died June 2nd (75 days afterwards).
Generalised tuberculosis of peritoneum, mesenteric glands, liver, spleen, kidneys, and lungs.

GUINEA-PIG.
Killed August 3rd (138 days afterwards).
Two or three granulations in the liver and spleen.

FOWL V.

Tuberculosis of the liver and spleen.

April 17th, 1890.

RABBIT.
Killed August 3rd (108 days afterwards).
Tubercles in the epiploon; a few granules in the liver and spleen.

GUINEA-PIG.
Killed March 20th, 1891 (229 days afterwards).
No lesion.

FOWL VI.

Tuberculosis of the liver and spleen.

June 16th, 1890.

GUINEA-PIG.
Killed October 5th (111 days afterwards).
No lesion.

GUINEA-PIG.
Died November 27th (164 days afterwards).
No lesion.

RABBIT.
Died August 24th (69 days afterwards).
Generalised tuberculosis of peritoneum, liver, spleen, kidneys, and lungs.

RABBIT.
Died February 7th, 1891 (236 days afterwards).
White swellings; some tubercles in the liver, kidneys, and lungs.

RABBIT.
Died November 24th (93 days afterwards).
Generalised tuberculosis of peritoneum, liver, pleuræ, and lungs.

GUINEA-PIG.
Died March 20th, 1891 (208 days afterwards).
No lesion.

FOWL VII.

Tuberculosis of the intestine, peritoneum, liver, and spleen.

July 6th, 1890.

FOWL.
Died October 7th (93 days afterwards).
Tuberculosis of the liver, spleen, and peritoneum.

FOWL.*
Died August 24th (49 days afterwards).
Ascites; tuberculosis of the liver and spleen.

GUINEA-PIG.
Died November 29th (146 days afterwards).
Abscess at the point of inoculation.

FOWL.
Died November 20th (88 days afterwards).
Tuberculosis of the liver, spleen, peritoneum, and kidneys.

FOWL.
Killed March 20th, 1891 (120 days afterwards).
Discrete tubercles in the spleen and peritoneum.

FOWL.
Died June 15th (87 days afterwards)
Tuberculosis of the liver, spleen, peritoneum, and lungs; fibrinous ascites.

GUINEA-PIG.
Killed July 12th (114 days afterwards).
No lesion.

FOWL VIII.

Tuberculosis of the intestine and liver.

November 6th, 1890.

HORSE.*
Killed January 7th, 1891 (62 days afterwards).
No lesion.

GUINEA-PIG.
Killed July 2nd, 1891 (248 days afterwards).
Large hepatic abscess.

GUINEA-PIG.
Died December 8th (32 days afterwards).
No lesion.

PHEASANT.

Ascites; tuberculosis of the intestine, liver, and spleen.

December 14th, 1889.

FOWL.
Died January 25th, 1890 (42 days afterwards).
Ascites; tuberculosis of the peritoneum, liver, and spleen.

FOWL.
Killed February 2nd, 1890 (50 days afterwards).
Tuberculosis of the peritoneum and liver.

GUINEA-PIG.
Killed June 8th (135 days afterwards).
Abscess at point of inoculation.

GUINEA-PIG.
Died May 9th (103 days afterwards).
Ascites; generalised tuberculosis (liver, spleen, lungs).

GUINEA-PIG.
Died March 4th (30 days afterwards).
No lesion.

GUINEA-PIG.
Killed September 8th.
Five or six granulations in the liver and lungs.

GUINEA-PIG.
Died December 25th (109 days afterwards).
A few granulations in the liver.

RABBIT.
Killed January 24th, 1891 (139 days afterwards).
Tuberculosis of the lungs, kidneys, and mesenteric glands.

GUINEA-PIG.
Killed July 12th (169 days afterwards).
Generalised tuberculosis (liver [cirrhotic], spleen, peritoneum, and lungs).

FOWL.
Killed July 12th (169 days afterwards).
No lesion.

FOWL.
Killed July 19th (176 days afterwards).
No lesion.

PHEASANT.

Ascites, tuberculosis of intestine, liver, and spleen.

December 15th, 1889.

GUINEA-PIG.
Killed June 8th, 1890 (165 days afterwards).
A few pulmonary tubercles.

GUINEA-FOWL.

Tuberculosis of the liver and spleen.

March 9th, 1890.

GUINEA-PIG.
Killed July 20th (121 days afterwards).
A few granulations in the peritoneum, liver, and spleen.

GUINEA-PIG.
Killed July 20th (121 days afterwards).
Three or four granulations in the epiploon.

GUINEA-PIG.
Killed February 15th, 1891 (210 days afterwards).
No lesion.

GUINEA-PIG.
Died November 29th (129 days afterwards).
No lesion.

Summary of Inoculation Experiments on the Guinea-pig.—In summarising the results obtained by inoculating guinea-pigs with avian tuberculosis the animals may conveniently be classified into four groups:—(1) Those in which the autopsy showed no appreciable lesion; (2) those in which a caseous abscess was found at the point of inoculation; (3) those which showed a few visceral tubercles; and (4) those in which the disease became generalised and revealed itself by an outbreak of tubercles sometimes as abundant as when human tuberculous material is used for inoculation.

These different results are given in the table hereafter. In each group the animals have been divided into two categories—those which died spontaneously, and those which were killed. In each of these again we have noted how long the animal lived after inoculation.

No Lesion.		Local Abscess.		Discrete Visceral Tuberculosis.			Generalised Tuberculosis.	
Animals which died.	Animals killed.	Animals which died.	Animals killed.	Animals which died.	Animals killed.	Organs affected.	Animals which died.	Animals killed.
Days.	Days.	Days.	Days.	Days.	Days.		Days.	Days.
16	111	—	135	109	—	Liver.	103	169
30	114	—	—	—	121	Peritoneum.	—	—
37	140	146	—	—	121	Liver and spleen.	—	—
129	165	—	—	—	138	Id.	—	—
164	208	—	—	—	141	Liver and lungs.	—	—
	210	—	—	—	158	Lungs.	—	—
	229	—	—	—	165	Id.	—	—
	248	—	—	—	—	—	—	—
5 cases	8 cases	1 case	1 case	1 case	6 cases		1 case	1 case
13 cases, or 54 per cent.		2 cases or 8 per cent.		7 cases, or 29 per cent.			2 cases, or 8 per cent.	

Successive Inoculation with Avian and Human Tuberculosis.—We might add to the experiments already described many others consisting of inoculating guinea-pigs with cultures of avian tuberculosis. Certain animals resisted, a fact which enabled us to undertake the study of a fresh problem, viz. whether after such inoculation any modification occurred in the animal's receptivity to human tuberculosis.

On the 25th March, 1890, we injected a guinea-pig intra-peritoneally with a certain quantity of avian culture. On the 19th October,

that is to say, at the end of 200 days, this animal, which had continued in excellent health, was killed. On *post-mortem* examination two encysted caseous abscesses were found in the epiploon; one the size of a pea, the other of a small nut. The pus from these abscesses, which contained very large numbers of bacilli, was used for the intra-peritoneal injection of three guinea-pigs and a fowl.

The latter remained in good health, and was destroyed on the 9th April, 1891, that is at the end of 172 days. At the site of each injection was a yellowish flattened mass, as large as an almond, formed of fibrous tissue, in the centre of which were seen round and fusiform cells and hyaline masses. Although we were unable to discover bacilli on section, we regarded this growth as tuberculous, and similar in character to the rice-like grains of certain cysts. But even rejecting this interpretation, the fact none the less shows that during their six months' sojourn in the organism of a guinea-pig the bacilli had become incapable of producing an outbreak of tubercle in the fowl. We cannot help comparing the above result with that obtained by passing the tuberculosis of the pheasant through three mammals. The reader will remember that in this case the virus was greatly modified, and that it became incapable of killing members of the Gallinaceæ.

Of the three guinea-pigs inoculated simultaneously with the fowl, two died rapidly in sixteen and twenty days, as sometimes occurs after inoculation with avian cultures. Autopsy only revealed a small local lesion at the point of injection. The third bird appeared in good health on the 12th March, 1891, five months after inoculation; some drops of an emulsion prepared with the liver of a guinea-pig, which had died from inoculated human tuberculosis, were then injected into the abdominal cavity. The animal died on the 3rd July, 1891. At the autopsy caseous infiltration of both lungs was noted. The spleen, which measured three inches in length and one and a half inches in breadth, appeared red, and dotted over with white points; the liver was large, and had a "nutmeg" appearance. Histological examination showed extremely extensive tuberculous infiltration.

Here, then, was a guinea-pig which had perfectly resisted inoculation with avian tuberculosis, but had in no sense become immune against human tuberculosis. It died as rapidly as the two control guinea-pigs inoculated simultaneously.

With this we may compare another precisely similar experiment.

On the 21st January, 1891, we inoculated two guinea-pigs with a culture of avian tuberculosis; they remained in good health. One was

injected on the 12th March, the other on the 12th April, with human tuberculosis; the first died on the 2nd July and the second on the 15th. In both we found generalised visceral tuberculosis precisely like that which follows inoculation with human tuberculosis.

These experiments may be summed up as follows:—Six guinea-pigs received avian cultures; two died rapidly, without showing visceral lesions on *post-mortem* examination; four resisted, three of which were afterwards inoculated with human tuberculosis. The latter behaved as though previously healthy. Without wishing to draw a final conclusion from these three experiments we think it allowable to conclude that previous inoculation with avian tuberculosis neither favours nor impedes the development of human tuberculosis.

To summarise the facts established in this first portion of our research, we have only to reproduce in their entirety the propositions formulated at the end of our previous note on avian tuberculosis.

Tuberculosis of Gallinaceæ is transmissible to fowls. Intra-venous or intra-peritoneal inoculation is followed by the development of generalised and rapidly fatal tuberculosis.

The rabbit readily contracts avian tuberculosis, at least when bacilli are introduced into the peritoneum; death follows in two or three months from generalisation of the infection.

The guinea-pig, though more sensitive to human tuberculosis than the rabbit, is much more resistant than it to avian tuberculosis. Inoculation rarely produces general infection. In almost all the cases (91 per cent.) either the animals show no lesion of tuberculosis (54 per cent.), or they show, at the point of inoculation, a caseous abscess which persists for a longer or shorter time (8 per cent.); or visceral infection occurs (29 per cent.), the tubercles remaining partial and discrete, and tending towards fibrous transformation and recovery.

Part 2.—Inoculation of the Gallinaceæ with Mammalian Tuberculosis.

Having shown the manner in which avian tuberculosis behaves when inoculated into animals, it now becomes necessary to approach the converse problem, and to discover if mammalian tuberculosis can be conveyed to birds.

We have already remarked that authors who have studied this question are far from agreeing. Although Bollinger, Koch, and Nocard were able to transmit human tuberculosis to the Gallinaceæ, the majority of pathologists have had negative results. Villemin, H. Martin, Straus and Wurtz, Riffi and Gotti, Rivolta, Maffucci,

Straus and Gamaleia were unable to convey mammalian tuberculosis to fowls; and M. Nocard had no greater success in a fresh series of experiments.

We have further pursued the study of this question. We inoculated thirty-nine fowls and a pheasant with tuberculous material obtained from man and from various mammals.

Inoculation with Human Tuberculosis.—In most of our experiments we employed pulmonary tuberculous material, choosing recent unsoftened centres, so as to obtain a pure lesion and to avoid injecting mixtures of microbes.

(1) In the first series of experiments we directly inoculated a guinea-pig and two fowls with human tuberculosis; the guinea-pig died in twenty-eight days with classical generalised tuberculosis; a fowl inoculated in the peritoneum was killed at the end of 211 days; its viscera appeared healthy, and inoculation of a fragment of its liver into a guinea-pig produced no appreciable disturbance. The results in the second fowl, which was intra-venously inoculated, were very different. This fowl was killed at the end of forty-two days, when it appeared in perfect health. We were, therefore, exceedingly surprised to find in its liver and spleen a considerable number of extremely minute granulations; they consisted of greyish, semi-transparent tubercles, evidently of recent date. This discovery alone seemed to show that the tuberculosis was not spontaneous in character; if the changes had existed prior to our inoculation they would have presented an entirely different aspect. As we before showed, one often finds in such cases large yellowish masses, not a crowd of greyish granulations. But if any doubt remain, it should be dissipated by the results of inoculations made with the liver of this fowl. An emulsion of the liver was injected into the peritoneal cavities of a guinea-pig and a fowl; the guinea-pig died in seventy-two days of generalised tuberculosis; the fowl was killed at the end of 207 days, but its organs remained healthy. This experiment appeared to us absolutely conclusive. We were dealing with human tuberculosis, and the bacillus which had in the first fowl produced tuberculous granulations had preserved its specific properties: inoculated into a second fowl it failed to produce tubercles, which would certainly have developed had we been dealing with an accidental avian tuberculosis. This fact alone sufficiently demonstrates that the bacillus of human tuberculosis may sometimes produce visceral granulations in the fowl.

As before, we summarise the results of the experiments in tabular form, so that the series of inoculations may more easily be followed.

The asterisks indicate animals which were intra-venously injected; the others were inoculated intra-peritoneally.

MAN.

Pulmonary tuberculosis.

August 24th, 1890.

- GUINEA-PIG. Died September 21st (28 days afterwards). *Ascites; tuberculosis of the peritoneum, liver, and spleen.*
- FOWL.* Killed October 5th (42 days afterwards). *Very numerous and very small granulations in the liver and spleen.*
  - GUINEA-PIG. Died December 16th (72 days afterwards). *Generalised tuberculosis (peritoneum, liver, spleen, and lungs).*
  - FOWL. Killed April 30th (207 days afterwards). *No lesion.*
- FOWL. Killed March 24th, 1891 (211 days afterwards). *No lesion.*
  - GUINEA-PIG. Killed July 12th (110 days afterwards). *No lesion.*

(II) Most of the fowls were inoculated with human material, which, however, had been passed through the guinea-pig.

Twenty-three fowls were used in these experiments: fifteen received the virus intra-venously; three intra-peritoneally; and five simul-

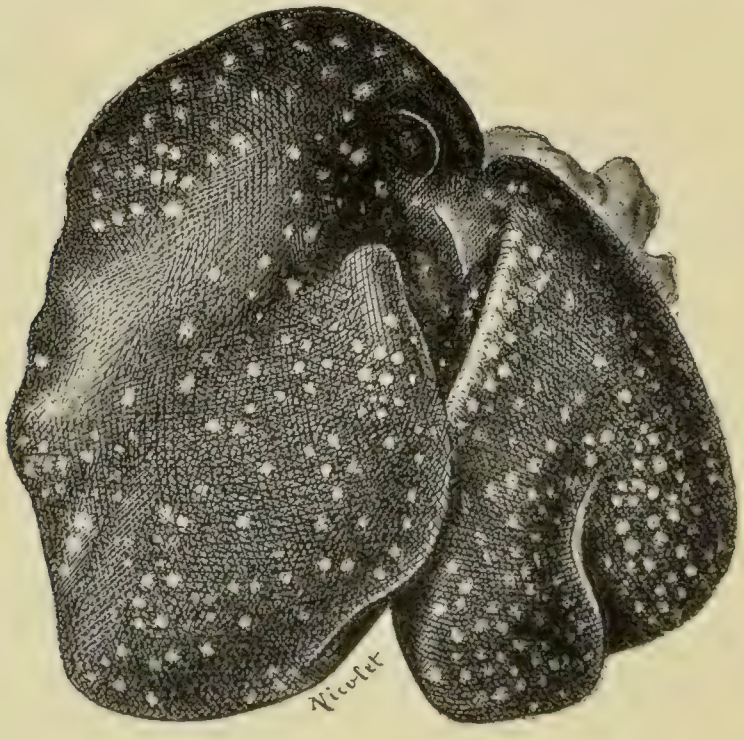

FIG. 77.—Tuberculosis of the liver, produced by inoculation with human virus.

taneously in the veins and in the peritoneum. None of these animals died; all were killed at the end of a period varying between eleven and 266 days. On *post-mortem* examination we only found tuberculous lesions in three fowls. These three belonged to the third series com-

prising five animals which had been simultaneously inoculated in the veins and peritoneum with an emulsion of guinea-pig's liver. The first of these five fowls was killed at the end of eleven days; its organs were unaffected. The second, killed at the end of twenty-four days, showed no visceral lesion, but the bacilli of human tuberculosis were still present in its liver, for inoculation of a guinea-pig with fragments of the organ produced typical tuberculosis. The third was killed on the thirty-fifth day; it was rather thin: on *post-mortem* examination sero-fibrinous ascites was noticed; the liver was slightly enlarged, and crammed with extremely small tuberculous granulations; the spleen was also slightly enlarged, but contained no granulations. The fourth, killed on the thirty-eighth day, also showed numerous granulations in the liver and on the mesentery. The fifth was killed at the end of fifty-nine days; in it the lesions were less marked; somewhat numerous but small tubercles, practically similar to those seen in the fowl, directly inoculated with human tuberculosis, had developed in the liver.

With tuberculous material from the fowl killed at the end of thirty-five days we inoculated another fowl, which remained in good health. It was killed at the end of eighty-six days; we found ascites and small granulations in the liver and spleen.

All these facts are given in the following tables:

MAN.
Pulmonary tuberculosis.
August 24th, 1890.

GUINEA-PIG.
Died September 21st (28 days afterwards).
Ascites; tuberculosis of the peritoneum, liver, and spleen.

GUINEA-PIG.
Killed October 18th (28 days afterwards).
Tuberculosis of the peritoneum, liver, and spleen.

FOWL.
Killed March 20th, 1891 (180 days afterwards).
No lesion.

FOWL.*
(Reinoculated March 18th.)
Killed July 12th, 1891 (266 and 121 days afterwards).
No lesion.

FOWL.
(Reinoculated March 13th.)
Killed July 12th, 1891 (266 and 121 days afterwards).
No lesion.

GUINEA-PIG.
Killed November 2nd, 1890 (15 days afterwards).
Tuberculosis of the peritoneum, liver, and spleen.

GUINEA-PIG.
Died November 28th, 1890 (26 days).
A few tubercles in the spleen.

FOWL.*
Killed January 24th, 1891 (83 days).
No lesion.

FOWL.*
Killed July 12th (252 days).
No lesion.

FOWL.
Killed July 12th (252 days).
No lesion.

GUINEA-PIG.
Generalised tuberculosis.
Killed March 13th, 1891.

Guinea-pig.	Fowl.*	Fowl.*	Fowl.*	Fowl.*	Fowl.*
Killed May 6th (54 days). *Generalised tuberculosis.*	Killed March 24th (11 days). *No lesion.*	Killed April 6th (24 days). *No lesion.*	Killed April 17th (35 days). *Ascites; granulations in the liver.*	Killed April 20th (38 days). *Granulations on the peritoneum and in the liver.*	Killed May 11th (59 days). *Very small tubercles in the liver.*
		Guinea-pig. Killed July 12th (97 days). *Tuberculosis of the liver, spleen, and lungs.*	Killed July 12th (86 days). *Ascites; tuberculosis of the liver and spleen.*		

Guinea-pig.	Fowls.		
Died May 25th (19 days). *Generalised tuberculosis.*	I.	Killed May 22nd (16 days).	*No lesion.*
	II.	Killed May 30th (24 days).	,,
	III.	Killed June 7th (31 days).	,,
	IV.	Killed June 15th (39 days).	,,
	V.	Killed June 22nd (46 days).	,,
	VI.	Killed July 1st (55 days).	,,
	VII.	Killed July 9th (63 days).	,,
	VIII.	Killed July 17th (71 days).	,,
	IX.	Killed July 19th (73 days).	,,
	X.	Killed July 26th (80 days).	,,
	XI.	Killed Sept. 14th (131 days).	,,
	XII.	— — —	—

Of the first five fowls inoculated in this last series, three showed tuberculous lesions on *post-mortem* examination. When these results were laid before the Société de Biologie various objections were made, the chief of which are as follows :—(1) The best evidence of the immunity of fowls against human tuberculosis is to be found in the fact that none died spontaneously; (2) we were wrong in not using cultures for our inoculations; (3) we had mistaken for tuberculosis, nodular lesions produced by the injection of emulsified tuberculous material; (4) we should have experimented on fowls already affected with avian tuberculosis.

To the first objection we reply, that if none of our fowls died spontaneously it was for the simple and decisive reason that we killed them.

To the second, that of the various methods of inoculation with human tuberculosis (direct inoculation, or inoculation with cultures prepared in living animals, or on inert media), we consider that none is superior to the others unless it give better results.

To the third, that histological and bacteriological examination clearly proved the tuberculous nature of the lesions noted.

Finally, in order to refute the last objection, we shall not shelter ourselves behind the assurance of the person who furnished us with the

animals, that tuberculosis had never occurred in his fowl run, and that during the previous four years no contagious disease had occurred there; but draw attention to the fact that two fowls killed respectively eleven and twenty-four days after inoculation were free of any visible tubercle, whilst the last three fowls, killed thirty-five, thirty-eight, and fifty-nine days after inoculation, had become tuberculous.

In these three fowls the tubercles were small, greyish, and transparent, unquestionably recent. On histological examination they were seen to be composed of simple epithelioid nests without trace of degeneration. Our sections showed in an absolutely unanswerable way that the granulations of the fowl inoculated with human tuberculosis, and killed on the 35th day, were less advanced in their development than those of the fowl inoculated with avian tuberculosis, which died on the thirty-ninth day.

We are, therefore, convinced that the tuberculosis was the result of inoculation.

But the fact which seems to us most important is, that human tuberculosis could be transmitted from one fowl to another; the lesions were well marked, notwithstanding which this animal, like the preceding, seemed little affected by the presence of these visceral granulations; it had not lost flesh in the least, and we were exceedingly surprised at the result of the *post-mortem*. Thus, in the same way that avian tuberculosis may, in mammals, produce growths of minute tubercles without interfering with general health, and without causing emaciation, human tuberculosis may in the fowl produce specific lesions, which are very well tolerated.

(III) We have to record a third series of experiments, in which we utilised the caseous magma from a case of tuberculosis of the testicle. It seemed interesting to utilise this local lesion, for a virus attenuated for man might very well be more active for the fowl.

With the material from this tuberculous testicle we inoculated four fowls, one pheasant, and two guinea-pigs. The guinea-pigs died from visceral tuberculosis, in fifty-four and fifty-six days respectively. The birds all resisted, and when killed, after an interval varying between 62 and 248 days, their viscera showed no appreciable changes.

These results are indicated in the following table. It will be seen that we inoculated a guinea-pig with the liver of a fowl killed at the end of seventy-two days. The result was negative. The bacilli had therefore been destroyed, or changed by their sojourn of two and a half months in the body of the fowl.

MAN.

Tuberculosis of the testicle.

November 13th, 1890.

- GUINEA-PIG. Died January 6th, 1891 (54 days). *Tuberculosis of the spleen.*
- GUINEA-PIG. Died January 8th (56 days). *Tuberculosis of the spleen and liver.*
- FOWL.* Killed January 24th (72 days). *No lesion.*
  - GUINEA-PIG. Killed July 12th (169 days). *No lesion.*
- FOWL.* Died April 10th (149 days). *No lesion.*
- FOWL. Killed January 24th (72 days). *No lesion.*
- FOWL. Killed July 19th (248 days). *No lesion.*
- PHEASANT. Killed January 16th (62 days). *No lesion.*

Summarising the facts noted after inoculating members of the Gallinaceæ with human tuberculosis, the results are as follows :

Thirty-two fowls were inoculated with tuberculous material derived directly from man, or having passed through other animals; on *post-mortem* examination five showed visceral granulations; in all inoculations tuberculosis had been produced, *i. e.* tuberculosis resulting from human, and not from avian bacilli. Even though objection might be made regarding the second series of experiments, no doubt seems possible concerning the fowl in which the granulations proved inoculable to the guinea-pig and to another fowl. In these cases the bacillus had preserved its original characteristics, and the nature of the infection appeared to us absolutely proved.

Inoculation with Bovine Tuberculosis.—We were not content to inoculate with human tuberculosis alone, but utilised tuberculous material from different mammals, and particularly from animals of the bovine species; such a test appearing more important on account of the doubts which have recently been thrown on the identity of pulmonary tuberculosis in animals and human tuberculosis. Fowls remained unaffected whilst the disease was transmitted to the rabbit, guinea-pig, and cat.

COW.

Pleural and pulmonary tuberculosis.

November 4th, 1889.

- GUINEA-PIG. Died November 20th (16 days). *A few tubercles on the peritoneum.*
- GUINEA-PIG. Died November 27th (23 days). *Tuberculosis of the spleen, liver, and peritoneum.*
- GUINEA-PIG. Died November 27th (23 days). *Tuberculosis of the liver, spleen, and peritoneum.*
- RABBIT. Died November 17th (13 days). *A few tubercles on the peritoneum and in the liver.*
- RABBIT. Died November 29th (25 days). *Tuberculosis of the liver, spleen, and peritoneum.*
- FOWL. Killed March 20th, 1890 (136 days). *No lesion.*

OX.
Pleural and pulmonary tuberculosis.
November 15th, 1889.
|
CAT.
Died November 16th (31 days).
Generalised tuberculosis.
|
FOWL.
Killed August 3rd, 1890 (230 days).
No lesion.

OX.
Pleural and pulmonary tuberculosis.
March 18th, 1890.
|
FOWL.
Killed October 12th (208 days).
No lesion.

Inoculation with Tuberculous Lesions from the Dog, Cat, and Horse.—Finally, we come to the last series of experiments in which material for inoculation was obtained from animals which rarely suffer from tuberculosis.

In the first the virus was obtained from a dog with tuberculosis of the lung and pleura. From a pulmonary centre which contained large numbers of bacilli we inoculated two guinea-pigs and two fowls. The fowls resisted, while the guinea-pigs died with all the ordinary symptoms of tuberculosis.

In the second the virulent material was obtained from a case of pulmonary tuberculosis in the cat. The inoculation was successful in the guinea-pig, but failed in the fowl. What renders this second series interesting is that the virus appeared pathogenic for the horse, intravenous inoculation producing death in twenty-four days. On *post-mortem* both lungs were found affected with miliary tuberculosis, the separate points being extremely small and confluent; this lesion was of surprising intensity. The bacilli inoculated must have been very virulent, for every one knows that the horse is not specially sensitive to tuberculosis. We therefore supposed that the virus, rendered still more virulent by its passage through the horse, would have developed in the fowl, but in this case again inoculation was unsuccessful, the fowl, on being killed at the end of 135 days, showing no appreciable lesion.

DOG.
Pulmonary tuberculosis.
January 5th, 1891.

GUINEA-PIG.	GUINEA-PIG.	FOWL.*	FOWL.
Died February 13th (39 days). *Generalised tuberculosis (liver, spleen, and lungs).*	Died February 23rd (49 days). *Generalised tuberculosis (liver, spleen, and lungs).*	Killed April 16th (101 days). *No lesion.*	Killed July 19th (195 days). *No lesion.*

CAT.

Pulmonary tuberculosis.

January 20th, 1891.

Guinea-pig.	Horse.*	Fowl.*	Fowl.
Died February 2nd (13 days). *A few granulations in the liver.*	Died February 13th (24 days). *Miliary tuberculosis of the lungs.*	Killed June 28th (159 days). *No lesion.*	Killed June 28th (159 days). *No lesion.*

Summary of the Attempts to inoculate Gallinaceæ with Mammalian Tuberculosis.—Forty members of the Gallinaceæ were inoculated with mammalian tuberculosis; none died spontaneously; all were killed after a varying period. On *post-mortem* examination tuberculosis was found in five, but in thirty-five no lesion could be detected.

The results obtained are indicated in the following table, which summarises all this portion of our experiments.

Origin.	Method of inoculation.	Number of animals inoculated.	Results. Negative.	Results. Positive.
Man { Pulmonary tuberculosis	Directly	2	1	1
	After passage through guinea-pig	23	20	3
	After passage through fowl	2	1	1
Man { Tuberculosis of the testicle	Directly	5	5	—
Oxen { Pulmonary tuberculosis	Directly	2	2	—
	After passage through cat	1	1	—
Dog { Pulmonary tuberculosis	Directly	2	2	—
Cat { Pulmonary tuberculosis	Directly	2	2	—
	After passage through cat	1	1	—
		40	35	5

Without attempting a comparative study of tuberculosis in the different mammals, we would draw attention to the fact that these experiments, performed with material from bovines, and from the dog, cat, and horse, may be cited in favour of the unicity of tuberculosis. The guinea-pigs and rabbits died in the same way as when inoculated with human tuberculosis. Development has often been very rapid, for bovine tuberculosis killed guinea-pigs in two and three weeks, and canine tuberculosis in five weeks.

Persistence of the Human Bacillus in the Organs of Gallinaceæ.—Our experiments, and those published by other investigators, show

that mammalian tuberculosis can only be transmitted to birds by special methods. We were therefore led to inquire what becomes of the bacillus when introduced into the bodies of birds. M. Martin first commenced the study of this question. He collected blood from a certain number of fowls which he had intra-peritoneally injected with human tuberculosis, and with it he inoculated guinea-pigs. The results were extremely variable: sometimes blood from fowls inoculated three months before did not appear virulent; sometimes blood from birds inoculated six or even seven months before transmitted tuberculosis. We again took up the question, but thought it better to utilise the liver instead of the blood, as the microbes become localised in the viscera. Our experiments gave the following results:—Fragments of liver from a fowl inoculated twenty-four days before transmitted tuberculosis to the guinea-pig; fragments of the same organ injected into other guinea-pigs seventy-two, eighty-three, and 211 days after the primary inoculation, produced no appreciable result.

Thus a month after inoculation with human tuberculosis the bacilli still persisted in the fowl's organism; at this time they seem to betray their presence by certain morbid reactions; the fowls often become ill towards the end of the first or commencement of the second month after inoculation; this fact had not escaped M. Martin, two of whose fowls had died on the forty-seventh and forty-eighth day, though the autopsy was negative. Now it was precisely about this time that we noted visceral tuberculosis (as shown in the table below, which gives the results of our experiments).

			Results.	
			Negative.	Positive.
Animals killed	Between the 11th and 31st days	5	5	—
	Between the 35th and 59th days	7	3	4
	Between the 62nd and 266th days	27	27	—
Total		39	35	4

Speaking generally, there was no tuberculosis before the thirty-fifth or after the fifty-ninth day.*

The question may therefore arise whether, towards the second month after inoculation, lesions may not be produced, which though in most cases only appreciable on microscopic examination, would nevertheless explain the symptoms shown. Histological examination, carried out in one case, did not support this hypothesis. The liver of

* The fowl to which tuberculosis of human origin was transmitted after passage through other fowls forms an exception; in this case the virus may have undergone modification by passage through the previous birds.

a fowl killed on the thirty-ninth day was steatomatous, but contained no granulations.

To sum up, inoculation of members of the Gallinaceæ with mammalian tuberculosis seldom proves fatal. In most cases it is well borne; towards the second month it sometimes excites certain temporary disturbance; finally, in rare cases it produces a crop of tuberculous granulations in the viscera.

V.—SUMMARY AND CONCLUSIONS.

HAVING arrived at the end of our investigation, we think it well to summarise our principal conclusions.

It has long been known that the Gallinaceæ suffer from a disease resembling tuberculosis, characterised by the production of granulations and caseous masses of varying size. These lesions especially affect the liver, spleen, and peritoneum. The intestine often shows ulceration; the intestinal contents then contain bacilli, which serve to transmit disease and explain certain outbreaks.

The histological characters of the tubercles differ in the fowl and in the pheasant. In the fowl the tubercle consists of a clump of epithelioid cells, the central portion of which has undergone hyaline necrobiosis, and is surrounded by a border of special cells. In the pheasant the lesion is at first formed by nests of epithelioid cells, the central portion of which afterwards disappears in consequence of molecular degeneration; simultaneously a connective-tissue ring is formed, which undergoes amyloid degeneration, and surrounds cavities resembling blood-vessels.

All these growths contain bacilli presenting the same appearance, and behaving to colouring agents in the same way, as those found in the tuberculosis of man and of other mammals.

Experiment appeared the only way of determining the connection between tuberculosis of mammals and that of birds.

Our research may be divided into two parts.

In the first group of experiments we studied the avian virus, and found that it is readily communicated to fowls. Injected into the veins or peritoneal cavity it produces lesions resembling those of spontaneous tuberculosis.

When introduced into the abdomen of the rabbit the avian behaves very similarly to the human bacillus, producing a generalised outbreak of granulations in the viscera.

In the guinea-pig the results are more variable. We inoculated twenty-seven guinea-pigs intra-peritoneally; thirteen of these showed

no appreciable lesion; five showed a caseous abscess at the point of inoculation; seven a few discrete visceral granulations; and three generalised miliary tuberculosis.

In passing through the organism of mammals, the avian virus becomes modified and loses its pathogenic properties for the fowl.

In a second series of experiments we injected fowls with tuberculous material derived from man and from different mammals (ox, dog, cat, and horse). Forty fowls were inoculated, either in the veins or in the peritoneal cavity, or simultaneously in both. None died. In five we found recent very small transparent tubercles; they were due to the human bacillus, for in one case they could be reinoculated into the guinea-pig, but could not be transmitted to another fowl; the virus had therefore preserved its original properties. In another case the bacilli became more markedly modified, and the lesions could be reinoculated from one fowl to another.

The cases we have described, and the experiments published by other observers, indisputably prove that profound differences exist between mammalian and avian tuberculosis. On the basis of the results obtained, the following comparison may be established between the two viruses.

The avian bacilli are longer and more granular; they develop more readily on artificial culture media, and grow at once on glycerine agar. The human bacilli only grow on this medium after having several times been sown on serum.

As MM. Straus and Gammeleia have well shown, cultures of the avian bacilli are moist, fatty in appearance, wrinkled, and soft; those of the human bacilli are dry, scaly or warty, dull and hard.

The avian bacillus grows at 43° C., and can resist a temperature of 65° C.; the human bacillus ceases to grow at 41° C., and dies at 65° C.

An avian culture six months old is still living, and can still be replanted. A human culture loses its power of reproduction in six months (Maffucci).

Avian tuberculosis can be transmitted to fowls. It seldom or never produces generalised tuberculosis in the guinea-pig, and cannot be inoculated in the dog. Human tuberculosis can only exceptionally be transmitted to fowls; it always produces generalised tuberculosis in the guinea-pig, and can readily be conveyed to the dog.

Such are the differences between the two viruses, and it must be confessed they are considerable. But are they sufficient to constitute a radical distinction? and must we regard the two bacilli as belonging to different species?

On reconsidering the distinctive characters just mentioned we see that they are perhaps less marked than might at first appear.

The general characters of the two bacilli are the same, and the reactions they produce in the living organism are similar. In reply to the objection that the histological characters of human tubercle differ from those of tubercle in the Gallinaceæ we may point to the still greater difference between the tubercles of the fowl and of the pheasant; in animals equally sensitive to both viruses, like the rabbit, the histological features of the lesions are identical; there is the same formation of nodules, the same tendency to caseation.

By studying the morphology of the two microbes they are seen to be very similar; the few differences which have been noted are secondary, and equally marked variations are observed on comparing tuberculous bacilli from different members of the same species; in man it is not uncommon to find certain bacilli longer and more granular than others. On the other hand, both in avian and in human bacilli the great specific characteristics remain, especially the staining reactions, which appear to us of infinitely greater importance than a morphological detail.

Without being absolutely identical, cultures of the two bacilli offer certain analogies; the human bacillus can grow on glycerine media, and in this respect tends to resemble the avian bacillus; even though it will not grow immediately, is this character sufficient to establish a fundamental distinction? Would not a simple variation of race suffice to explain this difference?

We might make similar suggestions regarding the other differential characters, but we hasten to consider those more particularly appropriate to our investigation—we mean the pathogenic properties.

It is certain that different animals do not react in the same way to both viruses; in this connection MM. Straus and Gamaleia lay stress on the following fact which they have discovered: the dog readily contracts human tuberculosis, but is proof against avian tuberculosis. This fact is of considerable interest, but is, nevertheless, in our estimation insufficient to establish a specific distinction. Equally marked differences often exist between varieties of the same species; the anthrax bacillus kills the rabbit, while the first anthrax vaccine is without action on it. To continue our comparison we might remark that from the point of view of form and of cultures there is certainly as much difference between the virulent anthrax bacillus and the attenuated bacillus as between the bacillus of human and of avian tuberculosis.

We do not think it advisable to rely on one or two differential characters in attempting to solve this question, but to take into con-

sideration all the characteristics of the two microbes. From this point of view we should bear in mind that a number of facts tend to prove a community of nature between the two viruses. The rabbit, for example, contracts avian as readily as human tuberculosis, at least when inoculated intra-peritoneally. Although the guinea-pig, the test *par excellence* for human tuberculosis, usually resists the avian disease, it nevertheless sometimes dies with generalised visceral granulations. Conversely the fowl is not absolutely immune against human virus; on several occasions we have seen tuberculous lesions produced in the fowl, and in one case we were able to prove that the lesions were due to the human bacillus, which had preserved its particular characters.

Finally, we have cited in this investigation various results which tend to establish that the two viruses may undergo modification, and even transformation; in one case human tuberculosis was transmitted from one fowl to another; in another avian tuberculosis by passage through mammals became exalted in virulence for these animals, but lost its pathogenic properties for the Gallinaceæ.

The results we have obtained, and those reported by other experimenters, lead us to think that the two bacilli only represent two varieties of the same species. Without doubt these two varieties are very different, and it is impossible to apply to one results obtained with the other. To prevent a recurrence of the confusion which previously obtained, it is, therefore, always necessary to state which virus has been used. But, despite their very important distinguishing characters, a common basis exists on which these two pathogenic agents may be compared and regarded as derived from a single source. The view which we think best agrees with hitherto observed facts is that tuberculosis of mammals and of Gallinaceæ are essentially one and the same.

II.—TUBERCULOSIS OF PARROTS—ITS RELATIONS TO HUMAN TUBERCULOSIS.

By MM. Cadiot, Gilbert, and Roger.

When Koch discovered the bacillus of tuberculosis it was hoped that the old unending dispute between the unicists and the dualists would have ended. It has not been so; the problem has only been modified. Doubt no longer exists of the unicity of tuberculosis in man, but the unicity of tuberculosis in animals is still disputed. Some authors have attempted to draw a sharp line of demarcation, an absolute distinction, between the pathogenic agent found in mammals and that discovered in birds; have attempted, in fact, to prove the existence of two distinct kinds of tuberculosis, human and avian.

The question has more than a theoretical interest, for its solution vitally affects hygiene. Depending on whether the avian bacillus represents a particular variety or species, and is or is not capable of developing in mammals, tuberculous birds must be considered dangerous or innocent for man. If the avian bacillus has no relation to that of mammals affected birds can be safely utilised for food, or kept in close proximity to man without danger.

It is impossible to deny that important differences exist between the tuberculosis of mammals and that of birds. We have shown that the avian bacillus, though very virulent for the rabbit, seldom produces in the guinea-pig more than circumscribed discrete lesions, with a marked tendency to undergo fibrous transformation. Conversely the human bacillus is but slightly dangerous to the Gallinaceæ, and its inoculation into birds is seldom followed by the growth of tubercles.

But there are exceptions to these rules: in the guinea-pig the avian bacillus sometimes produces visceral lesions of an extremely marked character, which can be transmitted in series. Moreover the Gallinaceæ are not entirely immune: of eighty-six fowls inoculated with mammalian tuberculosis nine showed positive results, *i. e.* a proportion of about 10 per cent.

Although the Gallinaceæ show unquestionable resistance, other

birds—the Psittaceæ (the parrot tribe),—very readily contract human tuberculosis. Observation tends to support this view, and experiment has established it beyond question.

The merit of having first drawn attention to the frequency of tuberculosis in parrots, and of having shown that the disease especially affects the skin, mucous membranes, subcutaneous and submucous connective tissues, the articulations and bones, is due to Fröhner and his assistant Eberlein. Of 700 parrots brought for examination to the Berlin school 170 were tuberculous, *i. e.* a proportion of 25 per cent. Eberlein gave a summary of fifty-six of these cases, according to which the principal localisations were as follows:

Eye and periocular region	14
Commissure of the beak	11
Tongue	9
Larynx	2
Bones and articulations	14

In Eberlein's observations tuberculosis affected the skin and its appendages in twenty-nine cases, *i. e.* a proportion of 50 per cent.

The cases which we have recorded number twenty-seven, and may be divided as follows:

Tuberculosis of the skin	15 cases, *i. e.* 55 per cent.
Tuberculosis of the mucous membrane	6 cases, *i. e.* 22 per cent.
Simultaneous tuberculosis of the skin and mucous membrane	6 cases, *i. e.* 22 per cent.

On more closely studying the localisation of these lesions we see that they most frequently occur about the head, especially the sides of the face, the periorbital region, and the commissures of the beak. Eberlein considers that the left side is more frequently attacked than the right, without, however, being able to give any reason for this predominance. Finally, it is not uncommon to find several massed or distributed cutaneous centres in the same animal.

Studied according to their localisation an analysis of the lesions in our twenty-seven cases proves very similar to that of Eberlein:

Cheeks, periorbital region, and eye	12 cases
Commissures of the beak	7 ,,
Tongue	8 ,,
Palate	4 ,,
Upper limbs and wings	7 ,,
Claws	3 ,,
Cervical, dorsal, and caudal regions	5 ,,

In order to convey a better idea of the seat and appearance of the lesions we very briefly summarise these observations.

1. *Tuberculous Lesions of the Skin and Appendages.*

CASE 1. A green parrot bought in April, 1886. In December, 1894, a little greyish, firm, scaly swelling was noted on the right side of the face. It gradually extended to subjacent parts, becoming more prominent.

On the 1st January, 1895, this tumour was removed by a veterinary surgeon. A fortnight later it returned.

On the 19th January the parrot was brought here. The right side of the face showed a greyish, conical, scaly vegetation, slightly incurved at its extremity. Examination of a scraping from the inflamed skin around the base of the growth revealed numerous bacilli.

The tumour was removed, the skin curetted and touched with the thermo-cautery.

The parrot was brought back again on the 12th February, 1895. The horny mass had again grown, and another swelling was in course of formation above the former. The same treatment was repeated.

On the 2nd March both growths had returned, and a fresh one had appeared between the skin and the upper mandible.

CASE 2. A parrot, the globe of whose eye was almost entirely covered by the lower eyelid, which formed a fungating swelling the size of a haricot bean; the central portion was caseous, and contained bacilli.

CASE 3. A parrot with a tuberculous horny growth developed on the right side of the head immediately behind the buccal commissure. Brought back again a month later it showed other small horny growths close to the first.

CASE 4. A parrot showing a large horny growth below the lower mandible; the surface of implantation occupied half the depth of the head; this horn was pyramidal in shape; the anterior side measured one and a half inches in length; it was hard, fragile, and stony in appearance. Two similar growths the size of hemp-seeds existed in front of the left eye.

CASE 5. A four-year-old parrot, imported from Brazil at the age of three months. For some time this bird, previously very talkative, had appeared dull and quiet. A horny growth, the size of a small hazel-nut, existed on the right cheek, behind the base of the mandible.

CASE 6. A parrot which had shown marked wasting for several months. On the right side of the head was an indurated cutaneous patch the size of a sixpence; at the lower part of the neck was a horny growth as large as a haricot bean; on the back a similar but smaller patch; finally, on the sacrum a fungous, bleeding, ulcerated spot. Examination of these various lesions revealed the existence of numerous bacilli.

CASE 7. A parrot brought to hospital on the 4th May, 1894. It was thin, dull, and had not talked for several weeks. On the right side of the head, three eighths of an inch from the base of the beak, was a horny growth, conical in shape, covering a surface about three eighths of an inch square. A similar growth existed at the base of the neck. In the lumbar region was a circular, granulating, bleeding wound surrounded by a zone, from which the feathers had fallen.

CASE 8. A five-year-old parrot, which for two years had belonged to the woman who brought it. A horny growth had appeared on the left wing, and somewhat later another had developed on the head.

CASE 9. A five-year-old parrot, which had been in its owner's possession for three years, and had been ill for five to six months. The left side of the head behind the eye was the seat of a cylindrical, horny growth, about three eighths of an inch in length, and one sixth of an inch in thickness.

CASE 10. A parrot which had appeared ill for the previous five to six months. Had been in its owner's possession for two years. On the right side of the neck were two horny tuberculous growths, about three eighths of an inch in length. In the subcutaneous connective tissue, covering the larynx, were two growths the size of a small hazel-nut. The right wing showed an ulcerated tuberculous patch.

CASE 11. A parrot which had belonged to the same person for the previous eighteen months. About three months before its appearance here a growth of fibrous consistence which granulated freely, and the centre of which was occupied by caseous material, had appeared on the carpal region of the left wing.

CASE 12. Parrot ill for about six months. Horny growth on right wing over the humero-radial articulation.

CASE 13. Parrot affected for the previous two months with an ulcerated tuberculous swelling of the metatarsal region.

CASE 14. Parrot affected with two swellings the size of hazel-nuts on the lower part of the right claw. The muscles of the claw were atrophied, and the animal could not use the limb.

CASE 15. Parrot showing a horny tumour of conical form at the base of the tail. This growth, which had only been discovered ten

days previously, measured three eighths of an inch in length. It had invaded the anus and caused obstinate constipation.

2. *Tuberculous Lesions of the Skin and Mucous Membranes.*

CASE 16. Parrot ill for the previous three months. Two horny growths, one over the throat, the other on the left side of the head. Several small yellowish vegetations on the buccal mucous membrane behind the commissure and on the palate.

CASE 17. Parrot showing two cutaneous horns on the back opposite the wings; whitish patches, the size of a lentil, at the base of the tongue and on the left side of the larynx.

CASE 18. Parrot ill for the previous two years. On either side of the head, opposite the commissures, were small horny growths. On the palate was a conical horny growth, the size of a haricot bean, directed forwards. The end extended beyond the tongue. The base, which was about three eighths of an inch in diameter, was attached to a finely granulating surface.

CASE 19. Parrot bought eighteen months before. Had shown difficulty in swallowing for the past six months; was emaciated. Two small tumours existed, one above the upper mandible, the other behind the left commissure, each the size of a pea. A third ulcerated swelling was seen on the palate. The bird died on the 15th March, 1895. No visceral lesions.

3. *Tuberculous Lesions of the Mucous Membrane.*

CASE 20. Parrot which for the previous two months had shown several small greyish swellings on the commissures of the beak and on the tongue. These growths had gradually increased in size, become confluent, and ended by forming two flattened tumours of considerable thickness, the outer part of which extended as far as the branches of the lower mandible. The lingual patches having been detached with a director the mucous membrane beneath was seen to be red, thickened, and granulating. Another patch of similar character, but smaller extent, occupied the palate.

CASE 21. A parrot which had been ill for five months; swallowing very difficult; extreme wasting during the last month; tuberculous vegetation on the tongue and hard palate.

CASE. 22. Parrot affected with a large swelling at the base of the tongue; great difficulty in deglutition. For five or six months previously the animal had suffered in condition.

CASE 23. Parrot showing a rounded tuberculous growth the size of a pea on the hard palate.

CASE 24. Parrot suffering from tuberculous patches on the tongue.

4. *Visceral Lesions.*

CASE 25. Parrot which had been ill for the previous eight months. Tuberculous hardened growth on the right side of the head; tuberculous swelling on the left wing; hardened growth, about three quarters of an inch in length, on the extremity of the rump. Feet deformed and contorted; the bird had difficulty in holding on its perch. It died a month later.

Autopsy.—The liver and spleen were crammed with tuberculous granulations; both legs showed deep-seated lesions of the bones, articulations, periosseous and periarticular tissues.

CASE 26 (Autopsy). Tuberculosis of the tongue, larynx, lungs, and liver. The lesions were similar to those usually noted in the Gallinaceæ. Two tuberculous spots in the muscles of the thigh and leg; tuberculosis of the tarsal joints; some cutaneous tubercles.

CASE 27 (Autopsy). Tuberculosis of the tongue and nasal cavities, lungs and liver; a tuberculous spot in the muscles of the left foot.

The above cases show that the lesions are almost always of so

FIG. 78.—Horny growth developed on a tuberculous patch on the cheek (Eberlein-Krampf).

special a character as to have rendered it impossible to detect their nature before the introduction of bacteriological methods. These cutaneous manifestations differ entirely from the lesions seen in other animals, and can only be compared to certain forms of verrucous lupus. In general the first sign is furnished by the falling of the feathers. The skin then becomes thickened and verrucous, after which the growths develop and are covered with thick crusts. These hardened

growths may even attain two inches in length, and three eighths to three quarters of an inch in width at their base (Fig. 78). When detached they are seen to have grown from a granular or fungous tissue. Ulceration is not uncommon, and occurs most readily when the diseased part has been exposed to injury, or to repeated rubbing.

In some cases the lesion occupies the subcutaneous tissue. It then forms a growth of fibrous consistence, sometimes as large as a cherry. At a later period the centre undergoes softening and is transformed into a caseous magma.

Finally, peculiar local growths are sometimes seen, which have caused mistaken diagnosis; the tubercles develop in certain parts of

Fig. 79.

the feet, which become deformed and contorted, precisely as in the cases described under the title of "gout in birds."

The external lesions may, by their size and position, cause varying functional disturbance. They may cover, or close the eyes (Fig. 79); interfere with the movement of the mandibles, and when in the anal region render defæcation difficult; while those on the feet are usually accompanied by muscular atrophy, and sometimes by paresis.

Vegetations resembling the skin lesions may be seen on the buccal mucous membranes; sometimes they are simply hard, white or yellowish, slightly prominent patches; in others conical or rounded tubercles, varying in size between a pea and haricot bean, considerably dimin-

ishing the buccal cavity and interfering with deglutition. Despite their development from a mucous membrane, they present a horny appearance; in only one case have we seen an ulcerated growth on the palate. Visceral growths may develop simultaneously with, or apart from, cutaneous, articular, or buccal lesions. Some may be detected by the symptoms shown during life; gastro-enteritis, for instance, produces diarrhœa and sometimes passage of blood; and pulmonary tuberculosis (which Eberlein regards as the commonest visceral localisation) causes continual attacks of coughing.

In most cases development is extremely slow. The onset being insidious, the disease is often overlooked; and the large growths seen on examination have often been described as the product of a week or so.

When it causes no functional disturbance, and is unaccompanied by visceral lesions, tuberculosis produces little disturbance; birds may, therefore, continue for a long period to incubate and distribute the bacillus of tuberculosis.

Sooner or later, however, they become ill, appear dull and thin, cease to talk, and usually die, extremely emaciated, in six months to a year. Sometimes, however, they survive for a much longer period. We have seen parrots, still in very fair condition, two years after the onset of disease.

In spite of their slow development, the cutaneous lesions are difficult to cure. In Eberlein's and in our own experience, extirpation always failed, the growth recurring in a few weeks.

It is difficult to exactly estimate the frequency of visceral lesions. Eberlein, who made fifteen *post-mortem* examinations, gives the following results:

No visceral lesions	7 cases.
Tuberculosis of the lungs . . .	4 ,,
,, of the liver	4 ,,
,, of the intestine . . .	3 ,,
,, of the muscles . . .	1 case.
,, of bones and articulations .	2 cases.
,, of the heart . . .	1 case.

The same author has several times detected tubercle bacilli in the liver, even when there were no visible granulations. He justly lays stress on the frequency of pulmonary lesions, which, on the other hand, are very rare in the Gallinaceæ.

In most of the cases we have seen the birds were kept alive by their owners; in only seven were we able to carry out *post-mortem*

examinations. In three of these (Cases 25, 26, and 27) we found visceral tuberculosis in the form of little miliary granulations scattered through the liver, spleen, and lungs. In these three cases we also noted tuberculous points in the bones, articulations, and muscles.

By histological examination of one of these cases we discovered that the tubercles in the liver of the parrot resemble human tubercles, and differ from those of the fowl and pheasant. They consist of central giant-cells, round or fusiform, peripheral cells, and epithelioid intermediate cells (Fig. 80). The giant-cells contained a very large number of nuclei, which are usually distributed throughout the cell, or occupy the centre, but not the periphery, thus differing in appearance from the ordinary giant-cell in human tuberculosis. In these centres, and especially in their giant-cells, bacilli appear very numerous.

What is the origin of tuberculosis in parrots? This is the most

Fig 80.

interesting question both from the theoretical and practical point of view.

One can hardly believe that in the majority of cases parrots have been inoculated by Gallinaceæ. Living with man, they never, or scarcely ever, leave the house, and, as a rule, have no opportunity of coming in contact with poultry. It is, therefore, impossible to imagine how they could contract avian tuberculosis.

These theoretical considerations are supported by the results of an inquiry made by us regarding our twenty-seven cases. In seven instances the affected parrots belonged to persons in bad health, who appeared thin and had for a considerable time suffered from chronic

cough; that several were unquestionably tuberculous was proved by bacteriological examination of their sputa.

Case 1, described in the foregoing pages, is in this respect absolutely conclusive. The parrot had lived in the same house for eight years, and had always enjoyed good health; in April, 1894, its owner began to cough; in December the bird showed tuberculous patches on the sides of the face. At this time microscopic examination revealed the presence of tubercle bacilli in the cutaneous growth on the head of the parrot, and in the expectorations of its owner. The owner told us that he was in the habit of fondling the bird; that he often kissed it on the head and sides of the face; and that he made it take from his mouth food which he himself had masticated. He added that this parrot was the only animal in his rooms; that it had never come in contact, even for a short time, with other birds, and that it lived on seeds, coffee and milk, boiled milk, and, finally, food which he himself had chewed. Is not this case as complete and as instructive as a laboratory experiment? How is it possible to deny that this bird, which showed cutaneous tuberculosis four months after its owner had developed the first symptoms of pulmonary tuberculosis, from which he died a year later, had been infected by the owner himself?

In Case 2 the human origin of the disease is scarcely less clear. A man who had suffered with pulmonary tuberculosis from 1887, and who died of the disease in January, 1895, bought in 1890 a very fine parrot, which showed no cutaneous lesions. At the commencement of 1894 the bird, which its owner was in the habit of fondling, and which ate from his mouth, developed a greyish nodule on the lower eyelid of the left eye; the nodule gradually increased in size, and ended by invading the entire eyelid.

In Case 16 the disease may have been caused in the same way. The parrot belonged to a tuberculous woman, who was in the habit of feeding it from her mouth. Tuberculosis developed simultaneously on the buccal mucous membrane and on the skin.

Cases 3, 17, and 21 refer to birds which belonged to tuberculous persons; and the parrot in Case 4 had often been in contact with a woman who afterwards died of pulmonary tuberculosis.

We were scarcely surprised that in the other cases our inquiries threw no light on the question of human infection. Parrots may contaminate one another, and may also contract tuberculosis from the dust existing in rooms,—that is to say, from bacilli introduced from out of doors.

Infection may occur by three different paths. Sometimes the bacilli penetrate by the respiratory tract. Thus pulmonary tuberculosis,

though exceptional in Gallinaceæ, is fairly frequent in parrots; this constitutes a further analogy with human tuberculosis. Sometimes, however, infection occurs through the skin; sometimes through the digestive tract. But while the Gallinaceæ are almost always infected by means of the food, and frequently show tuberculous enteritis, parrots, although they sometimes swallow food soiled with bacilli, are most commonly inoculated by contact with tuberculous persons, or by rubbing the head against the bars of their cage. This explains the frequency in them of lesions about the head, beak, tongue, palate, or pharynx.

Although the cases we have recorded appear to suggest that tuber-

Fig. 81.

culosis in the parrot is of human origin, the question could only be finally decided by experiment, and by directly transmitting mammalian tuberculosis to birds. We made three attempts of this character. The results were so clear and concordant that it appeared unnecessary to multiply experiments.

Experiment 1. On the 20th June, 1894, a green parrot was inoculated on the head with tuberculous material obtained from a guinea-pig, which had died from tuberculosis of canine origin.

On the 5th July two small nodules appeared, and became covered with thick blackish crusts. On the 15th August the crusts fell, leaving exposed a roughened, irritable, verrucous surface. Most of the nodules

showed a kind of horny covering, which could easily be removed. Microscopic examination of a fragment of morbid tissue revealed numerous bacilli. By the 1st October the lesion had extended to the root of the beak and upper part of the neck. On either side it overlapped the eyes, which were covered by the vegetations developed around them (Fig. 81).

The loss of condition and increasing dyspnœa caused us to suspect visceral extension of the disease. Unfortunately during the night between the 20th and 21st October this bird was partly eaten by rats, so that no complete autopsy could be made. The results obtained, however, sufficiently showed that mammalian tuberculosis may in the parrot produce cutaneous lesions identical with those which occur spontaneously.

Experiment 2. On the 10th August, 1894, a green parrot was ino-

Fig. 82.

culated like the preceding, and in October and November was similarly re-inoculated. In December the feathers were shed from around the point of inoculation, and the skin became thickened and wrinkled; gradually the lesions extended to the neck, beak, and claws; around the mandibles a kind of sheath developed, particularly marked towards the upper parts. The vegetations on the eyelids almost entirely covered the eyes (Fig. 82). The parrot died on the 28th September, 1896. On *post-mortem* examination no visceral lesions were discovered.

Experiment 3. On the 17th March, 1895, a parrot was inoculated

on the crown of the head with canine tuberculosis. At the commencement of June the skin over this part became thickened and covered with crusts. The lesions continued to grow and vegetations developed, one of which was specially notable on account of its size and horny covering (Fig. 83).

The parrot died on the 13th September, 1895, having survived inoculation 179 days. On *post-mortem* examination no visceral growth was discovered, but the tuberculous lesion developed at the point of inoculation was seen to have invaded and perforated the subjacent bones of

Fig. 83.

the cranium. On microscopical examination tubercle bacilli were identified in the new growth.

Mammalian tuberculosis inoculated into parrots had therefore produced lesions similar to those of spontaneous tuberculosis. The birds lost condition, and died emaciated in from four to thirteen months. On *post-mortem* examination the viscera appeared healthy, and contained no bacilli ; the organisms had remained confined to the point of inoculation. Sections showed large numbers in the local lesions. A single inoculation, however, does not always produce tuberculous lesions. In some cases the virus must be introduced several times, a fact which explains how certain parrots only become contaminated after months, or even years, passed in the neighbourhood of tuberculous persons.

Having shown that tuberculosis of parrots is, or at least may be, of human origin, the question arises whether the bacillus maintains its virulence in the organism of these birds. We have endeavoured to answer this question by directly inoculating with bacilli obtained from several parrots. We took care not to grow the virus on artificial media, for culture notably modifies its pathogenic properties: we wished to determine the virulence of the original bacilli.

The two following tables summarise two series of inoculations, the first of which was started with caseous material contained in the centre of a tuberculous swelling of the wing (Case 11), the second with a horny growth occupying the right side of the face (Case 5).

EXPERIMENT IV.

PARROT.
Tuberculous growth on the wing.
April 11th, 1894.

- GUINEA-PIG. Died May 26th (45 days). *Tubercle at point of inoculation; tuberculosis of the peritoneum and liver.*
  - GUINEA-PIG. Died June 18th (23 days). *Tuberculosis of the peritoneum, liver, and spleen.*
    - GUINEA-PIG. Died October 15th (99 days). *Generalised tuberculosis, spleen, liver, and lungs.*
  - RABBIT. Killed November 7th (162 days). *A few granulations on the peritoneum and in the liver.*
- GUINEA-PIG. Died May 29th (48 days). *Tubercle at point of inoculation; generalised tuberculosis* (peritoneum, liver, spleen, and lungs).*
  - GUINEA-PIG. Died September 29th (123 days). *Generalised tuberculosis.*
  - GUINEA-PIG. Died October 26th (144 days). *Generalised tuberculosis.*
  - RABBIT. Killed September 23rd (117 days). *A few granulations on the peritoneum and in the liver.*

* We have rarely witnessed such a development of tubercles; the peritoneum was covered with granulations, the spleen enlarged tenfold, and the liver was crammed with nodules. The lungs contained innumerable large tubercles, particularly in the posterior lobes. The mediastinal and mesenteric lymphatic glands were enlarged and caseous. Microscopic examination showed all the affected organs and tissues to contain numerous bacilli.

EXPERIMENT V.

PARROT.

Horny tuberculous growth on the right cheek.

July 5th, 1894.

GUINEA-PIG.

Died September 7th (64 days).

Generalised tuberculosis (peritoneum, liver, spleen, kidneys, and lungs).

GUINEA-PIG.

Died October 15th (38 days).

Generalised tuberculosis (liver, spleen, and lungs).

GUINEA-PIG.

Died September 27th (43 days).

Generalised tuberculosis (peritoneum, liver, spleen, and lungs).

RABBIT.	RABBIT.	FOWL.	FOWL.
Died September 1st, 1895 (278 days). *For seventeen days prior to death showed paraplegia. Generalised tuberculosis (liver, spleen, kidneys, lungs, dorso-lumbar paralysis of cord).*	Killed November 21st (357 days). *A few fibrous tubercles on the peritoneum and the liver.*	Killed November 11th, 1895 (349 days). *No lesion.*	Killed March 5th (454 days). *No lesion.*

EXPERIMENT 6. Guinea-pig inoculated on the 9th July, 1894, with part of a horny cutaneous growth from the right side of the head (Case 6). The guinea-pig died on the 30th August, *i. e.* at the end of fifty-seven days. Autopsy showed numerous granulations on the peritoneum, in the liver, spleen, and lungs.

EXPERIMENT 7. On the 28th September, 1895, three fowls were intra-peritoneally inoculated with experimental tuberculosis of the parrot (Experiment 2). One was killed on the 24th November following; another on the 5th December; the third on the 5th March, 1896. No change whatever was found on *post-mortem* examination.

To sum up, ten guinea-pigs inoculated with tuberculous material obtained directly from the parrot, or having passed through other guinea-pigs, died after periods varying between 23 and 144 days, that is after an average period of sixty-seven days. In all, *post-mortem* examination showed intense and generalised lesions.

Of four rabbits inoculated under the same conditions only one died spontaneously at the end of 378 days. The others were killed between the 117th and the 359th day. In spite of this much longer survival, which rendered the average period 226 days, we only found on *post-mortem* examination a few discrete granulations on the peritoneum and in the liver.

Tuberculosis of the Psittaceæ, unlike that of the Gallinaceæ, is therefore much more virulent for the guinea-pig than for the rabbit. In this respect it more closely resembles tuberculosis of mammals, with which it also agrees in being comparatively harmless for the Gallinaceæ (Experiments 5 and 7).

Bearing in mind the results already obtained, we have now to consider the relations existing between the tuberculosis of mammals and that of birds.

Avian tuberculosis, which is very frequent in the Gallinaceæ, can be transmitted to the fowl, pigeon, and the rabbit, and, with less facility, to the guinea-pig. It may also occur, with its own special characters, in the ox and in man (Kruse's and Pansini's cases).

Mammalian tuberculosis affects man, the dog, ox, and horse, and is readily conveyed to the guinea-pig and rabbit, which, however, is perhaps less sensitive to it than to avian tuberculosis: it can also be inoculated into the parrot, and sometimes the fowl.

The two viruses, therefore, affect the same animals. The titles given them are, therefore, not precisely correct, for the so-called tuberculosis of mammals is identical with that very commonly seen in parrots.

These results, therefore, render the barrier which was erected between the two viruses very narrow. Though it is allowable and necessary to admit the existence of two races of tubercle bacilli, it seems to us exaggeration to speak of two species. Between the extreme types numerous transition forms exist, and one variety can sometimes be transformed into the other. We have shown, for example, that the avian virus, after several passages through mammals, may lose its virulence for the Gallinaceæ; and conversely that human tuberculosis, when by chance conveyed to a fowl, may sometimes be afterwards passed through a series of fowls. But to obtain such positive results it is necessary to multiply experiments, and not to rest content with a few. For this reason we inoculated eighty-six fowls with human, and forty-two guinea-pigs with avian virus. It will be conceded that so large a number of experiments gives a certain weight to our conclusions.

To sum up, we have no intention of attempting to establish a complete parallel between the tuberculosis of Gallinaceæ and that of mammals. They show notable differences which we were not the last to recognise, but we continue to believe that, however important their distinctive characteristics may be, they are insufficient to destroy the unicist theory of tuberculosis.

This view of the question has important practical consequences. In parrots, for instance, the bacilli acquire extraordinary virulence for certain mammals, as shown by our inoculation of guinea-pigs; very rarely is human tuberculosis so active in these little rodents. Now bacilli exist in large numbers in the cutaneous growths, the buccal secretions, the nasal discharge, and sometimes in the excrement; they may readily be disseminated, and are much more dangerous when mixed with particles of organic matter. Parrots inoculated by man, therefore, become in turn permanent centres of tuberculous infection.

III.—EXPERIMENTAL TUBERCULOSIS IN THE GOAT.

By MM. Cadiot, Gilbert, and Roger.

Not all mammals are equally prone to contract tuberculosis, and it has been suggested that the goat and dog are almost completely refractory. Cases and experiments published during the last few years have, however, shown, contrary to formerly held opinion, that the dog has no particular immunity, and we believe the same is true of the goat.

Cases of spontaneous tuberculosis—that is to say, tuberculosis occurring apart from experimental inoculation—are, it is true, rare, but this is partly due to the small number of goats which are kept, to the little attention which has as yet been given to their diseases, and to the conditions under which they live. We know, in point of fact, that goats usually live in the open air; in poor countries they seldom leave the hills; under other circumstances they are kept in special sheds, and are therefore little exposed to contagion. Now the majority of reported cases refer to animals which lived in stables with cows or horses.

In 1871 Carsten Harms published the history of a goat which had been ill for six months, and on the *post-mortem* examination of which he found tubercles and cavernous spaces in the lungs. Gerlach published a similar case. Lydtin and Motz reported five others.

In a case mentioned by Sluys, Korevaar, and Thomassen, infection appeared due to the use of milk from a tuberculous cow; the lesions seen on autopsy were extremely extensive; they affected the intestine, mesenteric glands, liver, spleen, kidneys, and lungs. We may also refer to König's case, where the mesenteric glands, liver, and lungs were affected, and d'Alston's, in which tubercles were discovered in the lungs and bronchial glands.

This problem has been taken up by experimental pathologists, and a certain number of instructive cases related. The goat proves to be no more refractory to infection by the digestive tract than other

domestic animals; Bollinger's experiments remove all doubt on that point. Wesemer, who summarised all experiments made between 1865 and 1884 regarding this question, found that in the goat, as in the calf and sheep, the results were positive in about 50 per cent. of cases.

Among more recent work may be cited an interesting experiment by M. Nocard. On November 3rd, 1885, a goat was inoculated by injecting a certain quantity of tubercle culture into the jugular vein. The animal was killed in 1890. Its lung was riddled with cavernous spaces, and caseous or encysted nodules in which bacteriological examination revealed tubercle bacilli. This case is all the more remarkable inasmuch as the organism used was probably that of avian tuberculosis, the only one then cultivated in France.

M. Nocard supposed that tuberculosis had only developed because the goat employed had become affected with mange, which had enfeebled its general health; and he states that as a rule the goat "is almost absolutely refractory to tuberculosis, or at least is inoculated with difficulty." M. Colin again took up the question. He subcutaneously inoculated a goat with bovine tuberculosis. The animal was killed at the end of two months. Characteristic lesions were found at the point of inoculation, in the lymphatic glands of the corresponding side, and in the lungs. With this result before him M. Colin had no hesitation in declaring that the goat is not refractory to tuberculosis. This is also the opinion of M. Galtier, who, whilst freely admitting the rarity of spontaneous tuberculosis, recognises that the disease may be experimentally transmitted.

Such a collection of facts appears convincing. Undoubtedly the objection may be made that in the old experiments tuberculosis was not produced, but the objection is not of much value, for the lesions noted were as typical as those of the ox; and in more recent researches the detection of the tubercle bacillus entirely removed this objection.

As some authors continue to maintain that goats are refractory to tuberculosis we may here briefly give the results of three fresh experiments.

On the 28th January, 1892, two goats were inoculated by intraperitoneal injection with tuberculous material from a dog. They were killed on the 8th May. In the first tubercles were found on the peritoneum, in the mesenteric glands, lungs, and mediastinal glands, and some granulations in the liver and kidneys. In the second tubercles were also found on the peritoneum, and in the lungs and liver, while the chest contained a slight amount of exudate.

On the 29th July, 1892, a third goat was subcutaneously and intraperitoneally inoculated with tuberculous material from a horse. It remained in good condition until October. From that time it began to lose condition, and in spite of its appetite remaining good, wasting

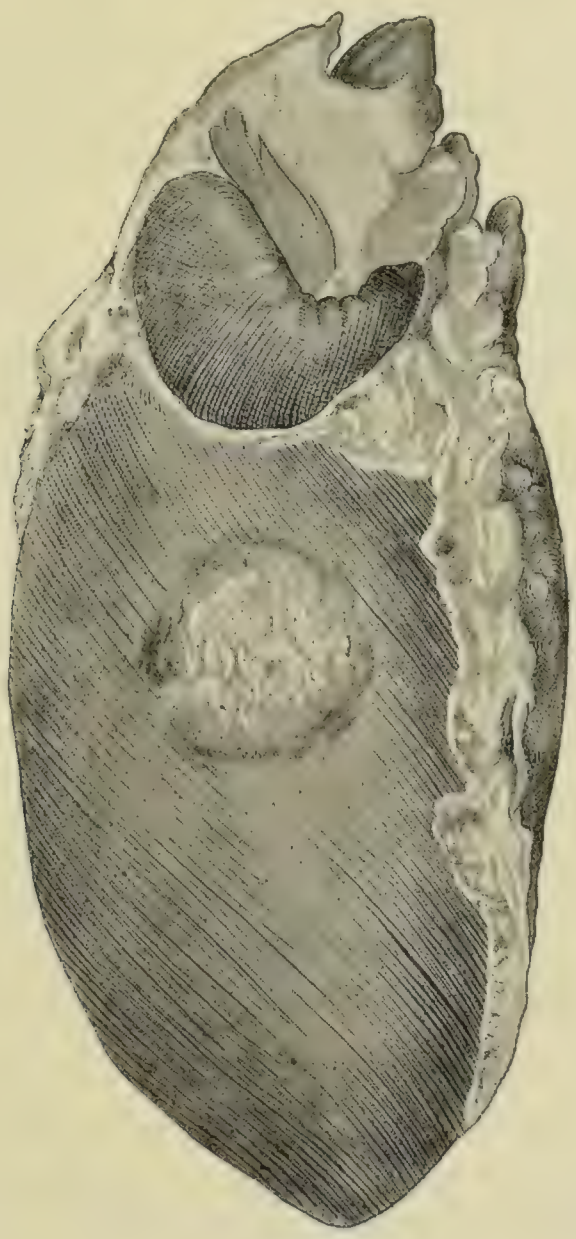

Fig. 84.

gradually became more marked until death occurred on the 6th April, 1893. The autopsy revealed somewhat extensive lesions.

On opening the abdominal cavity a quantity of greyish liquid, holding in suspension fibrinous flocculi, escaped. The parietal and visceral peritoneum was covered with fine granulations and tubercles, some the size of a hazel nut. The lesions were confluent over the entire extent of the epiploon, and in the portions of the peritoneum covering the lower wall of the abdomen, diaphragm, and rumen. The

loops of intestine were glued together, and to the parietal peritoneum by numerous adhesions. The liver, spleen, and kidneys were infiltrated with tubercles. All the abdominal lymphatic glands were affected. The thoracic cavity contained half a pint or more of greyish serosity mixed with fibrinous flocculi. The pleura was completely covered with fine granulations. On its diaphragmatic portion were tubercles varying in size between a millet seed and of a haricot bean. Along the course of the aorta the mediastinal glands formed a voluminous, fusiform, greyish mass marked with numerous little greyish-white tubercles.

The surface of both lungs—and particularly that of the posterior lobes—showed prominent greyish tuberculous growths, the centres of which were softened; similar growths had developed in the depths of the lungs. Even the heart was invaded, the myocardium of the left ventricle showing a large tuberculous growth (Fig. 84).

The tubercle from the heart was examined histologically, and for tubercle bacilli. Almost the whole of this tubercle was composed of degenerating cells. Only the periphery contained masses of living cells. In places the growth had undergone fibrous change, and these contained numerous bacilli.

The cases and experiments we have described in this note appear sufficiently numerous to carry conviction. We were, therefore, somewhat surprised to see in a recent book that the goat is refractory to tuberculosis, and that up to the present day no observations have been published proving the occurrence in it of tuberculous lesions. The slightest bibliographical search would have convinced the author of his error.

But, if the goat possesses no immunity, what becomes of that method of treatment, which consists in transfusing its blood into the veins of phthisical patients? As no serious experiments appear to justify this method of treatment its application to man is entirely unwarranted. Luckily the suggestion almost immediately fell into well deserved oblivion.

IV.—MALIGNANT TUMOURS IN ANIMALS.

By MM. Cadiot, Gilbert, and Roger.

Animals frequently suffer from tumours similar to those affecting man. The occurrence of such lesions was recognised by the oldest authors who devoted their attention to animal pathology. They are mentioned in the writings of the Greeks and Latins, and in the works of the Hippiâtres, but the merit of having first given exact descriptions of some of them, and of having shown their frequency in carnivora—especially in the dog—must be ascribed to Huzard in the eighteenth century.

From 1825, when the first French veterinary medical journals appeared, the question was studied by a large number of observers, among whom may be mentioned Trousseau and U. Leblanc, Gerlach, C. Leblanc, Trasbot, and Plicque.

At the present day we know that cancer may occur in all species of animals. The fact that it has seldom been noted in the goat and sheep is undoubtedly due to neglect of the pathology of these animals; what is true of tuberculosis probably applies also to cancer; cases will be found if trouble is taken to look for them.

Among the domestic animals the dog is most frequently affected with new growths, then the horse, and afterwards the cat, ox, and pig. In birds, tumours are not uncommon, but many show special histological characters.

Ætiology and Pathogeny.—In animals the ætiology of tumours is as obscure as in man. The influence of heredity seems established by several cases. We saw a bitch which had twice been operated on at intervals of a year for cancer of the mammary gland. Two of her progeny were also attacked with mammary cancer, one when four years old, and the other when five, that is, at ages when epithelial new growths are somewhat rare.

Age plays an important part as a predisposing cause. Of thirty-three cases in the dog, in which the age was exactly known, the figures were as follows:—one case at three years; one at four years; two at five years; four at six years; nine at seven to eight years; eight at

nine to ten years; five at eleven to twelve years; two at fourteen years; and one at twenty years. In the horse the age varies between seven and fifteen years. The nature of the congenital tumours described by some authors has not been established by sufficiently exact microscopic examination to justify us in admitting their existence.

Primary cancers generally appear on the surface of glandular organs, or in external parts exposed to mechanical irritation. It has been suggested that in the horse friction of the harness is sufficient to produce cancer. In reality these growths are chronic inflammatory indurations, sometimes exhibiting the appearance of fibromata, or are parasitic lesions due to the presence of bothryomyces. Mere mechanical injury is not sufficient to produce the growth of tumours; observation tends to establish this point, and experiments also point in the same direction. We mechanically irritated the mammary gland in several old eczematous bitches; every day, or every two days the glands were compressed and bruised by means of strong wooden forceps; although the experiments were continued for months, we never succeeded in producing new growths, and only in two cases did an abscess form.

Mechanical injury, therefore, only plays a secondary part. The same is true of the hygienic conditions under which animals exist. Contrary to the statements of some authors, we believe that it is impossible to render animals cancerous by submitting them to special life conditions. But it seems, according to Leblanc's statement, that animals restricted to meat diet and chained or shut up are more often affected with cancerous lesions than others.

Among predisposing causes it is still usual to mention gout. M. Trasbot strongly insists on the part played by this diathesis. According to him, dogs, and even horses, suffering from cancer have almost always previously shown eczematous eruptions.

At the present time the tendency is to consider cancer as a parasitic affection, and cases have been described in man which appear to establish this contagious character. We have noted nothing similar in animals. All the attempts we have made to transmit new growths from man to the dog, from dog to dog, or from the dog to the rabbit or fowl, have uniformly failed; nor were we more successful in attempting to graft fragments of their own tumours on healthy parts of cancerous dogs. On two occasions we seemed at first to have obtained a positive result; but in one of these cases the secondary tumour had none of the histological characters of the primary; and, in the other, the lesions, though offering

the macroscopic appearances of cancer, proved in reality due to tuberculosis.

These two cases led us to doubt the old records and those in which the histological or bacteriological characters of the lesions produced have not been carefully studied. We may add, however, that we succeeded in transmitting to dogs papillomatous vegetations developed on the glans penis of an affected dog. The growths thus produced, however, remained local and underwent retrogressive processes, behaving in fact like simple grafts. MM. Duplay and Cazin have related a similar case.

Negative results do not justify us in denying the parasitic nature of cancer. They simply suggest the need for modifying our experimental methods, for they tend to show that we shall not solve the problem by merely multiplying inoculations by processes hitherto employed.

Position of the Tumours.—In animals, as in man, cancer may attack the most varied tissues, but shows a well marked predilection for the mammary gland. Of thirty-eight cases observed in dogs eighteen consisted of mammary tumours, a fact which explains the greater frequency of cancer in the bitch. After the mammary gland the testicle is one of the organs most frequently attacked. Retention of this gland within the abdomen seems to predispose it to degenerative new growths. It is not uncommon to find cancerous testicles in monorchid or cryptorchid horses.

Malignant tumours also occur with some frequency in certain exposed parts and on certain mucous membranes. The nose and sinuses of the face are the seat of various new growths. The same is true of the digestive tract. Cancer of the tongue is exceptional; that of the lips, though rare in large animals, is fairly frequent in old dogs, in which, however, it must not be confused with a special affection which has long been regarded as of epitheliomatous nature. This so-called canchroid of the lip is oftenest noted in the cat, and has also been seen in the dog; it is an ulcerative inoculable lesion, but it heals with great facility. On histological examination the growth shows no resemblance to cancer.

Cases have been published of cancer of the pharynx (Benjamin); of the œsophagus (Lorenz); of the stomach in the horse (Roloff, Mouquet, and Cadiot); of the pylorus in the dog (Müller); of the rumen (Siedamgrotzky); and of the reticulum in the cow (Beylot); of the intestine (numerous observations); of the anus (Trasbot). Sometimes the abdominal viscera are affected, as the pancreas (Nocard, Martin); liver (Benjamin and Martin); kidney (Siedamgrotzky, Johne,

Harvey); bladder (Martin and Stolz); prostate (Cadiot); and other parts of the genital apparatus. We have already mentioned the frequency of new growths in the testicle. Cases have also been seen of cancer of the penis, of the sheath, and of the ovary (Krüger); uterus (Gürlt, Lucet), and vulva (Martin). Contrary to the experience of human surgeons, cancer of the uterus is, in animals, extremely rare.

Among the other organs affected we may mention the parotid (Laugeron and Cadiot); pituitary gland (Mollereau); thyroid gland (Cadiot); the lung and maxillaries (Leisering, Barrier, Cadiot); neck (Müller); tail (Müller, McFadyean). We have several times seen cancer of the eye in the horse and dog. Mauri saw pulmonary cancer with secondary growths, in the ox.

Visceral cancers are much rarer than was formerly believed. In a great number of cases the growths found in the thoracic or abdominal viscera, are due to tuberculosis. This mistake has long been made in connection with the dog, for in this animal tuberculosis often produces large growths which invade the viscera, especially the liver and lungs, or the serous membranes, particularly the peritoneum and pleura. The mistake may not be discovered even on histological examination, because the structure of the growth rather recalls sarcoma or lymphadenoma than tubercle. Only the detection of bacilli and the results of inoculation reveal the true nature of these growths. The same remarks apply to the horse. Many cases regarded as lymphadenoma or visceral tumours are really due to tubercle.

Growths produced by vegetable parasites have long been mistaken for cancer, and especially for sarcoma. Among such are bovine actinomycosis and equine bothryomycosis, both of which, however, are well known and readily diagnosed at the present day.

It would almost seem that acari may excite the development of new growths. In an old bitch suffering from tumours of the vulva, which had deformed the vagina and at certain points had perforated its walls, microscopic examination showed the new growths to be formed of round cells, amidst which acari were discovered.

To sum up, animals may show lesions resembling tumours, which, however, have been produced by the most varied processes, some tuberculous in character, others due to vegetable parasites, like actinomycoses and bothryomycoses, or to animal parasites, like acari; others, again, of an ulcerous nature resulting from the action of microbes, like canchroid of the lip in the cat.

Most of the older writers having failed to sufficiently guard against these causes of error, it is difficult to draw conclusions from their reports. Confusion has occurred even in recent experiments, a fact

which explains the opinion still held that sarcoma is more frequent than carcinoma.

Thus Semmer, after examining fifty-seven malignant tumours, which he had collected, found thirty-two sarcomatous and twenty-five carcinomatous. In a special report he related fifty-six new cases of sarcoma. In the table printed below we have compared Semmer's figures with our own. It will be noted how widely our results differ from his.

According to our researches, chiefly on the dog, epithelioma is much commoner than sarcoma. The opposite opinion is probably due to the mistakes so often made between sarcoma and tuberculosis.*

Species of Animal.	Semmer's Statistics.			Our own Statistics.		
	Carcinomata.	Sarcomata.		Epitheliomata	Sarcomata	Tumours of doubtful character.
Dog	7	17	30	27	11	—
Horse . . .	14	7	12	4	1	—
Ox	4	2	4	—	—	—
Pig	—	1	2	—	—	—
Cat	—	—	—	1	—	—
Birds . . .	—	4	6	—	—	3
Fishes . . .	—	1	2	—	—	—
	25	32	56	32	12	3

The figures showing the frequency of tumours in animals treated at the Berlin, Munich, and Dresden schools, for an average period of seven years, are as follows:—

Of 86,113 diseased horses, 1113 suffered from tumours = 1·3 per cent.
Of 85,537 diseased dogs, 4020 ,, ,, ,, = 4·7 ,,
Of 4972 diseased oxen, 102 ,, ,, ,, = 2 ,,

Fröhner determined the nature of 643 tumours removed from dogs in the clinique for small animals at the Berlin school. He found: 306 malignant tumours (*i. e.* about 47 per cent.); 262 epitheliomata (40 per cent.); and 44 sarcomata (7 per cent.). Of 47 new growths removed from the horse, 16 were malignant (34 per cent.); 10 sarcomata (21 per cent.); and 3 epitheliomata (6 per cent.). Of 75 new growths from oxen, the histological examination of which was carried out by

* In his *Pathologie der Geschwülste bei Thieren*, Caspar has collected interesting statistics regarding tumours in animals from the reports made by the professors of clinical medicine and pathological anatomy in the German veterinary schools.

Eggeling of the ambulatory clinique at Berlin, 22 were malignant (29 per cent.); 20 sarcomata (27 per cent.); and 2 epitheliomata (2·7 per cent.).

A pathological report by Johne comprises a description of all the new growths seen in 4439 animals examined after death at the Dresden school during a period of sixteen years :—

Of 1181 horses, 128 suffered from tumours (11 per cent.); of 1600 dogs, 93 suffered from tumours (5·8 per cent.); of 1658 oxen, 104 suffered from tumours (6·3 per cent.). Among the 128 tumours from the horse were 60 sarcomata (47 per cent.), and 28 epitheliomata (22 per cent.). The 93 tumours from the dog furnished 48 epitheliomata (52 per cent.), and 26 sarcomata (28 per cent.). The 104 tumours from

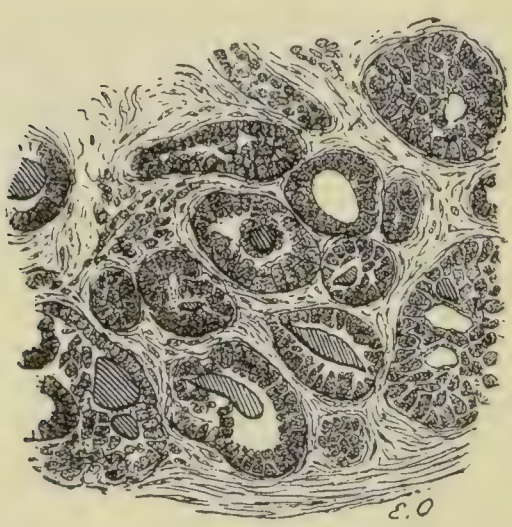

FIG. 85.—Epithelioma of the mammary gland (bitch). The centres of the alveoli contain a hyaline substance.

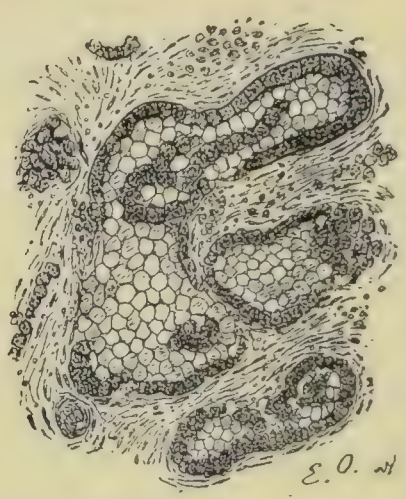

FIG. 86.—Epithelioma of the mammary gland. The central portions of the alveoli are occupied by degenerating cells.

the ox gave 36 sarcomata (35 per cent.), and 8 epitheliomata (8 per cent.

The differences revealed on comparing these clinical and anatomo-pathological statistics are explained by the fact that the first referred almost exclusively to external tumours, whilst the others took note of the total number of new growths found in different organs. It is also well to remark that the majority of these statistics were collected at a time when the lesions of actinomycosis, bothryomycosis, and tuberculosis were included under the title of sarcomata.

But taken as a whole the results given confirm the greater frequency of epithelial tumours in the dog as compared with the horse and ox; and they again show that in the herbivora these tumours are not so exceptional as is generally suggested.

Histological Appearance.—All authors agree in recognising the

frequency of mammary tumours. We have studied nineteen, one of which was obtained from a mare; the others being of canine origin.

The tumour from the mare, and eleven of the tumours removed from bitches, showed the histological appearances of epitheliomata. They were composed according to the classical schema of a stroma surrounding alveolar cavities. In these cavities the epitheliomatous cells were generally arranged around the margin, producing acini, in the centres of which was sometimes found a clear substance exuded undoubtedly by the newly formed cells (Fig. 85); but most frequently (Fig. 86) degenerating cells without nuclei, which were stained a dirty yellow by picrocarmine. At places the new growth deviated from the original type and showed irregularly arranged cells contained within alveolar cavities, or grouped together in large masses. In some cases the stroma predominated, displacing the new cells and producing the appearance of scirrhous cancer.

Among other tumours developed in the mammary glands we first

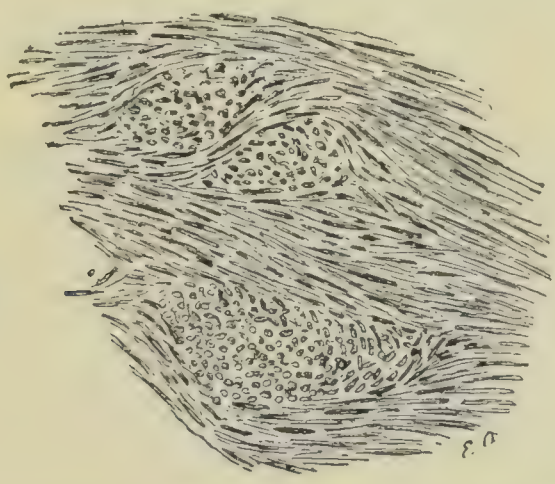

Fig. 87.—Fusiform-celled sarcoma from the mammary gland of the bitch.

mention two fusiform-celled sarcomata (Fig. 87). The cells contained large nuclei provided with clearly marked nucleoli; at certain points degenerating cells could be seen.

In three cases we found a form of sarcoma with rounded or oval cells massed together or scattered through a chondroid, hyaline, or fibrillated substance, showing at several points true chondroplasts provided with cartilaginous cells (Fig. 88).

In other cases the development of the growth had led to formation of a tissue resembling bone; of this we saw two examples. In one the tumour was formed of granular blind sacs alternating with hyaline cartilage and osteoid growths; osteoplasts and canaliculi could even be detected, though the latter were less numerous and less well defined than normal.

The other case was that of an aged bitch, in which the new growth had existed for two years and had returned after partial ablation. When the animal was killed the mammary gland and lungs were found to contain tumours of cartilaginous appearance, ossified in places. Histological examination showed that the tissue resembled the spongy tissue of bone and contained intercommunicating areolæ. The osseous portions were pierced with little angular cavities filled with nucleated cells; they differed from normal bone inasmuch as there was no lamellar arrangement and no Haversian canals, while the basement substance stained red with picrocarmine. The areolæ surrounded by

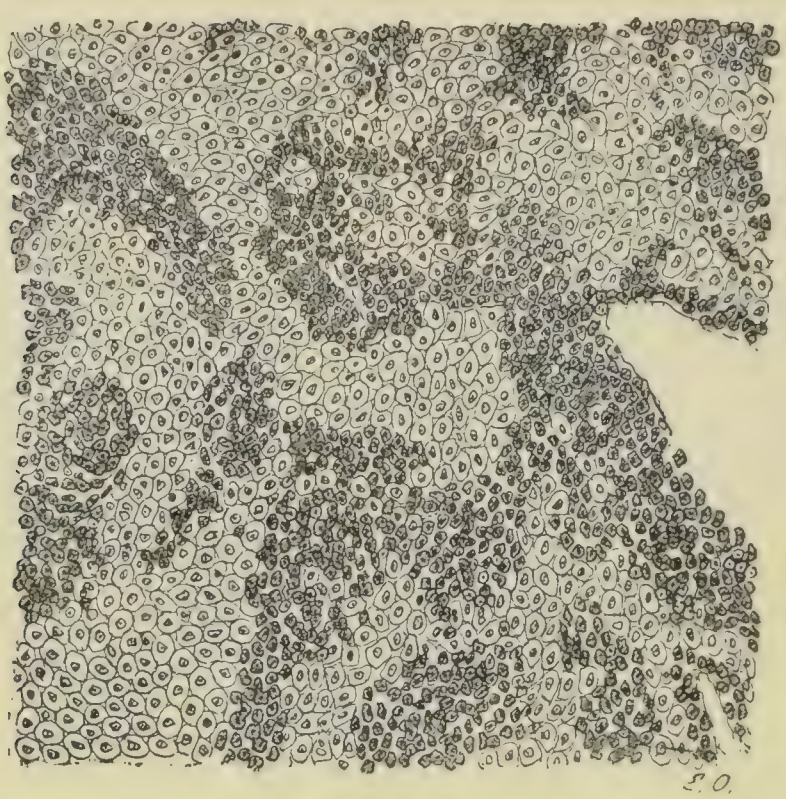

Fig. 88.—Chondroid sarcoma of the mammary gland (bitch.)

this osteoid tissue contained cells like those in bone marrow (Fig. 89).

After those of the mammary gland, tumours of the testicle are amongst the most frequent. We have examined five, three from the dog and two from the horse.

In the horse the tumour may attain considerable size: in one case it weighed four and a half lbs.; in another affecting a retained testicle the weight was 6 lbs. 10 ozs.

All five tumours had a very similar appearance. They consisted of a stroma, according to the development of which in various parts the new growth resembled encephaloid or scirrhous cancer. The

individual characteristics of the cells and general arrangement of the cylinders recalled the appearance of normal testicle tissue (Fig. 90).

In animals cancer not infrequently appears first in the nasal fossæ, or in the facial sinuses. Sometimes it originates in the paradental

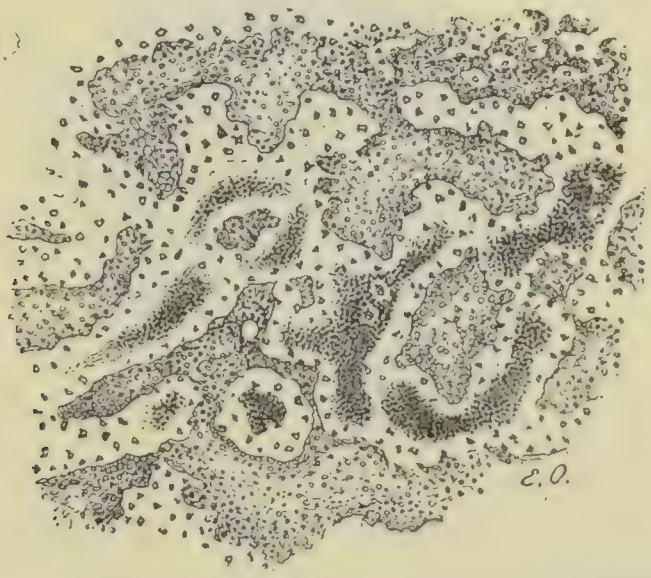

Fig. 89.--Osteoid sarcoma of the mammary gland (bitch).

epithelial débris and invades the superior maxilla. We have collected three cases of these various localisations in the dog and two in the horse.

One of the dogs exhibited a lymphadenoma readily recognisable by its reticulated stroma containing small round cells and vessels with normal walls. The two other dogs showed alveolar epitheliomata, in which the stroma was scanty and the cells polyhedral or polymorphic.

The lesions were very different in the horses; one horse showed a

Fig. 90.—Epithelioma of the testicle (dog).

globo-cellular sarcoma; in the other the tumour was more complex, being formed of rounded cells, among which were disposed epitheliomatous tracts.

Cancer may attack any of the glands of the digestive tract. In the dog we have seen epithelioma of the parotid (Fig. 91) remarkable for the presence of epidermal nests. This appearance, also seen in man,

FIG. 91.—Epithelioma of the parotid (dog).

is explained by the embryological origin of the parotid, which forms a simple outgrowth of the buccal mucous membrane.

One of the most curious of all the epithelial tumours was seen in an

FIG. 92.—Pavement epithelioma of the stomach (mare).

eleven-year-old mare which, though previously in good health, rapidly succumbed to an accidental infection. On *post-mortem* examination

the stomach was found to contain an enormous cancer, which had remained completely latent. The new growth occupied the left side of the stomach, and was irregularly triangular in form, with its base

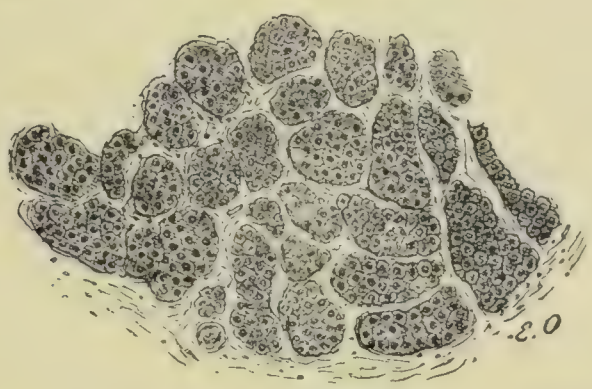

FIG. 93.—Epithelioma of the peri-anal gland (bitch).

uppermost; it measured ten and a quarter inches in length, and nine and a half inches in breadth; its surface was ulcerated and covered with reddish mammillated vegetations. The lesion, which had extended three eighths of an inch into the œsophagus, stopped abruptly at the line of separation between the cuticular and villous portions of the gastric mucous membrane, altogether avoiding the latter. At its margin the wall of the stomach was thickened, indurated, and in places œdematous. The growth occupied that portion of the gastric mucous membrane which in the horse is continuous

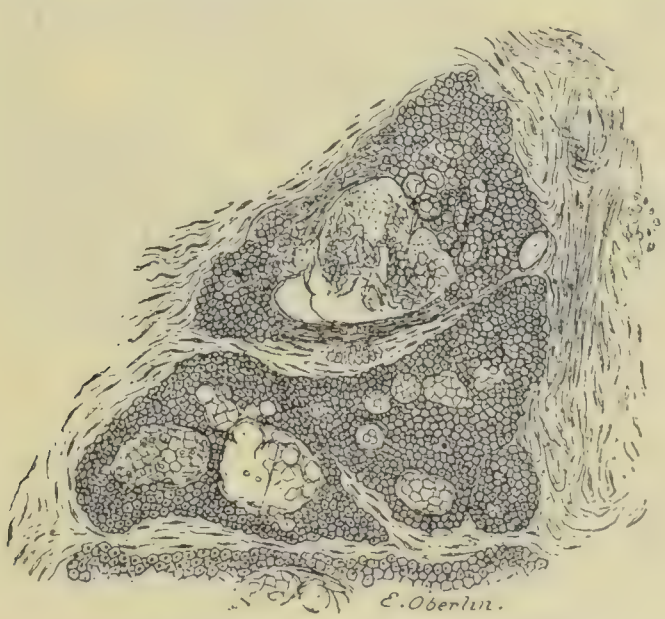

FIG. 94.—Sebaceous epithelioma (dog).

with the œsophagus. Microscopic examination showed, as a knowledge of anatomy would lead one to anticipate, that the tumour was of the pavement epitheliomatous type (Fig. 92).

We also examined a tumour developed in the anal region of an eight-year-old bitch. This tumour, which had existed for a year and attained the size of a hen's egg, was composed of tracts of cells, divided, subdivided, and separated from one another by partitions of fibrous tissue. The cells were polyhedral in shape and formed of a mass of protoplasm which stained yellow with picrocarmine, surrounding a circular or oval nucleus; none showed any signs of degeneration (Fig. 93). The analogies between this new growth and certain tumours of the liver, pancreas, and kidney led us to regard it as of glandular origin; a view strengthened by histological examination of the perianal region in the dog, in which we found many glands pre-

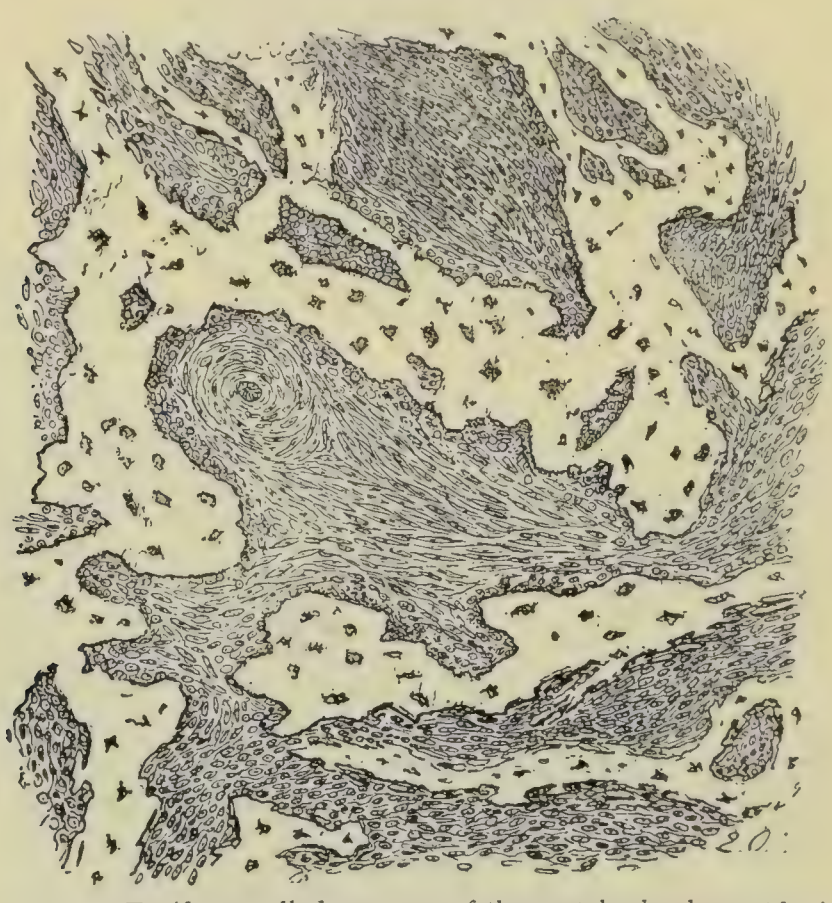

FIG. 95.—Fusiform-celled sarcoma of the vertebral column (dog).

senting a striking resemblance in structure or arrangement to the tumour examined.

We have studied three cases of cancer of the skin. In one the tumour was in the anal region and consisted of a pavement epithelioma containing epidermal nests. In another the lesion had originated from certain sebaceous glands. The patient, a seven-year-old dog, showed a large number of verrucous tumours about the body. One of these the size of a hazel nut was excised; it consisted of masses of cells similar to those in the Malpighian layer of the skin; the

central cells were infiltrated with fat globules or had undergone fatty degeneration; at several points these degenerated cells were surrounded by other flattened cells arranged in lamellæ (Fig. 94). The third consisted of an epithelioma the alveoli of which contained small rounded elements. Sections showed numerous cells resembling those described by various authors as coccidia. We have several times noted cells of this character, but in the above cases they were particularly abundant and remarkable. Although the source of the cancer was evident in the two first cases it was extremely doubtful in the third.

In passing we may also mention the various epithelial tumours affecting the point of the elbow, thoracic walls, lung, thyroid body, penis, and lips in the dog. In a cat we saw an epithelioma occupying the thoracic wall, and the substance of the lungs.

Though rarer than has usually been described, sarcoma is nevertheless fairly frequent in the dog. We found a round-celled sarcoma in the elbow region, and a fusiform-celled sarcoma on the buttock. We had under observation a nine-year-old sheep dog with complete paraplegia, accompanied, however, by persistence of cutaneous sensation, due to a tumour which had destroyed the body of the first lumbar vertebra; it projected considerably into the neural canal, and was almost as large as a fowl's egg. This tumour proved to be a fusiform celled sarcoma (Fig. 95), containing tracts of osteoid tissue, which stained rose-red with picrocarmine, and were pierced with stellate cavities provided with canaliculi, resembling in shape osteoplasts.

In two horses we saw lesions resulting from repeated mechanical injury. In one case a tumour, the size of a man's fists, had developed on the anterior margin of the shoulder beneath the collar. In another the growth had existed for two years. It was located on the metatarsus of the near hind limb, a little above the fetlock, was very large and ulcerated on the surface. It had returned after removal. These new growths were not true tumours but chronic inflammatory growths formed by fibrous tissue. We mention these cases because without recourse to the microscope they might have been mistaken for cancerous tumours, the result of injury. The return after operation and the ulceration of the surface might seem to justify such a view.

We have also seen tumours in three fowls. In one case the feet were the seat of soft new growths. In the two others, numerous tumours, varying in size between a haricot bean and a hazel nut, were found in the liver, spleen, lungs, intestine, and peritoneum. These

various lesions, which were unsuccessfully used for inoculating other fowls, rabbits, and guinea-pigs, were all of similar structure, being formed of small, closely packed, polyhedric cells provided with large nuclei. A considerable number of vessels were seen, but no stroma could be discovered. These peculiar tumours differed considerably from any seen in mammals.

To facilitate study of the results of our research we recapitulate them in the form of a table.

Species of Animal.	Seat of the Tumours.	Nature of the Tumours.	Number.	
Dog, 38 cases.	Mammary gland	Adenoid epithelioma	11	18
		Fusiform-celled sarcoma	2	
		Chondroid sarcoma	3	
		Osteoid sarcoma	2	
	Testicle	Adenoid epithelioma	3	
	Facial sinuses and superior maxilla	Alveolar epithelioma	2	
		Lymphadenoma	1	
	Parotid gland	Epithelioma with epidermal "nests"	1	
	Peri-anal glands	Adenoid epithelioma	1	
	Thyroid gland	Epithelioma with small polyhedral cells	1	
	Skin	Pavement epithelioma with epidermal "nests"	1	3
		Small-celled epithelioma	1	
		Epithelioma of the sebaceous gland	1	
	Lips	Epithelioma with tendency to scirrhous transformation	1	
	Penis	Adenoid epithelioma	1	
	Lungs	Epithelioma	1	
	Thoracic wall	Epithelioma	1	
	Buttock	Fusiform-celled sarcoma	1	
	Elbow region	Round-celled sarcoma	1	2
		Epithelioma	1	
	Spinal column	Fusiform-celled sarcoma	1	
Horse, 5 cases.	Mammary gland	Adenoid epithelioma	1	
	Testicle	Adenoid epithelioma	1	
	Facial sinuses	Epithelioma	1	2
		Globo-cellular sarcoma	1	
	Stomach	Pavement epithelioma with epidermal "nests"	1	
Cat	Thoracic wall and lungs	Cylindrical epithelioma	1	
Fowl	Feet	Masses of polyhedral cells	1	
	Viscera	Masses of polyhedral cells	2	

When cancer occurs in parts accessible to manual examination, it first appears as a swelling, which gradually increases in size and soon becomes adherent to the skin. In almost all cases the primary lesion is surrounded by hard, irregular, lymphatic chains running towards the neighbouring lymphatic glands, which are enlarged. Secondary tumours next appear, either around the new growth or over the track of the indurated lymphatics. At the same time the tumour increases in size, becomes bosselated and sometimes ulcerated at certain points.

The mode of development of cancer varies extremely. Speaking

generally, sarcoma grows more rapidly than carcinoma, and although it has less tendency to invade the skin and lymphatic glands, it probably more often becomes generalised in the viscera. One of us reported a case of primary sarcoma of the femur in a large dog, which died in consequence of invasion of the lungs; on *post-mortem* examination more than 2000 tumours were counted on the surface of the internal organs.

Despite the existence of cancer the patient's general condition may remain good. This is particularly the case in cancer of the mammary gland. Distinct wasting may only commence after one or two years. When the lesions become generalised the animals appear weak and depressed, showing a train of symptoms depending on the organs attacked.

As death approaches the white blood-corpuscles usually increase in number. In the dog just mentioned, the proportion shortly before death was one leucocyte to seventy-three red blood-corpuscles.

Incomplete ablation of cancerous tumours is always followed by return, the new tumour generally developing more rapidly than the primary. But early and total extirpation seems to give better results than in man. Horses and dogs which had been operated on were under observation for periods of a year, eighteen months, and two years without showing any return.

To sum up, cancer in animals seems, in a general sense, less grave than in man. It has a greater tendency to remain localised to the point of origin and returns less rapidly and less frequently. But these differences are far from being absolute, and in spite of the reserve with which we have spoken, it must be recognised that in all mammals cancer presents the same anatomical and clinical characters.

We have sufficiently dwelt on the microscopic appearance of the new growths and shall not therefore return to it.

We simply add that examination of tumours in animals affords powerful evidence in favour of the epithethelial origin of cancer. It shows that the tumour presents special characters indicating its origin, as we pointed out when speaking of new growths in the mammary gland, testicle, and skin, and when describing the case of the horse with a pavement epithelioma developed on the cuticular portion of the gastric mucous membrane. It is also interesting to note that tumours of the mammary gland have a tendency to develop into complex types and to undergo chondroid, or even osteoid, transformation. This tendency is also seen in man, though in an infinitely smaller proportion of cases.

Our object in this report has been to give the results of our personal researches. For this reason we make no mention of certain neoplasms, like melanotic tumours, which are very common and are almost always of sarcomatous character (Cornil and Trasbot).

In conclusion, we again draw attention to the difficulty of utilizing old records in the synthetic study of malignant tumours, on account of the frequent confusion which has occurred between cancer and parasitic, or tuberculous lesions.

PART V.

EXPERIMENTAL THERAPEUTICS.

I.—THE TREATMENT OF TUBERCULOSIS.

In the experiments hitherto made regarding the serum treatment of tuberculosis five principal methods have been adopted: (1) Injection of blood, or serum, from animals regarded as refractory to tuberculosis; (2) injection of extracts of organs from such animals; (3) injection of blood or serum from animals previously inoculated with virulent tuberculous material, or with living cultures; (4) injection of serum from animals previously inoculated either with tuberculous products, with sterilized cultures, or with tuberculin; (5) injection of serum from animals inoculated with certain soluble products derived from tubercle bacilli.

MM. Héricourt and Richet, in a note communicated to the 'Académie des Sciences,' announced the result obtained by intraperitoneally injecting into rabbits already inoculated with *Staphylococcus pyosepticus*, blood from normal healthy dogs, or from dogs which had been inoculated with this staphylococcus and had recovered from the local infection thus produced. In certain cases injection of normal blood was followed by recovery, but when blood from prepared dogs was used all the rabbits survived.

Concluding from these results that the blood injected exercised a microbicide action, MM. Héricourt and Richet asked themselves whether this influence of dog's blood did not apply to other diseases, to which the animal is but little sensitive, and they, therefore, extended the treatment, by injection of blood, to certain of these diseases, among others to tuberculosis. Experimenting on rabbits inoculated with cultures of bovine or avian tuberculosis, they found that animals which received injections of dog's blood died in the proportion of only 17 per cent., whilst in control animals the mortality was 55 per cent.

As early as 1881 M. Bouchard had succeeded in increasing the resistance to the pyocyanic bacillus by injecting into the rabbit's veins blood or serum obtained from the dog. Shortly afterwards he found that the serum possessed similar immunising powers and produced the same therapeutic effects as blood itself.

Starting with these facts and the then very general belief that goats were refractory to tuberculosis MM. Bertin and Picq subjected rabbits inoculated with tuberculosis to injections of goats' blood. According to their observations this fluid in doses of 2·50 grammes per kilo of body-weight checked the development of the disease, and even cured animals when treatment was commenced shortly after inoculation. These authors and M. Bernheim applied this method of treatment to man; M. Lepine also tested in man the effects of injecting goat's serum.

The experiments undertaken by M.Bouchard in 1891, and published in January, 1892, show that the blood and serum of animals which are refractory (or were so considered), and of the goat in particular, far from having a favourable influence when injected into tuberculous animals often appeared to exercise an absolutely injurious effect. He says :—" As a whole the cases inoculated have been graver and more rapidly fatal in the guinea-pigs treated than in the control animals."

The end of the year 1890 had been marked by an important discovery which inaugurated the era of sero-therapy. Behring and Kitasato had discovered the existence of anti-toxic substances in the fluids of animals vaccinated against tetanus and diphtheria. They had found that the blood of animals rendered refractory, either by Nicolaier's or Löffler's bacillus, had the power of neutralizing or rendering harmless the toxins of these bacilli; that this property extended to the serum as well as to the unaltered blood; and that it permitted of definite treatment. Everyone knows the results of sero-therapy in diphtheria and tetanus.

Attempts were, therefore, made to effect for tuberculosis what had been done for tetanus and diphtheria; efforts were made to immunise animals (goat, sheep, dog, horse), to bring about by various methods the production of tuberculous antitoxins in the bodily fluids of these animals. Numerous experiments were undertaken with this object. We should specially mention those of MM. Héricourt and Richet, who prepared serum-yielding animals by injecting them with virulent tuberculous cultures, both human and avian; those of Behring, who produced an antitoxic serum by injecting different animals with tuberculin; of Nieman, who prepared dogs and goats by injections with an alcoholic extract of tuberculin; of Maragliano, who first injected all

the toxic substances extracted from very virulent cultures of human tuberculosis and afterwards a quantity of tuberculin; those of Babès and Proca, who successively injected avian and human tuberculin, followed by dead bacill of avian and human origin.

According to the investigators who prepared them, certain of the sera thus obtained had a real antitoxin action; they prevented the development of bacilli and secured recovery from experimental tuberculosis. But as a whole the results seemed very uncertain, and despite the optimistic conjectures indulged in, the future of serum treatment for tuberculosis remained undecided.

The experiments of Gilbert, Roger, and Cadiot were commenced in 1892. Observed facts and experiments had shown that certain animals previously regarded as refractory to tuberculosis, among others the goat and dog, were in reality moderately sensitive to it: but, struck by the resistance of the Gallinaceæ to mammalian tuberculosis, these observers studied the action produced by the defibrinated blood and serum of birds on its evolution. In order to obtain sufficient quantities of blood and serum they chose the turkey, in which puncture of the humeral vein yields a considerable quantity of blood, and which can be bled two or three times per month for a considerable period.

Several series of experiments made on the guinea-pig showed that the serum and defibrinated blood of birds injected under the skin or into the peritoneum have no greater action on tuberculosis than similar fluids obtained from mammals. They in no way check the course of the disease; and, in fact, a certain number of the animals treated died before the controls.

They afterwards studied the action of serum from turkeys previously injected with tuberculous material by way of the veins. For several months these birds were periodically injected with one half to one fluid drachm of an emulsion prepared with tuberculous products, most frequently from the dog. The injections were repeated every week or fortnight, the total number of virulent injections varying between six and twelve. Some weeks after the last, when bacilli had disappeared from the blood, the defibrinated blood or serum was used. In a certain number of guinea-pigs treated at the therapeutical laboratory of the Faculty of Medicine with serum thus obtained, the development of tuberculosis was manifestly less rapid than in control animals.

In another series of experiments serum-yielding animals were prepared by injecting into the veins or peritoneum doses of fifteen to

forty-five minims, either of diluted tuberculin, or of living or dead cultures of canine tuberculosis, suspended in sterilised water. Except in birds, in which they produced disturbance, these injections were repeated eight to twelve times, at intervals of one to two weeks.

The sera thus obtained were of no value; either the animals treated died of tuberculosis like the controls, or both subjects and controls showed tuberculous lesions similar in point of intensity and generalisation when (regarding it as useless to prolong the experiment until the subjects died) the survivors were killed.

It is known that in tuberculous patients specific buccal lesions are relatively rare, although tubercle bacilli are to be met with in the mouth of many consumptives, being carried there by expectoration. Starting with this fact, M. Bloch, Doctor at the National Asylum at Vincennes, propounded the question whether saliva might not exercise an attenuating action on the tuberculous virus and on the infection it produces.

In tuberculosis especially every theory founded on observed facts deserves to be submitted to experimental proof, and therefore M. Cadiot undertook an inquiry into the influence which injections of saliva might exercise on the development of the disease.

Guinea-pigs rendered tuberculous by intra-peritoneal inoculation of a culture of canine tuberculosis emulsified in sterilised water were treated with parotid saliva collected aseptically from a horse. On the 1st September, 1898, M. Cadiot commenced the treatment of a preliminary group of eight guinea-pigs inoculated on August 14th, and of a second group of eight guinea-pigs inoculated on the 31st August.

In each series five subjects were treated. In three, sixteen to thirty-two minims of saliva were injected into the peritoneum every two or three days; in the other two the injection was made hypodermically. Three animals were reserved as controls.

On the 22nd September one guinea-pig of the first group, which had been inoculated eight times in the peritoneum, died. On autopsy enormous tuberculous lesions were found in the liver, spleen, and epiploon; the lymphatic glands were enlarged, and numerous granulations were seen in the lungs.

A guinea-pig of the second group died on the 29th September after the eleventh injection. It also showed tuberculous lesions in the liver, spleen, epiploon, and lungs, though the lesions were much less marked than in the first.

A second animal of the first group, which had received 380 minims of saliva in the peritoneum, died on the 30th September. The *post-*

mortem examination showed hepatic and splenic lesions of an even more marked character than in the first subject. The liver was enormous, yellowish in colour, and crammed with tubercles. There were numerous pulmonary granulations.

Although these results were discouraging, the injections were continued until the 10th October. At this time both the animals treated and the controls were very thin. The investigation was terminated by killing the surviving guinea-pigs. All showed tuberculous lesions, and except in the case of two guinea-pigs belonging to the second group, treated by subcutaneous injections, these lesions were more intense and more generalised in the animals which had been injected than in the controls.

The parotid saliva of the horse has no attenuating action *in vitro* on Koch's bacillus. M. Cadiot mixed 100 minims of saliva with a quantity of the same tuberculous culture as was used for the preceding experiments. After three days of contact, during which every precaution was taken to avoid changes in the emulsion, it was injected into the peritoneum of two guinea-pigs. At the same time a portion of the culture equal in quantity to that which had been added to the saliva was saved, and having been emulsified in a little sterilised water was injected into the peritoneum of two other guinea-pigs. The four animals were killed at the end of forty days and showed tuberculous lesions of the liver, spleen, and lungs. In the first two peritoneal granulations were found, but in the others nothing abnormal was discovered.

II.—THE SERUM TREATMENT OF GLANDERS.

In glanders, as in tuberculosis, attempts have been made to utilise in treatment blood and serum from refractory animals. Malzew and some other experimenters claim to have been successful in immunising animals by injections of ox serum. MM. Chenot and Picq by thus treating guinea-pigs rendered glanderous by inoculation with virus taken from the horse succeeded in curing seven cases out of ten. Similar attempts made by MM. Nocard and Leclainche failed.

During the past two years I have treated with defibrinated ox blood and serum, and afterwards with defibrinated blood and serum from birds, several series of guinea-pigs which had been inoculated by scarifying the skin of the flank or face and applying glanders pus. The results were as disappointing as those in connection with tuberculosis. The injections did not seem to me to exercise any real influence on the local lesions, or on the development of disease. In the majority of cases they did not prevent extension of the ulcer, enlargement of lymphatic glands, or production of visceral lesions. In some cases the local ulcer healed, but this also occurred in a proportion of the control animals. Such a result is not uncommon in chronic glanders in the guinea-pig, and as the secondary lesions are irregular in intensity and distribution, being sometimes confined to a few granulations or small caseous centres, it is easy to understand why certain authors came to believe in the efficacy of serum from refractory animals.

I attempted to prepare an antitoxic serum by the same methods as had been followed in connection with tuberculosis. Turkeys were intra-venously and hypodermically injected with sterilised glanders cultures and mallein. These birds proved fairly sensitive to the action of the glanders poison. Whilst they resisted large doses of tuberculin and tubercle bacilli fairly well, they suffered much more from repeated injections of mallein or of glanders bacilli. Nevertheless

several birds which had received eight to twelve hypodermic or intravenous injections survived for some months.

With serum thus obtained I treated during October and November, 1898, some guinea-pigs inoculated in the flank by scarification with glanders virus taken from the horse. From twenty animals thus inoculated on the 23rd September, 1898, I chose ten in which the local lesions were well developed and practically of uniform intensity. All showed ulcers with indurated bases, accompanied in most by inflammation of the precrural lymphatic glands. Seven of these guinea-pigs were injected every third or fourth day with thirty to eighty minims of serum; five were injected subcutaneously and two intra-peritoneally. In four the injections were continued for five weeks (4th October to 10th November). In three the ulcer healed with fair rapidity, and in general wasting appeared less marked than in the controls, but, like the latter, the animals treated showed various secondary complications, such as orchitis, abscess formation, and cutaneous ulcers; and although three months after inoculation one was still in fairly good condition and free of apparent complications, it proved to be suffering from grave visceral lesions.

Two of the injected animals and a control died before the end of the first month; three injected animals and the two last controls during the course of the second month; and one of the two surviving animals which had been treated on the seventy-fourth day. On autopsy all these animals showed multiple visceral lesions, but principally inflammation of lymphatic glands, granulations, and more or less numerous nodules in the liver, spleen, or lungs. On *post-mortem* examination the last of the animals, killed on the 27th December (after ninety-five days), also showed lesions in the lymphatic glands, liver, and spleen.

I shortly transcribe two of the records concerning injected animals:

(1) Male guinea-pig, weighing thirteen ounces, inoculated on the 23rd September. On the 29th there was marked swelling of the scarified region. On the 4th October a circular ulcer, the size of a threepenny piece, had developed; its base was cupped, greyish, dotted with red points, and surrounded by an indurated zone; the animal's weight was twelve ounces and a half.

On the 5th the first injection was made. On the 10th the precrural lymphatic glands were the size of a haricot bean, and a sarcocele had developed. The ulcer was stationary. On the 16th the external lesions were in the same condition, but the animal was already much wasted; weight eleven ounces and three quarters. On

the 23rd there was discharge from both nostrils; respiration was painful and wheezy. The animal died on the 27th; weight of the cadaver ten ounces. It had been injected six times, and had received in the subcutaneous connective tissue of the abdomen five and a half fluid drachms of serum.

Autopsy.—The ulcers in the flank and the enlarged precrural lymphatic glands were connected by a fine knotted lymphatic cord. An abscess the size of a haricot bean had developed in the thickness of the abdominal wall at the point where the injections had been made. Granulations and a few purulent nodules were present in the liver, spleen, and lungs. There was suppurative orchitis on the left side, acute inflammation of the peritoneal covering of the cord. The upper portion of the vaginal sheath was obliterated by an extensive fibrous exudate.

(2) Male guinea-pig, weighing fourteen ounces, inoculated on the 23rd September. On the 1st October the point of inoculation showed a large bright red indurated patch. On the 4th a grey, cupped ulcer had developed; the margins, from which the hair had fallen, were whitish in colour. Enlargement of the precrural glands as large as a pea.

First inoculation on the 5th October. On the 16th the ulcer in the flank was slightly enlarged, and the precrural glands formed a swelling the size of a haricot bean; weight twelve ounces and a quarter. On the 25th the appearance of the ulcer in the flank had improved; its borders were less red and hard. The right testicle was inflamed. On the 8th November a cutaneous ulcer appeared towards the centre of the dorsal region. On the 22nd this ulcer and that in the flank were healing. The orchitic swelling was as large as a hazel nut. Died on the 10th December. Weight of the cadaver ten ounces and three quarters. This guinea-pig had received nearly eight fluid drachms of serum in eleven injections.

Autopsy.—The ulcer in the flank had healed; that on the back only measured one sixth of an inch across. There was generalised inflammation of the lymphatic glands, the centres of which were caseous. The liver contained some purulent nodules; the spleen was enormous, weighing one and a quarter ounces, and was bosselated with nodules and caseous centres. Three or four small pulmonary tubercles. Suppurative orchitis.

Nine other guinea-pigs, inoculated by scarifying the skin of the face and applying glanders pus obtained from the horse, were treated with serum from turkeys injected with mallein, and afterwards with

living glanders bacilli. The results were similar to the preceding. The disease developed in the injected animals much as in the controls. I was unable to note any well-marked differences in the development and characters of the initial lesion, in those of the pre-auricular and pre-scapular lymphatic infections, or in those of the visceral lesions.

The favourable influence which serum appears to exercise on some subjects is exclusively due to the animal's individual power of resistance, and to the peculiar way in which glanders often develops in guinea-pigs. This is well shown by the fact that progress is slow and development localised just as frequently among control animals as among animals subjected to treatment.

III.—THE ACTION OF VANADINE.

For some years attempts have been made to utilise in practice the remarkable oxidising properties of vanadium and its compounds. Vanadic acid, vanadate of soda, and vanadine have all been studied, and have been recommended in the treatment of pneumonia, rheumatism, and tuberculosis.

I have made an experimental and therapeutic study of various preparations of vanadium, but especially of vanadine. Considerable doses of vanadine may be injected into the connective tissue or veins of animals without producing any toxic symptoms, in the guinea-pig a subcutaneous injection of thirty to fifty minims produces no appreciable disturbance. In most cases nothing abnormal follows hypodermic injection of 1 c.cm. per 100 grammes (approximately fifteen minims per three ounces) of body-weight, but a double dose is fatal. Guinea-pigs of 400 to 600 grammes (approximately twelve and a half ounces to eighteen and a half ounces) in weight bear hypodermic or intra-peritoneal injections with 1 c.cm. (fifteen minims) of vanadine repeated every second or third day, for a considerable period. In the rabbit intra-venous injection of 1 c.mm. of vanadine per kilogramme is well borne, and the animal often survives doses four times as large. A rabbit of five pounds weight, which had received 120 minims of vanadine in the auricular vein, showed grave symptoms (convulsions, paresis, dyspnœa, and prostration), which continued for several hours, but the animal gradually recovered. A dog, weighing sixteen and a half pounds, showed no disturbance after an intra-venous injection of 120 minims of vanadine; nor was anything noted in a dog weighing eighty one and a half pounds, which received into the saphenous vein two fluid ounces of vanadine. A horse weighing 528 lbs. showed nothing appreciable after a first intra-venous injection of fourteen fluid drachms of vanadine, followed some days later by a further injection of two fluid ounces. In a horse weighing 594 lbs., an injection of twenty-eight fluid drachms of vanadine into the jugular produced restlessness, trembling, soft evacuations, and lowering of temperature to the extent of 1° C.

Excessive doses of vanadine produce a series of grave symptoms, but particularly nausea, vomiting of food or glairy material followed by blood, diarrhœa, soon succeeded by blood-stained evacuations, lively thirst, apoplectiform attacks, acute pain, shown by groaning or crying, slowing of the circulation and respiration, attacks of dyspnœa, and finally depression of temperature. I noted all these troubles in a dog weighing thirteen pounds three ounces which received five and a half fluid drachms of vanadine in the saphenous vein.

I have used vanadine in the treatment of certain diseases in the horse and dog, principally pneumonia, the abdominal form of influenza, distemper and its complications, wasting diseases, and in persistent loss of appetite due to gastro-intestinal atony. I have injected it into the subcutaneous connective tissue in doses of fifteen to eighty minims in the dog, and of five and a half to seven fluid drachms in the horse. At the present time I have not collected sufficiently numerous statistics to show how much should be given in the treatment of acute diseases, but in such affections, and particularly in pneumonia, where the local lesion is far from possessing the importance attributed to it, where the morbid symptoms are due to diminution in the aërating surface, to auto-intoxication, to diminished elimination, or to the transformation of poisons, vanadine, like every agent possessing oxidising properties, appears to have a favourable effect. Injected in small doses repeated daily, or every second or third day, it acts as a tonic, increases or restores the appetite, stimulates nutrition, favours assimilation, arouses the forces, and improves the condition of emaciated animals. It may, perhaps, prove of service in the treatment of chronic affections with loss of strength or wasting.

I have also studied its effects on guinea-pigs rendered tuberculous by injecting cultures of canine origin emulsified in sterilised water. Eight guinea-pigs were thus inoculated on the 9th August, 1898, in the subcutaneous connective tissue of the flank, and a second series of eight guinea-pigs in the peritoneum. Two animals of each series were preserved as controls; the others received every third or fourth day a hypodermic injection of a few drops up to fifteen minims of vanadine. These injections were begun on the 17th August, and continued until the 15th October.

During the course of the research five guinea-pigs died; three inoculated in the peritoneum—two under treatment, and one control; two inoculated under the skin—one treated and one control. On *post-mortem* examination all showed more or less generalised lesions, depending on the time which had elapsed since inoculation. In the

guinea-pig under treatment the seat of inoculation in the flank showed a large tuberculous ulcer.

Of the survivors, those under treatment, equally with the controls, gradually lost weight; in no case where an ulcer had developed in the flank after inoculation did it heal.

All the guinea-pigs were killed on the 15th October, and all showed tuberculous lesions. In many of those treated with small doses of vanadine the lesions were only a little less numerous or less diffused than in the others.

MM. Laran and Hallion obtained very interesting results by treating guinea-pigs, rendered tuberculous by subcutaneous inoculation, with very small hypodermic injections of vanadic acid. Under the influence of these injections M. Laran has "often seen healing of tuberculous ulcers in animals. In a guinea-pig thus inoculated and treated by vanadic acid death was postponed for a year and a half. M. Hallion, who studied the pulmonary lesions histologically, noted "very marked fibrous transformation."

IV.—INTRA-VENOUS INJECTIONS OF IODINE.

In veterinary practice very few substances are introduced directly into the blood, and we may say that until now this method of administering medicines has scarcely extended beyond the laboratories and the text books. Although the first attempts at utilising certain remedies, and iodine in particular, by intra-venous injection are fairly old, it was long believed that the method was dangerous, and that iodine introduced into the blood-stream would cause sudden death by producing changes in the brain and spinal cord. Such an accident, in fact, followed certain intra-venous injections of iodine in the horse, but is explained without difficulty by the excessive doses and the method of procedure.

The credit of having first drawn attention to the remarkable tolerance of the blood towards iodine solutions is due to Cezard, a veterinary surgeon of Verennes-en-Argonne, in his 'Mémoire sur la Médication Antivirulente' (1874), who stated that he injected into the jugular vein of a horse weighing 1056 lbs., which was suffering from chronic glanders, two drachms of iodine and four drachms of potassium iodide in one dose. This injection being made slowly only produced a little temporary excitement; the animal took food almost immediately afterwards, and was worked two hours later. The author adds, "For intra-venous injection a two per cent. solution may be used, of which a medium-sized horse will take, without inconvenience, twelve and a half ounces at a dose." Four per cent. to five per cent. solutions are also without danger provided they be injected slowly. In this way from two and a half to ten drachms of iodine may be given to large animals in twenty-four hours."

Rossbach, who made experiments in this connection, also states that intra-venous injection of relatively large doses of iodine produce no complications in the horse.

More recent experiments have shown that other animals also tolerate iodine and the iodides when introduced directly into the blood. According to Bohm the dog shows no particular disturbance after injection of an aqueous solution in the proportion of ·15 to ·22 grain of iodine per pound of body-weight, the iodine being dissolved

by the addition of two or three times its weight of sodium iodide; but a dose of ·3 grain per pound of body-weight produced general weakness, difficulty in respiration, and in some cases convulsions and death in from twelve to twenty-four hours. G. Sée and M. Lapicque saw no special disturbance in a dog weighing 17 lbs. 3 oz., into whose saphenous vein they slowly injected at intervals of a quarter of an hour two doses of fifteen grains of potassium iodide.

Iodine when directly introduced into the blood probably assumes the condition of sodium iodide, or combines with albumen, forming unstable compounds, which disengage iodine in contact with living protoplasm. Elimination by the kidney commences rapidly. At the end of a few minutes iodine can be detected in the urine in the condition of sodium iodide, but a portion remains in the blood, and the drug appears to have a special predilection for the muscles, kidney, and brain. M. Gallard found that it is retained in the latter in considerable quantities.

In order to study the therapeutic action of iodine and its use in the treatment of certain animal diseases, I first determined the dose which could without danger be introduced into the blood. I prepared solutions varying in strength from 1 per cent. up to 5 per cent., the iodine being dissolved by the addition of potassium iodide (iodine 1, potassium iodide 1·5, water q. s.). My experiments on animals of different species have given results which, while confirming the tolerance of the organism for iodine, show that it has been greatly exaggerated, and that small doses produce very appreciable results. The following records are interesting in this respect:

(1) Dog, weighing 39½ lbs., received at 2 p.m. on the 14th February, 1898, an injection of five and a half fluid drachms of a 1 per cent. iodine solution into the saphenous vein. No manifest disturbance.

(2) Dog, weighing 41¾ lbs., received at 3 p.m. on the 18th February, an injection of one fluid ounce of a 1 per cent. iodine solution into the saphenous vein. At the end of an hour and a half restlessness appeared, followed by signs of depression and shivering fits, at first localised in certain regions, especially in the crural and gluteal muscles, but afterwards generalised. At 5 p.m. the temperature had risen to the extent of ½° C., and the heart's action was slightly accelerated. A little later the symptoms diminished; at 8 p.m. they had disappeared; the animal was bright, lively, and ate its food readily.

(3) Dog, weighing 79¼ lbs., received at 3 p.m. on the 20th February, an injection of six and a half fluid drachms of a 5 per cent. iodine solution, *i.e.* a little more than ·2 grain of iodine per pound of

body-weight, in the saphenous vein. In a quarter of an hour it showed signs of restlessness and whined a little. Twenty minutes later slight localised intermittent trembling occurred, and gradually became accentuated and generalised. The trembling fits afterwards diminished, and finally disappeared at the end of four hours. At 8 p.m. the animal showed no disturbance and readily ate. During the night urine resembling that of hæmoglobinuria was passed.

(4) A dog, weighing 30¾ lbs., received at 10 a.m. on the 24th February an injection of three fluid drachms of a 5 per cent. iodine solution (·3 grain per pound of body-weight) in the jugular vein. In a few minutes fæces were passed. Except for signs of restlessness no manifest disturbance; only a few shivering attacks. During the afternoon the dog passed blackish hæmoglobinuric urine; no after-symptoms.

(5) A goat, weighing 81½ lbs., received at 2 p.m. on the 25th February in the jugular vein an injection of seven fluid drachms of a 5 per cent. iodine solution (·26 grain of iodine per pound of body-weight). Temperature before injection 39·2° C. At 3 p.m. masticatory movements were made. At 4 p.m. slight trembling of the muscles of the quarter and thigh, passage of hæmoglobinuric urine. At 6 p.m. temperature 40·6° C.; prostration; the trembling attacks persisted. At 8 p.m. temperature 40·2° C.; fresh passage of hæmoglobinuric urine. After this the symptoms gradually disappeared.

(6) A cow, weighing 620½ lbs., received at 9 a.m. on the 25th February an injection into the jugular vein of two fluid ounces of a 5 per cent. solution of iodine (·07 grain per pound of body-weight). At the end of fifteen minutes, salivation; twenty minutes later, passage of normal fæces and yellowish urine; no manifest disturbance of circulation or respiration. At 3 p.m. slight trembling attacks in the hind quarters, continuing for two hours; hyperthermia, which attained its maximum (1·4° C.) at the eighth hour. At 4 p.m. passage of brownish hæmoglobinuric urine. During the night the symptoms disappeared.

(7) A horse, weighing 525¾ lbs., received at 1 o'clock on the 28th February an injection of eleven fluid drachms of a 1 per cent. iodine solution. At the end of a few minutes fæces were passed. Half an hour later trembling appeared, at first localised in the hind limbs, but soon becoming generalised; it diminished rapidly, and disappeared in an hour.

At 2 p.m. next day received an injection of thirteen and a quarter fluid drachms of the same solution. Immediately before injection temperature 39·3° C., respirations 12, pulse 45. Fæces were passed at the end of three minutes. 12.30 p.m., trembling movements in the

vasti and gluteal muscles, soon extending to all the hind limbs, and afterwards to the whole body; slight ptyalism and grinding of the jaws; ears and extremities cold. At 3 p.m. temperature 39·8° C.; respiration and circulation slightly disturbed; generalised trembling; somnolence. The symptoms afterwards disappeared.

(8) A horse, weighing 533½ lbs., received at 9 a.m. on the 11th March an injection in the jugular vein of fifteen and a quarter fluid drachms of a 5 per cent. iodine solution (·07 grain per pound of body-weight). Before injection temperature 38·0° C., respirations 17, pulse 45. During the succeeding two hours the temperature rose appreciably; the respiration and circulation became more rapid. At 11.30 a.m. muscular trembling, salivation, grinding of the jaws, cough, and slight weeping appeared; these troubles persisted for two or three hours. At 1 p.m. temperature 39·1° C., respirations 30, pulse 78; the respiration suggested dyspnœa. An hour later the trembling diminished; the circulation and respiration became slower, and the temperature fell. No after complications.

(9) A horse, weighing 682 lbs., received at 3 p.m. on the 18th March in the jugular vein seventeen fluid drachms of a 5 per cent. solution of iodine (·07 grain per pound of body-weight). Before injection temperature 38·2° C., respirations 18, pulse 46. At the end of half an hour slight salivation, grinding of the jaws, and acceleration of breathing (twenty-five per minute). At 4 p.m. trembling, especially marked in the hind limbs and face; passage of hard fæces and flatus. Temperature 38·7° C.; respirations 22; pulse 45. At 5 p.m. passage of fæces moister than on the preceding occasion; the passage of flatus and the trembling persisted. Temperature 39·1° C.; respirations 15; pulse 42. At 6.10 p.m. passage of hæmoglobinuric urine; slight trembling. At 7 p.m. the animal appeared a little depressed, but otherwise showed nothing abnormal.

(10) A horse, weighing 902 lbs., received at 2.50 p.m. on the 21st March an injection in the jugular vein of twenty-two fluid drachms of a 5 per cent. iodine solution (·07 grain per pound of body-weight). Before injection temperature 38° C.; pulse 38; respirations 10. At the end of a quarter of an hour grinding of the jaws and salivation; expulsion of flatus. Fifteen minutes later temperature 38·5° C.; pulse 38; respirations 18; respiration difficult, expiration irregular. Trembling attacks, at first localised in the crural and gluteal muscles, afterwards generalised; signs of depression. At 3.30 p.m. more abundant ptyalism; spasmodic contractions of the jaws; stamping and signs of excitement alternating with periods of depression; passage of soft fæces; strong and persistent borborygmus. At 4 p.m. temperature

38·4° C.; pulse 39; respirations 11; ptyalism and trembling continued; signs of depression became more marked; fresh passage of soft excrement. At 5 p.m. temperature 38·1° C.; pulse 45; respirations 13; passage of large quantities of hæmoglobinuric urine; the depression, salivation, and trembling fits were diminishing. At 6 p.m. temperature 38·4° C.; pulse 47; respirations 11; still a few trembling movements. At 7 p.m. temperature 38·4° C.; pulse 52; respirations 14. The animal seemed to have resumed its normal condition.

(11) Horse, weighing 594 lbs., received at 1 p.m. on the 29th March an injection into the jugular vein of twenty-four fluid drachms of a 5 per cent. iodine solution (containing 64·5 grains of iodine, *i. e.* a little less than ·12 grain per pound of body-weight). Before the injection temperature 38·1° C. At the end of three minutes defæcation; a quarter of an hour later salivation, attempts to vomit, rapid breathing; twenty minutes later excitement and signs of colic. At 2 p.m. ptyalism continued, and the animal attempted to vomit; softened fæces were passed; temperature 38·5° C. From the second to the fourth hour trembling and signs of depression; temperature 39·1° to 39·8° C. At 5 p.m. passage of hæmoglobinuric urine. After 6 p.m. the disturbance diminished. There was no after complication.

Introduced into the blood-stream in doses of ·007 grain per pound of the animal's body-weight (*i. e.* six grains for a horse weighing 880 lbs.), with the addition of sufficient iodide to dissolve it, iodine is well tolerated and produces no manifest external symptoms. In doses of ·014 grain per pound (twelve grains for a horse weighing 880 lbs.), whatever the degree of dilution, it usually produces more or less pronounced symptoms, depending on the species of animal and on its individual susceptibility, symptoms among which ptyalism, trembling fits, and localised convulsions are the most constant. Injection of larger doses is only justifiable if immediate intense action is necessary, if the doses can only be given at intervals of several days, or can only be repeated a few times.

In doses of ·07 grain (60 grains for a horse weighing 880 pounds), iodine produces grave disturbance, symptoms of hæmoglobinuria, and very frequently renal lesions similar to those of hæmaturia.

In my therapeutic experiments I did not exceed doses of 7 to 30 grains per day according to the weight of the horse.

According to some authors iodine when injected into the blood can have no useful effect because it combines with alkaline substances. It would, therefore, have no action on micro-organisms, to destroy which

such large quantities would be required as to cause death from acute iodism. In attacking the microbe one would destroy the cells and kill the animal. But in refutation of this we urge that iodine, like the iodides and other antiseptics, may prove valuable in toxi-infections without actually destroying the microbes. Small quantities of antiseptics and other chemical agents may act either by diminishing the production of microbic poisons, by assisting in their destruction by the organs, or by stimulating the emunctories; or again, by exciting the tissues to greater action, modifying the fluids of the body, and rendering them less favourable to pathogenic agents. From this point of view intra-venous injections of certain antiseptics seem capable of varied application. Only to mention one, if the reported cases of recovery from glanders after intra-tracheal injections of iodine are authentic—I especially allude to those of Chelchowski and of Neimann—intra-venous injections of similar solutions deserve trial in horses which mallein shows to be suffering from internal glanderous lesions, and which sometimes have to be kept under observation for mouths. As the specific lesions from which they suffer often end by spontaneously healing, it is conceivable that one might assist the organism in its struggle against infection and help it to emerge triumphant.

Many other drugs may also be given intravenously with advantage; thus intravenous injections of argentum colloidale Credé in doses of six to twelve grains dissolved in ten to thirteen fluid drachms of water have proved of remarkable value in purpura hæmorrhagica of the horse (Dieckerhoff, Meissner, Kröning) and in gangrenous coryza in the ox (Meissner, Tannebring, David).

In a similar way chloride of barium has been administered to produce rapid evacuation of the bowel when treating colic in the horse. Despite the accidents which have followed administration of excessive doses, or in which the animals were already intoxicated by intestinal poisons, many practitioners continue its use. Syncope is avoided by injecting small doses at intervals of fifteen to twenty minutes, as I suggested in 1897. The first dose injected should be from three and a half to nine grains, which may if necessary be repeated in fifteen to twenty minutes.

In animals intra-venous injection is very simple, though it requires a little practice. As a rule the substance employed is very active, the quantity of liquid injected small, and no special instrument necessary; a syringe of six fluid drachms capacity and a needle about three inches

in length being alone required. In large animals, and even in the dog, the jugular is the vessel chosen.

The vein is compressed at its lowest point until it becomes distended and prominent, the needle is then introduced obliquely in the direction of the vessel, the further wall of which must not be pierced; the skin is drawn slightly towards the head, and the needle gently passed in succession through it, the subcutaneous connective tissue, and the wall of the vein.

Escape of blood through the needle shows that it has entered the lumen of the vein. Should any doubt exist on this point—especially if the horse has struggled meanwhile—the vein is again "raised" for an interval of a few seconds and blood again caused to escape from the needle. The latter is then grasped between the index finger and thumb, the nozzle of the syringe attached to it, and the liquid slowly injected.

The bore of the needle being so narrow, passage of air need not be feared, though even should a few small bubbles pass into the vein no bad effects follow.

APPENDIX.

A COMPARATIVE table showing the approximate equivalent in Fahrenheit's scale of a given Centigrade reading.

Cent.	Fahr.	Cent.	Fahr.	Cent.	Fahr.	Cent.	Fahr.
Degrees.	Degrees.	Degrees.	Degrees.	Degrees.	Degrees.	Degrees.	Degrees.
38·0	100·4	39·0	102·2	40·0	104·0	41·0	105·8
·1	100·5	·1	102·3	·1	104·1	·1	105·9
·2	100·7	·2	102·5	·2	104·3	·2	106·1
·3	100·9	·3	102·7	·3	104·5	·3	106·3
·4	101·1	·4	102·9	·4	104·7	·4	106·5
·5	101·3	·5	103·1	·5	104·9	·5	106·7
·6	101·4	·6	103·2	·6	105·0	·6	106·8
·7	101·6	·7	103·4	·7	105·2	·7	107·0
·8	108·8	·8	103·6	·8	105·4	·8	107·2
·9	102·0	·9	103·8	·9	105·6	·9	107·4

INDEX.

PAGE

ABOMASUM, ulceration of 469
Abscess, cardiac 365
— cold, in retro-pharyngeal glands . 336
— of liver 376
Acariasis, symbiotic, and eczema of ear 312
Acute inguinal hernia 35
Adenoma, mammary, with pulmonary metastasis 517
Agoraphobia 273
Amenorrhœa 424
Amputation of penis 56, 412
Anæmia, parasitic 504
Aneurismal varix, spermatic . . 408
Aorta, posterior, rupture of . . 386
Aortic insufficiency in the horse . . 125
Aponeurosis of flank, necrosis of . 368
"Arterial dance" 128
Artery, pulmonary, rupture of . . 366
Ascites, chylous, in a cat . . . 380
Atrophy of penis 414
Auricles, ossification of . . . 153
Auricular myocarditis 150
Avian tuberculosis 522
— — summary and conclusions . . 554
Azoturia 249

BASEDOW'S disease 272
Behring's antitoxin in tetanus . 501
Blennorrhœa in the dog . . . 52
Bothryomycosis 477
Bradycardia 157
Brain, echinococcosis of . . . 504
Bruit de pot fêlé 177, 192

CACHEXIA 276
Calculus, urethral . . . 414

PAGE

Cancer of inferior maxilla . . . 328
— of kidney 389
— of penis 410
— of scrotum 405
— of stomach 374
— of superior maxilla 22
— of tail 287, 427
— of testicle 405
Cancerous intra-orbital growth . . 310
Cancroid, pseudo-, of lip . . . 324
Canine tuberculosis, method of infection in 241
— — origin of 241
Canker, auricular 287
"Canker" of the foot 296
Carcinoma of kidney 517
Cardiac abscess 365
— intermittency in the horse . . 157
"Cardiac heart" 149
— kidney" 136
— liver" 135
Caries, dental 8, 330
Carpal sheath, suppurating synovitis of 437
Cataract, operation for 312
— traumatic 311
Cerebral hæmorrhage 305
— injury and Cheyne-Stokes respiration 307
Cerebrum, tuberculosis of . . 470
Cervical desmotomy 341
Cheek, papillary sarcoma of . . 326
Cheyne-Stokes respiration . . . 307
Chorea 510
Chronic myocarditis 151
— pharyngitis 335
— pleurisy in the horse . . . 202

PAGE

Chronic roaring, surgical treatment of . 30, 347
Chylous ascites in cat 380
Cocco-bacille typhique 188
Cold abscess in retro-pharyngeal glands 336
Constipation 384
Contagious pneumonia in the horse . 185
— — Schütz's organism of . . . 187
Corn, complicated cases of . . . 455
"Corrigan's pulse" 139
Cortical or partial myocarditis . . 151
Costal region, abscess of . . . 357
"Critical abscesses" 192
Cryptorchid operations . . . 397
Cyst, hydatid, of heart . . . 364
Cystic degeneration of ovary . . 421
Cysts, dentigerous . . . 1, 23
— sebaceous, in false nostril . . 316

DÉBRIS, paradental epithelial . 2, 28
Degeneration, cystic, of ovary . . 421
Dental caries 8, 330
— fistula 331
Dentigerous cysts 1, 23
Desmotomy, cervical 341
Diabetes mellitus in the dog . . 264
Diaphragmatic hernia 44
— — mechanism of 47
"Discordant" breathing . . . 204

ECHINOCOCCOSIS 504
Eczema, chronic 286
— in the dog 279
— in the horse 291
— rubrum 282
— seborrhœic 284
Elbow, penetrating wound of . . 435
Endocarditis, acute, in the horse . . 115
— — microbes in 118
— chronic 359
— malignant, ulcerative, or septic . . 120
— "purring murmur" in . . . 119
— vegetative or verrucous . . . 120
Epithelioma 584
— of vulva 424
Exophthalmic goitre 272
External tuberculosis in the dog and cat 100
Eyelid, lower, and globe of eye, tumour of 309

FACIAL sinuses, epitheliomata in . . 25

PAGE

Facial sinuses, fibrous polypi in . . 23
— — mucous cysts in . . . 23
— — myxomata in 23
— — purulent collections in . . 8
— — sarcomata in 24
— — tumours in 22
False nostrils, sebaceous cysts in . . 316
Fehling's test for sugar . . . 271
Fistula, dental 331
Fistulous withers 354
Flank, necrosis of aponeurosis of . 368
Flexor brachii muscle, injury of . . 433
— tendons, rupture of, after neurectomy 448
Foot, granuloma of 457
Foreign body in mouth . . . 334
— — in œsophagus 345
— — in rectum 385
Fracture of humerus in a horse . . 434
— of lower jaw 326

GALLINACEÆ, tuberculosis in . . 523
Gangrene, moist, of neck . . . 340
Glanders, treatment of . . . 600
Globe of eye and eyelid, tumour of . 309
Glycosuria 264, 269
Goat, experimental tuberculosis in . 575
Goitre, exophthalmic 272
Granuloma, infective 519
— of foot 457
Graves' disease 272
"Grease" 295
Gutta percha for "stopping" alveolar cavity after tooth extraction . . 10
Guttural pouch, operation on . . 335

HÆMOGLOBINURIA 249
— experimental 260
— nature of 258
Hæmorrhage, cerebral, in the horse . 305
Hemiplegia laryngis 347
Hepatisation of lung, changes in . 178, 194
Hernia, diaphragmatic . . 44, 373
— inguinal 35, 370
— ventral 369
Humerus, fracture of, in a horse . . 434
Hydatid cyst of heart 364
Hydrotherapy in pneumonia . . 200
Hydrothorax 202
Hydroxyl as dressing 444
Hyovertebrotomy 335
Hysteria in a mare 417

PAGE

Iliac arteries, thrombosis of . . 387
Impaction of the cæcum following dental caries 13
Imperforate vagina 423
Infective granuloma 519
Inferior maxilla, cancer of . . . 328
— — ostitis of 327
Influenza in the horse, abdominal form 210
Inguinal abscess, deep-seated, after castration 40
— hernia, acute 35
Insufficiency, aortic, in the horse . . 125
— mitral, in the horse . . . 132
Intermittency, cardiac . . 157, 361
Intestine, obstruction of . . . 377
— perforation of 378
Intra-orbital growth, cancerous . . 310
Intra-pericardial hæmorrhage . . 365
Intra-venous injection of iodine . . 607
Iodine, intra-venous injection of . . 607
— — — in pneumonia . . . 495

Jugular vein, phlebitis of . . . 341

Kelotomy 37
Kidney, cancer of 389
— carcinoma of 517
Knee, foreign body in 436
Knuckling over at fetlock . . . 445

Lateral ligament of pedal joint, necrosis of 449
Lip, pseudo-cancroid of . . . 324
Liver, abscess of 376
— echinococcosis of 504
— subcapsular hæmorrhage of . . 379
Lower jaw, fracture of 326
Lung, sarcomatous disease of . . 515
Lungs, echinococcosis of . . . 504
Luxation of patella 438
Lymphangitis and multiple abscesses due to staphylococci 97
— suppurating 444

Mallenders 295
Mammary adenoma 517
Maxilla, rodent cancer of . . . 29
Median and ulnar neurectomy . . 92
— neurectomy 447
Melanuria 254
Meningo-encephalitis . . 323
Mitral insufficiency 132
Moist gangrene of neck . . . 340
Myocarditis 142, 361
Myoma of œsophagus 358
Myositis, degenerative 257
Myxoma of uterus 423

Nasal cartilage, necrosis of . . . 315
— cavities, tumours in . . . 319
— polypi 16
— septum, necrosis of . . . 314
— sinuses, purulent inflammation of . 323
Neck, fœtid abscess in 347
— lacerated wound of . . . 344
— moist gangrene of 340
— sinus of 340
— wound of 338
Necrosis of cartilage of nostril . . 315
— of lateral ligament of pedal joint . 449
— of nasal septum 314
— of scapula 430
— of turbinated bone 317
Nephritis, acute 388
Neurectomy, median . . . 92, 447
— plantar 86
— — trophic changes after . . . 87
— ulnar 92, 447
"Nutmeg" liver 135
Nymphomania 416

Obstruction of intestine . . . 377
Œsophagus, foreign body in . . 345
— myoma of 358
Omasum, inflammation of . . . 469
Ossification of the cardiac auricles . 153
Ossifying periosteal sarcoma of shoulder 429
Ostitis of inferior maxilla . . . 327
Othæmatoma 285
Otitis, suppurating median . . . 298
Ovariotomy 416
Ovary, cystic degeneration of . . 421

Pachymeningitis 512
Papillary sarcoma of cheek . . . 326
Paradental epithelial *débris* . . . 2, 28
Paralysis of penis 411
Parasitic anæmia 504
Paresis of hind limbs 570
Parrots, tuberculosis of . . . 558
Patella, luxation of 438
Penis, amputation of, in the horse 56, 412

PAGE
Penis, atrophy of 414
— cancer of 410
— cancroids of 56
— necrosis of 09
— papillomata of 56
— paralysis of 57, 411
Pericarditis, "dry" 167
— hæmorrhagic 166
— in the dog 162
— rubbing sound in 166
— tapping for 169
— tuberculous, in the dog 164
Pericardium, foreign body in . . 365
Perinæum, rupture of 426
Pharyngitis, chronic 335
— due to strangles 219
Phlebitis of jugular vein 341
Picked-up nail, operation for . . 451
— — treatment of 78
Plantar neurectomy 86
Pleurisy, chronic, in the horse . . 202
Pneumococcus 174
Pneumonia 480
— Friedländer's bacillus of . . . 174
— in the horse 170
— — contagious 185
— intra-venous injection of iodine in . 495
— quinine in 482
— salt solution in 493
— sporadic, fibrinous, croupous, or pneumonia *à frigore* 172
Poll-evil 339
Polydipsia 268
Polyuria 268
Popliteal glands, abscess in . . . 444
Posterior aorta, rupture of . . . 386
Prolapse of uterus 422
Prolapsus vaginæ in a mare . . . 418
Prostate, diseased, in dog 391
Pseudo-cancroid of lip 324
Pulmonary artery, rupture of . . 366
— gangrene 177
Purpura hæmorrhagica 496
— — injection of normal horse serum in 497
Purulent collections in the facial sinuses 8
— inflammation of nasal sinuses . 323

QUININE in pneumonia 482
Quittor 449

PAGE
RADIAL paralysis in the horse . . 64
Rectum, foreign body in 385
Retro-pharyngeal glands, cold abscess in 336
Rheumatism 511
Rib, fracture of 357
— necrosis of 357
"Rig" operations 397
Right ventricle, rupture of . . . 366
Roaring, chronic, surgical treatment of 30, 347
Rodent cancer of maxilla 29

SALLENDERS 295
Salt solution in pneumonia . . . 493
Sarcoma 585
— cutaneous 106
— ossifying periosteal, of shoulder . 429
— papillary, of cheek 326
— round-celled, of testicle 516
Sarcomatous disease, a case of . . 106
— — of lung 515
Scapula, necrosis of 430
Scapulo-humeral articulation, disease of 432
Scirrhous cord 408
Scrotum, cancer of 405
Sebaceous cysts in false nostril . . 316
Semi-tendinosus muscle, ossification of tendon of 442
Serotherapy in pneumonia 200
Sérum antityphique in contagious pneumonia 189
Serum injections in purpura hæmorrhagica 497
Sesamoid ligaments, rupture of . . 461
Shoulder, ossifying periosteal sarcoma of 429
Sinus of neck 340
Spavin 445
— nature of 72
— neurectomy in treatment of . . 76
— treatment of 72
Spermatic aneurismal varix . . . 408
Stomach, cancer of 374
"Stopping" alveolar cavity after removal of tooth 10
Superior maxilla, cancer of . . . 22
Supernumerary tooth in the temporal region 298
Suppurating lymphangitis 444
Symbiotic acariasis and eczema of the ear 312

PAGE

Synovitis, suppurating, of carpal sheath 437

TACHYCARDIA 157, 272
Tail, cancer of 287, 427
Tapping the chest 207
Temperature table (comparison of Centigrade and Fahrenheit scales) . 613
Tendon sheaths in front of hock, distension of 446
Testicle, cancer of 405
— round-celled sarcoma of . . . 516
Tetanus 498
— Behring's antitoxin in . . . 501
— injection of salt solution in . . 499
Thoracentesis 207
Thrombosis of iliac arteries . . . 387
Tibia, fracture of 443
Tongue, section of 333
Trachea, rupture of 344
Traumatic cataract 311
Tubercle lesions in pheasants . . 529
— — in fowls 530
Tuberculosis, avian 522
— comparative frequency of thoracic and abdominal lesions in . . 237, 244
— conveyance from man to parrot . 566
— experimental, in the goat . . 575
— external, in the dog and cat . . 101
— — lesions of 471
— in the cat 244, 473
— — mode of infection in . . . 247
— in the cow 469
— in the dog 234
— in the Gallinaceæ 523
— in the horse 225, 463
— mammalian and avian, relations between 573

PAGE

Tuberculosis of cerebrum 470
— of parrots 558
— pulmonary, transmission from man to cat 475
— transmission from man to paroquet 475
— treatment of 595
"Tuberculous septicæmia" 240
Tumour of eyelid and globe of eye . 309
— of vertebral column 308
Tumours in facial sinuses 22
— in nasal cavities 319
— malignant, conclusions regarding . 593
— — in animals 579
— of the brain 300, 301, 304
— of the cerebellum 303, 304
Turbinated bone, chronic inflammation of 317
— — disease of, in the horse . . 14
— — mucous degeneration of (Sand's disease) 17
— — new growths on 16
— — pus in necrosis of 18

ULNAR neurectomy 447
Urethral calculus 414
Urethrotomy for calculus 415
Uterus, myxoma of 423
— prolapse of 422

VAGINA, imperforate 423
Vanadine, on the action of . . . 604
Ventricle, right, rupture of . . . 366
Vertebral column, tumour of . . . 308
Vulva, epithelioma of 424

WITHERS, fistulous 354
Wound of neck 338

PRINTED BY ADLARD AND SON,
BARTHOLOMEW CLOSE, LONDON, E.C., AND 20, HANOVER SQUARE, W.

WELLCOME LIBRARY INSTITUTE

In one volume, 433 pages, 406 illustrations, price 15/- net.

A

HANDBOOK OF HORSE-SHOEING

WITH INTRODUCTORY CHAPTERS ON THE ANATOMY AND PHYSIOLOGY OF THE HORSE'S FOOT.

By JNO. A. W. DOLLAR, M.R.C.V.S.,

Translator and Editor of Möller's 'Veterinary Surgery,' 'An Atlas of Veterinary Surgical Operations,' etc.; Membre Correspondant de la Société de Médecine Vétérinaire de Paris, etc.

With 54 full-page plates and descriptive notes supplied by

ALBERT WHEATLEY, F.R.C.V.S.,

Late Examiner in Farriery to the Berks County Council.

CONDENSED SYLLABUS.

INTRODUCTION. HISTORY OF HORSE-SHOEING.

PART I.

SECT. I.—*The Structure of the Foot* (with chapters on the bones, ligaments, muscles, elastic tissues, blood-vessels, nerves, skin, and horn).

SECT. II.—*The Functions of the Foot.* 72 illustrations.

PART II.

SECT. I.—*Materials for and Methods of making Shoes* (chapters on aluminium, bronze, paper, and nailless shoes, shoes and their properties, forging the shoe, varieties of shoes, rough nailing, sharp heels and toes, frost screws, frost cogs, removable toe-grips), with 70 illustrations.

SECT. II.—Chapters on normal and abnormal limbs, feet and action; how the shoe and hoof are worn, control of horse during shoeing, choosing shoe, preparing hoof for shoeing, and working without shoes.

The Shoeing of (1) Hacks, (2) Hunters, (3) Race Horses, (4) Trotting Horses, (5) Carriage Horses, (6) Omnibus Horses, (7) Cart Horses, (8) the Charlier Shoe, (9) Tips, etc., etc., with 56 Large Plates.

Shaping and fitting the shoe, the nails, nailing on the shoe, examination after shoeing, disadvantages of shoeing, etc.

Shoes for Forging and Cutting, with 20 Large Plates.

SECT. III.—**The Shoeing of Diseased Feet and of Lame Horses** (with chapters on fever in the feet, contracted foot, sandcrack, pricks in shoeing, picked-up nails, treads on the coronet, corns, horn tumours, canker of the sole and frog, sidebone, navicular disease, curb, strained tendons and capped elbows), with 90 illustrations.

SOME PRESS NOTICES OF THE ABOVE WORK.

"A masterly work, most exhaustive and elaborate in every detail, and most copiously and beautifully illustrated. It is the *magnum opus* of one of the most erudite and most respected leaders of the veterinary profession."—*North British Agriculturist.*

"A singularly exhaustive and admirably analytical Handbook. . . . It deals in minute detail with every phase of the ancient craft. . . . The diagrams accompanying the book are of exceeding value."—*Daily Telegraph.*

"They have certainly produced the best printed, the best illustrated, and the most scientific book on Horse-shoeing in the English language. . . . Our general impression of the work is that it contains probably all that is worth knowing about shoeing and the foot. . . . No pains and no expense have been spared to reach the highest possible standard, and success has attended the effort."—*Veterinary Record.*

"Is throughout written in a clear and business-like fashion. . . . A standard book, to be used with equal confidence for purposes of study and of research."—*Scotsman.*

"This book is a very full and complete treatise; and its authors, and especially Mr. Dollar, bring to its elucidation a large fund of practical knowledge."—*Glasgow Herald.*

"This work, beautifully printed on thick paper, and illustrated with a very large number of excellent and instructive woodcuts, is unquestionably the most complete which has been issued upon this special subject."—*Manchester Guardian.*

"Thoroughly exhaustive yet skilfully condensed in treatment, . . . the Handbook, which is beautifully and profusely illustrated, deserves a cordial welcome."—*Dundee Advertiser.*

"*A Handbook of Horse-shoeing* is in itself a final proof, if such were needed, of the high importance and the complex difficulties of a very ancient craft. . . . The subject is exhaustively treated."—*Yorkshire Post.*

"An attractively written, voluminous, and practical publication, . . . profusely illustrated in a high-class style. . . . Should at once be found on the bookshelf of every go-ahead horse-owner."—*Irish Farming World.*

"Mr. Dollar's work will add to the reputation which his former publications have won for him. . . . The work is, in short, a credit alike to the author and publisher."—*Aberdeen Daily Free Press.*

EDINBURGH: DAVID DOUGLAS, 10, Castle Street.

In one volume, royal 8vo, 722 pages. Price 21/-, Post Free for 16/3.

MÖLLER'S OPERATIVE VETERINARY SURGERY

TRANSLATED AND EDITED FROM THE SECOND ENLARGED AND IMPROVED EDITION

By JNO. A. W. DOLLAR, M.R.C.V.S.

WITH 142 ILLUSTRATIONS.

"No practitioner who aspires to keep abreast of the times, or who means to keep in touch with the advances of modern Veterinary Surgery, can afford to do without it."—*Veterinarian.*

"Mr. Dollar has done good service to English-speaking Veterinarians all over the world by bringing *Möller's Veterinary Surgery* within their reach. To say that the work is comprehensive is to give but a faint indication of its scope, yet its special feature is its concise treatment of each subject—in the sense, that is to say, of economy of diction. It is impossible to read a page in any part of the book without being impressed with the conviction that the author has something to say, and is determined to say it in such a manner as to leave no doubt of his meaning."—*Field.*

"Mr. Dollar has done a great service to Veterinary Science by this translation of *Möller's Surgery*, a work of more than European fame. It ought to be in the library of every member of the veterinary profession."—*Edinburgh Medical Journal.*

"Both common and obscure diseases are treated with a degree of detail which only the most experienced and acute observer could command. . . . A text-book which both students and busy practitioners will find of inestimable value."—*Liverpool Daily Post.*

"The book gives a full and complete account of all the operative procedures which the veterinary surgeon is likely to be called upon to undertake. The descriptions are precise, and the science of the book is excellent; and being drawn from a very large experience, is on that account likely to be the more helpful to practitioners."—*Glasgow Herald.*

60 *large pages* (14½ × 10 *inches*), 315 *illustrations, price* 10/6.
First edition exhausted.

AN ATLAS OF VETERINARY SURGICAL OPERATIONS.

Just published, demy 8vo, 40 pages, illustrated with Wood Engravings and 10 full-page Process Blocks, price 2s. 6d. net.

A SURGICAL OPERATING TABLE FOR THE HORSE

By JNO. A. W. DOLLAR, M.R.C.V.S.,

Corresponding Member of the Central Society of Veterinary Medicine of Paris; Life Member of the Royal Italian Society of Hygiene; Corresponding Associate of the Royal Spanish Society of Hygiene; Corresponding Member of the Society of Veterinary Medicine of Brabant (Belgium); Honorary Associate of the Spanish Society of Arts; Corresponding Associate of the Spanish Gynæcological Society (Veterinary Section); Author of 'Horse-shoeing and the Horse's Foot,' 'An Atlas of Veterinary Surgical Operations,' etc.

The disadvantages and dangers of the older systems of controlling horses for operation have long exercised the minds of practitioners, and, abroad at least, have induced numerous inventors to attempt the production of an effective operating table. Mr. Dollar believes such a table has at last been devised. In an introductory chapter he briefly sketches the various tables, trevises, etc., hitherto produced, pointing out their merits and defects. The body of the work is reserved for the particular apparatus recommended. Originally invented by a French veterinary surgeon, this apparatus has been somewhat modified, and in its present form has been fully tested by over a year's continued use in Mr. Dollar's hospital. Full details are given of the apparatus, its manner of use, and of certain new operations which it renders practicable. To busy operators the apparatus will prove extremely valuable, and Mr. Dollar's description of it be found of the highest interest.

EDINBURGH: DAVID DOUGLAS, 10, Castle Street.